

Modified Arthroscopic McLaughlin Procedure in the Treatment of Posterior Glenohumeral Instability— Technical Note*

McLaughlin artroscópico modificado no tratamento de luxação glenoumeral posterior—nota técnica

Tiago Pinheiro Torres^{1,2,3} Sara Lima^{2,3} Manuel Gutierre^{2,3,4}

¹Centro Hospitalar de Vila Nova de Gaia, Vila Nova de Gaia, Portugal

²Casa de Saúde da Boavista, Porto, Portugal

³Hospital CUF, Porto, Portugal

⁴Centro Hospitalar de São João, Porto, Portugal

Address for correspondence: Tiago Pinheiro Torres, Centro Hospitalar de Vila Nova de Gaia, Vila Nova de Gaia, Portugal (e-mail: tiagocpt@gmail.com).

Rev Bras Ortop 2019;54:228–232.

Abstract

The diagnosis of and the treatment for traumatic posterior shoulder dislocation are challenging. Some series describe that between 60 and 80% of these lesions are not diagnosed during the first visit to the emergency room. As such, dislocations are frequently found after several days or even weeks, adding complexity to their treatment. Posterior dislocations are usually accompanied by a print fracture on the anterior surface of the humeral head, known as reverse Hill-Sachs injury. This bone defect can “engage” into the posterior glenoid ridge, leading to recurrent instability and progressive joint destruction. The authors describe a modified arthroscopic McLaughlin procedure, which allows filling the bone defect with the upper third of the subscapular tendon, avoiding recurrence of the posterior instability. Next, a posterior Bankart lesion repair is performed along with a tenodesis of the long portion of the bicipital tendon. This technique, in addition of repairing the posterior chondrolabral lesion, creates a remplissage effect, making the repair stronger and representing an optimal procedure for the definitive treatment of recurrent posterior luxation. It is an entirely arthroscopic procedure, avoiding the disadvantages of an open procedure.

Keywords

- ▶ arthroscopy
- ▶ shoulder articulation
- ▶ shoulder dislocation
- ▶ posterior shoulder instability

Resumo

A luxação do ombro posterior traumática é de difícil diagnóstico e tratamento. Há séries que descrevem que 60%-80% dessas luxações não são diagnosticadas numa primeira ida ao serviço de urgência. Desse modo, casos de luxações com vários dias e por vezes semanas são frequentes, o que sempre torna o tratamento mais complexo. As luxações posteriores são geralmente acompanhadas por uma fratura de impressão na superfície anterior da cabeça umeral, conhecida como lesão de Hill-Sachs reversa. Esse defeito ósseo pode “enclavar” na borda glenoidal posterior e levar a instabilidade

* Work developed at the Casa de Saúde da Boavista, Porto, Portugal.

Palavras-chave

- ▶ artroscopia
- ▶ articulação do ombro
- ▶ luxação do ombro
- ▶ instabilidade posterior do ombro

recorrente e destruição progressiva da articulação. Os autores descrevem um procedimento de McLaughlin artroscópico modificado, que permite o preenchimento do defeito ósseo com o terço superior do tendão subescapular, evita a recorrência da instabilidade posterior. Associadamente, fez-se uma reparação da lesão de Bankart posterior e uma tenodese da longa porção do tendão bicipital. Essa técnica, além de reparar a lesão condrolabral posterior, cria um efeito de remplissage anterior, o que torna a reparação mais forte, é um ótimo procedimento no tratamento definitivo da luxação posterior recidivante. É um procedimento inteiramente feito por via artroscópica, não apresenta as desvantagens dos procedimentos abertos.

Introduction

The posterior dislocation of the glenohumeral joint is a rare lesion representing < 2% of all shoulder dislocations, and its diagnosis and treatment are difficult. Some series describe that between 60 and 80% of these injuries are not diagnosed at a first emergency room visit, mostly due to the lack of a critical physical examination, to an inadequate radiographic examination, or to an inability of film reviewing by the assistant orthopedist. It may occur following trauma, convulsions, or electric shock. Thus, it is common to find dislocations with several days and sometimes weeks of evolution, adding complexity to the treatment.¹ Posterior dislocations are usually accompanied by a print fracture on the anterior surface of the humeral head, known as reverse Hill-Sachs injury.² This bone defect can “engage” into the posterior glenoid ridge, leading to recurrent instability and progressive joint destruction.³

Treatment options vary and depend on the size of the humeral head defect, on the duration of the dislocation, and on the degree of instability. Several techniques have been described to treat this type of lesion, including defect elevation and filling with bone graft, transposition of the subscapularis tendon (McLaughlin procedure) or of the small tuberosity into the defect, rotational osteotomy of the proximal humerus and/or shoulder arthroplasty.⁴

The authors describe a modified arthroscopic McLaughlin procedure, which allows filling the bone defect with the upper third of the subscapular tendon, avoiding recurrence of the posterior instability. In addition, a posterior Bankart lesion repair was performed.

This technique, in addition to repairing the posterior chondrolabral lesion, creates an anterior remplissage effect,⁵ which makes the retraction stronger and maintains the integrity of two-thirds of the subscapularis tendon; it is an optimal procedure for the definitive treatment of recurrent posterior dislocation. It is an entirely arthroscopic procedure, avoiding the disadvantages of an open surgery.

Material and Methods**Case Report**

A 45-year-old man fell from a bicycle, resulting in a right shoulder injury. He was treated in an institution where

maneuvers for shoulder dislocation reduction were performed. A magnetic resonance imaging (MRI) exam and a computed tomography (CT) scan were performed, and, 15 days later, the patient was referred to a shoulder specialist. At consultation, at 15 days of evolution, the patient presented with a posterior glenohumeral dislocation with a significant reverse Hill-Sachs injury of between 25 and 30% of the joint surface size (→Figs. 1, 2).

Surgical Technique

The patient was submitted to locoregional anesthesia with interscalene block and general anesthesia; beach chair positioning; successful reduction of the dislocated shoulder through manipulation under radiographic control.

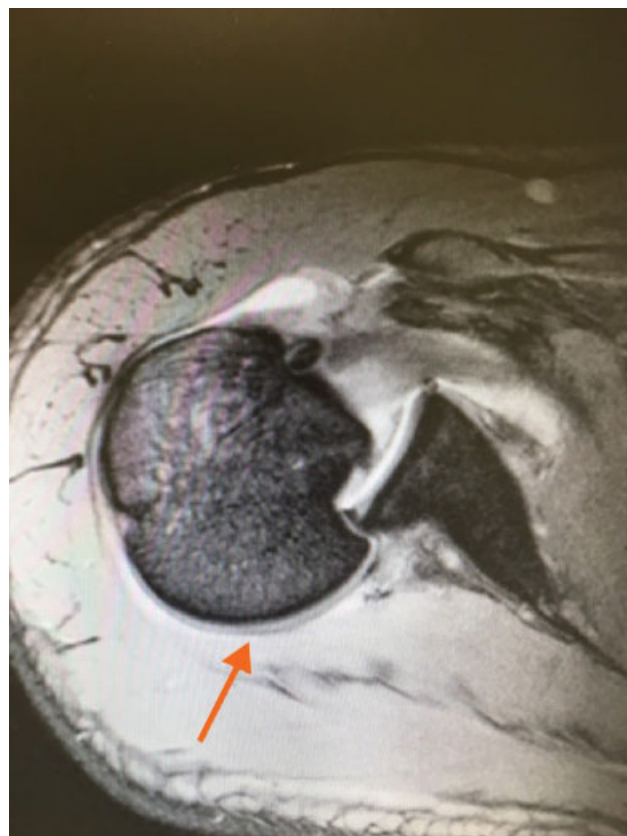


Fig. 1 Computed tomography scan showing an “engaged” posterior dislocation.

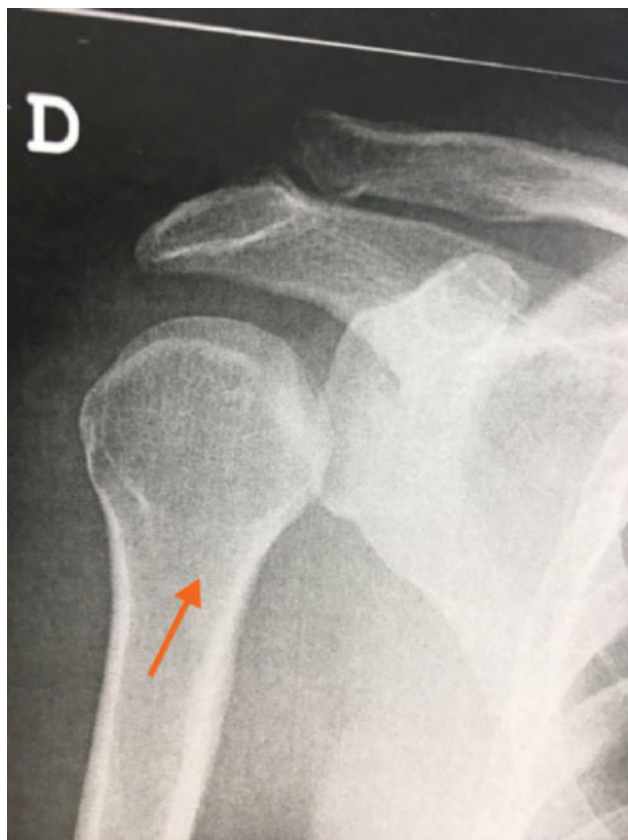

Fig. 2 Radiography showing the unreduced posterior glenohumeral dislocation.

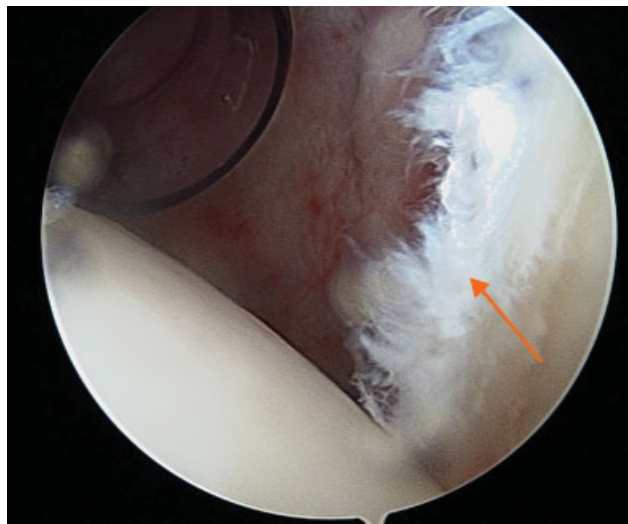


Fig. 3 Posterior Bankart lesion viewed through the anterior portal.

The arthroscopy began through the posterior portal: visualization of the posterior Bankart lesion with labral disinsertion from 7 hours to 11 hours (►**Fig. 3**) and reverse Hill-Sachs injury (►**Fig. 4**); visualization of the glenoid tracking/excursion⁶ and of an “engaging” Hill-Sachs injury (►**Fig. 5**); through the rotator interval portal, soft tissue tenodesis of the long portion of the biceps tendon due to marked tenosynovitis at the bicipital gutter region; isolation of the proximal third of the subscapularis tendon (►**Fig. 6**) and its tenodesis in the Hill-Sachs injury region

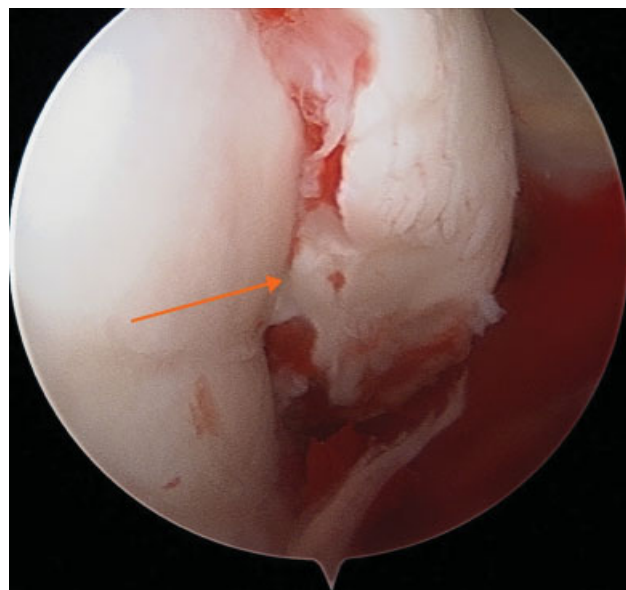


Fig. 4 Reverse Hill-Sachs injury with 25–30% of humeral head size.

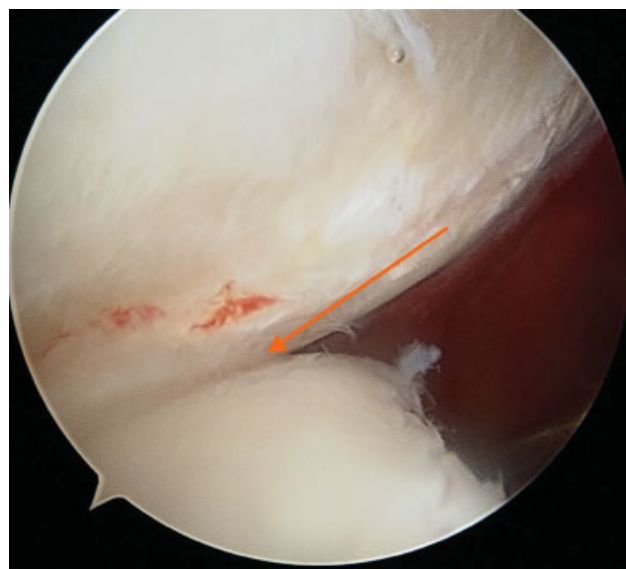


Fig. 5 Arthroscopic study of the glenoid tracking/excursion evidencing an “engaged” type lesion.

with a 4.5 mm PEEK anchor loaded with nonabsorbable wires (remplissage effect) (►**Figs. 7, 8**); Bankart lesion repair with posterior labrum treatment using 2.9 mm instability anchors loaded with nonabsorbable wires (►**Figs. 9, 10**); verification of the construction stability by glenoid tracking evaluation.

Rehabilitation

The patient was immobilized for 6 weeks. Pendulum movements were allowed in the 2nd week. Physical therapy started at 6 weeks.

Results

At 1-year of follow-up, the patient presented a slight loss of internal rotation. The remaining mobility is comparable to

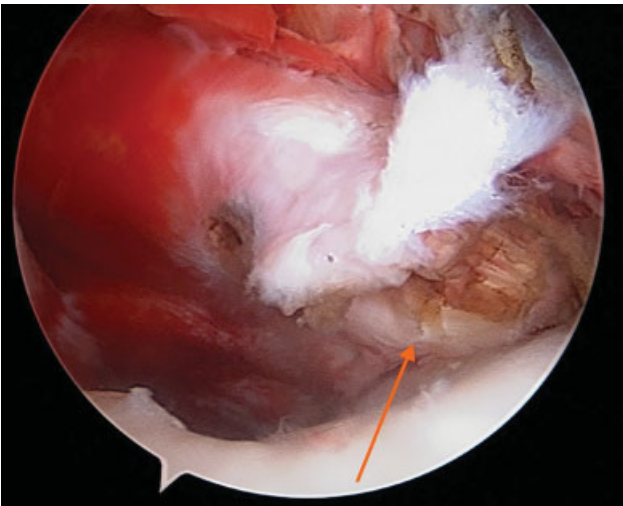


Fig. 6 Disinsertion of the upper third of the subscapular tendon. Joint visualization through the posterior portal.

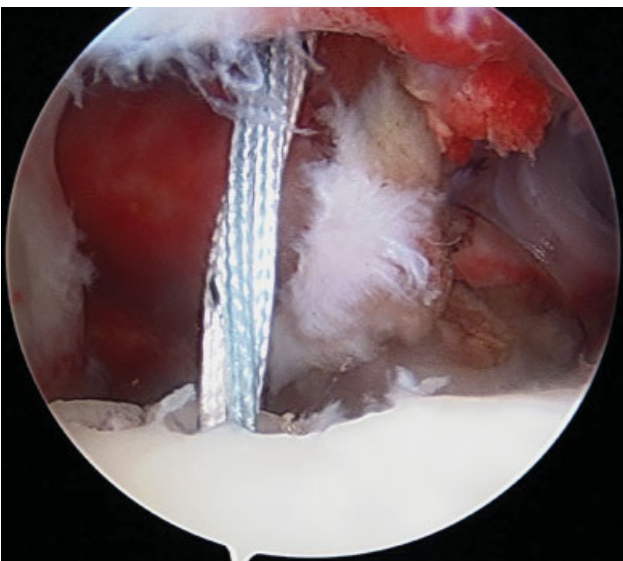


Fig. 7 Anchor placement in a reverse Hill-Sachs injury.

the contralateral shoulder. The constant score was 84%, with anterior extension of 163°, external rotation of 60°, internal rotation of 50°, and 140° of abduction. No new episodes of instability occurred.

Discussion

The posterior dislocation of the shoulder is an infrequent lesion. Because of its rarity and high rate of diagnostic failure, McLaughlin termed it the “diagnostic trap.” Once diagnosed, the treatment of this lesion should be individualized, depending on the size of the humeral head defect and on the duration of the injury. The size of the humeral head impaction fracture/reverse Hill-Sachs injury is critical in the decision-making process.⁷

In lesions $\leq 25\%$ of the joint surface size, patients with dislocations < 3 weeks old can be treated with closed reduction and external rotation immobilization. However, for

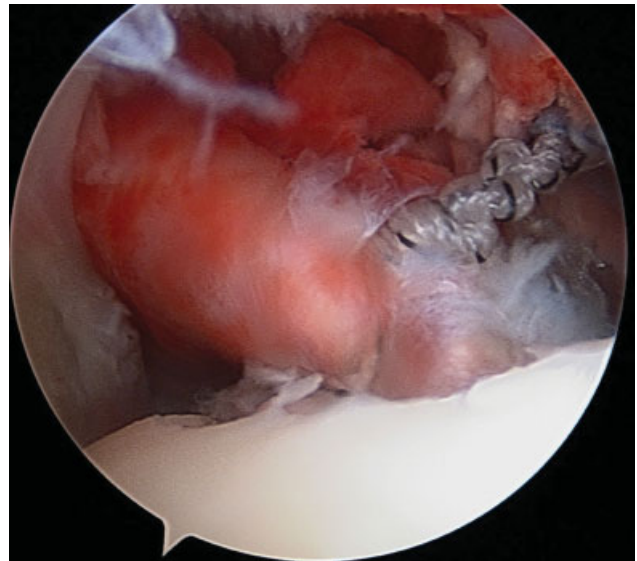


Fig. 8 Tenodesis of the upper third of the subscapular tendon in a reverse Hill-Sachs injury – remplissage effect – modified McLaughlin procedure.

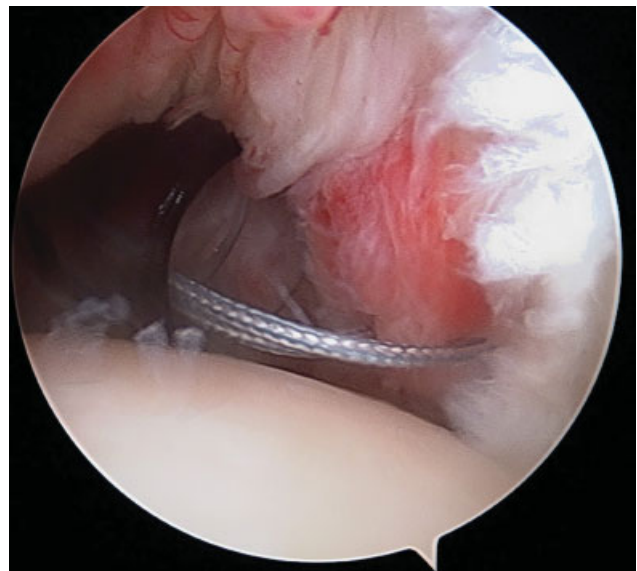


Fig. 9 Posterior Bankart lesion repair using anchors and nonabsorbable wires.

chronic dislocations (> 3 weeks old), the closed reduction has a high rate of poor results. In defects $> 50\%$ of the joint surface size, the patients should be treated with a shoulder arthroplasty. Defects between 25 and 50% of the joint surface size are very challenging for the orthopedist.⁸

One of the main advantages of the described procedure is the ability to perform it arthroscopically, as opposed to traditional open procedures. Although it is only a clinical case, not enough to support a recurrence rate reduction, the presented technique offers potential benefits in decreasing subsequent instability.

The literature on this subject is limited. Krackhardt et al⁹ described the arthroscopic subscapular mobilization and subsequent fixation in the reverse Hill-Sachs injury for the treatment of posterior instability in 2006. Duey et al²

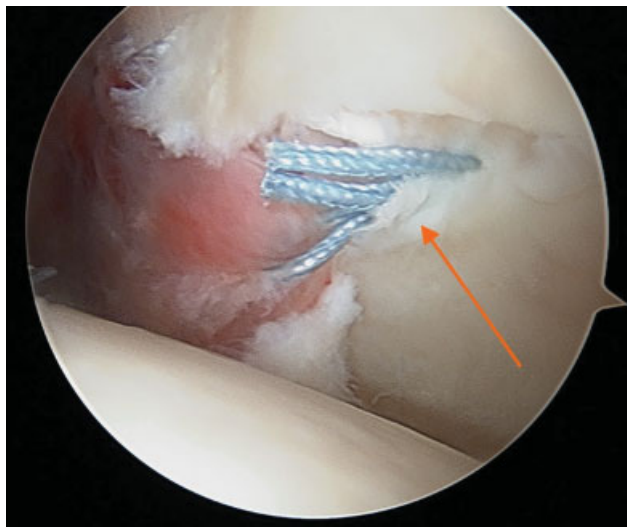


Fig. 10 Posterior Bankart lesion repair.

described an arthroscopic technique in which the Hill-Sachs reverse injury was filled with the medial glenohumeral ligament. Other authors have reported a modified arthroscopic McLaughlin procedure in which the bone defect is filled with the subscapular tendon.^{9–11}

Final Considerations

The authors describe an entirely arthroscopic technique for the treatment of posterior shoulder dislocation. The McLaughlin procedure proved to have good results by an open approach with the transference of the subscapularis tendon to the reverse Hill-Sachs humeral defect. The technique described above, in addition to the arthroscopic technique, only uses the upper third of the subscapular tendon and is associated to a posterior Bankart repair to gain stability.

In cases of posterior instability without expressive bone loss, the reconstruction of the posterior Bankart lesion by arthroscopy has shown good results; as such, this procedure should be performed in situations of unsuccessful Bankart surgeries, of large bone defects, and in patients in whom the

glenoid tracking evaluation shows an “engaging” reverse Hill-Sachs injury.

Conflicts of Interest

The authors have no conflicts of interest to declare.

References

- 1 Jones TP, Beckenbaugh JP, Sperling JW, Amrami KK, Sundaram M. Your diagnosis? Posterior shoulder dislocation. *Orthopedics* 2003;26(07):745–746, 682
- 2 Duey RE, Burkhart SS. Arthroscopic treatment of a reverse hill-sachs lesion. *Arthrosc Tech* 2013;2(02):e155–e159
- 3 Di Giacomo G, Itoi E, Burkhart SS. Evolving concept of bipolar bone loss and the Hill-Sachs lesion: from “engaging/non-engaging” lesion to “on-track/off-track” lesion. *Arthroscopy* 2014;30(01):90–98
- 4 McLaughlin HL. Posterior dislocation of the shoulder. *J Bone Joint Surg Am* 1952;24A(03):584–590
- 5 Wolf EM, Pollack M, Smalley C. Hill-Sachs “remplissage”: an arthroscopic solution for the engaging Hill-Sachs lesion (SS-02). *Arthroscopy* 2007;23(6, Suppl):e1–e2
- 6 Yamamoto N, Itoi E, Abe H, Minagawa H, Seki N, Shimada Y, et al. Contact between the glenoid and the humeral head in abduction, external rotation, and horizontal extension: a new concept of glenoid track. *J Shoulder Elbow Surg* 2007;16(05):649–656
- 7 Cicak N. Posterior dislocation of the shoulder. *J Bone Joint Surg Br* 2004;86(03):324–332
- 8 Loebenberg MI, Cuomo F. The treatment of chronic anterior and posterior dislocations of the glenohumeral joint and associated articular surface defects. *Orthop Clin North Am* 2000;31(01):23–34
- 9 Krackhardt T, Schewe B, Albrecht D, Weise K. Arthroscopic fixation of the subscapularis tendon in the reverse Hill-Sachs lesion for traumatic unidirectional posterior dislocation of the shoulder. *Arthroscopy* 2006;22(02):227.e1–227.e6
- 10 Millett PJ, Clavert P, Hatch GF III, Warner JJ. Recurrent posterior shoulder instability. *J Am Acad Orthop Surg* 2006;14(08):464–476
- 11 Martetschläger F, Padalecki JR, Millett PJ. Modified arthroscopic McLaughlin procedure for treatment of posterior instability of the shoulder with an associated reverse Hill-Sachs lesion. *Knee Surg Sports Traumatol Arthrosc* 2013;21(07):1642–1646, 23052127