

Femoroacetabular Impingement – Factors Associated with the Presence of Deep Injuries of the Chondrolabral Junction*

Impacto femoroacetabular – Fatores associados à presença de lesões profundas da junção condrolabral

Samuel Faccioni¹  Vinicius Adelchi Cachoeira¹ Gabriel Pozzobon Knop¹
Luiz Henrique Penteado Silva¹ Tercildo Knop¹

¹Institute of Orthopedics and Traumatology, Hospital São Vicente de Paulo, Passo Fundo, RS, Brazil

Endereço para correspondência Samuel Faccioni, Instituto de Ortopedia e Traumatologia (IOT), Hospital São Vicente de Paulo, Passo Fundo, RS, 99010-112, Brazil
(e-mail: faccionis@yahoo.com.br; pesquisa2@hsvp.com.br).

Rev Bras Ortop 2019;54:434–439.

Abstract

Objective The purpose of the present study was to evaluate factors associated with the presence of deep chondral lesions (Konan/Haddad grades III and IV) in patients submitted to hip arthroscopy to treat femoroacetabular impingement (FAI).

Method This was a prospective, cross-sectional study of a series of 125 consecutive hip arthroscopies performed between May 2016 and May 2017. After applying the exclusion criteria, 107 hips of 92 patients submitted to surgical treatment for mixed and CAM FAI were analyzed. For purposes of analysis, the present study considered groups with lesions considered mild and deep, which were associated with symptom score, lateral coverage angle, α angle, age, gender, and radiological classification of arthrosis. Results with a p -value < 0.05 were considered statistically significant.

Results Patients whose hips had lesions considered deep had significantly higher non-arthritic hip scores (NAHSs) than those whose hips presented lesions considered mild or who did not present chondral lesions (67.9 ± 19.4 versus 57.0 ± 21.9 , $p = 0.027$). The prevalence of deep lesions was higher in hips with Tonnis 1 compared with hips with Tonnis 0: 15 (55.6%) versus 10 (12.7%), respectively, $p < 0.001$. Men presented a higher prevalence of grades III and IV lesions than women, 23 (34.3%) versus 2 (5.0%), $p = 0.001$, and had significantly higher functional scores (65.6 ± 19.6 versus 49.3 ± 21.6 , $p < 0.001$).

Conclusion Men presented a higher prevalence of deep lesions. Hips classified as Tonnis 1 presented a 4.4-fold higher probability of presenting these lesions. Patients with deep chondrolabral lesions had a better preoperative functional score.


Keywords

- ▶ femoroacetabular impingement
- ▶ arthroscopy
- ▶ hip

Resumo

Objetivo Avaliar os fatores associados à presença de lesões condrais profundas (graus III e IV de Konan/Haddad) em pacientes submetidos à artroscopia do quadril para tratamento do impacto femoroacetabular (IFA).

* Originally Published by Elsevier Editora Ltda.

 Samuel Faccioni's ORCID is <https://orcid.org/0000-0002-3991-1499>.

Método Estudo transversal, prospectivo, de uma série de 125 artroscopias consecutivas do quadril feitas entre maio de 2016 e maio de 2017. Depois de aplicados os critérios de exclusão, foram analisados 107 quadris de 92 pacientes submetidos a tratamento cirúrgico do IFA dos tipos misto e CAM. Para fins de análise, os grupos foram divididos entre lesões consideradas leves e profundas, e foi feita associação com escore de sintomas, ângulo de cobertura lateral, ângulo alfa, idade, gênero, e classificação radiológica de artrose. Foram considerados como estatisticamente significativos testes com valor de probabilidade $< 0,05$.

Resultados Pacientes cujos quadris apresentaram lesões consideradas profundas tiveram escores de quadril não artrítico (NAHSs, na sigla em inglês) significativamente maiores do que aqueles cujos quadris apresentavam lesões consideradas leves ou não apresentavam lesão condrolabral ($67,9 \pm 19,4$ versus $57,0 \pm 21,9$; $p = 0,027$). A prevalência de lesões profundas foi maior nos quadris Tonnis 1 do que nos que apresentaram Tonnis 0: 15 (55,6%) versus 10 (12,7%), respectivamente; $p < 0,001$. Homens apresentaram melhores escores funcionais e maior prevalência de lesões graus III e IV do que as mulheres: $65,6 \pm 19,6$ versus $49,3 \pm 21,6$; $p < 0,001$, e 23 (34,3%) versus 2 (5,0%), $p = 0,001$, respectivamente.

Conclusão Homens apresentaram maior prevalência de lesões profundas. Quadris Tonnis 1 tiveram um risco 4,4 vezes maior de apresentar essas lesões. Pacientes com lesões condrolabrais profundas apresentaram melhor escore funcional pré-operatório.

Palavras-chave

- ▶ impacto femoroacetabular
- ▶ artroscopia
- ▶ quadril

Introduction

Since Beck et al¹ described the chordal lesion mechanism due to CAM-type femoroacetabular impingement (FAI), in which chondral delamination results from the shear forces caused by the alteration of the femoral head-neck normal morphology, numerous studies have been carried out to enhance the diagnosis and early treatment of these lesions, as well as to evaluate the outcomes from the surgical treatment, including techniques such as microfracture, chondrocyte implantation, and fibrin glue, which are dependent on the poor regeneration capacity of the chondral tissue.²

It is well-known that patients with hip osteoarthritis have a high risk of early conversion to arthroplasty³ and arthroscopic treatment failure,⁴ and that isolated chondral lesions of the hip are factors of poor prognosis for surgical treatment.⁵⁻⁷ Chondral delamination frequently occurs in patients with FAI.^{1,8-11} Its diagnosis, however, is often made only during the surgical procedure and, sometimes, patients with nonluxuriant symptomatology present extensive cartilaginous lesions.

There is already consensus that some factors are associated with chondral lesions. In addition to the preoperative finding of these lesions in magnetic resonance imaging studies,¹² the presence of arthrosis in grade II or higher of Tonnis,¹³ the CAM-type impingement is directly associated with the development of chondral flaps.¹⁴ Studies also demonstrate the association of chondral lesions of the hip with age and the male gender.^{1,4,13}

In transoperative diagnosis, classification systems are used to determine articular cartilage involvement. The classic classification of Outerbridge,¹⁵ deemed universal since it is used to classify chondral lesions in various joints, is moderately repro-

ducible and reliable.¹⁶ The Beck system was developed to classify chondral lesions during controlled hip dislocation for FAI treatment.¹⁷ More recently, the arthroscopic classification of Haddad¹⁸ (→ **Table 1**), was specifically described for hip lesions found during the arthroscopic procedure and it is related to chondral lesion progression. This classification system determines lesion location in quadrants, the presence of chondrolabral junction damage and, finally, the extent of the lesion. Chondrolabral junction damage is defined by lesion progression, where 0 is absence of lesion, grade I is defined by the presence of a wave sign (→ **Fig. 1A**), grade II is the damage to the chondrolabral junction, but with no acetabular cartilage delamination (→ **Fig. 1B**), and grade III is a lesion with subchondral bone cartilage detachment (→ **Fig. 1C**). Finally, in grade IV, there is subchondral bone exposure (→ **Fig. 1D**). This classification presents the best intra- and interobserver correlation when compared with the two aforementioned systems.¹⁷

Table 1 Arthroscopic classification of Haddad¹⁸

Grade 0	No chondral lesion.
Grade I	Wave sign, loss of subchondral bone fixation.
Grade II	Obvious chondrolabral junction rupture, but no evidence of cartilage delamination from the subchondral bone at probe exploration.
Grade III	Delamination with cartilage separation from the subchondral bone.
Grade IV	Exposed subchondral bone.

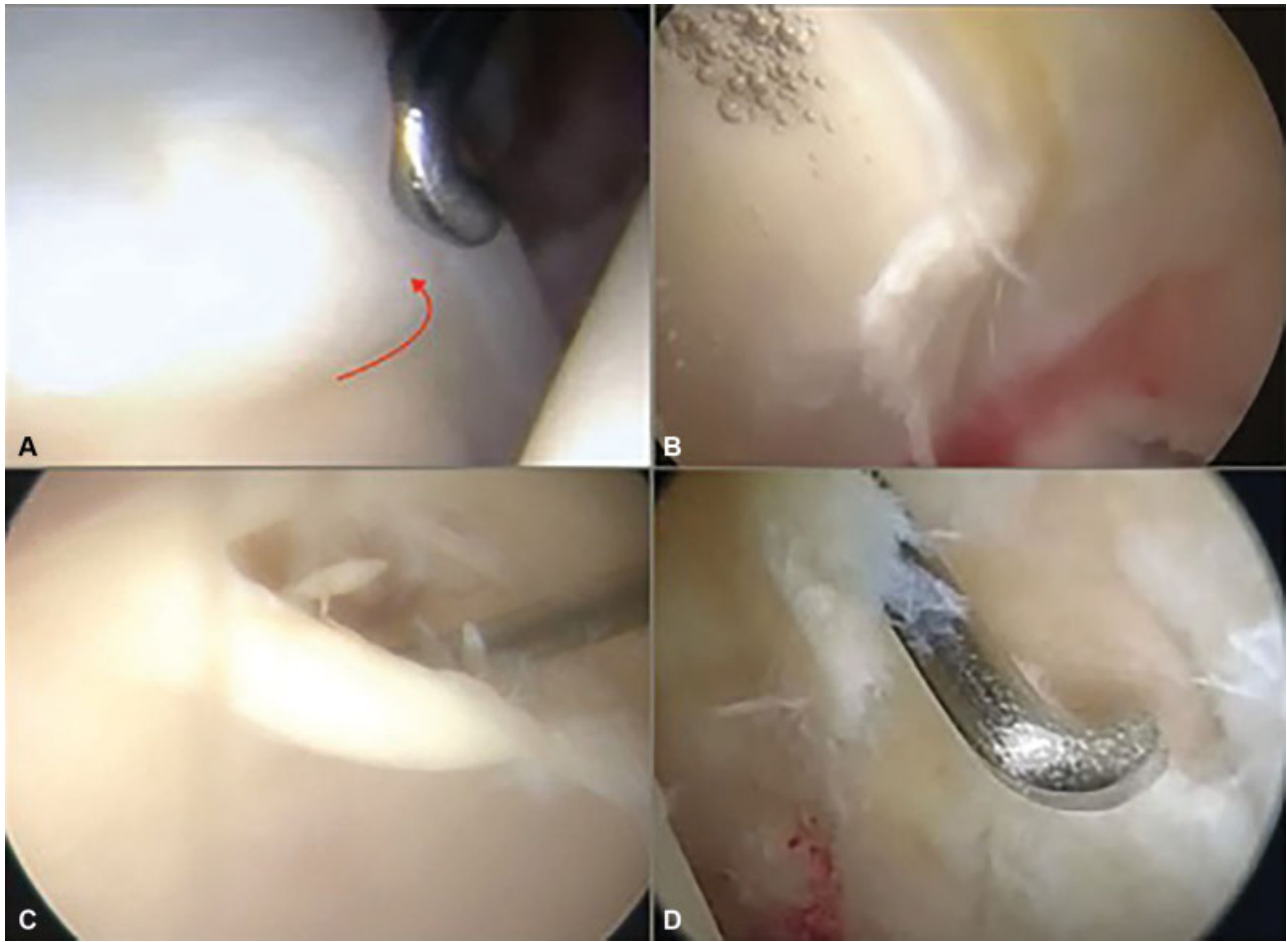


Fig. 1 (A) Grade I - wave sign; (B) Grade II - chondrolabral junction damage with no cartilage delamination; (C) Grade III - subchondral bone cartilage detachment; (D) Grade IV - subchondral bone exposure.

No specific maneuver can assist the diagnosis of isolated chondral lesions of the hip, since the articular cartilage has no nociceptors, and it may take time until it causes mechanical symptoms or joint irritation.¹⁷ The early management of these lesions, associated with FAI correction, is directly related to the outcome of the arthroscopic treatment.¹⁹ Thus, the identification of patients susceptible to deep articular cartilage lesions is decisive for defining the timing of the surgical treatment and to manage the postoperative expectations of the patient, especially regarding the return to sports activities.

The present study aims to evaluate if there is a relationship between the presence of deep chondral lesions in the hip during arthroscopic FAI treatment and to associate them to the preoperative nonarthritic hip score (NAHS) – Brazil²⁰ and to the preoperative alpha angle measurements, to the acetabular coverage angle, to the radiological Tonnis classification, and to the age and gender of the patients.

Material and Methods

The present study was approved by the Ethics Committee of the Universidade de Passo Fundo, state of Rio Grande do Sul, Brazil, under the number 1.749.565, according to Resolution 466/12 of the Brazilian Health Council. The present study

included 110 patients (125 hips) consecutively submitted to hip arthroscopy between May 2016 and May 2017 by a single surgeon, and who were prospectively evaluated for the presence of chondral lesions. Patients submitted to arthroscopy for the treatment of conditions other than FAI, those with a history of previous hip or spine surgeries, those presenting arthrosis classified as grade II of Tonnis at panoramic pelvic radiographs at the time of the surgery, and those with no functional scores collected on the day of the surgery were excluded from the initial sample. Thus, the final sample consisted of 92 patients (107 hips) submitted to treatment for mixed impingement (78%) or isolated CAM impingement (22%) and presenting pelvic radiographs classified as grades 0 and 1 of Tonnis. The patients were submitted to a questionnaire for functional evaluation on the day of the surgery; in addition, their radiological measurements were taken, and their arthrosis was classified according to the Tonnis criteria. An anteroposterior (AP) hip radiography with controlled rotation (pubic symphysis aligned to the coccyx) and tilt (distance from the pubic symphysis to the sacrococcygeal junction) was used to determine both the Wiberg acetabular coverage angle and the Tonnis classification of hip arthrosis. The alpha angle was measured in 45° Dunn views. The data was tabulated with Microsoft Excel (Microsoft Corporation, Redmond, WA, USA)

and the statistical analysis was performed with IBM SPSS Statistics for Windows, Version 22.0 (IBM Corp., Armonk, NY, USA). For the analysis, the sample units were the hips classified according to the severity of the chondrolabral lesion in two groups according to the depth of the chondral lesion, but regardless of its location and extent, following the arthroscopic classification of Haddad¹⁸; as such, one group was comprised by hips with no chondral or superficial, grades I to II lesions, while the other group was comprised by hips with deep, grades III and IV of Haddad¹⁸ lesions. The associations between lesion grade and symptom score, lateral coverage angle, alpha angle, and age were tested per a variance analysis with a classification criterion. The associations between lesion grade and gender or Tonnis classification were evaluated using the chi-squared test. Tests with a probability value < 0.05 were considered statistically significant.

Results

The final sample consisted of 107 joints from 92 patients; 67 hips (62.6%) were from male patients, and 59 hips (55.1%) were left hips; in addition, the average age of the patients was 33.56 ± 7.4 years old. Regarding the severity of the lesion, 11 hips presented grade IV lesions, and 14 hips had grade III lesions, totaling 25 patients (23.4%) in the deep lesion group. In the group of patients with mild lesions, 13 (12.1%) individuals were grade 0 (no chondral lesion), 24 (22.4%) had grade I chondral lesions, and 45 (42.1%) presented grade II lesions, totaling 82 hips (76.6%). Regarding the presence of radiographic changes according to the Tonnis criteria, 80 hips (74.8%) were classified as grade 0, while 27 (25.2%) hips were classified as grade I.

Male patients undergoing arthroscopic treatment for FAI had higher NAHS functional scores and a greater proportion of deep chondral lesions compared with female patients; 65.6 ± 19.6 versus 49.3 ± 21.6 , $p < 0.001$, and 23 (34.3%) versus 2 (5.0%); $p = 0.001$, respectively.

It was observed that patients with deeper lesions had significantly higher NAHS scores than those with more superficial lesions (67.9 ± 19.4 versus 57.0 ± 21.9 ; $p = 0.027$). There was no statistically significant difference between groups with superficial and deep lesions regarding the Wiberg lateral coverage angle and the alpha angle (35.1 ± 8.4 versus 33.1 ± 6.6 ; $p = 0.271$; and 66.3 ± 8.5 versus 69.0 ± 7.0 ; $p = 0.155$, respectively). Likewise, there was no statistically significant difference in the age of patients with superficial or deep chondral lesions (33.0 ± 7.6 versus 35.0 ± 7.4 ; $p = 0.253$). On the other hand, the proportion of Tonnis 1 classification was significantly higher among deeper chondral lesions (15, 60.0%), compared with more superficial lesions (12 [14.6%]; $p < 0.001$). The prevalence of deep chondral lesions was higher among hips classified as Tonnis 1 compared with Tonnis 0 hips (15 [55.6%] versus 10 [12.7%], prevalence ratio 4.4; $p < 0.001$) (► **Table 2**).

Discussion

The presence of chondral lesions in patients undergoing hip arthroscopy for FAI treatment is a frequent finding, docu-

Table 2 Lesion grade and analyzed variables

	Absent or mild lesion (n = 82)	Deep lesion (n = 25)	p-value
Gender (male)	44 (65.7%)	23 (34.3%)	0.001
Age (years old)	33.0 ± 7.6	35.0 ± 7.4	0.253
NAHS	57.0 ± 21.9	67.9 ± 19.4	0.027
Alpha angle	66.3 ± 8.5	69.0 ± 7.0	0.158
CE angle	35.1 ± 8.4	33.1 ± 6.6	0.288
Tonnis I	10 (12.7%)	15 (55.6%)	< 0.001

Abbreviations: CE, Center Edge Angle; NAHS, nonarthritic hip score. Values express mean \pm standard deviation or absolute and relative frequency.

mented in between 45 and 75% of such surgeries.^{9,21,22} In our series, chondral lesions were found in 87.9% of the sample. Bhatia et al¹⁹ observed a 28% prevalence of Outerbridge grade IV lesions in patients submitted to hip arthroscopy; 78% of these lesions were isolated acetabular injuries, and independent risk factors for their presence were joint space reduction and long duration of symptoms. In our study, deep chondral lesions (grades III and IV of Haddad¹⁸) were found in 23.4% of the patients; however, these lesions did not indicate the presence of a degenerative process (arthrosis), since chondral lesions classified as deep resulted from chondrolabral junction rupture followed by the detachment of the acetabular cartilage from the subchondral bone. Therefore, these lesions are delimited and not related to a diffuse joint degenerative process. These chondral lesions are candidates for arthroscopic treatment.²³

The lesions grouped as deep in the present study can be classified as Outerbridge grade IV due to subchondral bone exposure, as grade III due to macroscopic detachment of cartilage from the subchondral bone, and as grade IV due to exposure of the acetabular bone. In the present study, we did not find a statistically significant relationship between alpha angle measurements and the presence of these lesions. This finding is discordant from those of Bhatia et al,¹⁹ who demonstrated that large alpha angles are related to Outerbridge grade IV chondral lesions.

Cläßen et al,²⁴ in a study with 177 patients submitted to hip arthroscopy for isolated CAM-type impingement treatment, concluded that the NAHS analysis is also a predictive factor of chondral lesions; however, this method was considered unreliable, with low sensitivity and specificity (respectively, of 62.8 and 68.7%) when a cutoff value of 42.5 points was used and the presence of chondral lesions was defined by the Outerbridge classification. When the cutoff value is set to 30 NAHS points, the specificity is 100%, but the sensitivity is 1%. Our analysis, which evaluated patients submitted to hip arthroscopy for the treatment of mixed and CAM-type impingement, demonstrated an inverse relationship of lesion severity with nonarthritic functional score, since patients with deep chondral lesions had better preoperative functional scores. Surprisingly, this

result suggests that patients with better functional scores have worse joint injuries. Few studies evaluate the conservative FAI treatment. Wall et al,²⁵ in a systematic literature review, concluded that physical therapy and lifestyle modification may provide some benefit to the patient. Emarat et al,²⁶ in a prospective analysis of a case series with 37 patients, showed improvement of the mean NAHS values from 72 to 91 points after conservative treatment including restriction of joint overload, use of anti-inflammatory agents, physical therapy, and modification of activities predisposing to FAI; with an average follow-up period of 25 to 28 months; this treatment resulted in 4 failures that required surgery. Since there is a relation between the duration of symptoms and the incidence of chondral lesions,^{19,25} we suspect that patients with chronic pain can modify their lifestyle and reduce hip overload activities to obtain a partial improvement in their functional score.

In the sample studied, there was no significant difference ($p = 0.253$) between age and deep lesions, although the mean age was slightly higher in patients with deep chondral lesions. Men presented better functional scores and also a higher prevalence of deep lesions, a finding compatible with previous studies.^{1,4,13}

The main limitation of the present study was not to consider the time the patient was exposed to the chondral lesion and the impossibility to estimate the impact that the injury time has on the outcome (number of symptoms measured by the score). In addition, the sample is composed mainly by patients with mixed FAI, and there are indications in the literature that pincer impingement is a protective factor for chondral delamination.¹⁴

Conclusion

In our sample, patients with deep hip chondral lesions presented significantly better NAHS scores compared with patients with no chondral lesions or mild lesions. Hips classified as Tönnis 1 were 4.4 times more likely to have deep chondral lesions compared with those classified as Tönnis 0. Men undergoing FAI treatment had better preoperative functional scores than women, and a higher prevalence of Haddad¹⁸ grade III and IV lesions. There was no statistically significant association between the presence of deep chondral lesions and alpha angle, lateral coverage angle, and age.

Conflicts of Interests

The have no conflicts of interests to declare.

References

- 1 Beck M, Kalhor M, Leunig M, Ganz R. Hip morphology influences the pattern of damage to the acetabular cartilage: femoroacetabular impingement as a cause of early osteoarthritis of the hip. *J Bone Joint Surg Br* 2005;87(07):1012–1018
- 2 Zamber RW, Teitz CC, McGuire DA, Frost JD, Hermanson BK. Articular cartilage lesions of the knee. *Arthroscopy* 1989;5(04):258–268
- 3 Schairer WW, Nwachukwu BU, McCormick F, Lyman S, Mayman D. Use of hip arthroscopy and risk of conversion to total hip arthroplasty: a population-based analysis. *Arthroscopy* 2016;32(04):587–593
- 4 Philippon MJ, Briggs KK, Yen YM, Kuppersmith DA. Outcomes following hip arthroscopy for femoroacetabular impingement with associated chondrolabral dysfunction: minimum two-year follow-up. *J Bone Joint Surg Br* 2009;91(01):16–23
- 5 Egerton T, Hinman RS, Takla A, Bennell KL, O'Donnell J. Intraoperative cartilage degeneration predicts outcome 12 months after hip arthroscopy. *Clin Orthop Relat Res* 2013;471(02):593–599
- 6 Haviv B, O'Donnell J. Arthroscopic treatment for acetabular labral tears of the hip without bony dysmorphism. *Am J Sports Med* 2011;39(39, Suppl):79S–84S
- 7 Sankar WN, Matheney TH, Zaltz I. Femoroacetabular impingement: current concepts and controversies. *Orthop Clin North Am* 2013;44(04):575–589
- 8 Peters CL, Erickson J. The etiology and treatment of hip pain in the young adult. *J Bone Joint Surg Am* 2006;88(Suppl 4):20–26
- 9 Beck M, Leunig M, Parvizi J, Boutier V, Wyss D, Ganz R. Anterior femoroacetabular impingement: part II. Midterm results of surgical treatment. *Clin Orthop Relat Res* 2004;(418):67–73
- 10 Beaulé PE, Zaragoza E, Copelan N. Magnetic resonance imaging with gadolinium arthrography to assess acetabular cartilage delamination. A report of four cases. *J Bone Joint Surg Am* 2004;86(10):2294–2298
- 11 Beaulé PE, Zaragoza EJ. Surgical images: musculoskeletal acetabular cartilage delamination demonstrated by magnetic resonance arthrography: inverted "Oreo" cookie sign. *Can J Surg* 2003;46(06):463–464
- 12 Ho CP, Ommen ND, Bhatia S, et al. Predictive value of 3-T magnetic resonance imaging in diagnosing grade III and IV chondral lesions in the hip. *Arthroscopy* 2016;32(09):1808–1813
- 13 Chandrasekaran S, Darwish N, Gui C, Lodhia P, Suarez-Ahedo C, Domb BG. Outcomes of Hip Arthroscopy in Patients with Tönnis Grade-2 Osteoarthritis at a Mean 2-Year Follow-up: Evaluation Using a Matched-Pair Analysis with Tönnis Grade-0 and Grade-1 Cohorts. *J Bone Joint Surg Am* 2016;98(12):973–982
- 14 Anderson LA, Peters CL, Park BB, Stoddard GJ, Erickson JA, Crim JR. Acetabular cartilage delamination in femoroacetabular impingement. Risk factors and magnetic resonance imaging diagnosis. *J Bone Joint Surg Am* 2009;91(02):305–313
- 15 Outerbridge RE. The etiology of chondromalacia patellae. *J Bone Joint Surg Br* 1961;43-B:752–757
- 16 MacDonald AE, Bedi A, Horner NS, et al. Indications and outcomes for microfracture as an adjunct to hip arthroscopy for treatment of chondral defects in patients with femoroacetabular impingement: a systematic review. *Arthroscopy* 2016;32(01):190–200.e2
- 17 Amenabar T, Piriz J, Mella C, Hetaimish BM, O'Donnell J. Reliability of 3 different arthroscopic classifications for chondral damage of the acetabulum. *Arthroscopy* 2015;31(08):1492–1496
- 18 Konan S, Rayan F, Meermans G, Witt J, Haddad FS. Validation of the classification system for acetabular chondral lesions identified at arthroscopy in patients with femoroacetabular impingement. *J Bone Joint Surg Br* 2011;93(03):332–336
- 19 Bhatia S, Nowak DD, Briggs KK, Patterson DC, Philippon MJ. Outerbridge grade IV cartilage lesions in the hip identified at arthroscopy. *Arthroscopy* 2016;32(05):814–819
- 20 Del Castillo LN, Leporace G, Cardinot TM, Levy RAL, Oliveira LP. Translation, cross-cultural adaptation and validation of the Brazilian version of the Nonarthritic Hip Score. *Sao Paulo Med J* 2013;131(04):244–251
- 21 Beaulé PE, Le Duff MJ, Zaragoza E. Quality of life following femoral head-neck osteochondroplasty for femoroacetabular impingement. *J Bone Joint Surg Am* 2007;89(04):773–779

- 22 Nepple JJ, Carlisle JC, Nunley RM, Clohisy JC. Clinical and radiographic predictors of intra-articular hip disease in arthroscopy. *Am J Sports Med* 2011;39(02):296-303
- 23 Mella C, Villalón IE, Núñez Á, Paccot D, Díaz-Ledezma C. Hip arthroscopy and osteoarthritis: Where are the limits and indications? *SICOT J* 2015;1:27
- 24 Claßen T, Körsmeier K, Kamminga M, et al. Is early treatment of cam-type femoroacetabular impingement the key to avoiding associated full thickness isolated chondral defects? *Knee Surg Sports Traumatol Arthrosc* 2016;24(07):2332-2337
- 25 Wall PD, Fernandez M, Griffin DR, Foster NE. Nonoperative treatment for femoroacetabular impingement: a systematic review of the literature. *PM R* 2013;5(05):418-426
- 26 Emara K, Samir W, Motasem H, Ghafar KA. Conservative treatment for mild femoroacetabular impingement. *J Orthop Surg (Hong Kong)* 2011;19(01):41-45