



Cervical Osteoblastoma: A Case Report*

Osteoblastoma cervical: relato de caso

Carolina Oliveira¹ Luísa Vital² Francisco Serdoura² André Rodrigues Pinho² Vitorino Veludo²

¹ Departamento de Cirurgia Ortopédica, Unidade Local de Saúde do Alto Minho, Viana do Castelo, Portugal

² Departamento de Cirurgia Ortopédica, Hospital de São João, Faculdade de Medicina, Universidade do Porto, Porto, Portugal

Address for correspondence Carolina Oliveira, Departamento de Cirurgia Ortopédica, Unidade Local de Saúde do Alto Minho, Viana do Castelo, Portugal (e-mail: carolinafernandesoliveira@gmail.com).

Rev Bras Ortop 2019;54:219–222.

Abstract

Osteoblastoma is a rare benign primary bone tumor. It accounts for 3% of benign and 1% of all primary bone tumors. The treatment goal is complete surgical resection. This treatment limits the risk of recurrence. As osteoblastoma is a highly vascular tumor, complete resection is often difficult. This report describes the case of a 19-year-old male patient who presented severe right-sided neck and shoulder pain. The computed tomography scan revealed a mass lesion on C7 compatible with osteoblastoma. Preoperative embolization and tumor resection were performed. At the 3-year follow-up, the patient had no restrictions on daily activities, and, to date, there has been no evidence of recurrence.

Keywords

- ▶ osteoblastoma
- ▶ neck pain
- ▶ embolization
- ▶ spinal cord neoplasms

Resumo

Osteoblastoma é um tumor primário benigno raro. Constitui cerca de 3% dos tumores benignos e 1% de todos os tumores ósseos. O objetivo do tratamento é a ressecção completa, que limita o risco de recidiva. Por se tratar de um tumor vascularizado, a ressecção completa é, muitas vezes, difícil. Os autores descrevem um caso clínico de um paciente do sexo masculino de 19 anos que apresentava queixas de cervicalgia direita com irradiação para o ombro. O exame por tomografia computadorizada indicou uma lesão em C7 compatível com osteoblastoma. O paciente foi submetido a ressecção cirúrgica após embolização pré-operatória e artrodese anterior. Aos 3 anos de seguimento, o paciente encontra-se assintomático e, até a data, sem evidência de recidiva.

Palavras-chave

- ▶ osteoblastoma
- ▶ cervicalgia
- ▶ embolização
- ▶ neoplasias da medula espinhal

Introduction

Osteoblastoma is a rare and benign primary bone tumor that account for 3% of benign and 1% of all primary bone tumors.^{1,2} Approximately 32–46% involve the spine.^{2,3} These lesions occur predominately in second and third decade of life and in male with a 2:1 male to female ratio.^{3,4} Pain is the most commonly cited symptom and often present for greater than a year prior to diagnosis.^{1–4} Late diagnosis of these lesions

relates to its low incidence, non-specific symptoms and normal radiological study during the initial course of disease.^{3,4} The treatment goal is complete surgical resection which allows the complete regression of complaints and decrease the likelihood of relapse.^{2,5}

Case Report

A 19-year-old boy was referred to Orthopedic Consult for neck pain. The past medical history was unremarkable. He presented with a year history of severe right-sided neck and shoulder pain, worst in the night. The pain was progressive, not relieved with medical treatment and exacerbated in the

* Study conducted at Departamento de Cirurgia Ortopédica, Hospital de São João, Faculdade de Medicina, Universidade do Porto, Porto, Portugal. Published originally by Elsevier Ltda.

received
September 16, 2017
accepted
November 21, 2017

DOI <https://doi.org/10.1016/j.rboe.2017.11.017>
ISSN 0102-3616.

Copyright © 2019 by Sociedade Brasileira de Ortopedia e Traumatologia. Published by Thieme Revnter Publicações Ltda, Rio de Janeiro, Brazil

License terms



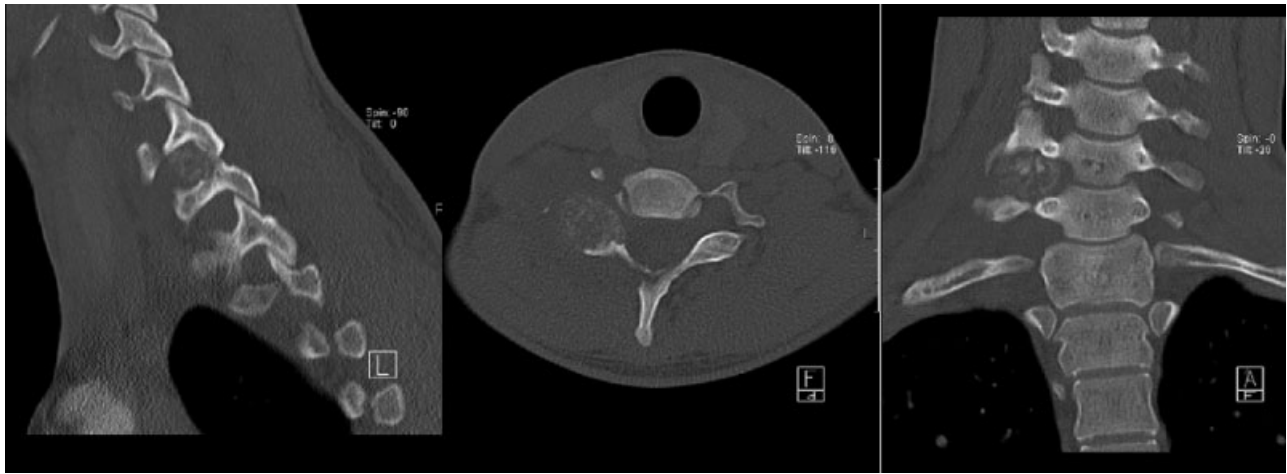


Fig. 1 Cervical CT scan: mass lesion with well-defined limits involving facet joint and the right pedicle of C7.

last two months with paresthesias. On examination, cervical range of motion was restricted and painful. Neurological examination was unremarkable. Cervical spine X-ray was normal. A cervical CT scan revealed a mass lesion with well-defined limits involving facet joint and the right pedicle of C7, with about 18.9×15.2 mm larger diameter without spinal cord compression, compatible with osteoblastoma (**Fig. 1**). We completed study with angio-CT and neck vessels Doppler revealing stenosis of vertebral artery with cleavage plan with the same (**Fig. 2**). It was decided surgical resection.

The patient underwent preoperative embolization one day prior to surgery (**Fig. 3**). On the following day, the patient underwent tumor resection by posterior approach followed by C6-C7 intersomatic arthrodesis with “cage” filled with iliac crest autograft for anterior approach (**Fig. 4**).

The postoperative period was uneventful. A CT scan was obtained on a first postoperative day and demonstrated a

complete surgical resection (**Fig. 5**). He was discharged on the fifth day postoperatively. Histopathologic examination confirmed the diagnosis. Present at 3 years postoperatively, the patient presents no complaints and with normal daily life activity without evidence of recurrence (**Fig. 6**).

Discussion

Osteoblastoma and osteoid osteoma were described in 1935 by Jaffe apud Samdani et al.³ They are both hypervascular tumors benign clinically and histologically similar.^{3,6} However, osteoblastoma demonstrates more aggressive characteristics. It can be locally aggressive and cause neurologic impairment due the expansible growth. Furthermore, it can undergo malignant transformation to osteosarcoma.^{2,3,6}

In spine osteoblastoma usually involves the posterior elements.^{2,4,6} Although it is considered a benign tumor, spinal lesions recurrence is not uncommon and have been reported in 9.7–15% of series of spinal osteoblastomas.⁶

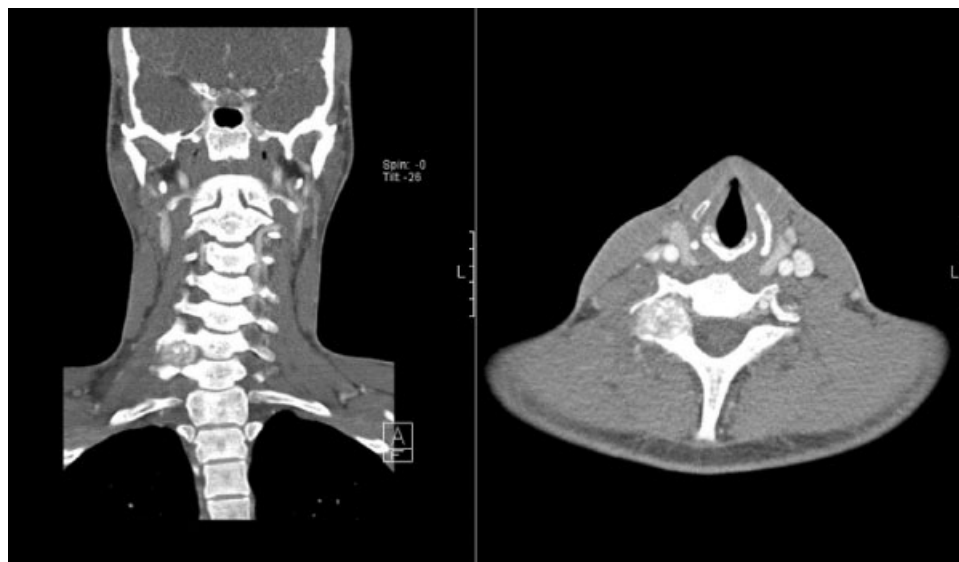


Fig. 2 Angio-CT.

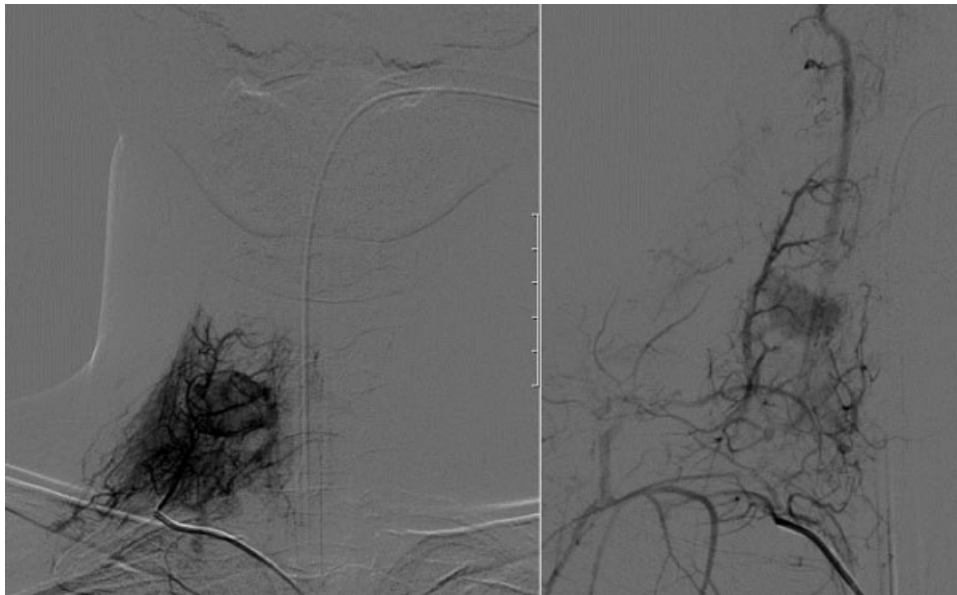


Fig. 3 Preoperative embolization images.

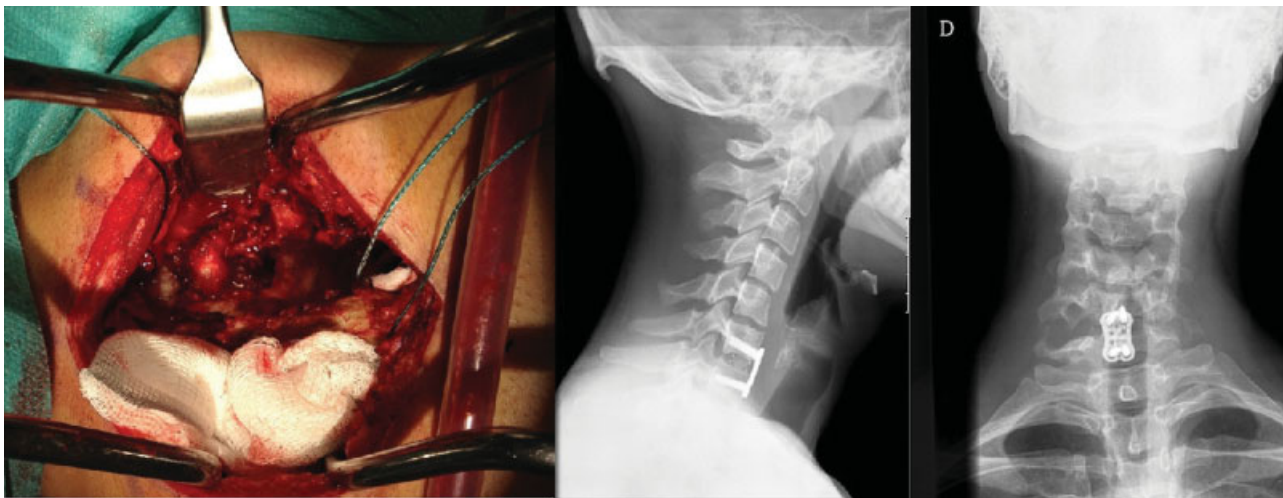


Fig. 4 Left: intraoperative picture of tumor resection; right: postoperative X-ray (lateral view and AP).

The most common presentation is neck pain^{1,4,6} and it is not relieved by nonsteroidal anti-inflammatory drugs.⁵ Other common signs and symptoms include toricollis, stiffness and local tenderness.⁴

The diagnosis is usually made by CT scan.⁵ It will delineate the location and osseous involvement of the mass.³

Surgical excision is the treatment of choice for osteoblastoma.^{1,2,5,7} This treatment limits the risk of recurrence.⁵ The main reason for high rate of recurrence is incomplete resections.^{6,7} Careful pre-operative planning is essential.⁷

Because osteoblastoma is a high vascular tumor, complete resections is often impeded by extensive intraoperative bleeding.² Some authors recommend pre-operative embolization. It has been described since 1979 by Dick et al. and apud Samdani et al.³ as an adjunctive therapy for benign bone tumors. More recently, it has been successfully applied to highly vascular spinal tumors.³ It reduces intraoperative bleeding, and help to enhance visualization to

perform a complete resection. It also reduces post-operative complications.^{2,3}

The authors report a well-succeeded case of C7 osteoblastoma. In the current case, the authors preferred a two stage approach. The posterior approach allowed tumor resection. The anterior approach allowed anterior fusion for spine stabilization, with interbody cage and instrumentation with anterior plate and screws. We chose anterior arthrodesis to facilitate imaging follow-up, since it diminishes the imaging artifact in the posterior elements and that could hinder the interpretation of a possible local recurrence.

We perform a pre-operative embolization that facilitated tumor resection because it decrease bleeding and improve visualization. The complete resection of this lesion allowed the complete regression of complaints and decreases the likelihood of recurrence (without it, the recurrence rate has been reported between 9.8% and 15%).⁶

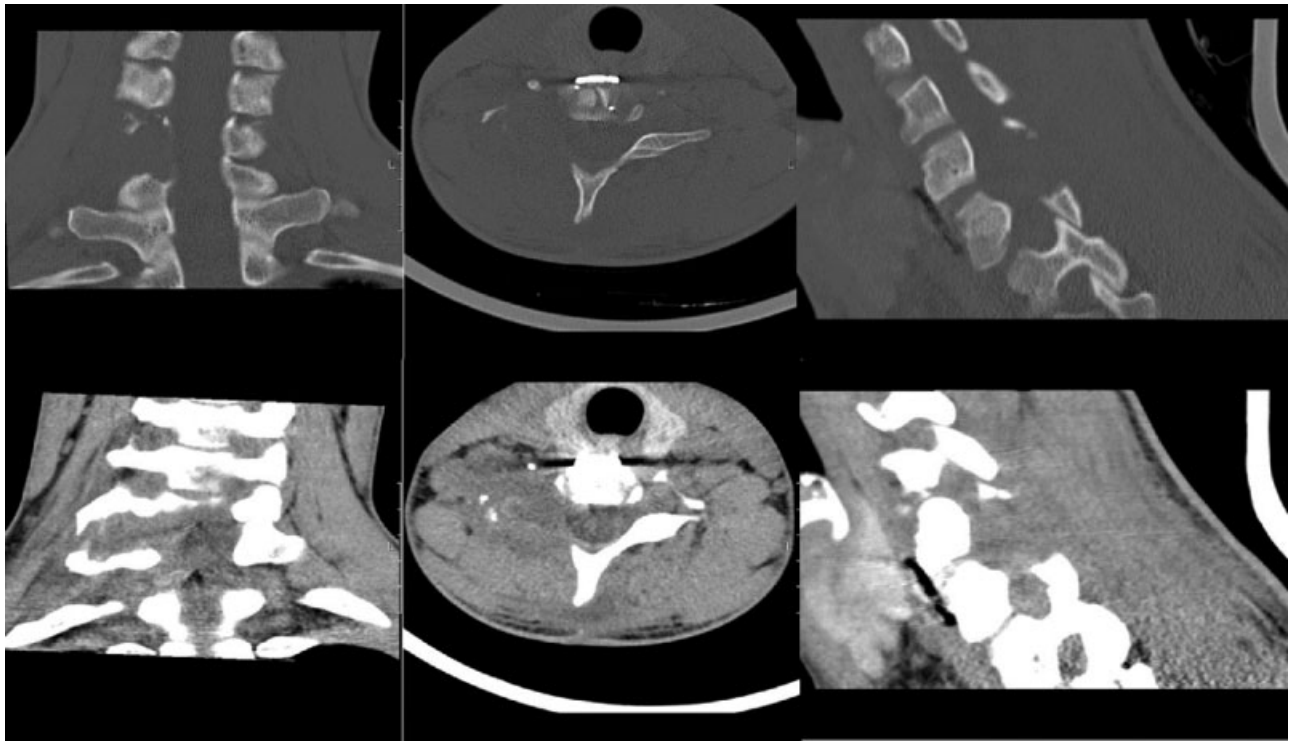


Fig. 5 Post-operative cervical CT scan: complete surgical resection.

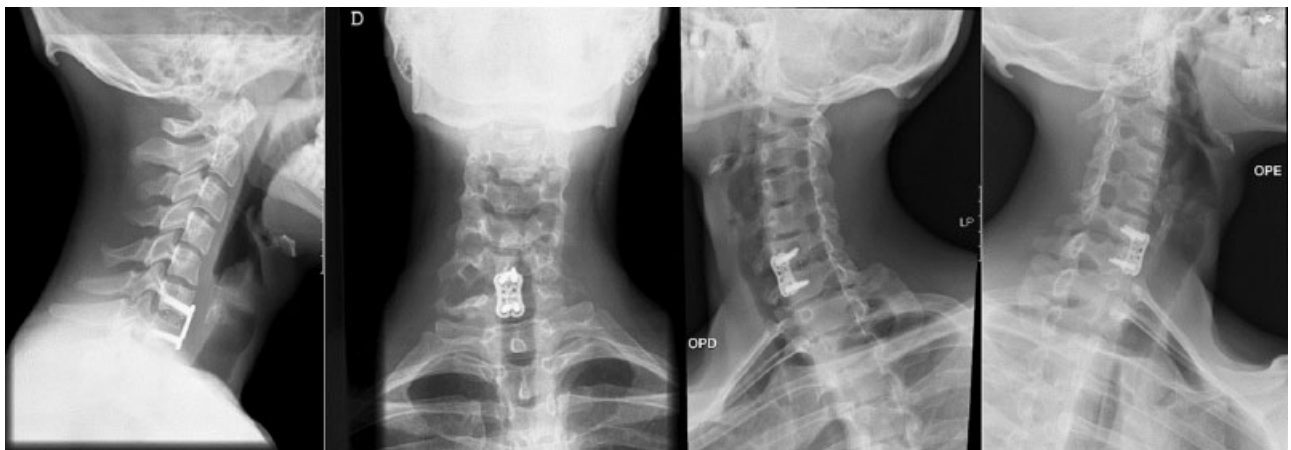


Fig. 6 3 years follow-up cervical spine radiographs: lateral view, AP and oblique view.

Conflicts of Interest

The authors declare no conflicts of interest.

References

- 1 Yin H, Zhou W, Yu H, Zhang D, Wu Z, Liu T, et al. Clinical characteristics and treatment options for two types of osteoblastoma in the mobile spine: a retrospective study of 32 cases and outcomes. *Eur Spine J* 2014;23(02):411–416
- 2 Trübenbach J, Nägele T, Bauer T, Ernemann U. Preoperative embolization of cervical spine osteoblastomas: report of three cases. *AJNR Am J Neuroradiol* 2006;27(09):1910–1912
- 3 Samdani A, Torre-Healy A, Chou D, Cahill AM, Storm PB. Treatment of osteoblastoma at C7: a multidisciplinary approach. A case report and review of the literature. *Eur Spine J* 2009;18 (Suppl 2):196–200
- 4 Stern P, Dzus A, Cassidy J. Cervical spine osteoblastoma presenting as mechanical neck pain: a case report. *J Can Chiropr Assoc* 1994; 38(03):146–151
- 5 Hadgaonkar SR, Shyam AK, Shah KC, Khurjekar KS, Sancheti PK. Extraosseous thoracic foraminal osteoblastoma: diagnostic dilemma and management with 3 year follow-up. *Asian Spine J* 2014;8(05):689–694
- 6 Yilmaz C, Civelek E, Caner H, Aydin E, Gerilmez A, Altinors N. Osteoblastoma of C2 corpus: 4 years follow-up. *Asian Spine J* 2012;6(02):136–139
- 7 Weatherley CR, Jaffray D, O'Brien JP. Radical excision of an osteoblastoma of the cervical spine. A combined anterior and posterior approach. *J Bone Joint Surg Br* 1986;68(02):325–328