

## “Filling the bladder” at Cesarean Hysterectomy for Placenta Percreta

OPEN  
ACCESS

### Dear Editor,

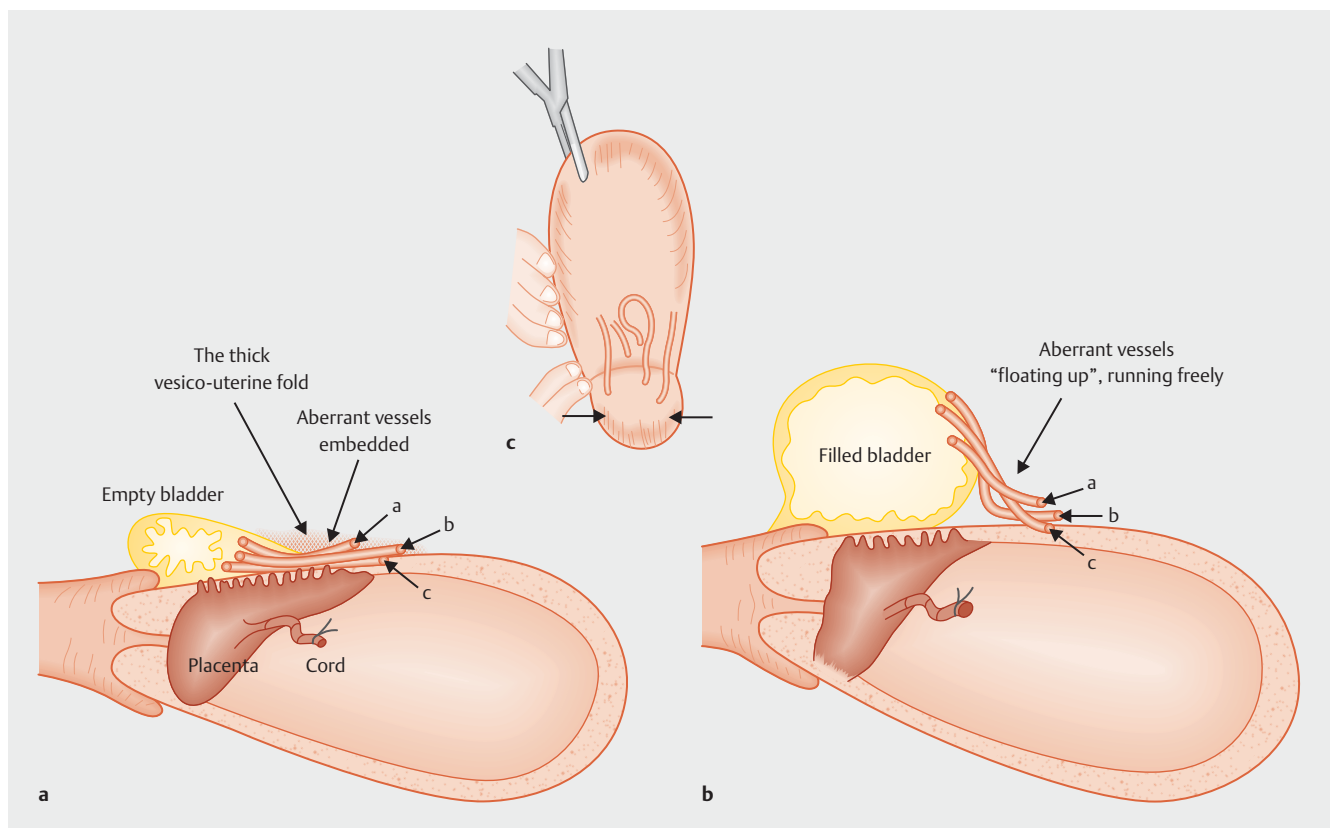
Cesarean hysterectomy for placenta percreta is challenging. I commend Özcan et al. for describing “filling the bladder” for this surgery: this led to a shorter operative time/hospital stay, although it did not decrease the incidence of bladder injuries [1]. I wish to share my opinion with readers: the first merit of “filling the bladder” is reducing bleeding, making this surgery easier, and the possibility of avoiding bladder injury may be the second merit.

We have long been taught that the bladder should be emptied at the time of hysterectomy for a non-pregnant uterus: a full bladder may complicate handling of the uterus

and even cause bladder injury. Filling the bladder with sterilized milk was performed for cesarean hysterectomy [2], which, however, was mainly to identify bladder injury if it occurred. Hysterectomy for percreta may have some specific features different from these surgeries. As Özcan et al. pointed out [1], the vesico-uterine fold (the cephalad end of the bladder) becomes thick in percreta (due to repeated previous cesarean or possibly percreta per se), which makes identifying the bladder separation site difficult (► Fig. 1 a). “Filling the bladder” facilitates its recognition (► Fig. 1 b).

Based on my 4-decade-long experience, I have been using “filling the bladder” in percreta hysterectomy, as was previously

described [3–5]. Engorged aberrant vessels usually exist in the bladder separation site in percreta, which usually run between the bladder surface and lower uterine segment, or they are sometimes “embedded” in this site (► Fig. 1 a; marked as vessels a, b, and c). Without filling the bladder, their cutting and ligation are very difficult. “Filling the bladder” makes it easy. Please look at Özcan et al.’s Figure 2, which effectively illustrates the point. Using “filling the bladder”, these engorged vessels “float up”, running freely like an “electric wire-cable in the air” between the filled bladder and uterus: these vessels are no longer “embedded” in the site. Their cutting and ligation become easy (comparison between ► Fig. 1 a vs. b).



► **Fig. 1** Schema of “filling the bladder” in cesarean hysterectomy for placenta percreta. **a** Without “filling the bladder”. The vesico-uterine fold is thick, and, thus, the bladder cephalad end (bladder separation site) is obscure. Engorged aberrant vessels (marked as a, b, and c) exist between the bladder surface and uterus, which adhere to this site or are even “embedded”, which makes their cutting and ligation difficult. **b** With “filling the bladder”. The bladder separation site becomes evident. Engorged aberrant vessels (a, b, and c) “float up”, running freely like an “electric wire-cable”, which enables easier cutting and ligation. **c** Schema of Özcan et al.’s Figure 2. Arrows indicate the aberrant vessels running freely between the bladder surface and lower uterine segment.

If bladder invasion is severe, we intentionally cut the bladder wall using an automatic stapling/cutting apparatus, an ENDO-GIA stapler (Tyco International Co. Ltd., New York, USA), which makes bladder repair easy [3,6,7]. Bladder injuries are sometimes inevitable depending on the degree of bladder invasion, and even if bladder injuries occur, they can be repaired. Contrarily, bleeding from engorged aberrant vessels is usually severe to the extent that it prevents the completion of surgery, even causing maternal death. No bladder injury and no vessel rupture are ideal, but the latter outweighs the former.

In Özcan et al.'s study, although the amount of blood transfusion did not differ between the two groups, I believe that total blood loss, or at least that during bladder separation, might have been smaller in the filled bladder group. Even if this was not so, the shorter operative time in the filled bladder group may be ascribed to/as-associated with "easy cutting and ligation" of the aberrant vessels. I wish to more fully understand the situation.

"Filling the bladder" makes percreta hysterectomy easier. This is mainly because of easier handling of the aberrant vessels rather than avoiding bladder injury: actually, the incidence of bladder injuries

did not differ between filling the bladder (+) vs. (-) [1]. Putting this aside, it is my hope that filling the bladder becomes more widely used in this surgery. Filling the bladder has been time-tested by our team.

### Conflict of Interest

The authors declare that they have no conflict of interest.

### Authors

**Shigeki Matsubara, MD, PhD, Director and Professor**

Department of Obstetrics and Gynecology,  
Jichi Medical University, Tochigi, Japan

### Correspondence

**Shigeki Matsubara, MD, PhD**

Department of Obstetrics and Gynecology  
Jichi Medical University  
3311-1 Yakushiji, Shimotsuke  
Tochigi 329-0498  
Japan  
matsushi@jichi.ac.jp

### References

- [1] Özcan HÇ, Balat Ö, Uğur MG et al. Use of Bladder Filling to Prevent Urinary System Complications in the Management of Placenta Percreta: a Randomized Prospective Study. *Geburtsh Frauenheilk* 2018; 78: 173–178

- [2] Shellhaas CS, Gilbert S, Landon MB, et al. The frequency and complication rates of hysterectomy accompanying cesarean delivery. *Obstet Gynecol* 2009; 114: 224–229
- [3] Matsubara S, Kuwata T, Usui R et al. Important surgical measures and techniques at cesarean hysterectomy for placenta previa accreta. *Acta Obstet Gynecol Scand* 2013; 92: 372–377
- [4] Matsubara S, Takahashi H, Baba Y. Handling aberrant vessels located in the posterior bladder wall in surgery for abnormally invasive placenta: a non/less-touch technique. *Arch Gynecol Obstet* 2017; 296: 851–853
- [5] Matsubara S. Cesarean hysterectomy for placenta praevia accreta: filling the bladder technique to identify an appropriate bladder separation site. *J Obstet Gynaecol* 2013; 33: 163–164
- [6] Matsubara S, Ohkuchi A, Yashi M et al. Opening the bladder for cesarean hysterectomy for placenta previa percreta with bladder invasion. *J Obstet Gynaecol Res* 2009; 35: 359–363
- [7] Matsubara S. Bladder-opening technique for hysterectomy for placenta previa percreta. *Arch Gynecol Obstet* 2011; 283: 1427–1428

### Bibliography

DOI <https://doi.org/10.1055/a-0592-5032>  
*Geburtsh Frauenheilk* 2018; 78: 715–716 © Georg Thieme Verlag KG Stuttgart · New York | ISSN 0016-5751

