

Oblique Sagittal Images Prevent Underestimation of the Neuroforaminal Stenosis Grade Caused by Disc Herniation in Cervical Spine MRI

Schräg sagittale Aufnahmen verhindern die Unterschätzung des neuroforaminalen Stenosegrades bei Bandscheibenherniationen in der MRT der Halswirbelsäule

Authors

Laurent Kintzelé¹, Christoph Rehnitz¹, Hans-Ulrich Kauczor¹, Marc-André Weber²

Affiliations

- 1 Diagnostic and Interventional Radiology, University Hospital Heidelberg, Germany
- 2 Institute of Diagnostic and Interventional Radiology, University Medical Center Rostock, Rostock, Germany

Key words

oblique sagittal images, neuroforaminal stenosis, disc herniation, cervical spine, MR imaging

received 19.02.2018

accepted 29.03.2018

Bibliography

DOI <https://doi.org/10.1055/a-0612-8205>

Published online: June 6, 2018

Fortschr Röntgenstr 2018; 190: 946–954

© Georg Thieme Verlag KG, Stuttgart · New York

ISSN 1438-9029

Correspondence

Dr. Laurent Kintzelé

Diagnostic and Interventional Radiology, Universitäts

Klinikum Heidelberg, Im Neuenheimer Feld 110,

69120 Heidelberg, Germany

Tel.: ++ 49/62 21/5 63 44 28

laurent.kintzele@med.uni-heidelberg.de

ZUSAMMENFASSUNG

Ziel Zu untersuchen ob sagittale MRT-Standardaufnahmen, im Vergleich zu schräg-sagittalen Aufnahmen den neuroforaminalen Stenosegrad unterschätzen bei Patienten mit Bandscheibenherniationen der Halswirbelsäule.

Material und Methoden Es wurden 74 Patienten mit insgesamt 104 lateral gelegenen zervikalen Bandscheibenherniationen ausgewertet. Hier wurde der Grad der neuroforaminalen Stenose in sagittalen Standardaufnahmen und schräg-sagittalen Aufnahmen von jeweils zwei erfahrenen Radiologen bewertet. Die schräg-sagittalen Aufnahmen wurden dabei 30° zur Standardebene gekippt. Die Klassifikation unterteilte 4 Grade, von 0 (keine Stenose) bis 3 (hochgradige Stenose).

Ergebnisse Der durchschnittliche neuroforaminalen Stenosegrad war signifikant niedriger beim Vergleich von standard-sagittalen zu schräg-sagittalen Aufnahmen ($p < 0,001$). In 47,1 % der Fälle detektierte einer der beiden Radiologen eine neuroforaminalen Stenose, die mindestens 1 Grad niedriger war als in der schräg-sagittalen Gruppe. Ein signifikanter Unterschied bestand auch für die Subgruppen der Patienten mit neurologischer Symptomatik ($p = 0,002$) sowie derer bei denen im Anschluss ein operativer Dekompressionseingriff durchgeführt wurde ($p = 0,004$). Sowohl der Kappa-Wert als Zuverlässigkeitsmaß als auch der Übereinstimmungsgrad zwischen beiden Radiologen waren jeweils höher für schräg-sagittale Aufnahmen (0,94 vs. 0,88 und 99 % vs. 93 %).

Schlussfolgerung Sagittale Standardaufnahmen tendieren im Vergleich zu schräg-sagittalen Aufnahmen zu einer Unterschätzung des neuroforaminalen Stenosegrades bei der Befundung von Bandscheibenherniationen in der Halswirbelsäulen-MRT. Zur besseren Evaluation einer potentiellen therapeutischen Konsequenz werden schräg-sagittale Aufnahmen daher als Zusatzmaßnahme bei Patienten mit radikulärer Symptomatik empfohlen.

Kernaussagen

- Der neuroforaminalen Stenosegrad wird beim Vergleich von standard-sagittalen zu schräg-sagittalen Aufnahmen unterschätzt
- Die Zuverlässigkeit der Messungen zwischen Radiologen kann mit schräg sagittalen Aufnahmen gesteigert werden
- Schräg-sagittale Aufnahmen sollten bei Patienten mit radikulärer Symptomatik zum Standardprotokoll hinzugefügt werden

ABSTRACT

Purpose To identify whether standard sagittal MRI images result in underestimation of the neuroforaminal stenosis grade compared to oblique sagittal MRI images in patients with cervical spine disc herniation.

Materials and Methods 74 patients with a total of 104 cervical disc herniations compromising the corresponding nerve root were evaluated. Neuroforaminal stenosis grades were

evaluated in standard and oblique sagittal images by one senior and one resident radiologist experienced in musculoskeletal imaging. Oblique images were angled 30° towards the standard sagittal plane. Neuroforaminal stenosis grades were classified from 0 (no stenosis) to 3 (high grade stenosis).

Results Average neuroforaminal stenosis grades of both readers were significantly lower in standard compared to oblique sagittal images ($p < 0.001$). For 47.1 % of the cases, one or both readers reported a stenosis grade, which was at least 1 grade lower in standard compared to oblique sagittal images. There was also a significant difference when looking at patients who had neurological symptoms ($p = 0.002$) or underwent cervical spine surgery subsequently ($p = 0.004$). Interreader reliability, as measured by kappa value, and accordance rates were better for oblique sagittal images (0.94 vs. 0.88 and 99 % vs. 93 %).

Conclusion Standard sagittal images tend to underestimate neuroforaminal stenosis grades compared to oblique sagittal

images and are less reliable in the evaluation of disc herniations within the cervical spine MRI. In order to assess the potential therapeutic consequence, oblique images should therefore be considered as a valuable adjunct to the standard MRI protocol for patients with a radiculopathy.

Key Points

- Neuroforaminal stenosis grades are underestimated in standard compared to oblique sagittal images
- Interreader reliability is higher for oblique sagittal images
- Oblique sagittal images should be performed in patients with a cervical radiculopathy

Citation Format

- Kintzele L, Rehnitz C, Kauczor H et al. Oblique Sagittal Images Prevent Underestimation of the Neuroforaminal Stenosis Grade Caused by Disc Herniation in Cervical Spine MRI. *Fortschr Röntgenstr* 2018; 190: 946–954

Introduction

Neck pain has a prevalence ranging from 30 % to 50 % in the general population. About a third of these patients will suffer from chronic neck pain in the future [1, 2]. Despite the fact that clear evidence of benefit has not been demonstrated, cervical spine surgery is often performed in patients with severe radiculopathy and conservative treatment failure [3, 4]. Identifying adequate risk groups who can benefit from surgical procedures is therefore a major objective for diagnostic imaging.

Spinal disc herniation is one of the most common causes of neck pain and can be evaluated with magnetic resonance imaging (MRI). Furthermore, laterally located cervical disc herniations are the most common cause of acute radiculopathy, narrowing the neuroforamen, which each contain a spinal nerve [5].

Anatomic studies demonstrated that the cervical neuroforamen is angled 45° degrees towards the anterior-posterior plane and inclined 10–15° towards the horizontal plane. Despite this fact, standard sequences for cervical spine MRI mainly include axial and sagittal planes, commonly not displaying the neuroforamen [6].

This is the reason why sagittal MRI images angled towards the neuroforamen were introduced and studied by different groups [7, 8]. Subsequently they were named oblique sagittal images (OSIs).

However, to date, no study has been published, which showed that OSIs are able to improve the assessment of the severity of a neuroforaminal stenosis due to disc herniation compared to standard sagittal images (SSIs). Although in clinical practice, the assessment of the severity of a neuroforaminal stenosis helps to evaluate its clinical relevance and to determine the location from which the symptoms originate.

For that reason, the aim of our study was to evaluate whether OSIs, in comparison to SSIs, are able to enhance the accuracy of the assessment of the severity of a neuroforaminal stenosis

caused by disc herniations. Moreover, we correlated our results with clinical data including neurological symptoms and whether spinal surgery was subsequently performed.

Materials and Methods

Case Selection

All consecutive patients who had received cervical spine MRI from January 2014 to July 2017 at our hospital were retrospectively analyzed, encompassing a total number of 405 exams. MRI exams were screened manually for disc herniations, which compromised the cervical neural foramen on axial T₂-weighted images. This evaluation was done according to an established definition: When the narrowest width of the neuroforaminal was equal to or smaller than the extraforaminal nerve root width, the disc herniation was classified as compromising the neural foramen [9]. 104 disc herniations of 74 patients were identified in this context. Foraminal disc herniations as well as extraforaminal, recessal (subarticular) and bulged discs with a relation to the neural foramen were included. Median (central) and recessal disc herniations without relation to the neural foramen were excluded. Herniations from the levels C3/4 to C7/Th1 were included. Patient age ranged from 34 to 79 with a mean of 55 years. 44 patients (59 %) were male and 30 were female (41 %). The study was performed with waiver of informed consent by the local review board.

Clinical data

29 of the 74 identified patients were neurologically examined and evaluated after the cervical spine MRI in our neurosurgical outpatient clinic by a senior neurosurgeon. These 29 patients accounted for 45 included disc herniations. The other 45 patients were referred from external physicians and only came to our clinic to complete the MRI exam.

► **Table 1** In-house 3 Tesla MRI protocol for the cervical spine.

► **Tab. 1** 3-Tesla Halswirbelsäulen MRT-Protokoll in unserer Abteilung.

sequence	TR/TE [ms]	Slice thickness
T2 tse sagittal	4000/101	3 mm
T1 tse sagittal	1600/10	3 mm
STIR coronal	4500/40	3 mm
T2 medic axial	832/22	3 mm
T2 tse axial	7980/102	3 mm
T2 tse oblique sagittal right	3000/100	2 mm
T2 tse oblique sagittal left	3000/100	2 mm

► **Table 2** Number of cases assessed according to the neuroforaminal stenosis grade for standard and oblique sagittal images of reader MAW.

► **Tab. 2** Anzahl der ausgewerteten Fälle hinsichtlich des neuroforaminalen Stenosegrades in sagittalen Standardaufnahmen sowie schräg sagittalen Aufnahmen der Radiologen MAW.

reader MAW	standard sagittal	oblique sagittal
grade 0	1	0
grade 1	7	0
grade 2	44	9
grade 3	52	95

For the 29 patients who were seen in our neurosurgical clinic, the corresponding and following reports were checked. It was noted if the patients had neurological symptoms at the time of the MRI exam and if a cervical spine surgery was performed at the corresponding level subsequently. The neurosurgical technique was not taken into account. If the patient suffered from cervicobrachial numbness, tingling, weakness or paralysis, he was defined as positive for neurological symptoms. Pain was not included because of the lack of specificity for originating radiculopathy.

Image analysis

Patients with disc herniations were evaluated for neuroforaminal stenosis grade on standard sagittal and oblique sagittal images by one senior (MAW) and one resident radiologist (LK), both with experience in musculoskeletal imaging. Radiologists worked independently and were blinded for clinical information and the radiological report.

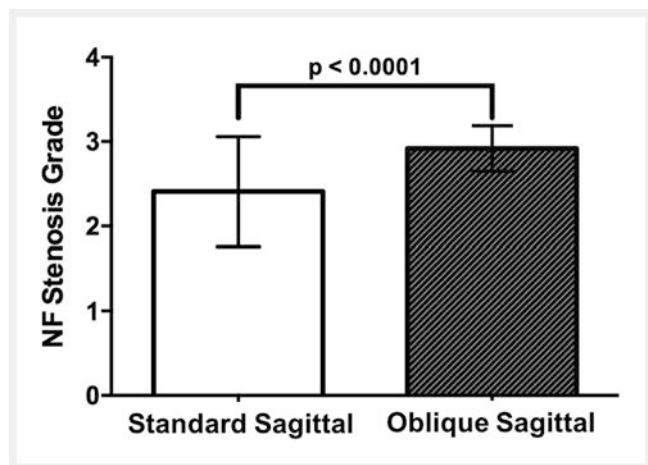
Grading system for neuroforaminal stenosis

Grading was performed using an established classification by Park et al., which was originally designed for oblique sagittal images

► **Table 3** Number of cases assessed according to the neuroforaminal stenosis grade for standard and oblique sagittal images of reader KILA.

► **Tab. 3** Anzahl der ausgewerteten Fälle hinsichtlich des neuroforaminalen Stenosegrades in sagittalen Standardaufnahmen sowie schräg sagittalen Aufnahmen der Radiologen KILA.

reader KILA	standard sagittal	oblique sagittal
grade 0	1	0
grade 1	7	0
grade 2	45	8
grade 3	51	96



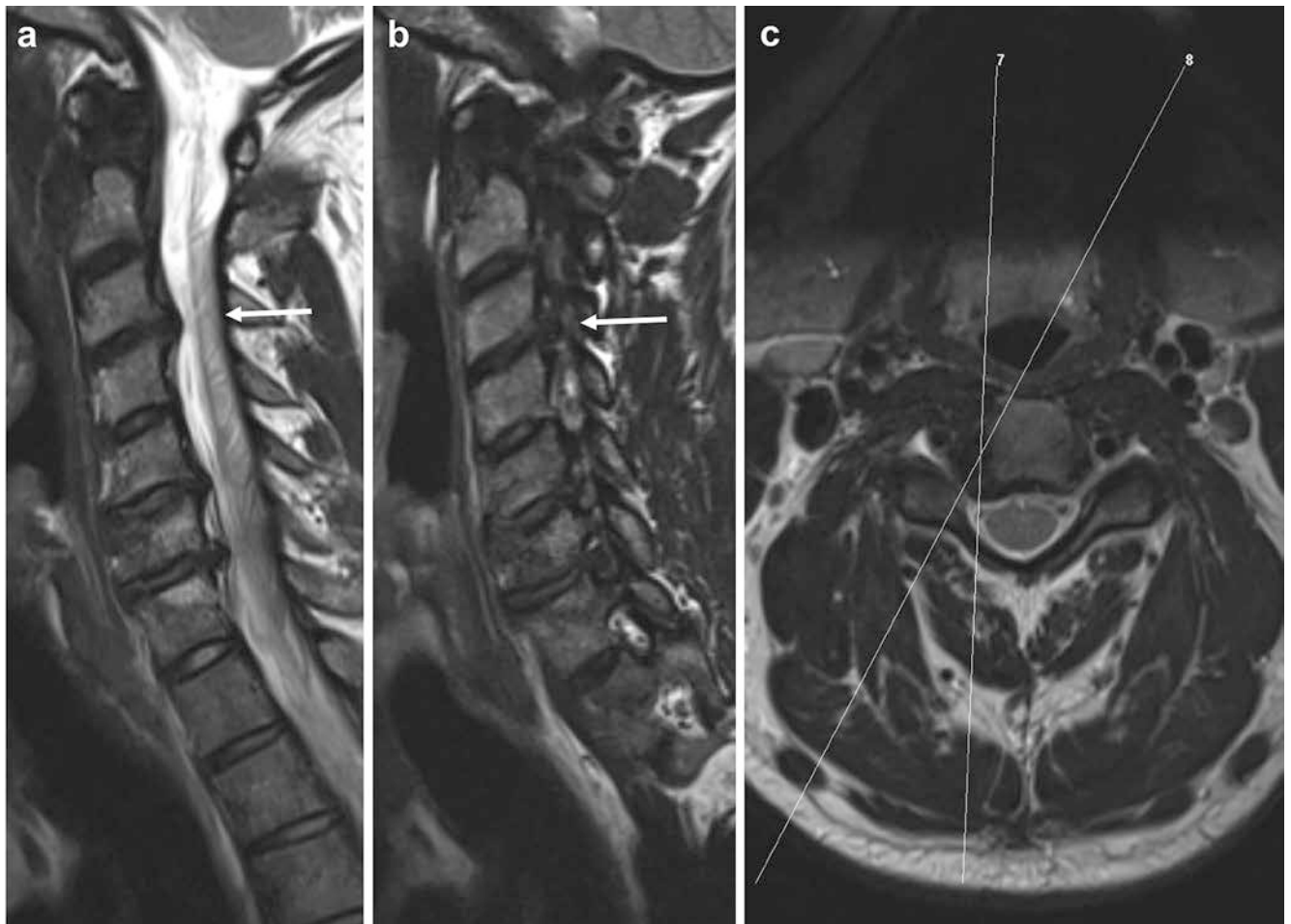
► **Fig. 1** Mean neuroforaminal stenosis grade of all 104 cervical disc herniations including evaluations from reader MAW and KILA, comparing standard sagittal to oblique sagittal images. The mean neuroforaminal stenosis grade was significantly lower in standard sagittal (2.41 ± 0.65) compared to oblique sagittal images (2.92 ± 0.27 ; $n = 104$; $p < 0.0001$).

► **Abb. 1** Der durchschnittliche neuroforaminal Stenosegrad zwischen beiden Radiologen war signifikant niedriger in den sagittalen Standardaufnahmen ($2,41 \pm 0,65$) im Vergleich zu den schräg-sagittalen Aufnahmen ($2,92 \pm 0,27$; $n = 104$; $p < 0,0001$).

(OSIs) and differentiates the following 4 groups: 0 – no significant stenosis of the neural foramen and no perineural fat obliteration; 1 (mild) – perineural fat obliteration involving less than 50% of the nerve root circumference without morphological change of the nerve root itself; 2 (moderate) – perineural fat obliteration involving more than 50% of the nerve root circumference without morphological change of the nerve root itself; 3 (severe) – morphological change of the nerve root including nerve root collapse and severe perineural fat obliteration [10, 11].

MRI protocol

All exams were completed using a uniform MRI protocol. T₂-weighted turbo spin echo sequences were used for OSIs. The parameters were as follows: field of view, 26 cm; slice thickness



► **Fig. 2** **a** Standard sagittal, **b** oblique right sagittal and **c** axial T2-TSE MRI images of the cervical spine of a 40-year-old male patient. A right foraminal disc extrusion at C3/4 is shown (arrows). **a** On standard sagittal images a “grade 1” neuroforaminal stenosis is expected. **b** Although oblique sagittal images show complete obliteration of perineural fat including compression of the right C4 nerve root, signifying a “grade 3” neuroforaminal stenosis. **c** Thin white lines on the axial image mark the flip angle of images **a**, **b**.

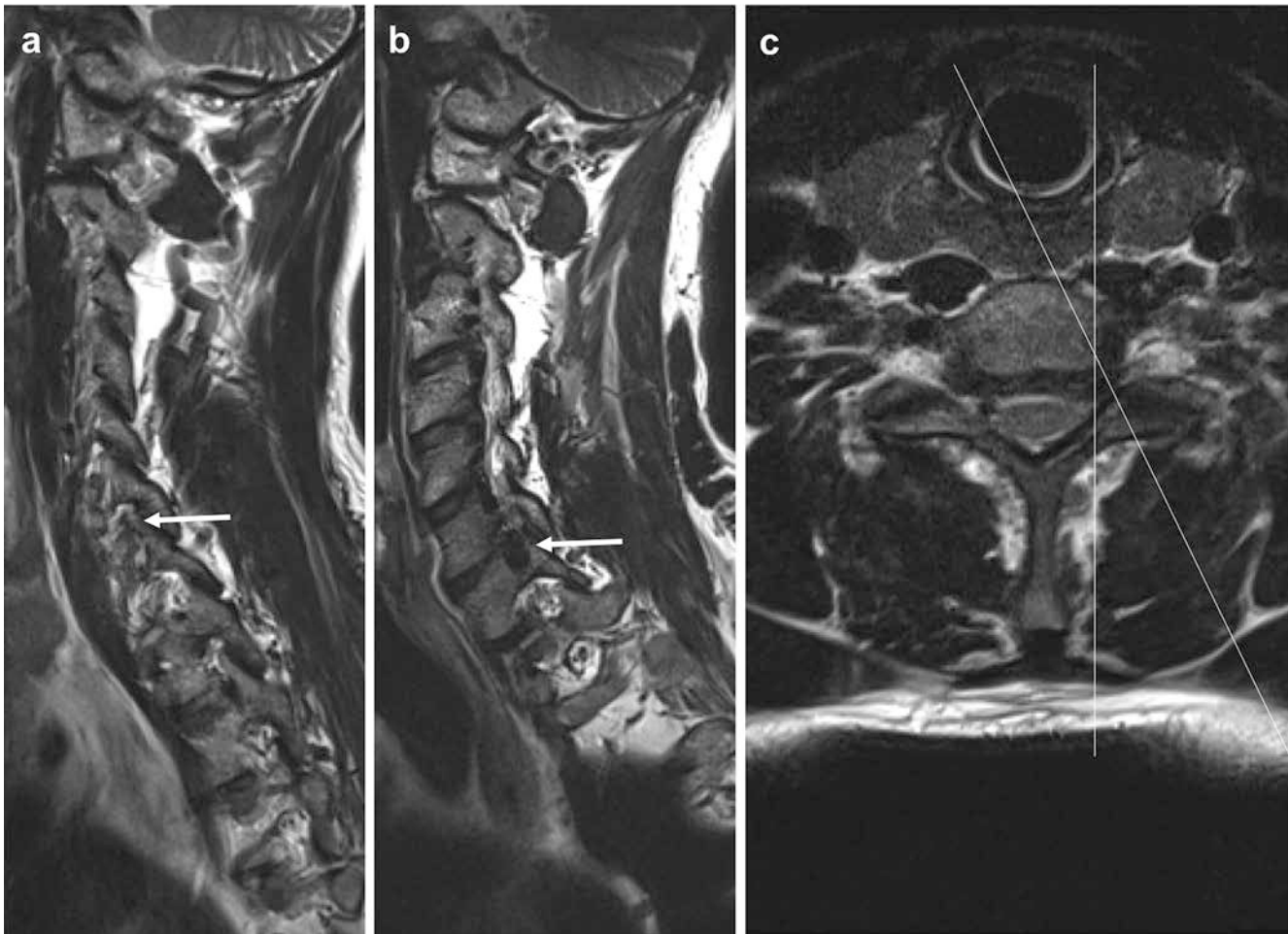
► **Abb. 2** **a** Standard sagittale, **b** schräg-rechts sagittale und **c** axiale T2-TSE-MRT-Aufnahmen der Halswirbelsäule eines 40-jährigen Patienten. Eine rechts-foraminal gelegene Bandscheibenextrusion besteht auf Höhe C3/4 (Pfeile). **a** In den sagittalen Standardaufnahmen wird eine „Grad 1“ neuroforaminale Stenose erwartet. **b** In den schräg-sagittalen Aufnahmen zeigt sich jedoch eine vollständige Verdrängung des perineuralen Fettes sowie eine Kompression der rechten C4-Spinalwurzel und somit eine „Grad 3“ neuroforaminale Stenose. **c** Die dünnen weißen Linien markieren die Kippwinkel für **a**, **b** in der axialen Aufnahme.

2 mm; slice number 13; acquisition time, 2:29 min; repetition time/echo time, 3000/100 ms. T₂-weighted turbo spin echo sequences were also used for standard sagittal images (SSIs). The parameters were as follows: field of view, 30 cm; slice thickness 3 mm; slice number 17; acquisition time, 3:30 min; repetition time/echo time, 4000/101 ms. OSIs were angled 30° to the right and left, respectively, in the axial plane compared to the SSIs. An additional angulation in the sagittal or coronal plane was not performed. Images were acquired on a 3T-MRI scanner (Magnetom Verio, Siemens Healthineers, Erlangen, Germany).

Our related in-house 3 Tesla MRI protocol for the cervical spine is shown in ► **Table 1**.

Statistical Analysis

Descriptive statistics (mean, standard deviation, median, and range) were provided where appropriate. Parametric data were tested using the 2-tailed Student’s t-test. Before applying the Student’s t-test, normality of data was tested and proved according to the Shapiro-Wilk test. Results with a corresponding p-value of less than 0.05 were considered statistically significant. Intra- and interobserver reliability between both radiologists was performed using kappa statistics. A kappa value of 0.81 – 1 was considered to be almost perfect [12]. GraphPad Prism 6 (GraphPad Software Inc., La Jolla, CA, USA) was used for the statistical analysis.



► **Fig. 3** **a** Standard sagittal, **b** oblique right sagittal and **c** axial T2-TSE MRI images of the cervical spine of a 48-year-old male patient. An asymmetric bulged disc with relation to the left neural foramen at level C6/7 is shown (arrows). **a** On sagittal images less than 50% of the perineural fat seems to be infiltrated, signifying a “grade 1” neuroforaminal stenosis. **b** Although oblique sagittal images show complete obliteration of the perineural fat and root compression of the left C7 nerve root, demonstrating “grade 3” neuroforaminal stenosis. **c** Thin white lines on the axial image mark the flip angle of images **a**, **b**.

► **Abb. 3** **a** Standard sagittale, **b** schräg-rechts sagittale und **c** axiale T2-TSE-MRT-Aufnahmen der Halswirbelsäule eines 40-jährigen Patienten. Ein asymmetrisches „Disc-Bulging“ mit Bezug zum linken Neuroforamen besteht auf Höhe C6/7 (Pfeile). **a** In den sagittalen Standardaufnahmen wird erwartet, dass weniger als 50% des perineuralen Fettgewebes infiltriert wird. **b** In den schräg-sagittalen Aufnahmen demarkiert sich jedoch eine vollständige Verdrängung des perineuralen Fettes sowie eine Kompression der linken C7-Spinalwurzel. **c** Die dünnen weißen Linien markieren die Kippwinkel für **a** und **b** in der axialen Aufnahme.

Results

Correlation between neuroforaminal stenosis grades in standard and oblique sagittal images

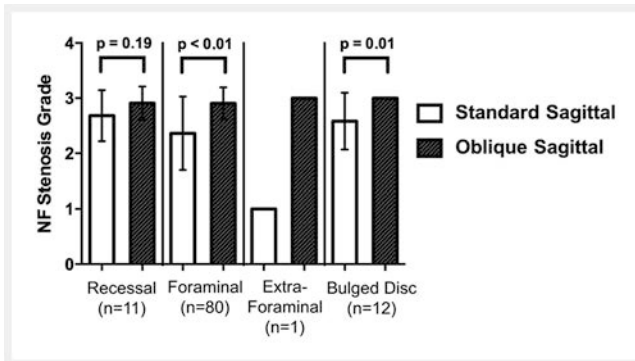
Interestingly major differences were obtained between both techniques. In 49 of 104 disc herniations (47.1%), at least one reader reported a neuroforaminal stenosis, which was at least 1 grade lower in standard sagittal images (SSIs) compared to oblique sagittal images (OSIs). In 7 cases (6.7%) both readers underestimated the neuroforaminal stenosis grade (NSG) by 2 units in SSIs compared to OSIs. In 40 cases (38.5%) reader KILA and in 39 cases (37.5%) reader MAW underestimated the NSG by 1 unit. Only in 1 of 104 cases (1%) was NSG overestimated by 1 unit in SSIs com-

pared to OSIs by reader MAW. An overestimation was not reported by reader KILA.

Considering averages of both readers, grade 0 was assessed in 1 case for SSIs compared to 0 cases for OSIs (► **Table 2, 3**). Grade 1 was assessed in 7 compared to 0 cases, grade 2 in 44.5 compared to 8.5 cases and grade 3 in 51.5 compared to 95.5 cases.

Moreover, the mean NSG of all evaluated disc herniations, taking into account results of both readers, was significantly lower for SSIs compared to OSIs ($p < 0.001$), ► **Fig. 1**.

Examples of two different cervical spine herniations, where the NSG was underestimated in SSIs opposed to OSIs, are shown in ► **Fig. 2, 3**.



► **Fig. 4** Mean neuroforaminal stenosis grades based on the location of the disc herniation in sagittal compared to oblique sagittal images. Significant differences were obtained for foraminal herniations with a mean neuroforaminal stenosis grade of 2.36 ± 0.67 in standard sagittal images compared to 2.91 ± 0.29 ($n = 80$; $p < 0.001$) in oblique sagittal images, as well as for bulged discs with relation to the neural foramen with 2.58 ± 0.51 compared to 3.00 ± 0 ($n = 12$; $p = 0.010$). No significant difference was seen for recessal disc herniations with relation to the neural foramen with 2.68 ± 0.46 in standard sagittal images and 2.91 ± 0.30 in oblique sagittal images ($n = 11$; $p = 0.187$). Extraforaminal herniations were not representative with only one evaluated disc herniation.

► **Abb. 4** Durchschnittliche neuroforaminale Stenosegrade in Abhängigkeit von der Lokalisation der Herniation in sagittalen Standardaufnahmen im Vergleich zu schräg sagittalen Aufnahmen. Signifikante zeigten sich für foraminal gelegene Herniationen bei einem durchschnittlichen Stenosegrad von $2,36 \pm 0,67$ in Standardaufnahmen verglichen mit $2,91 \pm 0,29$ ($n = 80$; $p < 0,001$) in schrägen Aufnahmen, sowie für „bulged-discs“ mit Bezug zum Neuroforamen mit $2,58 \pm 0,51$ verglichen zu $3,00 \pm 0$ ($n = 12$; $p = 0,010$). Kein signifikanter Unterschied ergab sich für rezessal gelegene Herniationen mit Bezug zum Neuroforamen mit $2,68 \pm 0,46$ in Standardaufnahmen und $2,91 \pm 0,30$ in schrägen Aufnahmen ($n = 11$; $p = 0,187$). Extraforaminale Herniationen waren nicht repräsentativ bei nur einer einzigen eingeschlossenen Herniation.

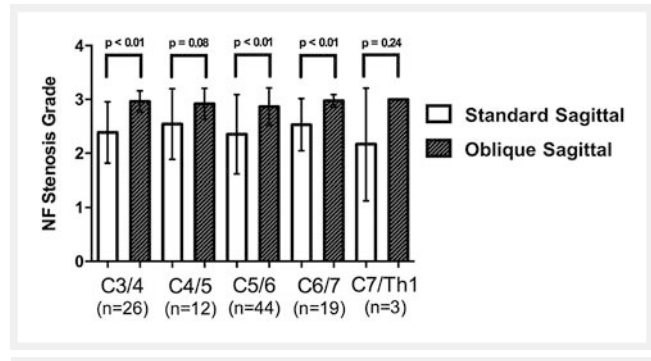
Correlation between neuroforaminal stenosis grades in standard and oblique sagittal images based on the location of the disc herniation to the neural foramen

The average NSG was significantly lower in SSIs compared to OSIs for foraminal herniations ($p < 0.001$) and bulged discs with relation to the neural foramen ($p = 0.010$). In contrast, no significant difference was obtained between the two groups for recessal disc herniations with relation to the neural foramen ($p = 0.187$), ► **Fig. 4**.

Only a single case of an extraforaminal disc herniation was included in the study. Therefore, the data was assessed as not being representative, although a difference was seen between SSIs and OSIs by both readers (1 vs. 3).

Correlation between neuroforaminal stenosis grades in standard and oblique sagittal images based on the cervical spine level of the disc herniation

For each level from C3/4 to C7/Th1, the NSG was lower on SSIs compared to OSIs, ► **Fig. 5**. Differences between the two groups were significant for the levels C3/4 ($p < 0.001$), C5/6 ($p < 0.001$)



► **Fig. 5** Mean neuroforaminal stenosis grades based on disc herniation level between standard and oblique sagittal images. Significant differences were obtained for the levels C3/4, C5/6 and C6/7, no significant differences were obtained for levels C4/5 and C7/Th1. Size difference did not vary relevantly between different levels. Sagittal compared to oblique sagittal sequences, for C3/4 (2.39 to 2.96 ; $n = 26$; $p < 0.001$), C4/5 (2.54 to 2.92 ; $n = 12$; $p = 0.084$), C5/6 (2.35 to 2.85 ; $n = 44$; $p < 0.001$), C6/7 (2.53 to 2.97 ; $n = 19$; $p < 0.001$), C7/Th1 (2.17 to 3.00 ; $n = 3$; $p = 0.248$).

► **Abb. 5** Durchschnittliche neuroforaminale Stenosegrade abhängig von der Höhenlokalisierung des Bandscheibenfaches in sagittalen Standardaufnahmen im Vergleich zu schräg sagittalen Aufnahmen. Signifikante Unterschiede ergaben sich für die Höhen C3/4, C5/6 und C6/7, keine signifikanten Unterschiede ergaben sich für C4/5 und C7/Th1. Das Maß der Unterschiede variierte nicht relevant zwischen den einzelnen Höhen. Sagittale Standardaufnahmen im Vergleich zu schräg sagittalen Aufnahmen, für C3/4 ($2,39$ zu $2,96$; $n = 26$; $p < 0,001$), C4/5 ($2,54$ zu $2,92$; $n = 12$; $p = 0,084$), C5/6 ($2,35$ zu $2,85$; $n = 44$; $p < 0,001$), C6/7 ($2,53$ zu $2,97$; $n = 19$; $p < 0,001$), C7/Th1 ($2,17$ zu $3,00$; $n = 3$; $p = 0,248$).

and C6/7 ($p < 0.001$). Calculated differences were not significant for the levels C4/5 ($p = 0.084$) and C7/Th1 ($p = 0.248$). However, it has to be stated that the number of included herniations were notably lower for these levels. It has to be assumed that a greater number of herniations would have turned into a significant result. Nevertheless, an obvious difference could not be determined between the different cervical spine levels.

Correlation of clinical data with neuroforaminal stenosis grades in standard and oblique sagittal images

18 of the 29 patients who were neurologically examined in our outpatient clinic had neurological symptoms. These 18 patients accounted for 29 disc herniations in our study. In this group, SSIs also led to a significantly lower NSG in comparison to OSIs ($p = 0.002$), ► **Fig. 6**.

20 of these 29 patients subsequently underwent cervical spine surgery in our clinic. These 20 patients accounted for 30 disc herniations in our study. In this group, the average NSG was also significantly lower in SSIs compared to OSIs ($p = 0.004$).

Thus, the fact that SSIs tend to underestimate the severity of neuroforaminal stenosis compared to OSIs is of clinical relevance.

► **Table 4** Grading of both readers. Matrix view of neuroforaminal stenosis grades from reader KILA and MAW in standard sagittal images (upper table) as well as in oblique sagittal images (lower table).

► **Tab. 4** Gradeinteilungen beider Radiologen. Matrixansicht der neuroforaminalen Stenosegrade der Radiologen KILA und MAW in sagittalen Standardaufnahmen (oben) und schräg sagittalen Aufnahmen (unten).

standard sagittal		reader KILA				
reader MAW		grade 0	grade 1	grade 2	grade 3	total
grade 0		1	0	0	0	1
grade 1		0	7	0	0	7
grade 2		0	0	41	3	44
grade 3		0	0	4	48	52
total		1	7	45	51	104
oblique sagittal		reader KILA				
reader MAW		grade 0	grade 1	grade 2	grade 3	total
grade 0		0	0	0	0	0
grade 1		0	0	0	0	0
grade 2		0	0	8	1	9
grade 3		0	0	0	95	95
total		0	0	8	96	104

Accordance rates and interreader reliability

NSGs of both readers are shown in the matrix view in ► **Table 4**.

Notably, grading of SSIs seemed more prone to error than grading of OSIs (► **Table 5**). The accordancy rate between both readers was better for OSIs (103/104; 99%) than for SSIs (97/104; 93%). Interreader reliability analysis emphasized this tendency with kappa values of 0.94 and 0.88, respectively, but demonstrated “almost perfect” interreader reliability for both angulations.

Discussion

Patients commonly present with symptoms such as neck and shoulder pain as well as upper extremity hypesthesia. However, their origin can be difficult to diagnose based on physical examination [13]. Furthermore, cervical surgeries which are indicated in patients with severe radiculopathy and conservative treatment failure or significant myelopathy, have a relevant risk of complication, requiring the best possible tests to obtain a precise diagnosis [3, 4]. Currently, AP and lateral radiographs are still the first option in patients with chronic neck pain. Only patients with neurological symptoms or patients with chronic neck pain in whom conservative treatment has failed should undergo cervical spine MRI [14, 15]. In that context, MRI plays a key role in the assessment of spinal cord and root impingement. However, the neural foramen which contains the spinal root is poorly depicted on standard sagittal and axial images, which is the reason why oblique sagittal images (OSIs) were introduced [6–8].

In this study, we could firstly demonstrate that standard sagittal images (SSIs) in cervical spine MRI compared to OSIs significantly underestimate the severity of neuroforaminal stenoses

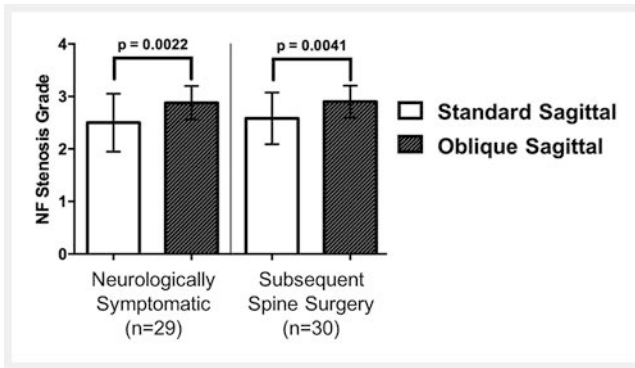
► **Table 5** Grading of both readers. Interreader reliability scores between reader KILA and MAW. Unweighted kappa values showed a lower interreader reliability in conventional sagittal images (0.88) compared to oblique sagittal images (0.94), both being “almost perfect”. Accordance between reader KILA and MAW was obtained in 97 of 104 cases (93%) on standard sagittal images and in 103 of 104 cases (99%) on oblique sagittal images.

► **Tab. 5** Gradeinteilungen beider Radiologen. Zuverlässigkeitsberechnungen zwischen den Radiologen KILA und MAW. Der ungewichtete Kappa-Wert war niedriger in den Standardaufnahmen (0,88) als in den schrägen Aufnahmen (0,94), beide waren allerdings „fast perfekt“. Eine Übereinstimmung erfolgte in 97 von 104 Fällen (93%) in den Standardaufnahmen und in 103 von 104 cases (99%) in den schrägen Aufnahmen.

	standard sagittal	oblique sagittal
κ-value	0.88	0.94
accordance	0.93	0.99

caused by disc herniations, ► **Table 2, 3**, ► **Fig. 1**. Shim et al. were able to show that neuroforaminal stenoses can be overlooked in SSIs compared to OSIs. However, they did not take the severity of the narrowing into account even though the severity is very relevant information because it allows for an assessment of whether the affected nerve root is compressed [10].

As expected, foraminal disc herniations and bulged discs with relation to the neural foramen showed significantly lower means of neuroforaminal stenosis grades (NSG) for SSIs compared to OSIs, ► **Fig. 4**. In contrast, no significant difference was obtained for recessal (subarticular) disc herniations with relation to the neural foramen. That confirms our expectations, because recessal



► **Fig. 6** Mean neuroforaminal stenosis grades in standard sagittal compared to oblique sagittal images taking clinical data into account. In both partly overlapping groups, a significant difference was obtained for the mean neuroforaminal stenosis grade, comparing standard sagittal to oblique sagittal images, in the neurologically symptomatic group 2.50 ± 0.55 compared to 2.88 ± 0.32 ($n = 29$; $p = 0.0022$) and in the group which underwent spinal surgery subsequently 2.58 ± 0.49 compared to 2.90 ± 0.31 ($n = 30$; $p = 0.0041$).

► **Abb. 6** Durchschnittliche neuroforaminale Stenosegrade zwischen sagittalen Standardaufnahmen im Vergleich zu schräg sagittalen Aufnahmen unter Berücksichtigung der klinischen Daten. In beiden, partiell sich überlappenden Gruppen, Nachweis eines signifikanten Unterschiedes, in der Gruppe der neurologisch symptomatischen Patienten mit $2,50 \pm 0,55$ verglichen zu $2,88 \pm 0,32$ ($n = 29$; $p = 0,0022$) und in der Gruppe der Patienten bei denen im Anschluss ein operativer Dekompressionseingriff erfolgte mit $2,58 \pm 0,49$ verglichen zu $2,90 \pm 0,31$ ($n = 30$; $p = 0,0041$).

herniations are medially located and therefore mostly well depicted in SSIs [16, 17]. According to our expectations, no significant differences were seen between the different disc levels, ► **Fig. 5**.

Additionally, our results are of clinical relevance. Looking at the patients in our study who had neurological symptoms consistent with cervical radiculopathy and subsequently underwent cervical spinal surgery confirms the results. The mean NSG was significantly lower for SSIs compared to OSIs, ► **Fig. 6**. That signifies that even in clinically relevant cases, OSIs allow a more precise evaluation of neuroforaminal stenoses. These results are in accordance with the study of Shim et al., which could demonstrate that the sensitivity and specificity to detect a neuroforaminal stenosis in a cohort with surgically confirmed narrowing are higher for OSIs. However, stenosis severity was not assessed in this study.

Moreover, our study confirmed results from other groups showing that the interreader reliability as well as the accordance rate are higher for OSIs compared to SSIs when assessing laterally located disc herniations, ► **Table 4, 5** [18–20]. A lower variability between the reading radiologists can therefore be expected in OSIs.

Concerning laterally located disc herniations, surgical treatment is only considered in patients with severe radiculopathy [3]. Additionally, MRI schedules are often very busy and it should therefore be avoided to extend protocols unnecessarily. Therefore, we recommend performing OSIs in addition to the standard protocol in patients with a cervical radiculopathy.

Conclusion

This study was able to demonstrate that oblique sagittal images (OSIs) are valuable sequences in cervical spine MRI and can prevent underestimation of the severity of neuroforaminal stenoses caused by disc herniations. In order to assess the potential therapeutic consequence, OSIs should therefore be performed as an adjunct to the standard MRI protocol for patients with a cervical radiculopathy.

Contribution to the field of radiology

In this study, we could demonstrate for the first time that standard sagittal images in comparison to oblique sagittal images underestimate the severity of neuroforaminal stenoses caused by disc herniations in cervical spine MRI. That is confirmed by looking at the clinical data and particularly applies for foraminal disc herniations as well as for bulged discs with relation to the neural foramen. Oblique sagittal images should therefore be performed in addition to the standard MRI protocol in selected patients with a radiculopathy in order to improve clinical assessment.

ABBREVIATIONS

NSG	neuroforaminal stenosis grade
SSI	standard sagittal image
OSI	oblique sagittal image
MRI	magnetic resonance imaging

Conflict of Interest

The authors declare that they have no conflict of interest.

References

- [1] Hogg-Johnson S, van der Velde G, Carroll LJ et al. The Burden and Determinants of Neck Pain in the General Population Results of the Bone and Joint Decade 2000–2010 Task Force on Neck Pain and Its Associated Disorders. *Spine (Phila Pa 1976)* 2000; 33: 39–51
- [2] Côté P, Cassidy JD, Carroll LJ et al. The annual incidence and course of neck pain in the general population: A population-based cohort study. *Pain* 2004; 112: 267–273
- [3] Bambakidis NC, Feiz-Erfan I, Klopfenstein JD et al. Indications for Surgical Fusion of the Cervical and Lumbar Motion Segment. *Spine (Phila Pa 1976)* 2005; 30: S2–S6
- [4] Van Middelkoop M, Rubinstein SM, Ostelo R et al. Surgery versus conservative care for neck pain: A systematic review. *Eur Spine J* 2013; 22: 87–95
- [5] Steilen D, Hauser R, Woldin B et al. Chronic neck pain: making the connection between capsular ligament laxity and cervical instability. *Open Orthop J* 2014; 8: 326–345
- [6] Daniels DL, Hyde JS, Kneeland JB et al. The cervical nerves and foramina: Local-coil MR imaging. *Am J Neuroradiol* 1986; 7: 129–133
- [7] Yenerich DO, Houghton VM. Oblique Plane MR Imaging of the Cervical Spine. *J Comput Assist Tomogr* 1986; 10: 823–826

- [8] Humphreys SC, An HS, Eck JC et al. Oblique MRI as a Useful Adjunct in Evaluation of Cervical Foraminal Impingement. *J Spinal Disord* 1998; 11: 295–299
- [9] Kim S, Lee JW, Chai JW et al. A New MRI Grading System for Cervical Foraminal Stenosis Based on Axial T2-Weighted Images. *Korean J Radiol* 2015; 16: 1294–1302
- [10] Park HJ, Kim SS, Han CH et al. The clinical correlation of a new practical MRI method for grading cervical neural foraminal stenosis based on oblique sagittal images. *Am J Roentgenol* 2014; 203: 412–417
- [11] Park HJ, Kim SS, Lee SY et al. A practical MRI grading system for cervical foraminal stenosis based on oblique sagittal images. *Br J Radiol* 2013; 86: 1–7
- [12] Landis JR, Koch GG. The Measurement of Observer Agreement for Categorical Data. *Biometrics* 1977; 33: 159–174
- [13] Caridi JM, Pumberger M, Hughes AP. Cervical Radiculopathy: A Review. *Musculoskelet J Hosp Spec Surg* 2011; 7: 265–272
- [14] Boutin RD, Steinbach LS, Finnesey K. MR imaging of degenerative diseases in the cervical spine. *Magn Reson Imaging Clin N Am* 2000; 8: 471–490
- [15] American College of Radiology Appropriateness Criteria. Chronic Neck Pain. 2013: 1–14
- [16] Fardon DF, Williams AL, Dohring EJ et al. Lumbar disc nomenclature: version 2.0. *Spine J* 2014; 14: 2525–2545
- [17] Costello RF, Beall DP. Nomenclature and Standard Reporting Terminology of Intervertebral Disk Herniation. *Magn Reson Imaging Clin N Am* 2007; 15: 167–174
- [18] Freund W, Klessinger S, Mueller M et al. Nutzen der halbkoronaren Schichtung im MRT der Halswirbelsäule: Verbesserte Erkennbarkeit von Neuroforamina. *Radiologe* 2015; 55: 1000–1008
- [19] Park MS, Moon SH, Lee HM et al. Diagnostic value of oblique magnetic resonance images for evaluating cervical foraminal stenosis. *Spine J* 2015; 15: 607–611
- [20] Kim W, Ahn KS, Kang CH et al. Comparison of MRI grading for cervical neural foraminal stenosis based on axial and oblique sagittal images: Concordance and reliability study. *Clin Imaging* 2017; 43: 165–169

CORRECTION

Oblique Sagittal Images Prevent Underestimation of the Neuroforaminal Stenosis Grade Caused by Disc Herniation in Cervical Spine MRI

L. Kintzelé, C. Rehnitz, H.-U. Kauczor, M.-A. Weber. *Fortschr Röntgenstr* 2018; 190: 946–954, doi 10.1055/a-0612-8205

The affiliation of M.-A. Weber has been corrected. Correct is

Laurent Kintzelé¹, Christoph Rehnitz¹, Hans-Ulrich Kauczor¹, Marc-André Weber²

¹ Diagnostic and Interventional Radiology, University Hospital Heidelberg, Germany

² Institute of Diagnostic and Interventional Radiology, University Medical Center Rostock, Rostock, Germany