

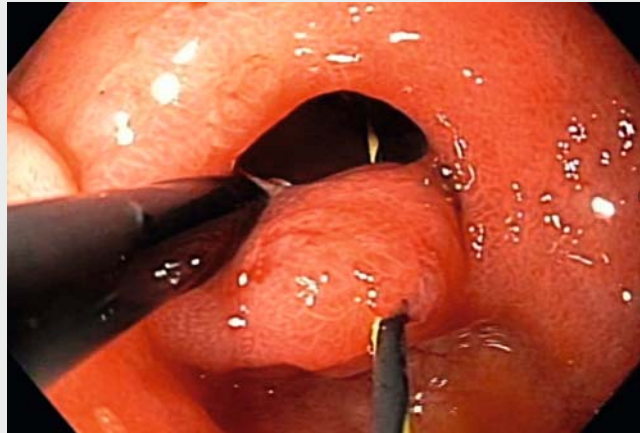Combination of endoscopic treatment – septectomy and stricturotomy in the afferent ileal limb of the ileal pouch

Endoscopic therapy of inflammatory bowel disease associated complications, such as stricture and fistula, has become an adjunct to medical and surgical treatment [1, 2]. Here we describe the case of a patient with ulcerative colitis and ileal pouch-anal anastomosis (IPAA) with complex stricture, which was successfully treated with a combined endoscopic stricturotomy and septectomy (► **Video 1**).

The patient was a 68-year-old woman with a diagnosis of ulcerative colitis since 1997. She underwent a subtotal colectomy in 2000 and IPAA in 2001. Since her surgery, she suffered from recurrent episodes of pouchitis, which were successfully treated with antibiotics. In 2016, she developed an ano-vaginal fistula, which was treated by ano-rectal advancement flap.

In 2017 the patient's symptoms worsened, and she had 10 bowel movements daily along with abdominal pain, bloating, and early satiety. In January, 2018, the pouch endoscopy showed mucosal edema, erosions, and erythema in the pouch body. About 5 cm above the ileal inlet into the pouch there was a moderate narrowing of the lumen along with a septum (► **Fig. 1 a**), which a regular gastroscope could not traverse. The septum was thought to result from a full-thickness bowel wall bridge.

As a first step, a guidewire was inserted to verify the position of the septum. Then, the septum was cut with an isolated-tip (IT) knife alongside the guidewire (► **Fig. 1 b**), and the stump of the septum was resected using a polypectomy snare (► **Fig. 1 c**). The remaining stricture was then treated by IT knife stricturotomy (► **Fig. 1 d**). Subsequently, three endoscopic clips were placed along the incised edges of the stricture to maintain luminal patency and to prevent bleeding and perforation. Finally, the afferent limb was successfully intubated.



► **Video 1** Stages of combination endoscopic treatment – septectomy and stricturotomy in the afferent ileal limb of the ileal pouch.

The traditional approach to treatment of bowel strictures in patients with IBD involves endoscopic balloon dilation (EBD) or surgery. An “interventional IBD” approach extends the therapeutic armamentarium by several other techniques, such as stricturotomy, fistulotomy, and sinusotomy [3].

An endoscopic stricturotomy with needle-knife or IT knife seems to carry a higher efficacy, a lower risk of perforation, but a higher risk of bleeding than endoscopic balloon dilation [4]. Endoscopic septectomy, resection of the stump of the septum, stricturotomy, and clip placement were used to treat our patient, with no immediate or delayed complications. To the best of our knowledge, this is the first report of the combination of four endoscopic techniques used to treat a patient with IBD surgery-related complication. However, randomized controlled studies should be carried out to properly assess the endoscopic techniques described.

Endoscopy_UCTN_Code_TTT_1AQ_2AF

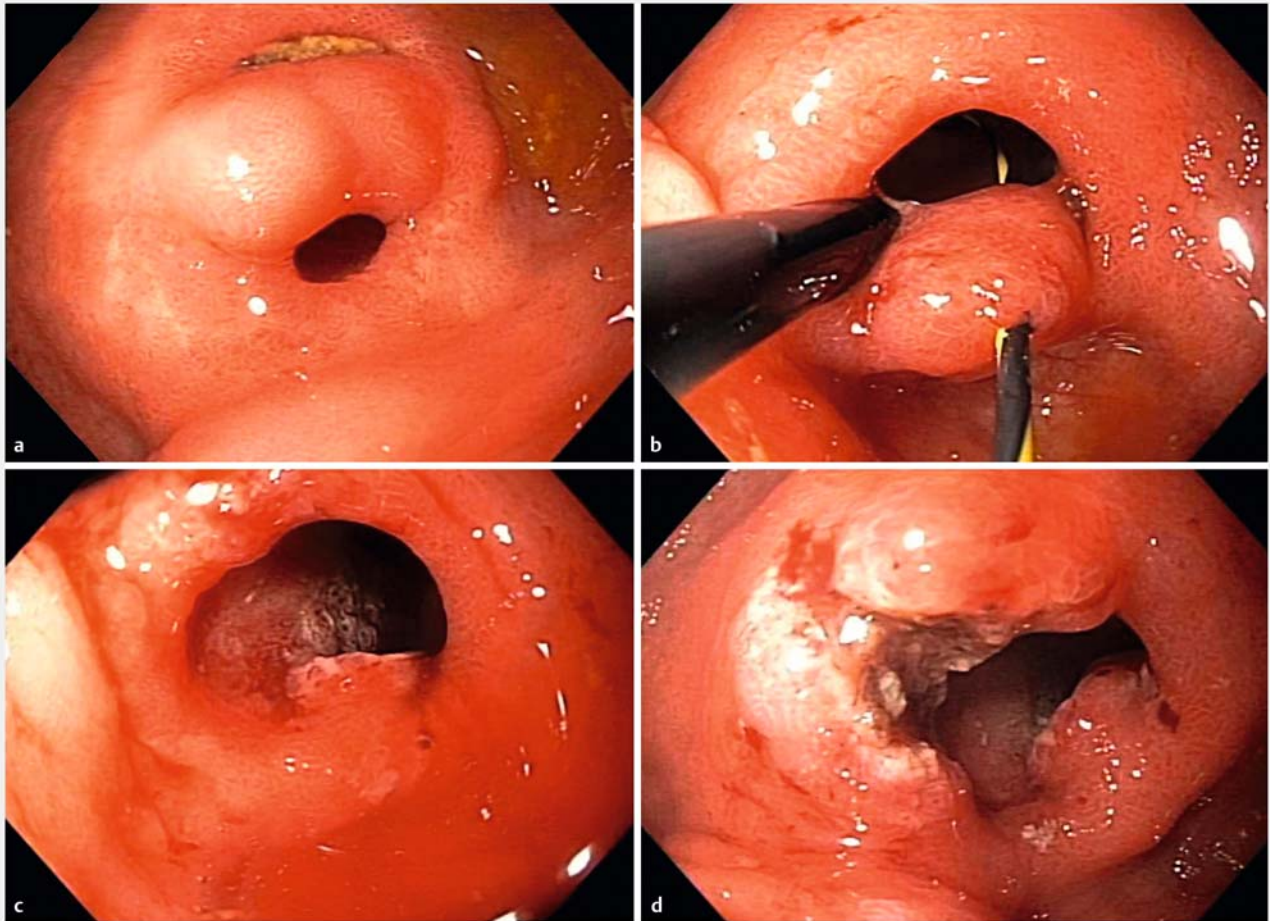
Competing interests

None

The authors

Martin Lukas¹, Martin Bortlik^{1,2,3}, Bo Shen⁴

- 1 Gastroenterology, Clinical and Research Centre for Inflammatory Bowel Disease ISCARE, Prague, Czech Republic
- 2 First Medical Faculty, Charles University, Internal Department, Central Military Hospital, Prague, Czech Republic
- 3 First Medical Faculty, Charles University, Institute of Pharmacology, Prague, Czech Republic
- 4 Gastroenterology, Center for Inflammatory Bowel Disease, Digestive Disease and Surgery Institute, The Cleveland Clinic Foundation, Cleveland, Ohio, United States



► **Fig. 1** Endoscopic views. **a** Stricture with septum in the afferent limb of the ileal pouch. **b** Endoscopic septectomy alongside the guidewire. **c** The stricture after removal of the septum. **d** Endoscopic stricturotomy.

Corresponding author

Martin Lukas, MD

Gastroenterology, Clinical and Research
Centre for Inflammatory Bowel Disease
ISCARE, Jankovcova 1569, Prague 7 Prague
17004, Czech Republic
Fax: +420-2-34770300
looker@email.cz

References

- [1] Ferlitsch A, Reinisch W, Püspök A et al. Safety and efficacy of endoscopic balloon dilation for treatment of Crohn's disease strictures. *Endoscopy* 2006; 38: 483–487
- [2] Thomas-Gibson S, Brooker JC, Hayward CM et al. Colonoscopic balloon dilation of

Crohn's strictures: a review of long-term outcomes. *Eur J Gastroenterol Hepatol* 2003; 15: 485–488

- [3] Shen B. Interventional IBD: the role of endoscopist in the multidisciplinary team management of IBD. *Inflamm Bowel Dis* 2018; 24: 298–309
- [4] Lan N, Shen B. Endoscopic stricturotomy with needle knife in the treatment of strictures from inflammatory bowel disease. *Inflamm Bowel Dis* 2017; 23: 502–513

Bibliography

DOI <https://doi.org/10.1055/a-0624-1518>
Published online: 7.6.2018
Endoscopy 2018; 50: 820–821
© Georg Thieme Verlag KG
Stuttgart · New York
ISSN 0013-726X

ENDOSCOPY E-VIDEOS

<https://eref.thieme.de/e-videos>



Endoscopy E-Videos is a free access online section, reporting on interesting cases and new techniques in gastroenterological endoscopy. All papers include a high quality video and all contributions are freely accessible online.

This section has its own submission website at
<https://mc.manuscriptcentral.com/e-videos>