

A pneumatosis intestinalis case diagnosed with water-immersion technique

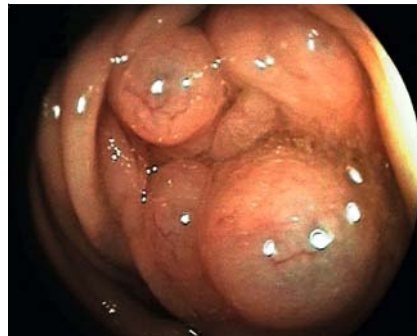
A 65-year-old man presented to the outpatient department with a complaint of moderate flatulence for 2 years. His personal history included coronary artery disease and type 2 diabetes mellitus, which was poorly controlled by oral anti-diabetic medications. He also underwent inguinal hernia operation 2 years previously.

Physical examination revealed no pathologic signs. Vital signs were within normal limits. Laboratory tests showed no abnormal values except high fasting blood sugar level. After colonic preparation with polyethylene glycol solution, colonoscopy was performed.

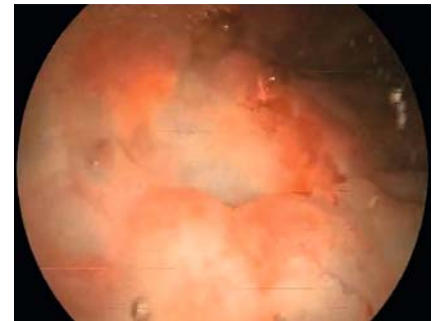
The sigmoid colon contained multiple polypoid cystic structures (► **Fig. 1**). The colonic section with these extensive lesions was filled with water. Polypoid cystic structures were punctured using a sclerotherapy needle under water. The emergence of gas bubbles from punctured sites was seen (► **Fig. 2**, ► **Video 1**). Preliminary diagnosis of pneumatosis intestinalis was considered. Subsequent computed tomography revealed intramural gas collections in the wall of the sigmoid colon.

In etiological investigation tests, chest X-ray and respiratory function tests were normal. Antinuclear antibodies and extractable nuclear antigen antibodies were found to be nonreactive. Direct examination, culture, and parasite tests of stool were negative. Rapid Detection of *Clostridium difficile* in feces by real-time polymerase chain reaction turned out to be negative too. There was no pathology on upper gastrointestinal endoscopy. Test for human immunodeficiency virus was negative. Hence, we considered our case to be idiopathic.

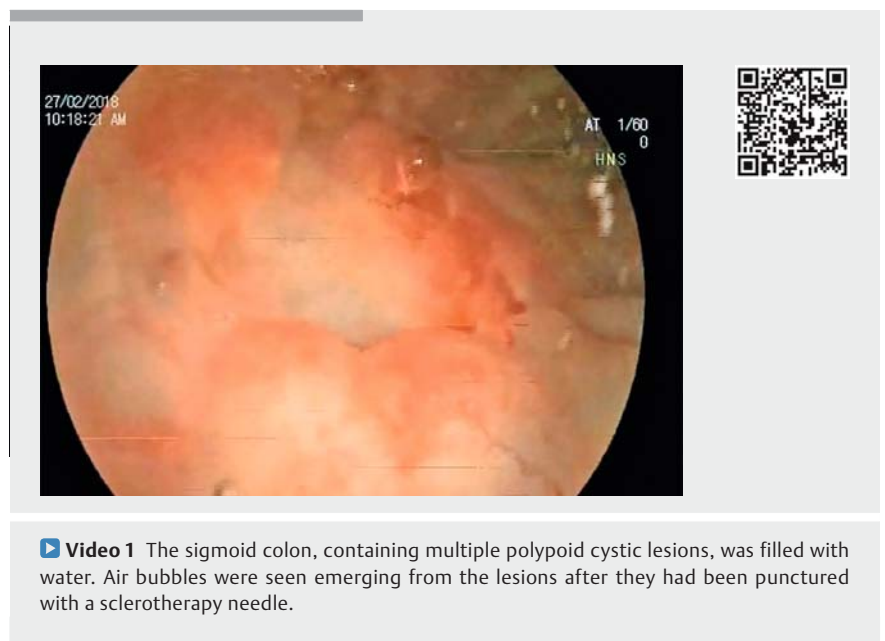Pneumatosis intestinalis is a rare disease, the clinic symptoms of which may be asymptomatic or serious enough to be a case of acute abdomen. Depending on different etiologies, it can occur in two forms – primary (idiopathic) or second-



► **Fig. 1** Multiple polypoid cystic lesions in the colon.



► **Fig. 2** Gas bubbles were seen emerging from the cystic lesion after it had been punctured.



► **Video 1** The sigmoid colon, containing multiple polypoid cystic lesions, was filled with water. Air bubbles were seen emerging from the lesions after they had been punctured with a sclerotherapy needle.

ary. Diagnosis is often made with radiologic or endoscopic imaging. We presented a case that was diagnosed endoscopically with water-immersion technique and puncture.

Endoscopy_UCTN_Code_CCL_1AD_2AJ

Competing interests

None

The authors

Mesut Akarsu, Yakup Duran, Zarni Htway
Division of Gastroenterology, Department of Internal Medicine, Dokuz Eylul Faculty of Medicine, Dokuz Eylul University Hospital, Izmir, Turkey

Corresponding author

Zarni Htway, MD

Division of Gastroenterology, Department of Internal Medicine, Dokuz Eylul Faculty of Medicine, Dokuz Eylul University Hospital, İnciraltı Mahallesi, Mithatpaşa Cd. İnciraltı yerleşkesi No: 1606, 35340 Narlıdere/Balçova/İzmir, Turkey
Fax: +90-232-4129797
zarnihtway@gmail.com

Bibliography

DOI <https://doi.org/10.1055/a-0640-2527>

Published online: 3.7.2018

Endoscopy 2018; 50: E267–E268

© Georg Thieme Verlag KG

Stuttgart · New York

ISSN 0013-726X

ENDOSCOPY E-VIDEOS

<https://eref.thieme.de/e-videos>



Endoscopy E-Videos is a free access online section, reporting on interesting cases and new techniques in gastroenterological endoscopy. All papers include a high quality video and all contributions are freely accessible online.

This section has its own submission website at <https://mc.manuscriptcentral.com/e-videos>