

Cerebral metastasis in breast cancer

Zerebrale Metastasierung beim Mammakarzinom



Authors

Volkmar Müller, Elena Laakmann, Astrid Grottke, Kerstin Riecke, Isabell Witzel



Affiliation

Klinik und Poliklinik für Gynäkologie, Universitätsklinikum Hamburg-Eppendorf, Hamburg

Key words

breast cancer, brain metastasis, radiotherapy, systemic therapy

Schlüsselwörter

Mammakarzinom, Hirnmetastasen, Strahlentherapie, systemische Therapie

Bibliography

DOI <https://doi.org/10.1055/a-0753-3504>

Senologie 2019; 16: 213–218

© Georg Thieme Verlag KG, Stuttgart · New York

ISSN 1611-6453

Correspondence

Prof. Dr. Volkmar Müller

Klinik und Poliklinik für Gynäkologie

Universitätsklinikum Hamburg-Eppendorf, Martinistraße 52, 20246 Hamburg

Tel.: ++ 49/40/7 41 05 25 10

Fax: ++ 49/40/7 41 04 00 70

v.mueller@uke.de



English version under:

<https://doi.org/10.1055/a-0753-3504>

ZUSAMMENFASSUNG

Die Inzidenz von Hirnmetastasen beim Mammakarzinom ist in den letzten Jahren stetig gestiegen. Hirnmetastasen stellen oft den limitierenden Faktor der Erkrankung dar, da das Überleben nach Auftreten einer Hirnmetastasierung meist nur wenige Monate beträgt. Neben der schlechten Prognose kommt es aufgrund kognitiver und neurologischer Defizite zu einer massiven Einschränkung der Lebensqualität. HER2-positive

oder triple-negative Karzinome entwickeln häufiger Hirnmetastasen. Untersuchungen zum Thema Hirnmetastasen wurden meist an Kohorten mit unterschiedlichen Primärtumoren durchgeführt. Um die Datenlage bei Patientinnen mit Mammakarzinom zu verbessern, wurde das Register „Brain Metastases in Breast Cancer (BMBC)“ zur Erfassung der deutschen Versorgungsrealität initiiert. Aufgrund der fehlenden spezifischen systemischen Therapieoptionen steht die lokale Therapie der Hirnmetastasen (Operation, stereotaktische Bestrahlung, Ganzhirnbestrahlung) zunächst im Vordergrund. Die lokale Therapie wird durch eine systemische Therapie ergänzt. Die Wahl der systemischen Therapie richtet sich v. a. nach der extrakraniellen Erkrankungssituation, da es derzeit praktisch keine Studiendaten speziell zur systemischen Therapie von Hirnmetastasen gibt. Erst in letzter Zeit werden Substanzen in Studien explizit bei Frauen mit Hirnmetastasen eines Mammakarzinoms untersucht.

ABSTRACT

The incidence of breast cancer brain metastases has risen steadily in recent years. Brain metastases are often the limiting factor of the disease, as survival is usually only a few months after brain metastasis occurs. Apart from the poor prognosis, cognitive and neurological deficits lead to a massive impairment of quality of life. HER2-positive or triple-negative cancers develop brain metastases more often. Studies on the subject of brain metastases were conducted mainly in cohorts with different primary tumours. To improve the available data on patients with breast cancer, the “Brain Metastases in Breast Cancer (BMBC)” registry was initiated to record the German care reality. Because of the lack of specific systemic treatment options, the main primary therapy of brain metastases is local (surgery, stereotactic radiation, whole-brain radiation). Local therapy is supplemented by systemic therapy. The choice of systemic therapy is guided especially by the extracranial disease situation, as there are practically no study data currently on the subject of systemic therapy of brain metastases specifically. Only very recently have drugs been investigated explicitly in women with breast cancer brain metastases.

Introduction

The improvement in the treatment options for patients with metastatic breast cancer has led to prolonged survival of many pa-

tients. With improved control of extracranial metastasis, about 30% of all patients with metastases develop brain metastases in the course of their disease. Brain metastases not only worsen the prognosis for the affected patients but also cause considerable

impairment of quality of life due to associated symptoms such as seizures or sensorimotor deficits. At present, unfortunately, there is little knowledge of the biological processes underlying cerebral metastasis or of specific treatment approaches. Against this background, current knowledge of the epidemiology, biology and treatment of cerebral metastasis in breast cancer is summarised below and new developments in clinical research are discussed.

Biological basis of cerebral metastasis

The development of distant metastases is a highly complex process in which the interaction between tumour cells and their environment, such as brain tissue, plays a crucial part [1]. Besides the genetic predisposition of the tumour cells, the cells' adaptation processes in the new environment are decisive for the development of metastases [2, 3]. Understanding these mechanisms is highly relevant for improving therapeutic and preventive strategies. Another important factor in the development and limited efficacy of treatment approaches for cerebral metastases is the blood-brain barrier. This is a highly selective physiological barrier between the blood system and the central nervous system, which represents a diffusion barrier for many drugs, thereby making systemic therapy of brain metastases more difficult [4–6].

Epidemiology and risk factors

Besides lung cancer, breast cancer is the most frequent cause of cerebral metastases. Brain metastases from these two tumours are diagnosed more often than primary brain tumours. An increasing incidence of cerebral metastases has been observed in recent years, probably because of an improvement in the systemic treatment of extracranial metastases. More patients now suffer cerebral metastasis before they die from their visceral metastases. This clinical observation reflects the inadequate effectiveness of current treatment approaches in controlling cerebral dissemination and growth. In addition, a greater number of subclinical brain metastases are probably diagnosed due to improvements in imaging using MRI, currently the standard method.

The risk factors for developing brain metastases are young age at disease onset, HER2-positive or triple-negative tumours, undifferentiated grade and/or positive nodal status [7]. With primary breast cancer, the cumulative incidence of brain metastases over 5 years is rather low at 1.7% in total and depends highly on the subtype with only 0.1% in luminal A, 3.3% in luminal B, 3.2% in luminal HER2, 3.7% for HER2-positive and 7.4% for triple-negative patients [8]. After neoadjuvant chemotherapy for primary breast cancer, the incidence of brain metastasis as the first site of metastasis was 3% (median follow-up 61 months) [9]. Here, too, patients with a HER2-positive or triple-negative primary tumour had an increased risk for brain metastases despite modern neoadjuvant therapy concepts. 4% of HER2-positive (34/809) and 6% of triple-negative patients (56/1008) developed brain metastases as the first site of metastasis. Other important risk factors identified for this group of patients were initially large tumours (cT3–4 vs.

cT1–2), positive nodal status and absence of complete pathological remission after chemotherapy.

At the metastatic disease stage, an incidence of cerebral metastases of up to 40% is reported in HER2-positive and triple-negative metastatic breast cancer [10, 11]. The subtype of the primary tumour also influences the distribution pattern of the brain metastasis. HER2-positive tumours appear to metastasise more often to the posterior cranial fossa (cerebellum) [12], whereas leptomeningeal involvement is overrepresented with hormone receptor-positive/HER2-negative tumours [13].

Prognosis

The median survival after the occurrence of brain metastases is under one year in the international literature published to date, and there are differences depending on the location and subtype of the primary tumour. Involvement of the meninges has the worst prognosis, with a median survival of only 3 months and one-year survival of 20% [13]. In an analysis of a Japanese cohort, patients with a triple-negative primary tumour have a worse prognosis than HER2-positive patients or patients with a HR+/HER2-negative primary tumour (median survival 5 months vs. 18 months vs. 9 months) [14]. Despite the overall poor prognosis, there are women who remain symptom-free for years after treatment of brain metastasis. Patients with an asymptomatic brain metastasis (e. g., incidental diagnosis on inclusion in a study) have a better prognosis. This fact has led to discussion of screening for brain metastases or even prophylactic radiation of the brain in high-risk groups. Studies to answer these questions are lacking or had to be stopped because of a lack of recruitment. National and international guidelines advise against screening as the benefit of early detection and treatment is rather doubtful [15, 16].

Clinical results from Germany: the BMBC registry

Most studies of brain metastases were conducted in cohorts with different primary tumours (lung, breast, malignant melanoma). Their results are therefore not necessarily applicable to the situation of women with breast cancer brain metastases. To obtain data on the reality of German care, the "Brain Metastases in Breast Cancer (BMBC)" registry was set up as a cooperation with the German Breast Group (GBG), the Gynaecological Oncology Working Group, Breast Committee (AGO-Mamma) and the Translational Research Committee (AGO-Trafo). Up to the summer of 2018, 149 German centres had registered for this study and 2315 patient datasets are available. The registry currently represents the largest cohort worldwide on this subject. In addition to clinical data collection, biopsies are collected for translational research projects. The first analysis of the registry was conducted on the basis of data from 1712 patients and published [17]. The median survival after the diagnosis of brain metastases was 7.4 months in the entire cohort and differed depending on the subtype of the primary tumour. Patients with HER2-positive breast cancer showed the longest survival (median 11.6 months), followed by

	Oxford		
	LoE	GR	AGO
Local therapy alone: SRS (≤ 4 cm) or FSRT	2b	B	++
WBRT + Boost (SRS, FSRT)	2a	B	++
WBRT alone *	2b	B	+
Hippocampal-sparing	2b	C	+/-

- Maximal number of metastases treated by SRS depends on localization, size and additional factors
- WBRT in addition to SRS/FSRT improves local control and symptoms, but has no survival benefit. Additional WBRT seems to impair neurocognitive function
- In case of limited number of brain metastases SRS/FSRT preferred

SRS = stereotactic radiosurgery (single session)

FSRT = fractionated stereotactic RT

WBRT = whole brain radiotherapy

* Patients with reduced general conditions and limited life expectancy

► **Fig. 1** Breast working group recommendation on local therapy of brain oligometastases. Depending on the size, number and location, stereotactic radiation is preferred to whole-brain radiation, which only prolongs progression-free but not overall survival. Source: slides from the recommendations of the breast cancer working group on the subject of CNS metastases.

HR+/HER2-negative breast cancer (median 5.9 months), and the shortest survival was observed for triple-negative patients (median 4.6 months). The one-year survival rate was 37.7%. Young age of disease onset in the patients when the brain metastases were diagnosed, triple-negative primary tumour, number of brain metastases (≥ 4) and poor general status (ECOG ≥ 2) were associated in the multivariate analysis with poorer overall survival. The overall poor survival rates in patients with breast cancer brain metastases emphasise the need to develop effective treatment strategies for patients with this tumour entity.

Local therapy

Since specific systemic therapy options are lacking, local therapy of brain metastases is of prime importance. Surgery has an important role. For instance, it is used for acute decompression of brain metastases with a space-occupying effect and, if necessary, for histological confirmation. Radiation only of the tumour bed is currently recommended after surgery in most cases. While subsequent whole-brain radiation reduces the recurrence rate, it does not prolong survival. In addition, whole-brain radiation has the disadvantage of causing more neurocognitive deficits than stereotactic radiation. Stereotactic radiation is becoming increasingly important as an alternative to surgery for single brain metastases or for a small number of them. It can also be combined with whole-brain radiation, which in this case merely increases local control without influencing survival [18, 19]. The maximum of 3 metastases previously cited as the limit for stereotactic radiation no longer applies today. In view of advances in radiation technology and the knowledge that whole-brain radiation for a limited

number of metastases can only prolong progression-free but not overall survival [20], the indication for stereotactic radiation is being extended steadily. Whole-brain radiation is the method of choice for brain metastases not suitable for stereotactic radiation. To minimise the neurocognitive side effects, hippocampus-sparing radiation is increasingly regarded as an option in whole-brain radiation. When recurrences occur after whole-brain radiation, further stereotactic radiation can be considered, and recurrences after stereotactic radiation or surgery can also be managed with further stereotactic radiation or whole-brain radiation. The current AGO recommendations are shown in ► **Fig. 1, 2**.

Glucocorticoids and anticonvulsants are used for symptomatic therapy. It is important to ensure that the glucocorticoids are tapered in patients following radiation and/or surgery as these should only be used in the short term while space-occupying oedema with symptoms is present. In practice, we see many women whose quality of life is further impaired by the long use of cortisone (Cushing syndrome). The current recommendations on systemic and symptomatic therapy of brain metastases is shown in ► **Fig. 3**.

Radiation can also be considered for local meningeal involvement, and intrathecal administration of methotrexate is otherwise a possibility. Single case reports and case studies have described intrathecal trastuzumab administration for underlying HER2-positive disease [21]. Because of the overall poor prognosis of the disease, treatment must be discussed individually with the patient and the option of purely symptomatic therapy should be offered.

	Oxford		
	LoE	GR	AGO
▪ WBRT (supportive steroids*)	1a	A	++
▪ Hippocampal-sparing radiotherapy	2b	C	+/-
▪ Corticosteroids alone*	3a	B	+/-
▪ Radiochemotherapy for control intracerebral	3b	C	-
▪ WBRT in case of recurrence**	4	C	+/-

SRS = stereotactic radiosurgery
 FSRT = fractionated stereotactic radiotherapy
 WBRT = whole brain radiotherapy

* adapted to symptoms
 ** can be discussed depending on the time-interval from first radiation, prior dose and localization if local therapy (surgery, SRS, FSRT) is not indicated and / od possible

► **Fig. 2** Breast working group recommendation on local therapy of multiple brain metastases when stereotactic radiation is not possible. Whole-brain radiation is still the method of choice. Source: slides from the recommendations of the breast cancer working group on the subject of CNS metastases.

	Oxford		
	LoE	GR	AGO
▪ Continuation of the actual systemic therapy if first diagnosis of brain metastases and stable extracranial disease	2c	C	+
▪ Lapatinib + Capecitabine as initial treatment (HER2 pos. disease)	1b	B	+/-
▪ Chemotherapy alone as primary treatment	3	D	-
▪ Anticonvulsants only if symptoms of seizures	3	C	+
▪ Glucocorticoids only when symptoms and / or mass effect	3	C	++

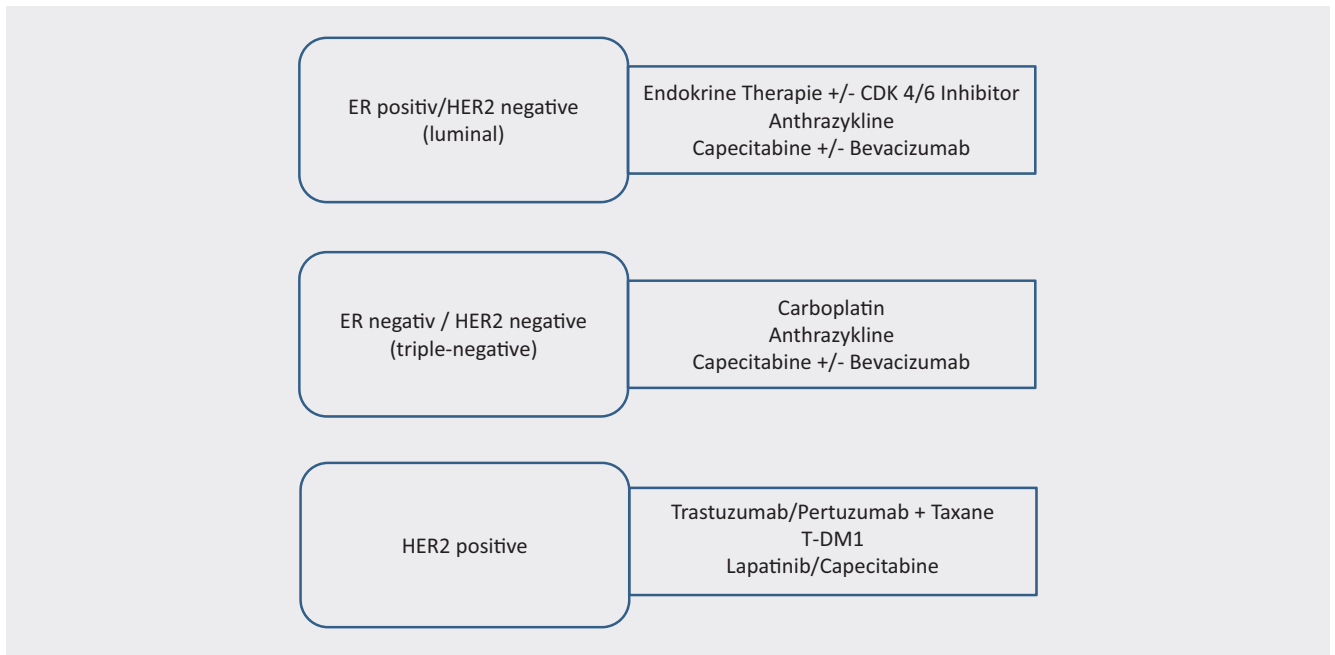
* In addition to local therapy

► **Fig. 3** Breast working group recommendation on systemic and symptomatic therapy of brain metastases. Adjust current systemic treatment regimens depending on extracranial metastasis, general status and previous therapies or continue if appropriate. Consider symptomatic therapy with glucocorticoids and anticonvulsants. Source: slides from the recommendations of the breast cancer working group on the subject of CNS metastases.

Systemic therapy

No drugs are as yet licensed especially for the treatment of brain metastases of solid tumours including breast cancer. Nevertheless, there is a series of smaller, prospective and usually unrandomised studies and of case reports that showed activity of various drugs in the brain. In addition, it has been shown that giving systemic therapy after the diagnosis of brain metastasis is associated with a better prognosis (median survival with systemic therapy 13 vs. 3 months without systemic therapy) [22]. Depending on the patient's general status, extracranial metastases and previous therapies, different drugs can be chosen according to the subtype of the primary tumour. ► **Fig. 4** lists examples but does not claim to be complete. After women with brain metastases were excluded from clinical studies for many years, studies increasingly allow women with brain metastases explicitly or analyse the occurrence of brain metastases. In the case of HER2-positive breast cancer, prolonged progression-free survival was shown for women with

brain metastases with pertuzumab and trastuzumab dual blockade in the Cleopatra study [23]. In the Emilia study of T-DM1, 10% of the patients had stable and asymptomatic brain metastases on inclusion in the study. Their survival was markedly longer in the T-DM1 arm than in the capecitabine/lapatinib arm [24]. Moreover, there are small case series of patients in whom regression of existing brain metastases due to the antibody T-DM1 was described [25]. The tyrosine kinase inhibitor ONT-380 showed a good response in a phase I study using the combination of T-DM1 and ONT-380 in 57 patients with brain metastases [26] and is currently being investigated in a phase II study ("HER2-Climb") in combination with capecitabine and trastuzumab with/without ONT-380 including in patients with breast cancer brain metastases. In patients who were not candidates for HER2-directed therapy, a survival advantage was shown in the BEACON study for the topoisomerase-I inhibitor etirinotecan pegol in the subgroup of patients with brain metastases (n = 67) compared with the investigator's treatment of choice [27]. In the phase III



► **Fig. 4** Drugs available and under development with a potential effect on cerebral metastases.

“ATTAIN” study, which is currently underway, patients with brain metastases of breast cancer were treated with etirinotecan pegol. There is some evidence from clinical case series for the efficacy of the VEGF antibody bevacizumab in patients with breast cancer [28–30]. CDK 4/6 inhibitors also show effectiveness in the brain. In a phase II study, a clinical benefit rate of 17% in patients with brain metastases and HR-positive/HER2-negative breast cancer was observed with abemaciclib [31]. At ASCO 2018, the OlympiaD study reported on a group of women with BRCA1/2 mutation and cerebral metastases of breast cancer who had prolonged progression-free survival on therapy with PARP inhibitors compared with the investigator’s therapy of choice.

Conclusion

Brain metastases in patients with breast cancer currently often represent the limiting factor of the treatment and the disease due to the poor prognosis and limitation of quality of life. Advances in research and therapy are urgently needed. Different drugs as systemic therapy approaches are currently being investigated in studies.

Conflicts of interest

VM: fees for research, lectures and consultancy work: Amgen, AstraZeneca, Celgene, Daiichi-Sankyo, Eisai, Pfizer, Pierre-Fabre, Novartis, Nektar, Roche, Teva, Janssen-Cilag, Genomic Health.

IW: grant for research, consultancy work, lecture fee: Daiichi-Sankyo, MSD, Pierre Fabre Pharma, Roche, Novartis

EL: none, KR: none, AG: none

References

- [1] Quail DF, Joyce JA. Microenvironmental regulation of tumor progression and metastasis. *Nat Med* 2013; 19: 1423–1437. doi:10.1038/nm.3394
- [2] Soni A, Ren Z, Hameed O et al. Breast cancer subtypes predispose the site of distant metastases. *Am J Clin Pathol* 2015; 143: 471–478. doi:10.1309/ajcpsy05fsv3upexs
- [3] Kang Y, Pantel K. Tumor cell dissemination: emerging biological insights from animal models and cancer patients. *Cancer Cell* 2013; 23: 573–581. doi:10.1016/j.ccr.2013.04.017
- [4] Pedrosa R, Mustafa DA, Soffiatti R et al. Breast cancer brain metastasis: molecular mechanisms and directions for treatment. *Neuro Oncol* 2018. doi:10.1093/neuonc/noy044
- [5] Zhang C, Yu D. Microenvironment determinants of brain metastasis. *Cell Biosci* 2011; 1: 8. doi:10.1186/2045-3701-1-8
- [6] Reese TS, Karnovsky MJ. Fine structural localization of a blood-brain barrier to exogenous peroxidase. *J Cell Biol* 1967; 34: 207–217
- [7] Witzel I, Oliveira-Ferrer L, Pantel K et al. Breast cancer brain metastases: biology and new clinical perspectives. *Breast Cancer Res* 2016; 18: 8. doi:10.1186/s13058-015-0665-1
- [8] Arvold ND, Oh KS, Niemierko A et al. Brain metastases after breast-conserving therapy and systemic therapy: incidence and characteristics by biologic subtype. *Breast Cancer Res Treat* 2012; 136: 153–160. doi:10.1007/s10549-012-2243-x
- [9] Laakmann E, Witzel I, Fasching PA et al. Hirnmetastasierung bei Patientinnen mit Mammakarzinom nach einer neoadjuvanten Chemotherapie. *Senologie – Zeitschrift für Mammadiagnostik und -therapie* 2018; 15 (2): e30. doi: 10.1055/s-0038-1651754
- [10] Witzel I, Kantelhardt E, Milde-Langosch K et al. Management of patients with brain metastases receiving trastuzumab treatment for metastatic breast cancer. *Onkologie* 2011; 34: 304–308. doi:10.1159/000328679
- [11] Yau T, Swanton C, Chua S et al. Incidence, pattern and timing of brain metastases among patients with advanced breast cancer treated with trastuzumab. *Acta Oncol* 2006; 45: 196–201. doi:10.1080/02841860500486630

- [12] Laakmann E, Witzel I, Scriba V et al. Radiological Patterns of Brain Metastases in Breast Cancer Patients: A Subproject of the German Brain Metastases in Breast Cancer (BMBC) Registry. *Int J Mol Sci* 2016; 17 doi:10.3390/ijms17101615
- [13] Morikawa A, Jordan L, Rozner R et al. Characteristics and Outcomes of Patients With Breast Cancer With Leptomeningeal Metastasis. *Clin Breast Cancer* 2017; 17: 23–28. doi:10.1016/j.clbc.2016.07.002
- [14] Niikura N, Hayashi N, Masuda N et al. Treatment outcomes and prognostic factors for patients with brain metastases from breast cancer of each subtype: a multicenter retrospective analysis. *Breast Cancer Res Treat* 2014; 147: 103–112. doi:10.1007/s10549-014-3090-8
- [15] Thill M, Liedtke C, Müller V et al. AGO Recommendations for the Diagnosis and Treatment of Patients with Advanced and Metastatic Breast Cancer: Update 2018. *Breast Care* 2018; 13: 209–215. doi: 10.1159/000489331
- [16] Harbeck N, Luftner D, Marschner N et al. ABC4 Consensus: Assessment by a German Group of Experts. *Breast Care (Basel)* 2018; 13: 48–58. doi:10.1159/000486722
- [17] Witzel I. Treatment and outcomes of patients in the Brain Metastases in Breast Cancer Network Registry. *European Journal of Cancer* 2018; 102: 1–9
- [18] Brown PD, Ballman KV, Cerhan JH et al. Postoperative stereotactic radiosurgery compared with whole brain radiotherapy for resected metastatic brain disease (NCCTG N107C/CEC.3): a multicentre, randomised, controlled, phase 3 trial. *Lancet Oncol* 2017; 18: 1049–1060. doi:10.1016/s1470-2045(17)30441-2
- [19] Kocher M, Soffiotti R, Abacioglu U et al. Adjuvant whole-brain radiotherapy versus observation after radiosurgery or surgical resection of one to three cerebral metastases: results of the EORTC 22952-26001 study. *J Clin Oncol* 2011; 29: 134–141. doi:10.1200/JCO.2010.30.1655
- [20] Brown PD, Jaeckle K, Ballman KV et al. Effect of Radiosurgery Alone vs Radiosurgery With Whole Brain Radiation Therapy on Cognitive Function in Patients With 1 to 3 Brain Metastases: A Randomized Clinical Trial. *Jama* 2016; 316: 401–409. doi:10.1001/jama.2016.9839
- [21] Stemmler HJ, Mengele K, Schmitt M et al. Intrathecal trastuzumab (Herceptin) and methotrexate for meningeal carcinomatosis in HER2-overexpressing metastatic breast cancer: a case report. *Anticancer Drugs* 2008; 19: 832–836
- [22] Niwinska A, Murawska M, Pogoda K. Breast cancer brain metastases: differences in survival depending on biological subtype, RPA RTOG prognostic class and systemic treatment after whole-brain radiotherapy (WBRT). *Ann Oncol* 2010; 21: 942–948. doi:10.1093/annonc/mdp407
- [23] Swain SM, Baselga J, Miles D et al. Incidence of central nervous system metastases in patients with HER2-positive metastatic breast cancer treated with pertuzumab, trastuzumab, and docetaxel: results from the randomized phase III study CLEOPATRA. *Ann Oncol* 2014; 25: 1116–1121. doi:10.1093/annonc/mdu133
- [24] Krop IE, Lin NU, Blackwell K et al. Trastuzumab emtansine (T-DM1) versus lapatinib plus capecitabine in patients with HER2-positive metastatic breast cancer and central nervous system metastases: a retrospective, exploratory analysis in EMILIA. *Ann Oncol* 2015; 26: 113–119. doi:10.1093/annonc/mdu486
- [25] Bartsch R, Berghoff AS, Vogl U et al. Activity of T-DM1 in Her2-positive breast cancer brain metastases. *Clin Exp Metastasis* 2015; 32: 729–737. doi:10.1007/s10585-015-9740-3
- [26] Borges VF, Ferrario C, Aucoin N et al. Tucatinib Combined With Ado-Trastuzumab Emtansine in Advanced ERBB2 / HER2-Positive Metastatic Breast Cancer: A Phase 1b Clinical Trial. *JAMA oncology* 2018. doi:10.1001/jamaoncol.2018.1812
- [27] Cortes J, Rugo HS, Awada A et al. Prolonged survival in patients with breast cancer and a history of brain metastases: results of a preplanned subgroup analysis from the randomized phase III BEACON trial. *Breast Cancer Res Treat* 2017; 165: 329–341. doi:10.1007/s10549-017-4304-7
- [28] Yamamoto D, Iwase S, Tsubota Y et al. Bevacizumab in the treatment of five patients with breast cancer and brain metastases: Japan Breast Cancer Research Network-07 trial. *OncoTargets and therapy* 2012; 5: 185–189. doi:10.2147/ott.s36515
- [29] Lu YS, Chen TW, Lin CH et al. Bevacizumab Preconditioning Followed by Etoposide and Cisplatin Is Highly Effective in Treating Brain Metastases of Breast Cancer Progressing from Whole-Brain Radiotherapy. *Clin Cancer Res* 2015. doi:10.1158/1078-0432.ccr-14-2075
- [30] Chen BB, Lu YS, Lin CH et al. A pilot study to determine the timing and effect of bevacizumab on vascular normalization of metastatic brain tumors in breast cancer. *BMC Cancer* 2016; 16: 466. doi:10.1186/s12885-016-2494-8
- [31] Sara MTolaney NUL, Donald Thornton, Suzanne Klise et al. Abemaciclib for the treatment of brain metastases (BM) secondary to hormone receptor positive (HR+), HER2 negative breast cancer. *ASCO* 2017. (abs 1019)