

Doppler Sonography during Pregnancy – DEGUM Quality Standards and Clinical Applications (Part 1)

Dopplersonografie in der Schwangerschaft – Qualitätsanforderungen der DEGUM und klinischer Einsatz (Teil 1)

Authors

R. Faber¹, Kai-Sven Heling², Horst Steiner³, Ulrich Gembruch⁴

Affiliations

- 1 Center of Prenatal Medicine, Leipzig, Germany
- 2 Praxis, prenatal diagnosis and human genetics, Berlin, Germany
- 3 Praxis prenatal medicine, Salzburg, Austria
- 4 Obstetrics and Prenatal Medicine, University-Hospital, Bonn, Germany

Key words

uterine arteries, fetal vessels, guideline, Doppler analysis

received 30.03.2018

accepted 12.11.2018

Bibliography

DOI <https://doi.org/10.1055/a-0800-8596>

Published online: March 20, 2019

Ultraschall in Med 2019; 40: 319–325

© Georg Thieme Verlag KG, Stuttgart · New York

ISSN 0172-4614

Correspondence

Prof. R. Faber

Leipzig, Center of Prenatal Medicine, Johannisplatz 1,

04103 Leipzig, Germany

Tel.: ++49/3 41/2 17 80 75

Fax: ++49/3 41/9 93 95 07

faber@praenatalmedizin-leipzig.de

ABSTRACT

Doppler sonography is widely established in prenatal medicine and obstetrics and is commonly used in screening for aneuploidy and preeclampsia during the first trimester. More

importantly, during the 2nd and 3rd trimester, it is used in the assessment of fetal health as well as the surveillance of underlying fetal conditions such as IUGR and anemia. Correct use of the method is vital for correct data interpretation and the inferred clinical decision process. Therefore, we aim to provide all users of doppler sonography with a guide for meeting the required quality standards. These quality standards will further be the basis of DEGUM-certified training courses. In the first part, we will introduce the technical principles of the method and potential error sources, vascular disciplines to which the method can be applied, analysis of the spectral curves, patient safety and the needed requirements for successful certification.

ZUSAMMENFASSUNG

Der Einsatz der Methode der Dopplersonografie in der Pränatal- und Geburtsmedizin hat sich allgemein durchgesetzt. Sie wird beim Screening auf Aneuploidie und Präeklampsie im 1. Trimester zunehmend angewendet, aber vor allem zur fetalen Zustandsdiagnostik bzw. Überwachung gefährdeter Feten bei IUGR, Anämie und anderen Erkrankungen im 2. und 3. Trimester eingesetzt. Die korrekte Anwendung der Methode der Dopplersonografie ist die Voraussetzung für die richtige Interpretation der Ergebnisse und daraus abgeleiteter klinischer Entscheidungen. Diese Qualitätsanforderungen sollen hiermit für alle Anwender formuliert werden und gleichzeitig als Grundlage für die durch die DEGUM zertifizierten Kurse dienen. Im 1. Teil werden die allgemeinen technischen Grundlagen, Gefäßgebiete, Auswertung der Spektralkurven, Fehlerquellen, Patientensicherheit und die Voraussetzungen für eine erfolgreiche Zertifizierung behandelt.

Part 1

Objective

The use of Doppler sonography in prenatal medicine and obstetrics to analyze flow rates in different maternal and fetal blood vessels has become extremely important. This is largely the result of extensive worldwide studies and the application of this knowl-

edge in daily clinical practice thanks to the DEGUM-certified courses offered over the last 25 years. Doppler sonography is used for screening, assessing fetal health, and monitoring complicated pregnancies, and serves as a tool for making obstetric decisions. It has a broad range of uses in hospitals and physician's offices during all three trimesters [1–5]. As in all areas of medicine, correct application of the method is a prerequisite for ensuring good quality of resulting clinical decisions [1, 4]. The first step

in quality management is to formulate general (Part 1) and special (Part 2) standards for the use of Doppler sonography in conjunction with the DEGUM recommendations.

Technical Principles and Methods

Equipment

The ultrasound device used for Doppler sonography in obstetrics provides color Doppler and spectral Doppler ultrasound images as well as B-mode images and is approved for use in obstetrical examination.

Technical Principles and Methods

Setting: Pulsed Doppler sonography (pulsed wave, PW-Doppler) is used for imaging in pregnancy. The color Doppler signal makes it possible to locate the vessel on the B-mode image and to position the Doppler window (sample volume) more quickly and easily. The Doppler signal can be derived in duplex or triplex mode, but duplex mode is preferable because the quality of the resulting Doppler sonogram (Doppler curve, spectral curve, envelope, Doppler effect curve) is better and the energy load is lower.

The default setting should emphasize the Doppler sonogram and not the B-mode image (2/3 vs. 1/3) (► Fig. 1).

Angle Based on the Doppler equation ($fd = 2fo \cdot \cos \alpha \cdot v/c$), the following parameters are significant. The insonation angle (α) in the direction of the blood flow should be as small as possible to achieve the highest Doppler shift frequencies (fd). The angle setting helps to adjust the insonation angle appropriately. When measuring absolute velocities, the insonation angle should be as close to 0° as possible; at angles $\geq 30^\circ$, velocity measurements are subject to greater errors because of the cosine function of the Doppler equation.

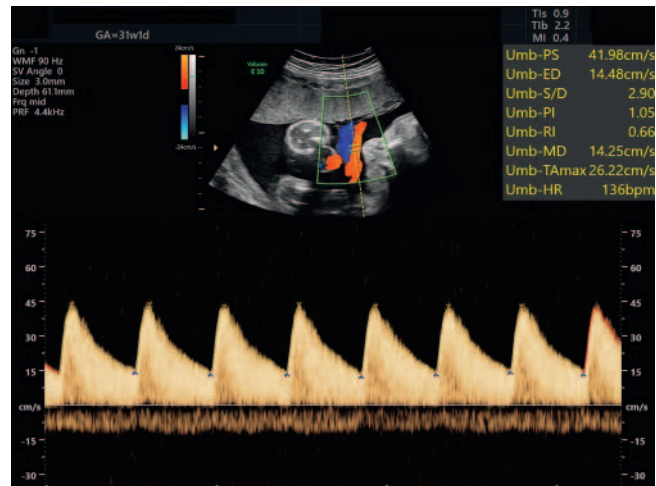
Flow rate An average flow rate should be selected when plotting the Doppler curve so that ideally 3 to 6 cycles are shown when measuring fetal and maternal vessels. This makes it possible to measure the Doppler curves exactly and to assess their uniformity.

Gain The gain should be selected so that the signal can be clearly differentiated from background noise and the Doppler spectrum is distinctly displayed against the background. In addition, the intensity of the individual Doppler shift frequencies within the spectrum should be visible.

High-pass filter The movements of the vessel walls produce low-frequency interference signals that a high-pass filter can suppress. It should be set to ≤ 60 Hz to ensure that low end-diastolic Doppler shift frequencies are recorded.

Display of the Doppler signal The recorded Doppler sonogram represents the measured frequency shift (Doppler shift frequency). The devices report either frequencies (Hz) or velocities (cm/s). The latter assumes an optimal insonation angle of 0° or 180° . Blood flow towards the transducer produces positive Doppler shift frequencies, while blood flow away from the transducer results in negative frequencies. In color Doppler sonography, these flows are coded red and blue, respectively.

Aliasing If the Doppler shift frequency exceeds the Nyquist limit (maximum pulse repetition frequency (PRF)/2), the higher



► Fig. 1 Biphasic spectral Doppler curve of a free loop of the umbilical artery in triplex mode in the 32nd gestational week with normal perfusion (high end-diastolic flow).

frequencies erroneously appear in the reverse channel (aliasing effect). There are multiple ways to correct aliasing. The first approach is to increase the PRF and/or adjust the baseline. If that does not work, the transducer can be used at a lower frequency in duplex mode because it allows a higher PRF. Using a CW Doppler transducer is yet another alternative.

Doppler window (sample volume) In pulsed Doppler sonography, the measurement site is precisely defined by the positioning of the sample volume. The size of the sample volume can vary depending on the case and is normally 2 – 3 mm. When measuring blood flow volume, the sonographer must ensure that the sample volume captures the entire cross-section of the vessel.

Transducer frequency Transducer frequency is differentiated into B-mode and Doppler mode. Higher frequencies in Doppler mode lead to higher Doppler shift frequencies at the same blood flow velocities. Higher Doppler frequencies are therefore better at capturing lower velocities.

Continuous wave (CW Doppler) In continuous wave Doppler, all Doppler shift frequencies in the overall ultrasound beam are recorded. It therefore is not possible to precisely define a measurement range. However, the aliasing effect poses no limitations, even permitting measurement of extremely high velocities.

Vascular areas

Both arterial as well as venous vessels can be examined via Doppler sonography, whereby maternal-placental, fetoplacental, and fetal vessels are differentiated (► Table 1, 2).

The arterial vessels exhibit a biphasic, pulsatile flow pattern with a systolic and a diastolic phase (► Fig. 1).

The velocities vary between the arteries and increase over the course of the pregnancy. The pulsatility of the blood flow pattern also depends on gestational age. Pathological changes are accompanied by an increase in pulsatility. Pulsatility decreases only in the cerebral arteries.

Depending on the cardiac cycle, there is a triphasic flow pattern in the veins surrounding the heart, with a systolic and early

► **Table 1** Maternal and fetal arteries and downstream vascular areas.

uterine arteries	uterus and placenta (maternal)
umbilical artery	placenta (fetal)
middle cerebral artery	brain
renal artery	kidney
descending thoracic aorta	trunk, abdominal organs, lower extremities, placenta
pulmonary arteries	lungs

► **Table 2** Fetal veins and their major resistive components.

ductus venosus	right arterial pressure
umbilical vein	right arterial pressure
inferior vena cava	right arterial pressure
hepatic veins	right arterial pressure
superior vena cava	right arterial pressure
pulmonary veins	left arterial pressure

diastolic peak as well as a nadir during the late diastolic atrial contraction (► **Fig. 2**).

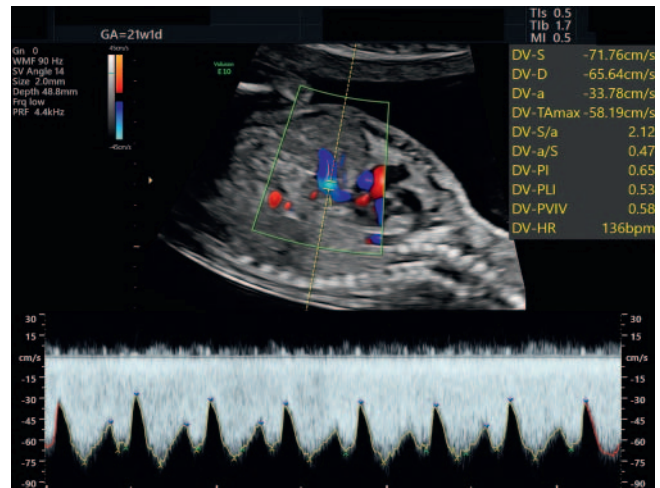
In the umbilical vein, the blood flow is uniform and hence monophasic (► **Fig. 3**). Pathological changes are accompanied by an increase in pulsatility in the veins near the heart. In the umbilical vein, the blood flow then becomes pulsatile.

Reference curves based on gestational age should be consulted to evaluate pulsatility and velocities.

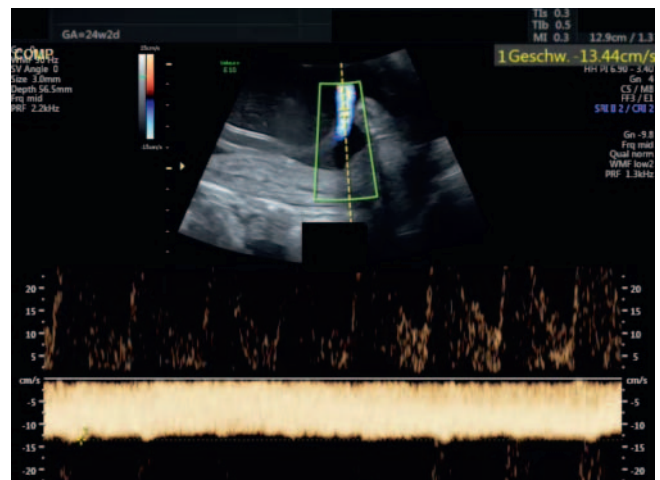
In practice, the following vessels are of particular importance:

Uterine arteries The blood flow in the uterine arteries is largely determined by the downstream maternal-placental vasculature, especially the shape of the spiral arteries. Owing to the expansion of the vascular lumina caused by the trophoblast invasion, the flow resistance drops and the pulsatility decreases as an expression of altered impedance. Accordingly, the pulsatility in the uterine arteries falls in the first and early second trimester [6]. An early diastolic notch is also an expression of increased impedance. A notch arises from a pulse wave reflection when vascular continuity changes; it then disappears when the spiral arteries are fully dilated. It is found bilaterally at the end of the first trimester (► **Fig. 4**) in approximately 50% of pregnant women but almost always disappears by the 24th week (► **Fig. 5, 6**). Bilateral notching is therefore detectable after the 24th week of pregnancy only in fewer than 5% of normal pregnancies [6–9]. The further from the placenta, the higher the pulsatility. It is measured near the cervix in the respective main branch of the right and left uterine arteries in the absence of contractions.

Umbilical artery The blood flow in the umbilical arteries is largely determined by the downstream fetoplacental vasculature, the number and width of the small arteries, arterioles, and especially the sinusoidal end segments of the placental villi. It therefore reflects the degree of villi maturation, which persists



► **Fig. 2** Triphasic spectral Doppler curve of the ductus venosus in the 22nd gestational week with exact position of the sample volume in the vessel (aliasing) and normal perfusion.

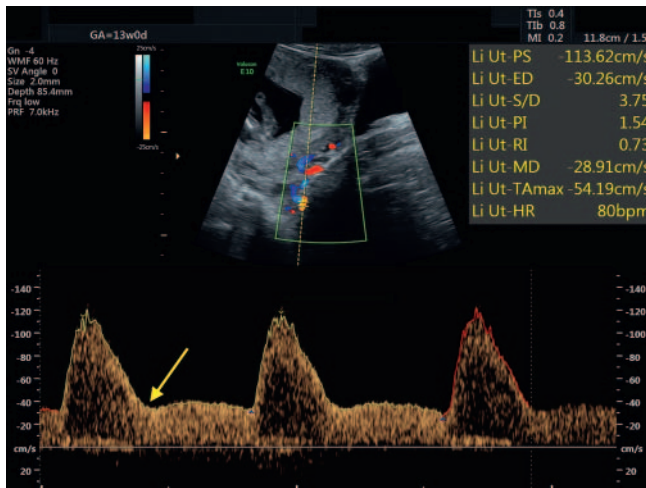


► **Fig. 3** Monophasic spectral Doppler curve of a free loop of the umbilical vein in the 25th gestational week with low velocity; the spectral curve of the umbilical artery is indicated in the reverse channel.

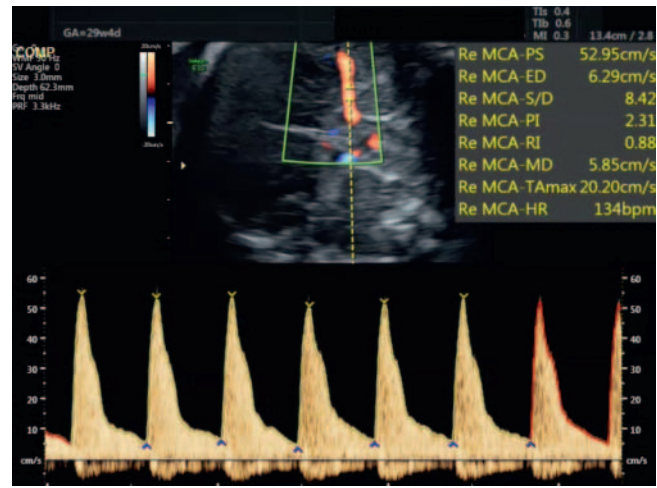
throughout the entire course of the pregnancy. Accordingly, the pulsatility in the umbilical arteries decreases over the course of the pregnancy [10–14]. Within the umbilical cord, the pulsatility decreases in the direction of the placental insertion [13]. It is therefore recommended to measure the middle section of the free umbilical cord (► **Fig. 1**).

Middle cerebral artery (MCA) The pulsatility of the middle cerebral artery is qualitatively assessed during Doppler sonography examination. Its pulsatility is largely determined by the flow resistance of the downstream cerebral vasculature. Pulsatility increases slightly during pregnancy and drops again around the 34th gestational week [10, 15–17].

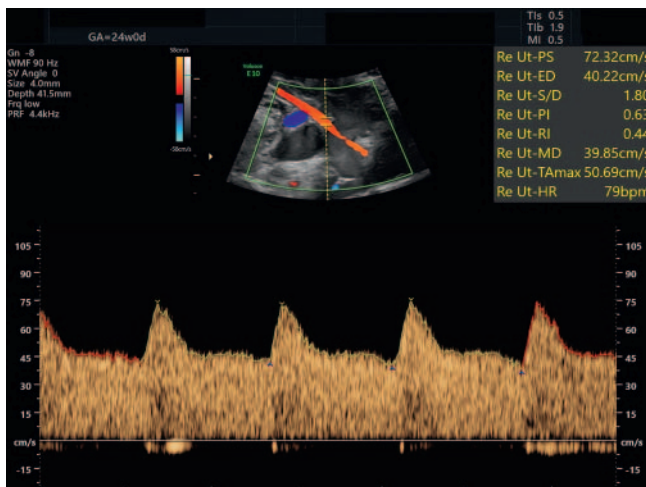
A quantitative measurement of the peak systolic velocity (PSV or Vmax) is performed in the MCA to diagnose anemia [18]. In this context, particular quality standards apply: Color Doppler sono-



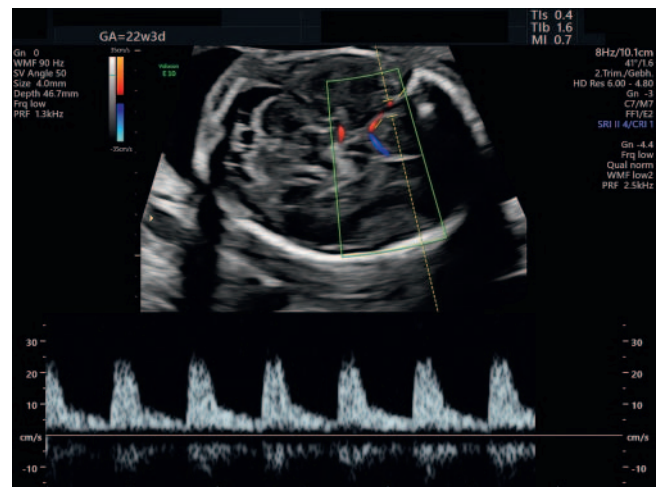
► **Fig. 4** Spectral Doppler of the left uterine artery in the first trimester with notching (yellow arrow) still evident but with normal perfusion.



► **Fig. 6** Spectral Doppler of the middle cerebral artery in the third trimester with exact position of the sample volume and normal perfusion.



► **Fig. 5** Spectral Doppler of the right uterine artery in the second trimester with high diastolic flow, normal perfusion.



► **Fig. 7** Spectral Doppler of the middle cerebral artery with visualization of the vessel and placement of the sample volume.

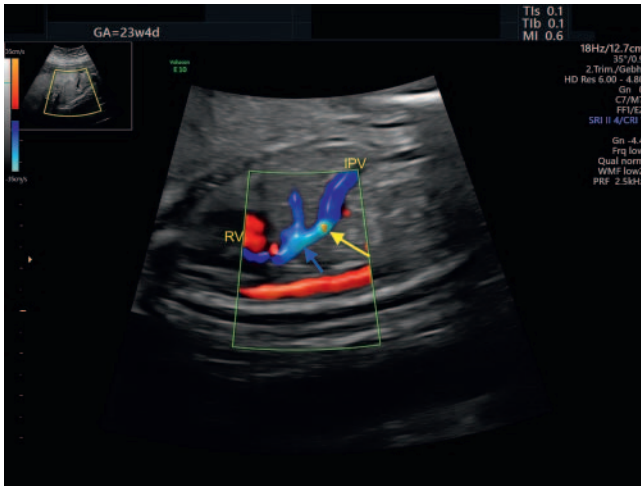
graphy is used to locate the circle of Willis in the transverse cerebral section. It is best to visualize the full length, rather than specific points or short stretches, of the MCA near the transducer. This also ensures that the azimuthal angle is close to 0° . The image is enlarged to nearly maximum such that the MCA takes up more than 50% of the image. The Doppler signal is derived from a 1–3 mm sample volume 1.0–1.5 cm from the branch of the MCA from the circle of Willis or the internal carotid artery. The insonation angle should be 0° if possible; an insonation angle $<15^\circ$ is tolerable (► **Fig. 6**), while insonation angles $\geq 30^\circ$ cannot be used [19, 20], because major errors in absolute velocity measurement are unavoidable even when the angle is adjusted (► **Fig. 7**). The peak systolic velocity (PSV), i.e., the highest point of the Doppler sonogram, is measured. Measurements should be performed three times; the highest PSV is evaluated [19, 20]. If the position is unfavorable, the measurement can also be performed in the MCA of the cerebral hemisphere remote from

the transducer [19]. Phases of fetal heart rate acceleration should be avoided particularly in the third trimester, because the PSV of the MCA decreases at that time [21].

Descending aorta The fetal aorta is no longer measured because it provides no additional information compared with the above-named vessels and also presents methodological difficulties. In particular, the pulsatility depends on the measurement site, and the insonation angle is almost always unfavorably large due to the position. These conditions adversely affect the reproducibility of this measurement.

Pulmonary arteries Measurements of the pulmonary arteries are reserved for special issues, especially for evaluating the pulmonary arterial vascular bed to predict pulmonary hypoplasia or pulmonary hypertension.

Ductus venosus The pulsatility of the ductus venosus (DV), like other systemic veins near the heart, is largely determined by fluctuations in central venous and right arterial pressure. It conti-



► **Fig. 8** Correct color Doppler sonography settings for measuring the ductus venosus with display of the following structures (from right to left): left portal vein (IPV), DV with aliasing (yellow arrow), confluence of DV and liver vein (blue arrow), right atrium (RV).

nally decreases over the course of the pregnancy [22, 23]. After the first trimester, there is an antegrade flow in all phases. The DV differs from other veins near the heart in that its blood flow velocities are significantly higher, which makes it easy to identify with color Doppler owing to the aliasing effect (► **Fig. 8**). The measurement is performed in a longitudinal parasagittal section, with the full length of the DV being visualized at a minimal insonation angle (<30°). The sample volume should not exceed 2 mm to avoid recording the pulsatile flow pattern with the negative a-wave of the adjacent liver veins (► **Fig. 2**).

Umbilical vein The blood flow pattern of the umbilical vein is determined in the free umbilical cord. It is monophasic with a consistent antegrade flow, like in the intra-abdominal section of the umbilicus vein (► **Fig. 3**). Only a marked increase in the pulsatility in the ductus venosus will result in flow patterns in the umbilical vein with biphasic, or rarely triphasic, pulsatility [24].

Pulmonary veins The pulmonary venous blood flow pattern is best derived in the vein near the transducer close to where the vein enters the left atrium.

The pulsatility in the pulmonary veins reflects the left atrial pressure, which equals the right atrial pressure when the foramen ovale is open. Therefore, the pulsatility in the pulmonary veins usually changes in line with that of the systemic veins. The blood flow pattern is triphasic with a constant positive flow [25, 26]. Regardless of the right atrial pressure, only severe diastolic dysfunction of the left ventricle will result in a poor or absent antegrade or retrograde flow during left atrial systole, which is particularly pronounced in the case of a highly restrictive or intact atrial septum [27, 28].

Evaluating the Doppler Sonogram

The Doppler curve can be evaluated qualitatively and quantitatively.

Qualitative evaluation means assessing the shape (e. g., retrograde flow or notching) and pulsatility of the Doppler curve.

► **Table 3** Indices for arterial and venous vessels

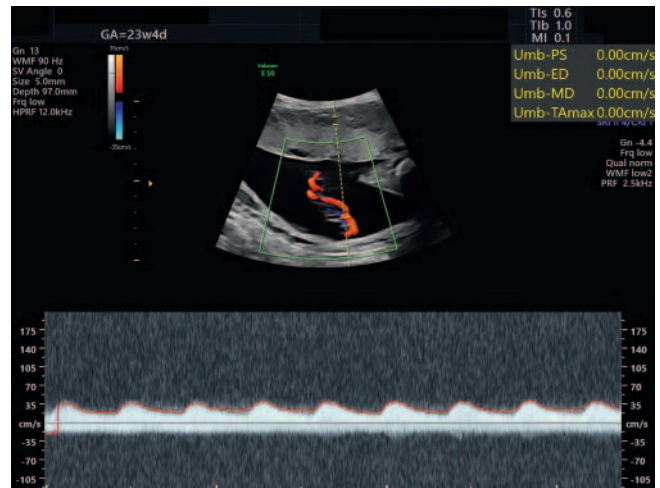
$$RI = (S-D)/S$$

$$PI = (S-D)/TAm_{ax}$$

$$PIV = (S-a)/D$$

$$PVIV = (S-a)/TAm_{ax}$$

RI = resistance index, PI = pulsatility index, PIV = pulsatility index for veins, PVIV = peak velocity index for veins, TAm_{ax} = average velocity of the envelope or maximum velocities of a cycle.



► **Fig. 9** Inadequate spectral Doppler of the umbilical artery, preventing measurement of the indices (PRF too high, gain too high).

Pulsatility is characterized by the impedance indices, the resistance index (RI), and pulsatility index (PI) (► **Table 3**). In general, the PI is favored because it contains more information about the blood flow. To qualitatively assess the uterine arteries, the average of the left and right PIs is used.

Quantitative evaluation involves recording absolute blood flow velocities and is reserved for special indications such as anemia diagnostics in the middle cerebral artery.

Most modern devices can analyze the Doppler curve via automatic curve tracing. This requires flawless recording of the Doppler curve (see ► **Fig. 1, 2, 6**). If the curve is not perfect, the measurement can be done manually. But it is better to repeat the measurement (► **Fig. 9**).

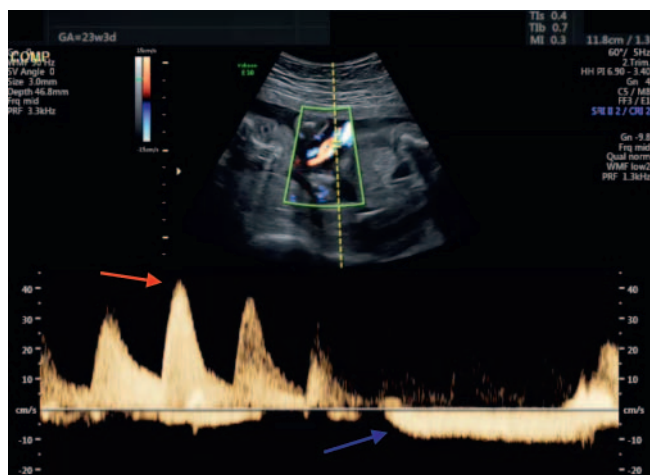
Sources of error

As with every examiner-dependent method, a number of errors are possible in Doppler sonography. Most errors occur when the above-described measurement techniques are not observed.

The following possible errors should also be kept in mind:

Uterine arteries – Measurement during a uterine contraction results in a decrease in the diastolic blood flow or even flow reversal, measurement of smaller uterine vessels (arcuate arteries);

Umbilical artery – Measurement during fetal body or respiratory movements (► **Fig. 10**);



► **Fig. 10** Spectral Doppler curves of the umbilical artery (red arrow) and umbilical vein (blue arrow) during fetal body movements.

Middle cerebral artery – Too much transducer pressure causes a loss of diastolic blood flow.

Ductus venosus (see ► **Fig. 2**) – Mix-up with adjacent vessels (e. g., liver veins) (► **Fig. 11**), resulting in incorrect Doppler spectrum, measurement during fetal respiration.

Documentation

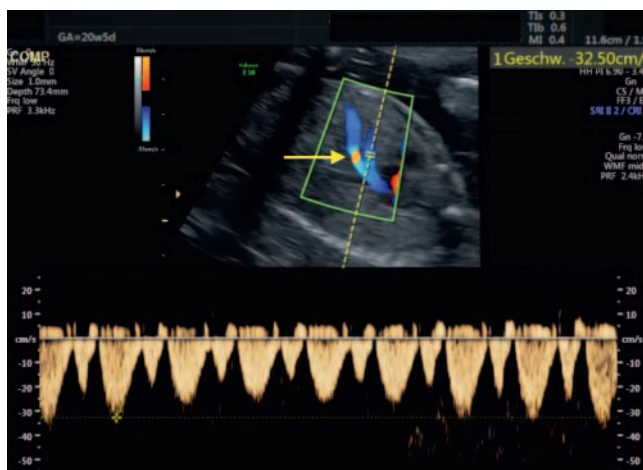
Images of every Doppler sonographic examination should be documented to show the envelope and its measurement.

Patient Safety

Ultrasound waves generate mechanical and thermal energy in biological tissues. Sonographic examinations should therefore follow the ALARA principle (as low as reasonably achievable). The default settings of modern ultrasound devices are adjusted specifically for use in fetuses. The examiner is required to check the thermal index (TI) and mechanical index (MI) settings. In B-mode ultrasound, the TI should be lower than 1.0 and the MI under 0.7. In pulsed Doppler sonography, in particular, these limits are exceeded to keep the examination time as brief as possible (ALARA principle). Especially in early pregnancy, the indications for Doppler sonography should be determined on a very strict basis [29].

Certification and Quality Management

Authorization for medical practices in Germany to use and bill for Doppler examinations in obstetrics and gynecology is regulated by the Ultrasound Agreement (Agreement on Quality Assurance Measures in accordance with § 135, paragraph 2 of Social Code Book V (SGB V) on ultrasound diagnostics (Ultrasound Agreement of October 31, 2008 in the currently valid version effective October 1, 2017). The Agreement differentiates between Doppler in prenatal diagnosis (application area = AB 22.1, duplex procedure – fetal cardiovascular system; AB 22.2, duplex procedure – fetomaternal vascular system) and Doppler examination of the vessels of the female genital system (AB 20.11 duplex procedure – vessels



► **Fig. 11** Spectral Doppler curve of a hepatic vein very close to ductus venosus with aliasing (yellow arrow), the hepatic vein has a significantly lower maximum systolic velocity (cf. ► **Fig. 2**).

of the female genital system). Authorization must be obtained for each of these application areas.

There are currently multiple options for obtaining Doppler sonography certification. These are likewise specified in the Ultrasound Agreement (§ 4: Acquisition of technical skills in accordance with the Regulation on Continuing Education; § 5 Acquisition of technical skills through regular activity; § 6 Acquisition of technical skills through ultrasound courses) (www.kbv.de/html/ultraschall).

Beyond the course specifications contained in the Ultrasound Agreement, the DEGUM also developed and specified quality standards for the content of these courses (www.degum.de).

The courses also cover the use of Doppler sonography on the uterine arteries, ductus venosus, and tricuspid valve during first-trimester screening. The use of these Doppler parameters in algorithms to identify the risk of aneuploidy and to predict the risk of preeclampsia and IUGR requires primary certification as well as annual auditing (www.fetalmedicine.com, www.fmf-deutschland.de).

Conflict of Interest

The authors declare that they have no conflict of interest.

References

- [1] Standards in der Perinatalmedizin – Dopplersonographie in der Schwangerschaft. AWMF-Leitlinie 2012
- [2] Stampalija T, Gyte GM, Alfirevic Z. Utero-placental Doppler ultrasound for improving pregnancy outcome. *Cochrane Database Syst Rev* 2010; 8: CD008363
- [3] Alfirevic Z, Stampalija T, Gyte GM. Fetal and umbilical Doppler ultrasound in normal pregnancy. *Cochrane Database Syst Rev* 2015; 15: CD001450
- [4] Bhide A, Acharya G, Bilardo CM et al. ISUOG Practice Guidelines: use of Doppler ultrasonography in obstetrics. *Ultrasound Obstet Gynecol* 2013; 41: 233–239

- [5] Bahada-Singh RO, Jodicke C. Uterine Artery Doppler in First-trimester Pregnancy Screening. *Clin Obstet Gynecol* 2010; 53: 879–887
- [6] Gómez O, Figueras F, Fernández S et al. Reference ranges for uterine artery mean pulsatility index at 11–41 weeks of gestation. *Ultrasound Obstet Gynecol* 2008; 32: 128–132
- [7] Bahlmann F, Fittschen M, Reinhard I et al. Reference values for blood flow velocity in the uterine artery in normal pregnancies from 18 weeks to 42 weeks of gestation calculated by automatic Doppler waveform analysis. *Ultraschall in Med* 2012; 33: 258–264
- [8] Weichert A, Hagen A, Tchirikov M et al. Reference Curve for the Mean Uterine Artery Pulsatility Index in Singleton Pregnancies. *Geburtshilfe Frauenheilkd* 2017; 77: 516–523
- [9] Stridsklev S, Salvesen Ø, Salvesen KÅ et al. Uterine artery Doppler measurements during first and second trimesters of normal pregnancy. *Acta Obstet Gynecol Scand* 2017; 96: 366–371
- [10] Arduini D, Rizzo G. Normal values of Pulsatility Index from fetal vessels: a cross-sectional study on 1556 healthy fetuses. *J Perinat Med* 1990; 18: 165–172
- [11] van Zalen-Sprock MM, van Vugt JM, Colenbrander GJ et al. First-trimester uteroplacental and fetal blood flow velocity waveforms in normally developing fetuses: a longitudinal study. *Ultrasound Obstet Gynecol* 1994; 4: 284–288
- [12] Acharya G, Wilsgaard T, Berntsen GK et al. Reference ranges for serial measurements of umbilical artery Doppler indices in the second half of pregnancy. *Am J Obstet Gynecol* 2005; 192: 937–944
- [13] Acharya G, Wilsgaard T, Berntsen GK et al. Reference ranges for serial measurements of blood velocity and pulsatility index at the intra-abdominal portion, and fetal and placental ends of the umbilical artery. *Ultrasound Obstet Gynecol* 2005; 26: 162–169
- [14] Bahlmann F, Fittschen M, Reinhard I et al. Blood flow velocity waveforms of the umbilical artery in a normal population: reference values from 18 weeks to 42 weeks of gestation. *Ultraschall in Med* 2012; 33: 80–87
- [15] Ebbing G, Rasmussen S, Kiserud T. Middle cerebral artery blood flow velocities and pulsatility index and the cerebroplacental pulsatility ratio: longitudinal reference ranges and terms for serial measurements. *Ultrasound Obstet Gynecol* 2007; 30: 287–296
- [16] Hsieh YY, Chang CC, Tsai HD et al. Longitudinal survey of blood flow at three different locations in the middle cerebral artery in normal fetuses. *Ultrasound Obstet Gynecol* 2001; 17: 125–128
- [17] Bahlmann F. Blood flow velocity waveforms of the fetal middle cerebral artery in a normal population: reference values from 18 weeks to 42 weeks of gestation. *J Perinat Med* 2002; 30: 490–501
- [18] Mari G. Noninvasive diagnosis by Doppler ultrasonography of fetal anemia due to maternal red-cell alloimmunization. *N Engl J Med* 2000; 342: 9–14
- [19] Detti L, Mari G. Noninvasive diagnosis of fetal anemia. *Clin Obstet Gynecol* 2003; 46: 923–930
- [20] Mari G, Norton ME, Stone J et al. Society for Maternal-Fetal Medicine (SMFM) Clinical Guideline #8: the fetus at risk for anemia – diagnosis and management. *Am J Obstet Gynecol* 2015; 212: 697–710
- [21] Swartz AE, Ruma MS, Kim E et al. The effect of fetal heart rate on the peak systolic velocity of the fetal middle cerebral artery. *Obstet Gynecol* 2009; 113: 1225–1229
- [22] Hecher K, Campbell S, Sniijders R et al. Reference ranges for fetal venous and atrioventricular blood flow parameters. *Ultrasound Obstet Gynecol* 1994; 4: 381–390
- [23] Kessler J, Rasmussen S, Hanson M et al. Longitudinal reference ranges for ductus venosus flow velocities and waveform indices. *Ultrasound Obstet Gynecol* 2006; 28: 890–898
- [24] Acharya G, Wilsgaard T, Berntsen GKR et al. Reference ranges for umbilical vein blood flow in the second half of pregnancy based on longitudinal data. *Prenat Diagn* 2005; 25: 99–111
- [25] Lenz F, Chaoui R. Reference ranges for Doppler-assessed pulmonary venous blood flow velocities and pulsatility indices in normal human fetuses. *Prenat Diagn* 2002; 22: 786–791
- [26] Dong FQ, Zhang Y, Li Z et al. Evaluation of normal fetal pulmonary veins from the early second trimester by enhanced-flow (e-flow) echocardiography. *Ultrasound Obstet Gynecol* 2011; 38: 652–657
- [27] Lenz F, Chaoui R. Changes in pulmonary venous Doppler parameters in fetal cardiac defects. *Ultrasound Obstet Gynecol* 2006; 28: 63–70
- [28] Divanović A, Hor K, Cnota J et al. Prediction and perinatal management of severely restrictive atrial septum in fetuses with critical left heart obstruction: clinical experience using pulmonary venous Doppler analysis. *J Thorac Cardiovasc Surg* 2011; 141: 988–994
- [29] Salvesen K, Lees C, Abramowicz J et al. ISUOG statement on the safe use of Doppler in the 11 to 13+6-week fetal ultrasound examination. *Ultrasound Obstet Gynecol* 2011; 37: 625–628