

Sarcoma of the Uterus. Guideline of the DGGG and OEGGG (S2k Level, AWMF Register Number 015/074, February 2019)

Uterine Sarkome. Leitlinie der DGGG und OEGGG (S2k-Level, AWMF-Register-Nummer 015/074, Februar 2019)

Authors

Dominik Denschlag¹, Sven Ackermann², Marco Johannes Battista³, Wolfgang Cremer⁴, Gerlinde Egerer⁵, Markus Follmann⁶, Heidemarie Haas⁷, Philipp Harter⁸, Simone Hettmer⁹, Lars-Christian Horn¹⁰, Ingolf Juhasz-Boess¹¹, Karin Kast¹², Günter Köhler¹³, Thomas Kröncke¹⁴, Katja Lindel¹⁵, Peter Mallmann¹⁶, Regine Meyer-Steinacker¹⁷, Alexander Mustea¹⁸, Edgar Petru¹⁹, Peter Reichardt²⁰, Dietmar Schmidt²¹, Hans-Georg Strauss²², Clemens Tempfer²³, Falk Thiel²⁴, Uwe Ulrich²⁵, Thomas Vogl²⁶, Dirk Vordermark²⁷, Paul Gass²⁸, Matthias W. Beckmann²⁸

Affiliations

- 1 Frauenklinik, Hochtaunuskliniken Bad Homburg, Bad Homburg, Germany
- 2 Frauenklinik, Klinikum Darmstadt, Darmstadt, Germany
- 3 Universitätsmedizin Mainz, Klinik und Poliklinik für Geburtshilfe und Frauengesundheit, Mainz, Germany
- 4 Berufsverband der Frauenärzte, Hamburg, Germany
- 5 Universitätsklinik Heidelberg, Heidelberg, Germany
- 6 Deutsche Krebsgesellschaft, Berlin, Germany
- 7 Frauenselbsthilfe nach Krebs e. V., Erlangen, Germany
- 8 Klinik für Gynäkologie und Gynäkologische Onkologie, Kliniken Essen Mitte, Essen, Germany
- 9 Universitätsklinik Freiburg, Freiburg, Germany
- 10 Abteilung für Mamma-, Urogenital, und Perinatalpathologie, Institut für Pathologie, Universitätsklinikum Leipzig, Leipzig, Germany
- 11 Klinik für Gynäkologie, Geburtshilfe und Reproduktionsmedizin, Universitätsklinikum des Saarlandes, Homburg/Saar, Germany
- 12 Universitätsklinik Dresden, Dresden, Germany
- 13 Deutsches klinisches Kompetenzzentrum für genitale Sarkome und Mischtumoren, Universitätsmedizin Greifswald, Greifswald, Germany
- 14 Klinik für Radiologie, Klinikum Augsburg, Augsburg, Germany
- 15 Klinik für Radioonkologie, Klinikum Karlsruhe, Karlsruhe, Germany
- 16 Klinik und Poliklinik für Frauenheilkunde und Geburtshilfe, Universitätsklinikum Köln, Köln, Germany
- 17 Universitätsklinik Ulm, Ulm, Germany
- 18 Universitäts-Frauenklinik Greifswald, Greifswald, Germany
- 19 Universitäts-Frauenklinik Graz, Graz, Austria
- 20 Klinik für interdisziplinäre Onkologie, Helios Kliniken Berlin-Buch, Berlin, Germany
- 21 Institut für Pathologie Viersen, Viersen, Germany
- 22 Klinik und Poliklinik für Gynäkologie, Universitätsklinikum Halle, Halle/Saale, Germany
- 23 Universitäts-Frauenklinik Bochum, Bochum, Germany
- 24 Frauenklinik, Alb Fils Kliniken, Göppingen, Germany
- 25 Klinik für Gynäkologie und Geburtshilfe, Martin-Luther-Krankenhaus Berlin, Paul Gerhardt Diakonie, Berlin, Germany
- 26 Institut für diagnostische und interventionelle Radiologie, Universitätsklinikum Frankfurt, Frankfurt/Main, Germany
- 27 Universitätsklinik und Poliklinik für Strahlentherapie, Universitätsklinikum Halle, Halle/Saale, Germany
- 28 Frauenklinik, Universitätsklinikum Erlangen, Friedrich-Alexander-Universität Erlangen-Nürnberg; Comprehensive Cancer Center (CCC) Erlangen-EMN, Erlangen, Germany

Key words

uterine sarcoma, leiomyosarcoma, endometrial stromal sarcoma, adenosarcoma, morcellation

Schlüsselwörter

uterine Sarkome, Leiomyosarkom, endometriales Stromasarkom, Adenosarkom, Morcellement

received 21.3.2019

accepted 22.3.2019

Bibliography

DOI <https://doi.org/10.1055/a-0882-4116>
Geburtsh Frauenheilk 2019; 79: 1043–1059 © Georg Thieme
Verlag KG Stuttgart · New York | ISSN 0016-5751

Correspondence

Prof. Dominik Denschlag
Hochtaunuskliniken Bad Homburg, Gynecology
Zeppelinstraße 20, 61352 Bad Homburg, Germany
dominik.denschlag@hochtaunus-kliniken.de



Deutsche Version unter:
<https://doi.org/10.1055/a-0882-4116>

ABSTRACT

Aims This is an official guideline published and coordinated by the German Society of Gynecology and Obstetrics (DGGG) and the Austrian Society of Gynecology and Obstetrics (OEGGG). Because of their rarity and heterogeneous histopathology, uterine sarcomas are challenging in terms of how they should be managed clinically, and treatment requires a multidisciplinary approach. To our knowledge, there are currently no binding evidence-based recommendations for the appropriate management of this heterogeneous group of tumors.

Methods This S2k guideline was first published in 2015. The update published here is the result of the consensus of a representative interdisciplinary group of experts who carried out a systematic search of the literature on uterine sarcomas in the context of the guidelines program of the DGGG, OEGGG and SGGG. Members of the participating professional societies achieved a formal consensus after a moderated structured consensus process.

Recommendations The consensus-based recommendations and statements include the epidemiology, classification, staging, symptoms, general diagnostic work-up and general pathology of uterine sarcomas as well as the genetic predisposition to develop uterine sarcomas. Also included are statements on the management of leiomyosarcomas, (low and high-grade) endometrial stromal sarcomas and undifferentiated uterine sarcomas and adenosarcomas. Finally, the guideline considers the follow-up and morcellation of uterine sarcomas and the information provided to patients.

ZUSAMMENFASSUNG

Ziel Offizielle Leitlinie, publiziert und koordiniert von der Deutschen Gesellschaft für Gynäkologie und Geburtshilfe (DGGG) und der Österreichischen Gesellschaft für Gynäkologie und Geburtshilfe (OEGGG). Aufgrund ihrer Seltenheit und heterogenen Histopathologie stellen uterine Sarkome eine Herausforderung bez. des klinischen Managements dar und bedürfen von daher eines multidisziplinären Ansatzes. Nach unserem Kenntnisstand existieren bis dato keine verbindlichen, evidenzbasierten Empfehlungen bez. des angemessenen Managements dieser heterogenen Tumoren.

Methoden Die vorliegende S2k-Leitlinie wurde erstmals 2015 publiziert. Das nun hier publizierte Update ist erneut das Ergebnis eines Konsenses eines repräsentativen interdisziplinären Expertenkomitees, das im Rahmen des Leitlinienprogramms der DGGG, OEGGG und SGGG eine systematische Literaturrecherche zum Thema uterine Sarkome durchgeführt hat. Mitglieder der beteiligten Fachgesellschaften entwickelten in einem strukturierten Prozess einen moderierten formalen Konsensus.

Empfehlungen Die konsentierten Empfehlungen und Statements beziehen sich auf die Epidemiologie, Klassifikation, Stadieneinteilung, Symptomatik, allgemeine Diagnostik, allgemeine Pathologie bzw. genetische Prädisposition von uterinen Sarkomen. Weiterhin werden Aussagen über das Management von Leiomyosarkomen, endometrialen Stromasarkomen (low- und high-grade) und undifferenzierten uterinen Sarkomen und Adenosarkomen getroffen. Abschließend werden die Nachsorge, das Morcellement und die Patientinnen-aufklärung von bzw. bei uterinen Sarkomen erwähnt.

I Guideline Information

Guidelines program of the DGGG, OEGGG and SGGG

For information on the guidelines program, please refer to the end of the guideline.

Citation format

Sarcoma of the Uterus. Guideline of the DGGG and OEGGG (S2k Level, AWMF Register Number 015/074, February 2019). Geburtsh Frauenheilk 2019; 79: 1043–1059

Guideline documents

The complete long version together with a slide version of this guideline and a list of the conflicts of interests of all authors involved are available in German on the homepage of the AWMF: <http://www.awmf.org/leitlinien/detail/II/015-074.html>

Guideline authors

See ► **Tables 1** and **2**.

II Guideline Application

Purpose and objectives

The purpose of this guideline is to provide information and advice to women about the diagnostic work-up, treatment and follow-up of uterine sarcomas (with the exception of carcinosarcomas). The guideline focuses on the differentiated management of different subtypes. In addition, the guideline should provide a basis for decision-making about the appropriate treatment during interdisciplinary tumor conferences held in DKG-certified gynecological cancer centers and sarcoma centers currently being set up.

► **Table 1** Lead author and/or coordinating lead author of the guideline.

Author	AWMF professional society
Prof. Dominik Denschlag	German Society of Gynecology and Obstetrics [Deutsche Gesellschaft für Gynäkologie und Geburtshilfe]

► **Table 2** Participating authors.

Author Mandate holder	DGGG working group (AG)/AWMF/non-AWMF professional society/organization/association
Prof. Dr. E. Petru (Graz)	Österreichische Gesellschaft für Gynäkologie und Geburtshilfe (ÖGGG)
Prof. Dr. M. W. Beckmann (Erlangen)	Deutsche Gesellschaft für Gynäkologie und Geburtshilfe (DGGG)
PD Dr. S. Ackermann* (Darmstadt), Dr. H. G. Strauss (Halle/Saale), PD Dr. P. Harter (Essen), Prof. Dr. P. Mallmann (Köln), PD Dr. F. Thiel (Göppingen)	Arbeitsgemeinschaft Gynäkologische Onkologie (AGO) of the Deutsche Gesellschaft für Gynäkologie und Geburtshilfe (DGGG)/Deutsche Krebsgesellschaft (DKG)
Prof. Dr. A. Mustea* (Greifswald)	Nordostdeutsche Gesellschaft für Gynäkologische Onkologie (NOGGO)
Prof. Dr. U. Ulrich (Berlin), PD Dr. I. Juhasz-Boess* (Homburg)	Arbeitsgemeinschaft Gynäkologische Endoskopie (AGE)
Prof. Dr. D. Schmidt* (Mannheim)	Deutsche Gesellschaft für Pathologie (DGP)
Prof. Dr. L. C. Horn (Leipzig)	Bundesverband Deutscher Pathologen (BDP) and Deutsche Gesellschaft für Pathologie (DGP) (substitute for Prof. Schmidt)
PD Dr. P. Reichardt (Berlin)	Deutsche Gesellschaft für Hämato-Onkologie (DGHO)
Prof. Dr. D. Vordermark (Halle/Saale)	Deutsche Gesellschaft für Radioonkologie (DEGRO) and Arbeitsgemeinschaft Radioonkologie (ARO) (substitute for Prof. Lindel)
Prof. Dr. K. Lindel* (Karlsruhe)	Arbeitsgemeinschaft Radioonkologie (ARO)
Prof. Dr. T. Vogl (Frankfurt am Main)	Deutsche Röntgengesellschaft (DRG) and Deutsche Gesellschaft für Interventionelle Radiologie (DEGIR) (substitute for Prof. Kröncke)
Prof. Dr. T. Kröncke* (Augsburg)	Deutsche Gesellschaft für Interventionelle Radiologie (DEGIR)
Dr. W. Cremer (Hamburg)	Berufsverband der Frauenärzte (BVF)
Dr. K. Kast* (Dresden)	Arbeitsgemeinschaft Erbliche Tumore (AET)
Prof. Dr. G. Egerer (Heidelberg), Dr. R. Mayer-Steinacker (Ulm)	Arbeitsgemeinschaft Supportive Maßnahmen in der Onkologie (AGSMO)
Heidrun Haase (Bad Homburg)	Federal Women's Self-help after Cancer Organization [Bundesverband Frauenselbsthilfe nach Krebs e. V.]
PD Dr. S. Hettmer* (Freiburg)	Society for Pediatric Oncology and Hematology [Gesellschaft für Pädiatrische Onkologie und Hämatologie]
Prof. Dr. G. Köhler* (Greifswald)	Expert
Prof. Dr. C. Tempfer (Bochum)	Expert
Dr. M. Battista (Mainz)	Expert

* These persons have contributed substantially to the development of the guideline. They did not vote on Recommendations or Statements.

Dr. M. Follmann (AWMF-certified guidelines advisor/moderator) was kind enough to moderate the guideline. Dr. P. Gaß (DGGG Guidelines Office, Erlangen) contributed substantially to the compilation of the long and short version of this guideline.

Targeted areas of patient care

- inpatient care
- outpatient care

Target user groups/target audience

This guideline is aimed at the following groups of people:

- gynecologists in private practice
- gynecologists working in hospitals
- pathologists
- radiation therapists
- hemato-oncologists specializing in internal medicine
- pediatric hemato-oncologists
- radiologists
- affected patients

Adoption and period of validity

The validity of this guideline was confirmed by the executive boards/heads of the participating professional societies/working groups/organizations/associations as well as by the board of the DGGG and of the DGGG Guideline Commission and the OEGGG

in December 2018 and was thereby approved in its entirety. This guideline is valid from 1 December 2018 through to 30 November 2021. Because of the contents of this guideline, this period of validity is only an estimate.

III Methodology

Basic principles

The method used to prepare this guideline was determined by the class to which this guideline was assigned. The AWMF Guidance Manual (version 1.0) has set out the respective rules and requirements for different classes of guidelines. Guidelines are differentiated into lowest (S1), intermediate (S2) and highest (S3) class. The lowest class is defined as a set of recommendations for action compiled by a non-representative group of experts. In 2004, the S2 class was divided into two subclasses: a systematic evidence-based subclass (S2e) and a structural consensus-based subclass (S2k). The highest S3 class combines both approaches.

This guideline is classified as: **S2k**

Grading of evidence

Grading of evidence based on a systematic search, selection, evaluation and synthesis of the evidence base followed by a grading of the evidence is not envisaged for S2k-level guidelines. The respective individual Statements and Recommendations are only differentiated by syntax, not by symbols (► **Table 3**).

► **Table 3** Grading of recommendations.

Level of recommendation	Syntax
Strong recommendation, highly binding	must/must not
Simple recommendation, moderately binding	should/should not
Open recommendation, not binding	may/may not

Statements

Expositions or explanations of specific facts, circumstances or problems which do not include any direct recommendations for action included in this guideline are referred to as “Statements”. It is *not* possible to provide any information about the grading of evidence for these Statements.

Achieving consensus and strength of consensus

At structured NIH-type consensus-based conferences (S2k/S3 level) authorized participants attending the session vote on draft Statements and Recommendations. The process is as follows: a Recommendation is presented, its contents are discussed, proposed changes are put forward, and finally, all proposed changes are voted on. If a consensus has not been achieved (>75% of votes), there is another round of discussions, followed by a repeat vote. Finally, the extent of consensus is determined based on the number of participants (► **Table 4**).

► **Table 4** Classification on the extent of agreement for consensus-based decisions.

Symbol		Extent of agreement in percent
+++	Strong consensus	>95% of participants agree
++	Consensus	>75–95% of participants agree
+	Majority agreement	>50–75% of participants agree
–	No consensus	<51% of participants agree

Expert consensus

As the name already implies, this refers to consensus decisions taken with regard to specific Recommendations/Statements without a prior systematic search of the literature (S2k) or for which

evidence is lacking (S2e/S3). The term “expert consensus” (EC) used here is synonymous with terms used in other guidelines such as “good clinical practice” (GCP) or “clinical consensus point” (CCP). The strength of the recommendation is graded as previously described in the chapter “Grading of recommendations”, i.e., purely semantically (“must”/“must not” or “should”/“should not” or “may”/“may not”) and without the use of symbols.

IV Guideline

1 Introduction

1.1 Epidemiology, classification, staging

Consensus-based Statement 1.S1

Expert consensus	Strength of consensus +++
------------------	---------------------------

Uterine sarcomas (homologous) are a heterogeneous group of rather rare malignancies (1.5–3/100 000) of the uterine musculature, endometrial stroma or uterine connective tissue.

Consensus-based Recommendation 1.E1

Expert consensus	Strength of consensus +++
------------------	---------------------------

The terminology and the morphological diagnosis of uterine sarcomas must be based on the most current edition of the WHO classification.

References: [1, 2]

Consensus-based Recommendation 1.E2

Expert consensus	Strength of consensus +++
------------------	---------------------------

The postoperative staging of uterine sarcomas must be based on the most current pTNM classification.

References: [2]

The WHO classification lists the following entities as malignant mesenchymal tumors or malignant mixed epithelial-mesenchymal tumors [2, 3]:

- leiomyosarcoma (LMS),
- low-grade endometrial stromal sarcoma (LG-ESS),
- high-grade endometrial stromal sarcoma (HG-ESS),
- undifferentiated uterine sarcoma (UUS),
- adenosarcoma (AS),
- PECome (perivascular epithelioid cell tumor), malignant variant.

The diagnosis of other extremely rare sarcomas of the uterus (e.g. rhabdomyosarcoma as an example of a heterologous sarcoma) must be based on the WHO classification of soft tissue sarcomas [4].

This guideline considers the more common entities (LMS, LG-ESS, HG-ESS and UUS or AS) to the exclusion of extremely rare types (rhabdomyosarcoma in adulthood, angiosarcoma, osteosarcoma, chondrosarcoma, liposarcoma, myxofibrosarcoma, al-

► **Table 5** FIGO and TNM stages for leiomyosarcomas and endometrial stromal sarcomas* of the uterus.

FIGO/TNM stage	Definition	
I/T1	Tumor limited to the uterus	
	IA/T1a	Tumor 5 cm or less in greatest dimension
	IB/T1b	Tumor larger than 5 cm in greatest dimension
II/T2	Tumor extends beyond the uterus, within the pelvis	
	IIA/T2a	Involvement of the adnexa (unilateral or bilateral)
	IIB/T2b	Tumor has spread to extrauterine pelvic tissue excluding the adnexa
III/T3	Tumor has infiltrated abdominal tissue	
N1	IIIA/T3a	One site
	IIIB/T3b	More than one site
	IIIC	Metastasis of pelvic and/or para-aortic lymph nodes
IV/T4	IVA/T4	Tumor has infiltrated bladder and/or rectum
	IVB	Distant metastasis

* Tumors simultaneously present in the corpus uteri and the ovary/pelvis accompanied by ovarian/pelvic endometriosis must be classified as independent primary tumors.

► **Table 6** FIGO and TNM stages for adenocarcinomas* of the uterus.

FIGO/TNM stage	Definition	
I/T1	Tumor limited to the uterus	
	IA/T1a	Tumor limited to the endometrium/ endocervix without myometrial infiltration
	IB/T1b	Tumor has infiltrated less than half of the myometrium
	IC/T1c	Tumor has infiltrated $\geq 50\%$ of the myometrium
II/T2	Tumor has spread to the pelvis	
	IIA/T2a	Involvement of the adnexa (unilateral or bilateral)
	IIB/T2b	Tumor has spread to extrauterine pelvic tissue excluding the adnexa
III/T3	Intraabdominal tumor spread	
N1	IIIA/T3a	One site
	IIIB/T3b	More than one site
	IIIC	Metastasis of pelvic and/or para-aortic lymph nodes
IV/T4	IVA/T4	Tumor has infiltrated bladder and/or rectal mucosa
	IVB	Distant metastasis

* Tumors simultaneously present in the corpus uteri and the ovary/pelvis accompanied by ovarian/pelvic endometriosis must be classified as independent primary tumors.

veolar soft part sarcoma and epithelioid sarcoma). A chapter on “Rhabdomyosarcoma of the uterus in children and adolescents” was added to the guideline.

The mean patient age at onset of disease is between 50 and 70 years, depending on the tumor type. Identified risk factors include tamoxifen therapy. Moreover, the incidence of uterine sarcomas is 2 to 3 times higher for women of African descent compared to Asian women or women of European descent.

Carcinosarcomas, which used to be referred to as uterine sarcomas in earlier classifications (also known as malignant mixed Müllerian tumors), are no longer classified as uterine sarcomas but as uterine carcinomas [5, 6]. For this reason, this tumor entity is now discussed in the German national S3 guideline “032-034OL Diagnosis, Treatment and Follow-up of Patients with Endometrial Cancer” [7] (Staging – ► **Tables 5** and **6**).

1.2 Symptoms, general diagnostic work-up (including imaging), general pathology

1.2.1 Symptoms

Consensus-based Statement 1.S2	
Expert consensus	Strength of consensus +++
Uterine sarcomas are not associated with any specific symptoms.	

Generally suspicious symptoms include a “rapidly growing uterus” despite low estrogen levels in the postmenopausal period.

Although it has been suggested that rapid growth of the uterus (e.g., an increase in size resembling 6 weeks of pregnancy over a period of one year [8]) may be an indication for sarcoma, an analysis by Parker and colleagues of more than 1300 patients (of whom around 350 had “rapid growth”) found no increased risk of sarcoma compared to the respective controls (0.27 vs. 0.23%) [9].

Finally, it should be noted that there is no valid definition of what constitutes “rapid growth” nor has any useful data been published which would permit this parameter to be usefully evaluated in terms of being able to differentiate between myomas and sarcomas.

1.2.2 Imaging

Consensus-based Recommendation 1.E3	
Expert consensus	Strength of consensus +++
Because of the high potential for metastasis, histologically verified uterine sarcomas should be investigated further, including imaging (CT/MRI) of the thorax and abdomen.	

Consensus-based Recommendation 1.E4

Expert consensus	Strength of consensus +++
Imaging procedures or diagnostic interventions may not be able to exclude uterine sarcoma.	

No imaging procedures (sonography, CT, MRT, PET-CT) have any specific or reliable criteria for detecting sarcomas [10].

In general, transvaginal ultrasound is the most important primary diagnostic procedure used to evaluate the uterus.

Computed tomography may be used for abdominal imaging. This is particularly suitable for staging and to identify distant metastasis.

If a patient is known to have a sarcoma, the patient should also have a thoracic CT scan which can then serve as the basis for current management, with the findings used for follow-up.

1.2.3 General pathology

1.2.3.1 Specimens after hysterectomy or surgery of uterine sarcoma

Consensus-based Recommendation 1.E5

Expert consensus	Strength of consensus +++
The morphological work-up must find out all of the information listed below.	
<ul style="list-style-type: none"> Grading of the histological tumor type based on the WHO classification Grading of ESS Evidence for/no evidence of lymph node or blood vessel infiltration (L and V status) Evidence for/no evidence of perineural infiltration (PNI status) Staging (pTNM) Infiltration depth into the myometrium or (endo-)cervical stroma Three-dimensional tumor size, in cm Metric data for the minimal distance between the sarcoma and the respective relevant resection margin R classification (UICC) Estrogen and progesterone receptor expression 	
References: [2, 11 – 13]	

Consensus-based Recommendation 1.E6

Expert consensus	Strength of consensus +++
As uterine sarcomas may be characterized by a high degree of intra-tumoral heterogeneity, all tumors with a maximum diameter of <2 cm must be fully investigated. Tumors with diameters of >2 cm must be embedded in paraffin, using one paraffin block per centimeter greatest tumor dimension.	

Consensus-based Recommendation 1.E7

Expert consensus	Strength of consensus +++
If the findings do not provide clear information about the malignancy or subtype, a pathological examination must be carried out to investigate the tumor further.	

Consensus-based Recommendation 1.E8

Expert consensus	Strength of consensus +++
All patients with a diagnosis of uterine sarcoma must be presented to an interdisciplinary tumor conference.	

Consensus-based Recommendation 1.E9

Expert consensus	Strength of consensus +
The presentation must be done at a DKG-certified gynecological cancer center or sarcoma center.	

1.3 Genetic predisposition

Consensus-based Recommendation 1.E10

Expert consensus	Strength of consensus +++
If conditions for a germline analysis of the TP53 gen are present, patients must be offered genetic counseling with subsequent analysis to exclude LFS.	

The majority of sarcomas occur sporadically. Nevertheless, a diagnosis of uterine sarcoma in childhood or early adulthood may be an indication of Li-Fraumeni syndrome (LFS), an inherited familial predisposition to certain cancers.

2 Uterine leiomyosarcoma

2.1 Introduction, clinical and diagnostic work-up

In Northern Europe, sarcomas occur in about 0.4 cases/100 000 women across all age groups with the highest incidence found in women between the ages of 45 and 59 years [14].

The median age at onset of disease is 50 years [15].

Clinical symptoms reported by the patient can include abnormal bleeding (e.g. mid-cycle bleeding postmenopausal bleeding) and, depending on the size of the lesion, a sensation of pressure in the vagina or abdomen. However, in around 50% of cases (e.g., in women with postmenopausal bleeding), the results of curettage and/or endometrial biopsy can be false-negative and do not allow LMS to be clearly excluded [16].

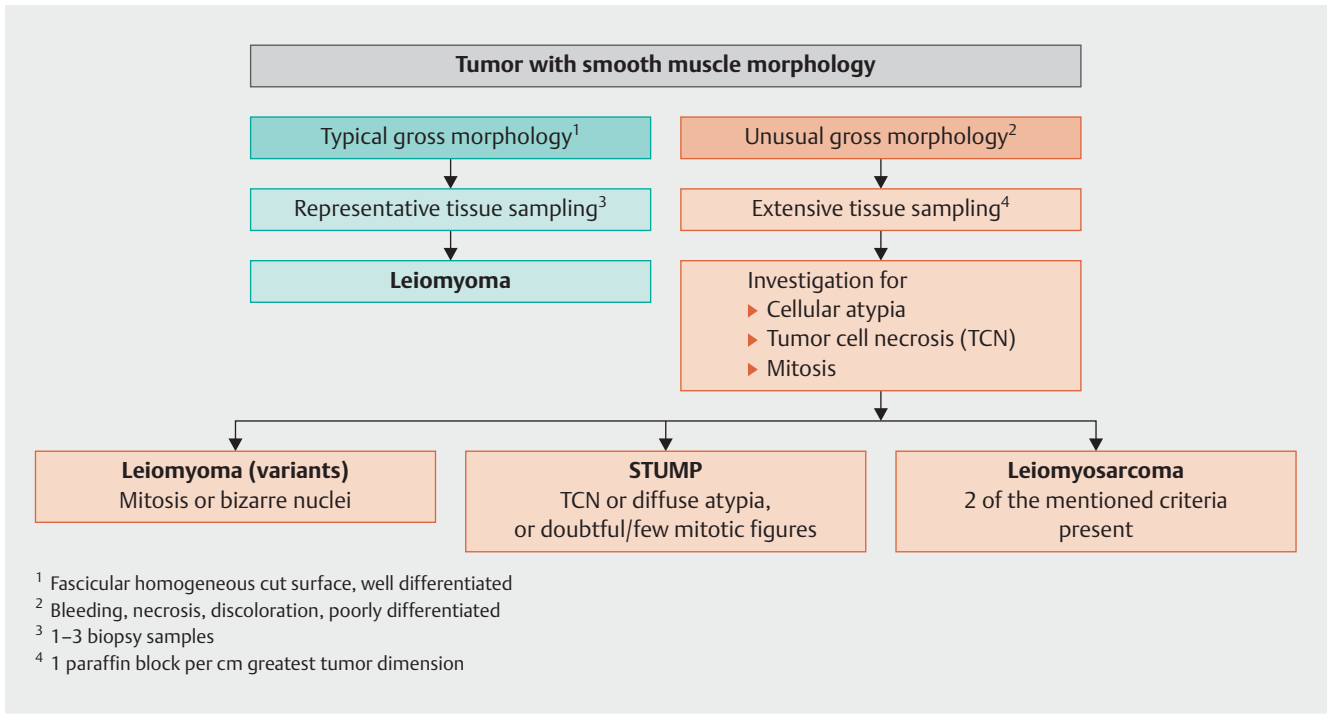
2.2 Histopathological diagnosis

The WHO classification lists both classic and spindle cell leiomyosarcoma as well as an epithelioid and a myxoid variant in its histological differentiation of sarcomas [2].

The WHO classification does not grade uterine LMS [2].

A diagnosis of smooth muscle tumor of uncertain malignant potential (STUMP) [17] should only be made in exceptional cases if it is not possible to clearly differentiate between (classic) LMS and leiomyoma [18–20].

► **Fig. 1** shows a diagnostic algorithm for smooth muscle tumors [17, 18, 20–23].



► Fig. 1 Diagnostic algorithm of smooth muscle tumors of the uterus. [rerif]

2.3 Prognosis

LMS are very aggressive tumors with an unfavorable prognosis. The rate of recurrence ranges from 53 to 71%, and the average 5-year overall survival rate is between 40 and 50% [24, 25].

Additional prognostic factors are age, tumor-free resection margins, mitotic index and vascular invasion [24, 26]. The most important iatrogenic negative prognostic factors are morcellation or tumor injury, e.g. caused by a “myomectomy” [27].

2.4 Surgical treatment

Consensus-based Recommendation 2.E11	
Expert consensus	Strength of consensus +++
Treatment of early-stage tumors must include complete removal of the uterus without morcellation but must include bilateral resection of the adnexa.	
In premenopausal patients, the ovaries may be preserved.	

Consensus-based Recommendation 2.E12	
Expert consensus	Strength of consensus +++
Systematic pelvic and para-aortic lymphadenectomy should not be carried out if the lymph nodes are diagnostically unremarkable.	

Total hysterectomy is the gold standard for the surgical management of LMS which are limited to the uterus. The decision whether the adnexa need to be resected will usually depend on the pa-

tient’s menopausal status. In young women, the ovaries can be preserved without affecting prognosis [26, 28, 29]. Ovarian metastasis is rare, with an incidence of just 3%, and occurs almost exclusively in cases with intraperitoneal spread [29].

The incidence of primary pelvic and para-aortic lymph node metastasis is low in cases with LMS. If lymph node involvement is present (involvement is often already detected intraoperatively), then extrauterine or hematogenous metastasis is usually also present. This means that systematic pelvic and para-aortic lymphadenectomy is not associated with a better prognosis, and it is therefore generally not recommended [28, 30, 31].

2.5 Adjuvant systemic therapy and radiotherapy

Consensus-based Recommendation 2.E13	
Expert consensus	Strength of consensus +++
Adjuvant chemotherapy should not be generally administered. Depending on the presence of other risk factors (e.g. higher stage tumor) it may be administered in individual cases after carefully weighing up the potential drawbacks/benefits with the patient.	

Consensus-based Recommendation 2.E14	
Expert consensus	Strength of consensus +++
Radiotherapy should not be carried out after complete resection of a stage I/II LMS.	

Adjuvant systemic therapy is not generally indicated as no randomized controlled study has been able to provide evidence for any benefit in terms of overall survival [32].

Based on the current results of both prospective phase II trials and a phase III trial, it appears that patients with leiomyosarcoma whose tumor is limited to the uterus (stage I–III A with involvement limited exclusively to the uterine serosa) could benefit from systemic therapy after surgery with no residual tumor.

In this context, it was found in a small phase III trial (n = 81 patients, 19 of whom presented with carcinosarcoma) that a combination of doxorubicin/ifosfamide/cisplatin had a significant positive effect on 3-year progression-free survival (55% had additional radiotherapy vs. 41% in the control group who had only radiotherapy), but it was accompanied by significantly higher toxicity [33].

Another phase II trial (n = 47) which used combination chemotherapy with docetaxel and gemcitabine followed by doxorubicin had similarly good results in terms of PFS but with lower toxicity (3-year PFS: 57%) [34, 35].

Based on these results, it would appear that adjuvant chemotherapy should at least be discussed in certain individual cases, even if there is, as yet, no evidence that it leads to a significant improvement in overall survival.

A randomized study reported that adjuvant pelvic irradiation with 50.4 Gy in cases with stage I or II disease resulted in improved local control in a patient population with different sarcoma entities [36], but in the subgroup of patients with leiomyosarcomas (n = 99) no effect was found on either the local rate of recurrence (20% with radiotherapy, 24% without radiotherapy) or the overall survival rate. This means that radiotherapy is not generally indicated after complete resection of a stage I/II LMS. Radiotherapy can be considered in patients with R1/2 resection and locally advanced disease if the tumor is limited to the pelvis.

2.6 Treatment for metastasis and recurrence

Consensus-based Recommendation 2.E15

Expert consensus	Strength of consensus +++
If the diagnosis is metastasized LMS, the first-line therapy must consist of doxorubicin.	

There is some evidence to suggest that when treating patients with uterine leiomyosarcoma and recurrence or metastasis, complete surgical resection is associated with a better prognosis compared to chemotherapy and/or radiotherapy [37–40]. Two studies carried out in a selected patient population reported improved survival rates (median survival: 45 vs. 31 months and 2.0 vs. 1.1 years, respectively) after complete resection of metastases in patients with leiomyosarcoma [37, 41].

Palliative systemic therapy is indicated for patients with diffuse metastasis and patients with recurrence/metastasis which cannot be/can no longer be treated with surgery. Such a therapy should be discussed in detail with the patient and the associated toxicity needs to be considered carefully.

There are only a few effective substances such as ifosfamide, gemcitabine or doxorubicin which can be used for mono-chemotherapy, and they are reported to have moderate rates of response (partial or complete remission) of between 17 and 25% [42, 43].

Paclitaxel, cisplatin, topotecan and etoposide are less effective and have low response rates of less than 10% [44–47].

In contrast, although combination chemotherapies have higher response rates compared to monotherapies, the toxicity associated with combination therapies is higher [48–50].

Only one prospective randomized phase II trial has shown that combination therapy is superior to mono-chemotherapy in terms of survival; therapy consisted of a combination of docetaxel/gemcitabine [51]. However, another study with a comparable design was unable to confirm the findings of the first study, so that it is still ultimately not clear whether this combination offers a benefit for patients [52].

According to more recent data from a phase III trial, a combination of docetaxel and gemcitabine offered no benefits compared to monotherapy with doxorubicin to either the overall patient population with soft tissue sarcomas or the subgroup with uterine LMS (median overall survival: 67 vs. 76 weeks; HR: 1.14, 95% CI: 0.83–1.57; p = 0.41 for the total patient population, n = 257) [53].

The use of trabectedin in second-line chemotherapy in a metastatic setting after prior administration of anthracyclines was investigated in phase II trials and should be the antitumoral drug of choice to treat this indication. Although the expected remission rates are very low, disease may be stabilized in up to 50% of cases [54].

Pazopanib, a multiple tyrosine kinase inhibitor, is another second-line therapy option which has been investigated in a double-blind, placebo-controlled phase III trial, although patients with a range of sarcoma types of varying histologies and with metastasis were included in the study. As regards the rate of remission and the percentage of patients who experienced disease stabilization, the same statement applies to pazopanib as for trabectedin. In this study, pazopanib significantly increased the progression-free survival period both in the overall patient population and in the subgroup of patients with leiomyosarcoma [55].

3 Low-grade endometrial stromal sarcomas

3.1 Introduction, clinical and diagnostic work-up

The median age at onset of disease is the 6th decade of life [15].

These tumors typically manifest as pathological bleeding, sometimes together with an enlarged uterus and corresponding symptoms.

The WHO classification of malignant endometrial stromal tumors (► Fig. 2) differentiates between

- low-grade endometrial stromal sarcomas,
- high-grade endometrial stromal sarcomas and
- undifferentiated uterine sarcomas [17].

3.2 Prognosis

Tumor stage is the most important prognostic factor for low-grade ESS [56]. The disease-specific 5-year survival rate for low-grade ESS is 80–90% and the 10-year survival rate is approxi-

Low-grade ESS	High-grade ESS	Undifferentiated uterine sarcoma (UES)
Morphologie		
<ul style="list-style-type: none"> ▶ Resemblance to endometrial stromal cells ▶ Limited polymorphism ▶ Very little (microscopic) necrosis ▶ Tongue-like myoinvasion ▶ Few/no mitotic figures 	<ul style="list-style-type: none"> ▶ Often transition from LG to HG-ESS ▶ Greater degree of polymorphism ▶ Microscopic/macrosopic necrosis ▶ Destructive growth ▶ Many mitotic figures (usually > 10/10 HPF) 	<ul style="list-style-type: none"> ▶ No resemblance to ESS ▶ High degree of polymorphism ▶ Usually macroscopic necrosis ▶ Destructive growth ▶ Rich in mitotic figures
Immunohistochemistry		
<ul style="list-style-type: none"> ▶ CD10+, ER/PR+ ▶ Cyclin D1_{nuc}+ usually < 10% of tumor cells ▶ SMA(+), CD117- 	<ul style="list-style-type: none"> ▶ CD10-, ER/PR- ▶ Cyclin D1_{nuc}+ > 70% of tumor cells ▶ CD117+, DOG-1- ▶ BCOR+ (> 70%) 	<ul style="list-style-type: none"> ▶ CD10, ER/PR variable, heterogeneous ▶ Cyclin D1_{nuc}+/- ▶ SMA, EMA, CKs, desmin variable
Molecular pathology		
Prognosis		
Good	Intermediate	Poor

▶ **Fig. 2** Synopsis of the morphology, immunohistochemistry and molecular pathology of endometrial stromal sarcomas (ESS) and undifferentiated uterine sarcomas (UUS). [rerif]

mately 70% [57, 58]. If the tumor is limited to the uterus at the time of diagnosis (stage I), then the rates are even higher: 100 and 90%, respectively. The rate drops to 40% for higher stage disease [31]. Positive hormone receptors are a favorable prognostic factor with regard to overall survival [59].

3.3 Surgical treatment

Consensus-based Recommendation 3.E16	
Expert consensus	Strength of consensus +++
Treatment of early-stage disease must consist of complete resection of the uterus without morcellation but with complete bilateral resection of the adnexa.	

Consensus-based Recommendation 3.E17	
Expert consensus	Strength of consensus +++
There are currently no data about the oncological safety of hormone replacement therapy after previous primary treatment of a low-grade ESS. Because the tumor biology of low-grade ESS is highly estrogen-dependent, patients should be dissuaded from starting hormone replacement therapy.	
Reference: [60]	

Consensus-based Recommendation 3.E18	
Expert consensus	Strength of consensus +++
Systematic pelvic and para-aortic lymphadenectomy should not be carried out if the lymph nodes are diagnostically unremarkable.	

The treatment of choice is total hysterectomy (without morcellation) and resection of both adnexa [61].

There is a lot of evidence regarding the endocrine dependence of LG-ESS. A retrospective analysis of 153 patients with LG-ESS found a significantly increased rate of recurrence when the ovaries of premenopausal patients were not removed. Neither this analysis nor two other evaluations of the SEER database found that this had a negative impact on overall survival. Thus, the benefits of ovarian preservation in younger patients must be carefully weighed against the risk of a higher probability of recurrence and must be critically discussed with affected patients [62–64].

Lymph node involvement does not appear to have an impact on prognosis. Systemic lymphadenectomy and any adjuvant therapy options based on systemic lymphadenectomy are therefore not expected to extend survival times, meaning that lymphadenectomy cannot be routinely recommended [10, 58, 64, 65].

3.4 Adjuvant systemic therapy and radiotherapy

Consensus-based Recommendation 3.E19

Expert consensus	Strength of consensus +++
Adjuvant endocrine therapy should not be generally carried out, although it may be considered depending on the presence of other risk factors (e.g. higher tumor stage) in individual cases after carefully weighing up the drawbacks/benefits with the patient.	

Consensus-based Recommendation 3.E20

Expert consensus	Strength of consensus +++
Adjuvant chemotherapy must not be carried out.	

Consensus-based Recommendation 3.E21

Expert consensus	Strength of consensus +++
Adjuvant radiotherapy must not be carried out.	

Postoperative adjuvant endocrine therapy may be discussed with patients with FIGO stage III disease and higher or after accidental morcellation, although prospective studies are lacking. The data from comparative retrospective analyses of adjuvant treatment support the use of either medroxyprogesterone acetate 200 mg/d (in Germany only available as 250 mg doses) or megestrol acetate 160 mg/d or as an alternative to aromatase inhibitors (letrozole 2.5 mg/d, anastrozole 1 mg/d or exemestane 25 mg/d). The appropriate duration for adjuvant treatment has not been sufficiently investigated. A period of 5 years is currently being discussed [66–68].

There are no valid data available on adjuvant chemotherapy.

A large epidemiological study from the USA carried out in 3650 patients with uterine sarcoma showed that adjuvant pelvic irradiation (\pm brachytherapy) had a significant positive effect on loco-regional recurrence-free survival for both the total patient population [69] and the subgroup of patients with ESS (n = 361:

after 5 years: 97 vs. 93%; after 8 years 97 vs. 87%). But another large epidemiological study from the USA in a total of 1010 patients with ESS was unable to confirm that adjuvant radiotherapy had a significant benefit on overall survival [58]. The only relevant randomized study on the use of pelvic radiation in patients with uterine sarcoma [36] included 30 patients with endometrial stromal sarcomas but did not carry out a separate survival analysis for this subgroup of patients. Because of the unclear data and the medium- and long-term side effects of adjuvant radiotherapy when loco-regional control is already good, this treatment is not generally indicated.

3.5 Treatment for metastasis and recurrence

Consensus-based Recommendation 3.E22

Expert consensus	Strength of consensus +++
Tamoxifen is contraindicated for LG-ESS.	

Endometrial stromal sarcomas usually have a better prognosis compared to leiomyosarcomas. However, recurrence is possible even after decades [70]. In every case with recurrence or metastasis, it is important to check whether surgery with the aim of complete macroscopic resection is possible [71].

The targeted administration of percutaneous radiotherapy is a palliative option for local or loco-regional recurrence which cannot be completely resected [72, 73].

Systemic therapy can be administered in cases with postoperative residual tumor, inoperable recurrence with distant metastasis of low-grade endometrial stromal sarcoma. Because of the high expression of estrogen and progesterone receptors, progestogens or aromatase inhibitors are used to treat low-grade endometrial stromal sarcomas [74–77].

A retrospective analysis of a small case series found medroxyprogesterone acetate 200 mg/d (in Germany only available in doses of 250 mg) or megestrol acetate 160 mg/d to be effective. Response rates of up to 82% were reported [75]. Alternatively, although there is less data available, aromatase inhibitors (letrozole 2.5 mg/d, anastrozole 1 mg/d or exemestane 25 mg/d) also appear to have a positive effect [76].

Because it is a risk factor for uterine sarcoma, tamoxifen must not be used for endocrine therapy [78].

Any ongoing therapy with tamoxifen should be discontinued. If the use of tamoxifen is indicated because of breast cancer, treatment should be switched to an aromatase inhibitor.

4 High-grade endometrial stromal sarcomas and undifferentiated uterine sarcomas

4.1 Introduction, clinical and diagnostic work-up

Although there are distinct pathological anatomical differences between HG-ESS and UUS, both entities share a number of similarities in terms of their incidence, clinical presentation, prognosis and even therapy, which is why they are discussed together here. The staging corresponds to that for LMS.

The median age at onset of disease is 60 years. These tumors also typically manifest as pathological bleeding, sometimes together with an enlarged uterus and the corresponding symptoms.

As previously mentioned, the term “undifferentiated endometrial sarcoma (UES)” which was still included in the WHO classification of 2003 [79] is no longer included in the most recent WHO classification [2] and should therefore no longer be used.

4.2 Prognosis

As regards prognosis, the prognosis for HG-ESS is between that of the more favorable prognosis associated with LG-ESS and the prognosis for aggressively progressive undifferentiated uterine sarcomas (UUS) [80].

However, because disease is often only detected in its later stages, the prognosis is generally unfavorable with a median overall survival of just 1–2 years [81, 82].

4.3 Surgical treatment

Consensus-based Recommendation 4.E23	
Expert consensus	Strength of consensus +++
Treatment of early-stage disease must consist of complete resection of the uterus without morcellation but with complete bilateral resection of the adnexa.	

Consensus-based Recommendation 4.E24	
Expert consensus	Strength of consensus +++
Systematic pelvic and para-aortic lymphadenectomy should not be carried out if the lymph nodes are diagnostically unremarkable.	

The treatment of choice also consists of complete hysterectomy (without morcellation) and bilateral adnexal resection. It is not clear whether the adnexa of premenopausal women can be left in situ.

Although positive pelvic and/or para-aortic lymph nodes are associated with a poorer prognosis, there is currently no indication that surgical removal followed by consequent adjuvant therapy would lead to an improvement of this limited prognosis.

4.4 Adjuvant systemic therapy and radiotherapy

Consensus-based Recommendation 4.E25	
Expert consensus	Strength of consensus +++
Adjuvant chemotherapy should not be routinely carried out, but it may be considered in individual cases depending on the presence of additional risk factors (e.g. higher tumor stage).	

There are currently no valid data which indicate that postoperative endocrine therapy would benefit patients, even though evidence for hormone receptors is rare.

There are currently no valid data on the benefit of adjuvant chemotherapy, which means that it must be discussed on an individual basis.

The data on adjuvant radiotherapy is similarly limited. A multi-center retrospective analysis evaluated 59 patients with endometrial stromal tumors, 29 of whom had undifferentiated uterine sarcoma (58% had stage I or II disease (FIGO 1988) [83]). 86% of patients received pelvic teletherapy (median dose for the total patient population: 48 Gy) and 51% received brachytherapy. Overall survival after 5 years of patients with undifferentiated uterine sarcomas was 65% and 40% had loco-regional control. Multivariate analysis showed that in the total patient population (endometrial stromal sarcoma and undifferentiated uterine sarcoma) pelvic radiotherapy was associated with a significantly improved overall survival. However, because of the limited case numbers and the retrospective analysis it is not possible to draw definitive conclusions.

4.5 Treatment for metastasis and recurrence

There are some indications that certain recurrences are histologically heterogeneous (displaying aspects of both high- and low-grade tumors) and that in tumors with evidence of receptors, endocrine therapy only affects the low-grade part and not the high-grade part, although it is this high-grade component which ultimately determines prognosis [84].

In contrast to LG-ESS, endocrine therapy does not play any role.

As regards the use of chemotherapy, this tumor entity can be treated similarly to other high-grade soft tissue sarcomas, although overall specific data on this point are limited.

5 Uterine adenosarcoma

5.1 Introduction, clinical and diagnostic work-up

This rare entity occurs in patients of all ages [85] but peaks in the 6th and 7th decades of life.

According to the WHO classification, adenosarcomas (AS) are defined as mixed epithelial-mesenchymal tumors of the uterus composed of benign epithelial and malignant mesenchymal components [86, 87].

If the mesenchymal component corresponds to a high-grade sarcoma (high-grade polymorphism, a higher mitotic rate, possible myometrial or cervical stromal invasion and venous invasion with evidence of heterologous elements) and if this is detected in >25% of the tumor, the diagnosis is an AS with sarcomatous overgrowth [88].

5.2 Prognosis

The rate of recurrence for adenosarcoma without sarcomatous overgrowth is 15–25%, but this increases to 45–70% for patients with sarcomatous overgrowth. A higher rate of recurrence has also been reported for cases with deeper myometrial invasion, lymph node invasion, a highly malignant heterologous stromal component and/or extrauterine spread. The mortality rate for a typical adenosarcoma is 10–25%, but it can be as high as 75% for adenosarcoma with sarcomatous overgrowth.

5.3 Surgical treatment

As with other sarcomas, the treatment of choice is hysterectomy without morcellation. It is not clear whether the adnexa should also be removed.

The benefit of systematic pelvic and para-aortic lymphadenectomy is also not clear [66]. The probability of lymph node involvement is only 3–4% [89]. Because of this low incidence and the fact that in this analysis lymph node status has no impact on patient survival, systematic lymphadenectomy is not routinely recommended.

5.4 Adjuvant systemic therapy and radiotherapy

To date, no benefit has been reported for any adjuvant therapy. Based on 1884 cases in the National Cancer Database, chemotherapy has no effect on survival and postoperative radiotherapy even has a negative impact on survival [89].

As with other uterine sarcomas, neither adjuvant systemic therapy nor radiotherapy are currently indicated after complete surgical resection.

If surgical resection was incomplete or in cases with advanced disease, the treating physician should consider whether sarcomatous overgrowth is present and/or whether hormone receptor expression is present; subsequent treatment should be similar to that for HG-ESS or LG-ESS.

5.5 Treatment for metastasis and recurrence

Because of the lack of data, the approach should be similar to that used for other uterine sarcomas, and surgery with complete resection is recommended.

Radiotherapy may be used as palliation to treat local inoperable recurrence or postoperatively to treat isolated findings.

There is no optimal regimen for systemic therapy. Recurrence of adenosarcoma with sarcomatous overgrowth should be treated the same way as other high-grade sarcomas [90]. Recurrence of adenosarcoma without sarcomatous overgrowth but with hormone receptor expression should be treated the same way as LG-ESS.

6 Follow-up

Consensus-based Recommendation 7.E26

Expert consensus	Strength of consensus +++
In the first 2–3 years after primary therapy, patients must be regularly followed up every three months with follow-up consisting of speculum examination, vaginal and rectal examination and, if necessary, ultrasound.	

Consensus-based Recommendation 7.E27

Expert consensus	Strength of consensus +++
An additional diagnostic work-up for the early detection of metastasis may be beneficial.	

Follow-up serves to ensure the success to treatment and safeguard the patient's quality of life.

It is, however, not clear whether intervention following the early detection of unilocular recurrence leads to an improvement in overall survival.

Nevertheless, the use of imaging as part of the further diagnostic work-up for the early detection of metastasis may be beneficial (cf. the specific chapters on individual entities).

7 Morcellation

Consensus-based Recommendation 8.E28

Expert consensus	Strength of consensus +++
The use of morcellation techniques to remove uterine sarcomas results in a worse prognosis. Patients must be informed of this.	

Consensus-based Recommendation 8.E29

Expert consensus	Strength of consensus +++
Morcellation must not be carried out in a postmenopausal patient if the patient has been diagnosed with a newly developed "myoma", a large rapidly growing "myoma" or a "myoma" which has become symptomatic for the first time.	

Consensus-based Recommendation 8.E30

Expert consensus	Strength of consensus +++
Contained in-bag morcellation cannot not exclude the possibility of tumor cell dissemination.	

Consensus-based Recommendation 8.E31

Expert consensus	Strength of consensus +++
Patients who had a morcellation procedure to remove a uterine sarcoma must present to a DKG-certified gynecological cancer center very soon after morcellation.	

Consensus-based Recommendation 8.E32

Expert consensus	Strength of consensus +++
Adjuvant systemic therapy should not be generally carried out; nevertheless, because of the higher risk of recurrence after morcellation, systemic therapy should be considered depending on the histological subtype.	

Morcellation of what is assumed to be benign tissue can occur during uterus-preserving surgery for the management of fibroid myomas or during total and subtotal hysterectomy, although postoperative examination of the resected specimen may reclassify it as a uterine sarcoma. Morcellation of the uterus or of parts of the uterus such as myomas and body of the uterus can occur during both endoscopic and vaginal procedures.

The prevalence of undetected uterine sarcomas during hysterectomies and myomectomies as reported in the literature varies between 1/204 and 1/7400 (0.49–0.014%) [91]. A summary analysis of the rate of accidentally operated uterine sarcomas in 10 international studies with 8753 procedures resulted in an incidence of 0.24% [91]. A meta-analysis of 10 120 patients from 9 studies resulted in a comparable incidence of accidentally operated uterine sarcomas of 0.29% [92]. A German analysis carried out in 2017 of 475 morcellation procedures performed from 2004 to 2014 reported a risk of 0.35% (1/280) for the accidental morcellation of a previously unknown uterine sarcoma during hysterectomy and no case of uterine sarcoma detected during 195 myoma morcellations (0/195) [93]. Another German study of 10 731 LSH operations reported a rate of 0.06% uterine sarcomas and 0.07% endometrial carcinomas [94].

Endoscopic intraabdominal morcellation of undetected sarcomas during hysterectomy, conservative surgical management of uterine myomas and laparoscopic supracervical hysterectomy (LSH) have been particularly associated with worsening of the oncological prognosis in terms of recurrence-free survival and overall survival [91, 95–100].

In a systematic review of the literature and meta-analysis of 4 studies with 202 patients (75 with and 127 without morcellation) done in 2015, the rate of recurrence was higher after morcellation (62 vs. 39%; odds ratio [OR]: 3.16; 95% confidence interval [CI]: 1.38–7.26) as was the intraabdominal rate of recurrence (39 vs. 9%; OR: 4.11; 95% CI: 1.92–8.81). The overall survival rate after morcellation was also significantly lower (48 vs. 29%; OR: 2.42; 95% CI: 1.19–4.92) [101]. However, there was no difference in the extra-abdominal rate of recurrence. These data have been confirmed by other studies [102–106] but not by all [107–110]. All of the studies were retrospective observational studies.

There is very little data on the prognosis of patients who had accidental morcellation of a uterine malignancy during vaginal hysterectomy. Wasson et al. analyzed 2296 vaginal hysterectomies, with morcellation carried out in 611 cases [111]. The incidence of accidentally morcellated malignancies was 0.82% (5/611): 3 cases were endometrial carcinomas and 2 cases were sarcomas. There was no recurrence in 5/5 cases; mean disease-free survival was 48 months. Another analysis of more than 3000 hysterectomies which included a total of 18 sarcomas confirmed the observation that transvaginal morcellation does not increase the rate of recurrence [112].

It is not possible to definitively exclude uterine sarcomas preoperatively based on clinical symptoms, growth patterns, ultrasound, CT, PET-CT or MR [91, 113].

Caution is always warranted if risk factors are present. In addition to age, the most common, known risk factor for uterine sarcoma is ongoing or completed tamoxifen therapy [114]. In addition, hereditary tumor syndromes such as Li-Fraumeni syndrome (which is associated with sarcoma) or Lynch syndrome and PTEN syndrome (which are associated with endometrial carcinoma) are also contra-indications for morcellation [115].

The occurrence of sonographically visible or palpable uterine tumors in the postmenopausal period is unphysiological as is increased growth of a known “myoma”. Although none of these factors have been confirmed to be risk factors for uterine sarcoma,

either in isolation or in combination, from a clinical and pathophysiological perspective it may be wise to assume that such cases may have an increased risk of uterine sarcoma.

The use of contained in-bag morcellation to prevent the dissemination of malignant cells has been described in various studies [116–119]. However, the technique of in-bag morcellation has not been clinically validated yet, and it is therefore not possible to make a reliable statement about the oncological safety of this technique [91, 99, 100].

As regards the appropriate procedure after morcellation of a sarcoma, all further approaches should be guided by the statements made in the position paper of the German Society of Gynecology and Obstetrics [91] and international recommendations and statements [95–100]. The statements also apply to open or endoscopic tumor resections with or without morcellation [108]. The consensus is that the appropriate oncologic surgery recommended for the individual tumor entity should be carried out as soon as possible. It has not been confirmed whether this approach affects overall survival.

8 Information for Patients

Consensus-based Recommendation 9.E33

Expert consensus	Strength of consensus +++
Patients must be given the opportunity to include their partner or family members in talks and discussions.	

Consensus-based Recommendation 9.E34

Expert consensus	Strength of consensus +++
Patients should be informed about contacting self-help groups.	

Conflict of Interest

The authors' conflicts of interest are listed in the long version of the guideline.

References

- [1] Wittekind C, Meyer HJ. TNM-Klassifikation maligner Tumoren. Weinheim: Wiley-VHC Verlag; 2010
- [2] Oliva E, Carcangiu ML, Carinelli SG, Ip P, Loening T, Longacre TA, Nucci MR, Prat J, Zaloudek CJ. Mesenchymal Tumors of the Uterus. In: Kurman RJ, Carcangiu ML, Herrington CS, Young RH, eds. WHO Classification of Tumours of female reproductive Tract. Lyon: IARC Press; 2014: 135–147
- [3] Conklin CM, Longacre TA. Endometrial stromal tumors: the new WHO classification. *Adv Anat Pathol* 2014; 21: 383–393
- [4] Fletcher CDM, Bridge JA, Hogendoorn PCW, Mertens F. WHO Classification of soft Tissue and Bone. Lyon: IARC Press; 2013
- [5] McLuggage WG. Malignant biphasic uterine tumours: carcinosarcomas or metaplastic carcinomas? *J Clin Pathol* 2002; 55: 321–325
- [6] Lopez-Garcia MA, Palacios J. Pathologic and molecular features of uterine carcinosarcomas. *Semin Diagn Pathol* 2010; 27: 274–286

- [7] Leitlinienprogramm Onkologie (Deutsche Krebsgesellschaft, Deutsche Krebshilfe, AWMF). Diagnostik, Therapie und Nachsorge der Patientinnen mit Endometriumkarzinom, Langversion 1.0, 2018, AWMF Registernummer: 032/034-OL. Online: <http://www.leitlinienprogramm-onkologie.de/leitlinien/endometriumkarzinom/>; last access: 03.06.2019
- [8] Buttram VC jr., Reiter RC. Uterine leiomyomata: etiology, symptomatology, and management. *Fertil Steril* 1981; 36: 433–445
- [9] Parker WH, Fu YS, Berek JS. Uterine sarcoma in patients operated on for presumed leiomyoma and rapidly growing leiomyoma. *Obstet Gynecol* 1994; 83: 414–418
- [10] Amant F, Coosemans A, Debiec-Rychter M et al. Clinical management of uterine sarcomas. *Lancet Oncol* 2009; 10: 1188–1198
- [11] Coffey D, Kaplan AL, Ramzy I. Intraoperative consultation in gynecologic pathology. *Arch Pathol Lab Med* 2005; 129: 1544–1557
- [12] Otis CN, Ocampo AC, Nucci MR et al. Protocol for the Examination of Specimens From Patients With Sarcoma. 2013. Online: http://www.cap.org/apps/docs/committees/cancer/cancer_protocols/2013/UterineSarcomaProtocol_3000.pdf; last access: 27.08.2018
- [13] McCluggage WG, Fisher C, Hirschowitz L. Dataset for histological reporting of uterine sarcomas. 2014. Online: <http://www.rcpath.org/publications-media/publications/datasets/uterine-sarcomas>; last access: 27.08.2018
- [14] Koivisto-Korander R, Martinsen JI, Weiderpass E et al. Incidence of uterine leiomyosarcoma and endometrial stromal sarcoma in Nordic countries: results from NORDCAN and NOCCA databases. *Maturitas* 2012; 72: 56–60
- [15] Zaloudek CJ, Hendrickson MR, Soslow RA. Mesenchymal Tumors of the Uterus. In: Kurman RJ, Hedrick Ellenson L, Ronnett BM, eds. *Blaustein's Pathology of the female genital Tract*. 6th ed. New York, Dodrecht, Heidelberg, London: Springer; 2011
- [16] Skorstad M, Kent A, Lieng M. Preoperative evaluation in women with uterine leiomyosarcoma. A nationwide cohort study. *Acta Obstet Gynecol Scand* 2016; 95: 1228–1234
- [17] Oliva E. Cellular mesenchymal tumors of the uterus: a review emphasizing recent observations. *Int J Gynecol Pathol* 2014; 33: 374–384
- [18] Clement PB. The pathology of uterine smooth muscle tumors and mixed endometrial stromal-smooth muscle tumors: a selective review with emphasis on recent advances. *Int J Gynecol Pathol* 2000; 19: 39–55
- [19] D'Angelo E, Prat J. Uterine sarcomas: a review. *Gynecol Oncol* 2010; 116: 131–139
- [20] Ip PP, Cheung AN. Pathology of uterine leiomyosarcomas and smooth muscle tumours of uncertain malignant potential. *Best Pract Res Clin Obstet Gynaecol* 2011; 25: 691–704
- [21] Ly A, Mills AM, McKenney JK et al. Atypical leiomyomas of the uterus: a clinicopathologic study of 51 cases. *Am J Surg Pathol* 2013; 37: 643–649
- [22] Hart WR. Symposium 2: mesenchymal lesions of the uterus. *Histopathology* 2002; 41: 12–31
- [23] Toledo G, Oliva E. Smooth muscle tumors of the uterus: a practical approach. *Arch Pathol Lab Med* 2008; 132: 595–605
- [24] Pelmus M, Penault-Llorca F, Guillou L et al. Prognostic factors in early-stage leiomyosarcoma of the uterus. *Int J Gynecol Cancer* 2009; 19: 385–390
- [25] Iasonos A, Keung EZ, Zivanovic O et al. External validation of a prognostic nomogram for overall survival in women with uterine leiomyosarcoma. *Cancer* 2013; 119: 1816–1822
- [26] Garg G, Shah JP, Kumar S et al. Ovarian and uterine carcinosarcomas: a comparative analysis of prognostic variables and survival outcomes. *Int J Gynecol Cancer* 2010; 20: 888–894
- [27] Pritts EA, Parker WH, Brown J et al. Outcome of occult uterine leiomyosarcoma after surgery for presumed uterine fibroids: a systematic review. *J Minim Invasive Gynecol* 2015; 22: 26–33
- [28] Kapp DS, Shin JY, Chan JK. Prognostic factors and survival in 1396 patients with uterine leiomyosarcomas: emphasis on impact of lymphadenectomy and oophorectomy. *Cancer* 2008; 112: 820–830
- [29] Nasioudis D, Chapman-Davis E, Frey M et al. Safety of ovarian preservation in premenopausal women with stage I uterine sarcoma. *J Gynecol Oncol* 2017; 28: e46
- [30] Leitao MM, Sonoda Y, Brennan MF et al. Incidence of lymph node and ovarian metastases in leiomyosarcoma of the uterus. *Gynecol Oncol* 2003; 91: 209–212
- [31] Seagle BL, Sobocki-Rausch J, Strohl AE et al. Prognosis and treatment of uterine leiomyosarcoma: A National Cancer Database study. *Gynecol Oncol* 2017; 145: 61–70
- [32] Bogani G, Fuca G, Maltese G et al. Efficacy of adjuvant chemotherapy in early stage uterine leiomyosarcoma: A systematic review and meta-analysis. *Gynecol Oncol* 2016; 143: 443–447
- [33] Pautier P, Floquet A, Gladieff L et al. A randomized clinical trial of adjuvant chemotherapy with doxorubicin, ifosfamide, and cisplatin followed by radiotherapy versus radiotherapy alone in patients with localized uterine sarcomas (SARCCYN study). A study of the French Sarcoma Group. *Ann Oncol* 2013; 24: 1099–1104
- [34] Hensley ML, Ishill N, Soslow R et al. Adjuvant gemcitabine plus docetaxel for completely resected stages I–IV high grade uterine leiomyosarcoma: Results of a prospective study. *Gynecol Oncol* 2009; 112: 563–567
- [35] Hensley ML, Wathen JK, Maki RG et al. Adjuvant therapy for high-grade, uterus-limited leiomyosarcoma: results of a phase 2 trial (SARC 005). *Cancer* 2013; 119: 1555–1561
- [36] Reed NS, Mangioni C, Malmström H et al.; European Organisation for Research and Treatment of Cancer Gynaecological Cancer Group. Phase III randomised study to evaluate the role of adjuvant pelvic radiotherapy in the treatment of uterine sarcomas stages I and II: an European Organisation for Research and Treatment of Cancer Gynaecological Cancer Group Study (protocol 55874). *Eur J Cancer* 2008; 44: 808–818
- [37] Bernstein-Molho R, Grisaro D, Soyfer V et al. Metastatic uterine leiomyosarcomas: a single-institution experience. *Int J Gynecol Cancer* 2010; 20: 255–260
- [38] Leitao MM, Brennan MF, Hensley M et al. Surgical resection of pulmonary and extrapulmonary recurrences of uterine leiomyosarcoma. *Gynecol Oncol* 2002; 87: 287–294
- [39] Levenback C, Rubin SC, McCormack PM et al. Resection of pulmonary metastases from uterine sarcomas. *Gynecol Oncol* 1992; 45: 202–205
- [40] Weiser MR, Downey RJ, Leung DH et al. Repeat resection of pulmonary metastases in patients with soft-tissue sarcoma. *J Am Coll Surg* 2000; 191: 184–190; discussion 190–181
- [41] Giuntoli RL 2nd, Garrett-Mayer E, Bristow RE et al. Secondary cytoreduction in the management of recurrent uterine leiomyosarcoma. *Gynecol Oncol* 2007; 106: 82–88
- [42] Sutton GP, Blessing JA, Barrett RJ et al. Phase II trial of ifosfamide and mesna in leiomyosarcoma of the uterus: a Gynecologic Oncology Group study. *Am J Obstet Gynecol* 1992; 166: 556–559
- [43] Look KY, Sandler A, Blessing JA et al.; Gynecologic Oncology Group (GOG) Study. Phase II trial of gemcitabine as second-line chemotherapy of uterine leiomyosarcoma: a Gynecologic Oncology Group (GOG) Study. *Gynecol Oncol* 2004; 92: 644–647
- [44] Thigpen T, Blessing JA, Yordan E et al. Phase II trial of etoposide in leiomyosarcoma of the uterus: a Gynecologic Oncology Group study. *Gynecol Oncol* 1996; 63: 120–122
- [45] Rose PG, Blessing JA, Soper JT et al. Prolonged oral etoposide in recurrent or advanced leiomyosarcoma of the uterus: a gynecologic oncology group study. *Gynecol Oncol* 1998; 70: 267–271
- [46] Miller DS, Blessing JA, Kilgore LC et al. Phase II trial of topotecan in patients with advanced, persistent, or recurrent uterine leiomyosarcomas: a Gynecologic Oncology Group Study. *Am J Clin Oncol* 2000; 23: 355–357

- [47] Gallup DG, Blessing JA, Andersen W et al.; Gynecologic Oncology Group Study. Evaluation of paclitaxel in previously treated leiomyosarcoma of the uterus: a gynecologic oncology group study. *Gynecol Oncol* 2003; 89: 48–51
- [48] Sutton G, Blessing JA, Malfetano JH. Ifosfamide and doxorubicin in the treatment of advanced leiomyosarcomas of the uterus: a Gynecologic Oncology Group study. *Gynecol Oncol* 1996; 62: 226–229
- [49] Hensley ML, Maki R, Venkatraman E et al. Gemcitabine and docetaxel in patients with unresectable leiomyosarcoma: results of a phase II trial. *J Clin Oncol* 2002; 20: 2824–2831
- [50] Gupta AA, Yao X, Verma S et al.; Sarcoma Disease Site Group and the Gynecology Cancer Disease Site Group. Systematic chemotherapy for inoperable, locally advanced, recurrent, or metastatic uterine leiomyosarcoma: a systematic review. *Clin Oncol (R Coll Radiol)* 2013; 25: 346–355
- [51] Maki RG, Wathen JK, Patel SR et al. Randomized phase II study of gemcitabine and docetaxel compared with gemcitabine alone in patients with metastatic soft tissue sarcomas: results of sarcoma alliance for research through collaboration study 002 [corrected]. *J Clin Oncol* 2007; 25: 2755–2763
- [52] Pautier P, Floquet A, Penel N et al. Randomized multicenter and stratified phase II study of gemcitabine alone versus gemcitabine and docetaxel in patients with metastatic or relapsed leiomyosarcomas: a Federation Nationale des Centres de Lutte Contre le Cancer (FNCLCC) French Sarcoma Group Study (TAXOGEM study). *Oncologist* 2012; 17: 1213–1220
- [53] Seddon B, Strauss SJ, Whelan J et al. Gemcitabine and docetaxel versus doxorubicin as first-line treatment in previously untreated advanced unresectable or metastatic soft-tissue sarcomas (GeDDiS): a randomised controlled phase 3 trial. *Lancet Oncol* 2017; 18: 1397–1410
- [54] Demetri GD, Chawla SP, von Mehren M et al. Efficacy and safety of trabectedin in patients with advanced or metastatic liposarcoma or leiomyosarcoma after failure of prior anthracyclines and ifosfamide: results of a randomized phase II study of two different schedules. *J Clin Oncol* 2009; 27: 4188–4196
- [55] van der Graaf WT, Blay JY, Chawla SP et al.; EORTC Soft Tissue and Bone Sarcoma Group; PALETTE study group. Pazopanib for metastatic soft-tissue sarcoma (PALETTE): a randomised, double-blind, placebo-controlled phase 3 trial. *Lancet* 2012; 379: 1879–1886
- [56] Chew I, Oliva E. Endometrial stromal sarcomas: a review of potential prognostic factors. *Adv Anat Pathol* 2010; 17: 113–121
- [57] Chang KL, Crabtree GS, Lim-Tan SK et al. Primary uterine endometrial stromal neoplasms. A clinicopathologic study of 117 cases. *Am J Surg Pathol* 1990; 14: 415–438
- [58] Barney B, Tward JD, Skidmore T et al. Does radiotherapy or lymphadenectomy improve survival in endometrial stromal sarcoma? *Int J Gynecol Cancer* 2009; 19: 1232–1238
- [59] Park JY, Baek MH, Park Y et al. Investigation of hormone receptor expression and its prognostic value in endometrial stromal sarcoma. *Virchows Arch* 2018; 473: 61–69
- [60] Chu MC, Mor G, Lim C et al. Low-grade endometrial stromal sarcoma: hormonal aspects. *Gynecol Oncol* 2003; 90: 170–176
- [61] Einstein MH, Barakat RR, Chi DS et al. Management of uterine malignancy found incidentally after supracervical hysterectomy or uterine morcellation for presumed benign disease. *Int J Gynecol Cancer* 2008; 18: 1065–1070
- [62] Chan JK, Kawar NM, Shin JY et al. Endometrial stromal sarcoma: a population-based analysis. *Br J Cancer* 2008; 99: 1210–1215
- [63] Bai H, Yang J, Cao D et al. Ovary and uterus-sparing procedures for low-grade endometrial stromal sarcoma: a retrospective study of 153 cases. *Gynecol Oncol* 2014; 132: 654–660
- [64] Shah JP, Bryant CS, Kumar S et al. Lymphadenectomy and ovarian preservation in low-grade endometrial stromal sarcoma. *Obstet Gynecol* 2008; 112: 1102–1108
- [65] Si M, Jia L, Song K et al. Role of Lymphadenectomy for Uterine Sarcoma: A Meta-Analysis. *Int J Gynecol Cancer* 2017; 27: 109–116
- [66] Gadducci A, Cosio S, Romanini A et al. The management of patients with uterine sarcoma: a debated clinical challenge. *Crit Rev Oncol Hematol* 2008; 65: 129–142
- [67] Yamaguchi M, Erdenebaatar C, Saito F et al. Long-Term Outcome of Aromatase Inhibitor Therapy With Letrozole in Patients With Advanced Low-Grade Endometrial Stromal Sarcoma. *Int J Gynecol Cancer* 2015; 25: 1645–1651
- [68] Amant F, De Knijf A, Van Calster B et al. Clinical study investigating the role of lymphadenectomy, surgical castration and adjuvant hormonal treatment in endometrial stromal sarcoma. *Br J Cancer* 2007; 97: 1194–1199
- [69] Sampath S, Schultheiss TE, Ryu JK et al. The role of adjuvant radiation in uterine sarcomas. *Int J Radiat Oncol Biol Phys* 2010; 76: 728–734
- [70] Piver MS, Rutledge FN, Copeland L et al. Uterine endolymphatic stromal myosis: a collaborative study. *Obstet Gynecol* 1984; 64: 173–178
- [71] Nam JH. Surgical treatment of uterine sarcoma. *Best Pract Res Clin Obstet Gynaecol* 2011; 25: 751–760
- [72] Weitmann HD, Knocke TH, Kucera H et al. Radiation therapy in the treatment of endometrial stromal sarcoma. *Int J Radiat Oncol Biol Phys* 2001; 49: 739–748
- [73] Kortmann B, Reimer T, Gerber B et al. Concurrent radiochemotherapy of locally recurrent or advanced sarcomas of the uterus. *Strahlenther Onkol* 2006; 182: 318–324
- [74] Cheng X, Yang G, Schmeler KM et al. Recurrence patterns and prognosis of endometrial stromal sarcoma and the potential of tyrosine kinase-inhibiting therapy. *Gynecol Oncol* 2011; 121: 323–327
- [75] Dahhan T, Fons G, Buist MR et al. The efficacy of hormonal treatment for residual or recurrent low-grade endometrial stromal sarcoma. A retrospective study. *Eur J Obstet Gynecol Reprod Biol* 2009; 144: 80–84
- [76] Maluf FC, Sabbatini P, Schwartz L et al. Endometrial stromal sarcoma: objective response to letrozole. *Gynecol Oncol* 2001; 82: 384–388
- [77] Pink D, Lindner T, Mrozek A et al. Harm or benefit of hormonal treatment in metastatic low-grade endometrial stromal sarcoma: single center experience with 10 cases and review of the literature. *Gynecol Oncol* 2006; 101: 464–469
- [78] Thanopoulou E, Aleksic A, Thway K et al. Hormonal treatments in metastatic endometrial stromal sarcomas: the 10-year experience of the sarcoma unit of Royal Marsden Hospital. *Clin Sarcoma Res* 2015; 5: 8
- [79] Hendrickson MA, Tavassoli FA, Kempson RL, McCluggage WG, Haller U, Kubik-Huch RA. Mesenchymal Tumors and related Lesions. In: Tavassoli FA, Devilee P, eds. *Pathology and Genetics of Tumours of the Breast and female genital Organs World Health Organization Classification of Tumours*. IARC Press; 2003: 233–249. Online: <https://www.iarc.fr/wp-content/uploads/2018/07/BB4.pdf>; last access: 03.06.2019
- [80] Benson C, Miah AB. Uterine sarcoma – current perspectives. *Int J Womens Health* 2017; 9: 597–606
- [81] Malouf GG, Lhomme C, Duvillard P et al. Prognostic factors and outcome of undifferentiated endometrial sarcoma treated by multimodal therapy. *Int J Gynaecol Obstet* 2013; 122: 57–61
- [82] Tanner EJ, Garg K, Leitao MM jr. et al. High grade undifferentiated uterine sarcoma: surgery, treatment, and survival outcomes. *Gynecol Oncol* 2012; 127: 27–31
- [83] Schick U, Bolukbasi Y, Thariat J et al. Outcome and prognostic factors in endometrial stromal tumors: a Rare Cancer Network study. *Int J Radiat Oncol Biol Phys* 2012; 82: e757–e763
- [84] Baniak N, Adams S, Lee CH et al. Extrapelvic Metastases in Endometrial Stromal Sarcomas: A Clinicopathological Review With Immunohistochemical and Molecular Characterization. *Int J Surg Pathol* 2019; 27: 208–215. doi:10.1177/1066896918794278

- [85] Fleming NA, Hopkins L, de Nanassy J et al. Mullerian adenosarcoma of the cervix in a 10-year-old girl: case report and review of the literature. *J Pediatr Adolesc Gynecol* 2009; 22: e45–e51
- [86] McCluggage WG. Mullerian adenosarcoma of the female genital tract. *Adv Anat Pathol* 2010; 17: 122–129
- [87] Wells M, Oliva E, Palacios J, Prat J. Mixed epithelial and mesenchymal Tumors of the Uterus. In: Kurman RJ, Carcangiu ML, Herrington CS, Young RH, eds. *WHO Classification of Tumours of female reproductive Tract*. Lyon: IARC Press; 2014: 148–151
- [88] McCluggage WG, Fisher C, Hirschowitz L. Dataset for histological reporting of uterine sarcomas. 2016. Online: <http://www.rcpath.org/publications-media/publications/datasets/uterine-sarcomas>; last access: 27.08.2018
- [89] Seagle BL, Kanis M, Strohl AE et al. Survival of women with Mullerian adenosarcoma: A National Cancer Data Base study. *Gynecol Oncol* 2016; 143: 636–641
- [90] Tanner EJ, Toussaint T, Leitao MM jr. et al. Management of uterine adenosarcomas with and without sarcomatous overgrowth. *Gynecol Oncol* 2013; 129: 140–144
- [91] Beckmann MW, Juhasz-Boss I, Denschlag D et al. Surgical Methods for the Treatment of Uterine Fibroids – Risk of Uterine Sarcoma and Problems of Morcellation: Position Paper of the DGGG. *Geburtsh Frauenheilk* 2015; 75: 148–164
- [92] Brohl AS, Li L, Andikyan V et al. Age-stratified risk of unexpected uterine sarcoma following surgery for presumed benign leiomyoma. *Oncologist* 2015; 20: 433–439
- [93] Kundu S, Zachen M, Hertel H et al. Sarcoma Risk in Uterine Surgery in a Tertiary University Hospital in Germany. *Int J Gynecol Cancer* 2017; 27: 961–966
- [94] Bojahr B, De Wilde RL, Tchartchian G. Malignancy rate of 10,731 uteri morcellated during laparoscopic supracervical hysterectomy (LASH). *Arch Gynecol Obstet* 2015; 292: 665–672
- [95] [Anonym]. Statement of the Society of Gynecologic Oncology to the Food and Drug Administration's Obstetrics and Gynecology Medical Devices Advisory Committee Concerning Safety of Laparoscopic Power Morcellation. 2014. Online: <https://www.sgo.org/wp-content/uploads/2014/04/SGO-Testimony-to-FDA-on-Power-Morcellation-FINAL.pdf>; last access: 20.07.2018
- [96] Halaska MJ, Haidopoulos D, Guyon F et al. European Society of Gynecological Oncology Statement on Fibroid and Uterine Morcellation. *Int J Gynecol Cancer* 2017; 27: 189–192
- [97] [Anonym]. AAGL Advancing Minimally Invasive Gynecology Worldwide. Morcellation During Uterine Tissue Extraction. 2014. Online: https://www.aagl.org/wp-content/uploads/2014/05/Tissue_Extraction_TFR.pdf; last access: 20.07.2018
- [98] US Food and Drug Administration. FDA Updated Assessment of The Use of Laparoscopic Power Morcellators to Treat Uterine Fibroids. 2017. Online: <https://www.fda.gov/downloads/MedicalDevices/ProductsandMedicalProcedures/SurgeryandLifeSupport/UCM584539.pdf>; last access: 20.07.2018
- [99] Sizzi O, Manganaro L, Rossetti A et al. Assessing the risk of laparoscopic morcellation of occult uterine sarcomas during hysterectomy and myomectomy: Literature review and the ISGE recommendations. *Eur J Obstet Gynecol Reprod Biol* 2018; 220: 30–38
- [100] Singh SS, Scott S, Bougie O et al.; SOGC Clinical Practice-Gynaecology Committee; GOC Executive Committee. Technical update on tissue morcellation during gynaecologic surgery: its uses, complications, and risks of unsuspected malignancy. *J Obstet Gynaecol Can* 2015; 37: 68–81
- [101] Bogani G, Cliby WA, Aletti GD. Impact of morcellation on survival outcomes of patients with unexpected uterine leiomyosarcoma: a systematic review and meta-analysis. *Gynecol Oncol* 2015; 137: 167–172
- [102] George S, Barysaukas C, Serrano C et al. Retrospective cohort study evaluating the impact of intraperitoneal morcellation on outcomes of localized uterine leiomyosarcoma. *Cancer* 2014; 120: 3154–3158
- [103] Park JY, Park SK, Kim DY et al. The impact of tumor morcellation during surgery on the prognosis of patients with apparently early uterine leiomyosarcoma. *Gynecol Oncol* 2011; 122: 255–259
- [104] Raspagliesi F, Maltese G, Bogani G et al. Morcellation worsens survival outcomes in patients with undiagnosed uterine leiomyosarcomas: A retrospective MITO group study. *Gynecol Oncol* 2017; 144: 90–95
- [105] Raine-Bennett T, Tucker LY, Zaritsky E et al. Occult Uterine Sarcoma and Leiomyosarcoma: Incidence of and Survival Associated With Morcellation. *Obstet Gynecol* 2016; 127: 29–39
- [106] Lin KH, Torng PL, Tsai KH et al. Clinical outcome affected by tumor morcellation in unexpected early uterine leiomyosarcoma. *Taiwan J Obstet Gynecol* 2015; 54: 172–177
- [107] Nemeč W, Inwald EC, Buchholz S et al. Effects of morcellation on long-term outcomes in patients with uterine leiomyosarcoma. *Arch Gynecol Obstet* 2016; 294: 825–831
- [108] Lee JY, Kim HS, Nam EJ et al. Outcomes of uterine sarcoma found incidentally after uterus-preserving surgery for presumed benign disease. *BMC Cancer* 2016; 16: 675
- [109] Gao Z, Li L, Meng Y. Correction: A Retrospective Analysis of the Impact of Myomectomy on Survival in Uterine Sarcoma. *PLoS One* 2016; 11: e0153996
- [110] Gao Z, Li L, Meng Y. A Retrospective Analysis of the Impact of Myomectomy on Survival in Uterine Sarcoma. *PLoS One* 2016; 11: e0148050
- [111] Wasson M, Magtibay P 2nd, Magtibay P 3rd et al. Incidence of Occult Uterine Malignancy Following Vaginal Hysterectomy With Morcellation. *J Minim Invasive Gynecol* 2017; 24: 665–669
- [112] Zhang J, Li T, Zhang J et al. Clinical Characteristics and Prognosis of Unexpected Uterine Sarcoma After Hysterectomy for Presumed Myoma With and Without Transvaginal Scalpel Morcellation. *Int J Gynecol Cancer* 2016; 26: 456–463
- [113] Ebner F, Friedl TW, Scholz C et al. Is open surgery the solution to avoid morcellation of uterine sarcomas? A systematic literature review on the effect of tumor morcellation and surgical techniques. *Arch Gynecol Obstet* 2015; 292: 499–506
- [114] Wickerham DL, Fisher B, Wolmark N et al. Association of tamoxifen and uterine sarcoma. *J Clin Oncol* 2002; 20: 2758–2760
- [115] Schmeler KM, Lynch HT, Chen LM et al. Prophylactic surgery to reduce the risk of gynecologic cancers in the Lynch syndrome. *N Engl J Med* 2006; 354: 261–269
- [116] Leal MA, Pinera A, De Santiago J et al. Novel Technique for Contained Power Morcellation through Umbilicus with Insufflated Bag. *Gynecol Obstet Invest* 2017; 82: 205–207
- [117] McKenna JB, Kanade T, Choi S et al. The Sydney Contained In Bag Morcellation technique. *J Minim Invasive Gynecol* 2014; 21: 984–985
- [118] Frasca C, Degli Esposti E, Arena A et al. Can In-Bag Manual Morcellation Represent an Alternative to Uncontained Power Morcellation in Laparoscopic Myomectomy? A Randomized Controlled Trial. *Gynecol Obstet Invest* 2018; 83: 52–56
- [119] Venturella R, Rocca ML, Lico D et al. In-bag manual versus uncontained power morcellation for laparoscopic myomectomy: randomized controlled trial. *Fertil Steril* 2016; 105: 1369–1376

Guideline Program

Editors

Leading Professional Medical Associations



**German Society of Gynecology and Obstetrics
(Deutsche Gesellschaft für Gynäkologie
und Geburtshilfe e. V. [DGGG])**

Head Office of DGGG and Professional Societies
Hausvogteiplatz 12, DE-10117 Berlin
info@dggg.de
<http://www.dggg.de/>

President of DGGG

Prof. Dr. med. Anton Scharl
Direktor der Frauenkliniken
Klinikum St. Marien Amberg
Mariahilfbergweg 7, DE-92224 Amberg
Kliniken Nordoberpfalz AG
Söllnerstraße 16, DE-92637 Weiden

DGGG Guidelines Representatives

Prof. Dr. med. Matthias W. Beckmann
Universitätsklinikum Erlangen, Frauenklinik
Universitätsstraße 21–23, DE-91054 Erlangen

Prof. Dr. med. Erich-Franz Solomayer
Universitätsklinikum des Saarlandes
Geburtshilfe und Reproduktionsmedizin
Kirrberger Straße, Gebäude 9, DE-66421 Homburg

Guidelines Coordination

Dr. med. Paul Gaß, Dr. med. Gregor Olmes, Christina Meixner
Universitätsklinikum Erlangen, Frauenklinik
Universitätsstraße 21–23, DE-91054 Erlangen
fk-dggg-leitlinien@uk-erlangen.de
<http://www.dggg.de/leitlinienstellungennahmen>



**Austrian Society of Gynecology and Obstetrics
(Österreichische Gesellschaft für Gynäkologie
und Geburtshilfe [OEGGG])**

Frankgasse 8, AT-1090 Wien
stephanie.leutgeb@oeggg.at
<http://www.oeggg.at>

President of OEGGG

Prof. Dr. med. Petra Kohlberger
Universitätsklinik für Frauenheilkunde Wien
Währinger Gürtel 18–20, AT-1090 Wien

OEGGG Guidelines Representatives

Prof. Dr. med. Karl Tamussino
Universitätsklinik für Frauenheilkunde und Geburtshilfe Graz
Auenbruggerplatz 14, AT-8036 Graz

Prof. Dr. med. Hanns Helmer
Universitätsklinik für Frauenheilkunde Wien
Währinger Gürtel 18–20, AT-1090 Wien



**Swiss Society of Gynecology and Obstetrics
(Schweizerische Gesellschaft für Gynäkologie
und Geburtshilfe [SGGG])**

Gynécologie Suisse SGGG
Altenbergstraße 29, Postfach 6, CH-3000 Bern 8
sekretariat@sggg.ch
<http://www.sggg.ch/>

President of SGGG

Dr. med. Irène Dingeldein
Längmatt 32, CH-3280 Murten

SGGG Guidelines Representatives

Prof. Dr. med. Daniel Surbek
Universitätsklinik für Frauenheilkunde
Geburtshilfe und feto-maternale Medizin
Inselspital Bern
Effingerstraße 102, CH-3010 Bern

Prof. Dr. med. René Hornung
Kantonsspital St. Gallen, Frauenklinik
Rorschacher Straße 95, CH-9007 St. Gallen