

# Feasibility of endoscopic submucosal dissection of lesions at anastomosis site post-colorectal surgery: a case series




## Authors

Chonlada Krutsri<sup>1,2</sup>, Takashi Toyonaga<sup>3,4</sup>, Tsukasa Ishida<sup>1,5</sup>, Namiko Hoshi<sup>1</sup>, Shinichi Baba<sup>4</sup>, Nelson Tomio Miyajima<sup>6</sup>, Yuzo Kodama<sup>1</sup>

## Institutions

- 1 Division of Gastroenterology, Department of Internal Medicine, Graduate School of Medicine, Kobe University, Kobe, Japan
- 2 Department of Surgery, Faculty of Medicine Ramathibodi Hospital, Mahidol University, Bangkok, Thailand
- 3 Department of Endoscopy, Kobe University Hospital, Kobe, Japan
- 4 Department of Gastroenterology, Kishiwada Tokushukai Hospital, Osaka, Japan
- 5 Department of Gastroenterology, Akashi Medical Center, Akashi, Japan
- 6 Endoscopia Digestiva no Serviço de Endoscopia Gastrointestinal e Broncoesofagoscopia do Hospital das Clínicas da Faculdade de Medicina da Universidade de São Paulo, São Paulo, Brazil

submitted 5.11.2018

accepted after revision 26.2.2019

## Bibliography

DOI <https://doi.org/10.1055/a-0903-2403> |  
Endoscopy International Open 2019; 07: E949–E954  
© Georg Thieme Verlag KG Stuttgart · New York  
eISSN 2196-9736

## Corresponding author

Takashi Toyonaga, MD, PhD, Department of Endoscopy, Kobe University Hospital, 7-5-1 Kusunoki-cho, Chuo-ku, Kobe, Japan  
Fax: +81-78-3826309  
[toyonaga@med.kobe-u.ac.jp](mailto:toyonaga@med.kobe-u.ac.jp)

## ABSTRACT

**Background and study aims** Patients who have undergone colorectal surgery for resection of cancer and benign lesions are at risk for recurrent, residual, or metachronous lesions at the anastomosis site. Surgical resection of such lesions is difficult because of adhesions, and a stoma may be required as there are risks for leakage after resection. The feasibility and safety of endoscopic submucosal dissection (ESD) for these lesions remain unknown. Therefore, this case series aimed to examine the feasibility and safety of ESD by evaluating the clinical outcomes.

**Patients and methods** We retrospectively investigated five patients who underwent ESD by a single expert for superficial neoplastic lesions at the anastomosis site after previous colorectal surgery.

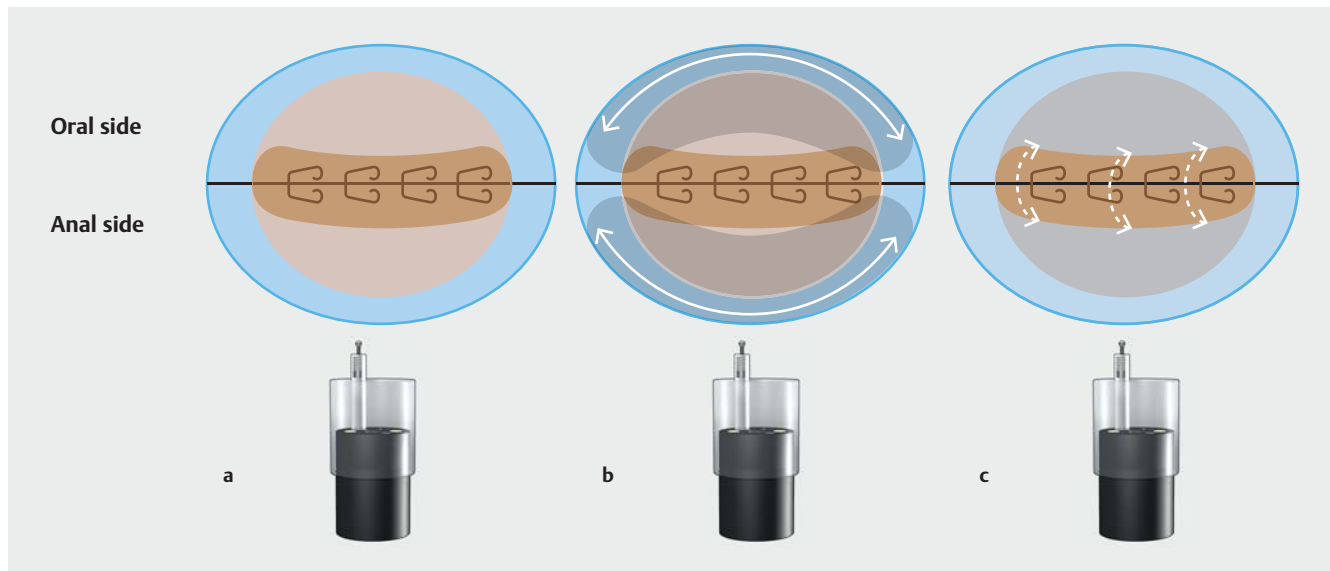
**Results** R0 resections were achieved for all lesions. Mean procedure time was 160.6 minutes. Mean dimensions of the resected specimen and tumor were 52.4mm and 31.8mm, respectively. None of the patients had complications or recurrence after surveillance colonoscopy 1-year post-resection.

**Conclusions** In an expert's hands, ESD at the anastomosis site might be feasible minimally invasive treatment for superficial neoplastic lesions.

## Introduction

Endoscopic submucosal dissection (ESD) is accepted as a minimally invasive treatment for superficial colorectal neoplasm [1, 2]. ESD has been reported to have a high rate of en bloc resection with good long-term outcome, irrespective of size and morphology [1, 3–6]. Patients who have undergone colorectal

resection for cancer or benign lesions, such as familial adenomatous polyposis (FAP) and ulcerative colitis (UC), are still at risk of developing recurrent, residual, or metachronous lesions in the residual colon, including the anastomosis site (AS). For lesions at the AS, resection by ESD should be technically more difficult than a regular site due to severe fibrosis and presence



► **Fig. 1** Basic strategy of endoscopic submucosal dissection at the AS when the tumor lesion spreads over the anastomosis line with staples. Beige, tumor; dark beige, severely fibrosed area; light blue, background normal mucosa. **a** Tumor spread to both the oral and anal sides of the anastomosis line. **b** Mucosal incision is initiated from the non-fibrotic mucosa (white line), and submucosal dissection proceeds along the tumor. A complete mucosal flap is created by dissecting the submucosal layer in the mildly fibrosed or non-fibrosed area (gray-shaded area). **c** Finally, the severely fibrosed area (dark beige) is dissected in the direction of the white dotted line to complete tumor removal.

of staples from the previous surgery. Surgical resection can be also difficult based in the case of adhesions, and a stoma may be required [7]. ESD for lesions at the AS may have advantages for minimally invasive treatment, therefore, we report on our technical tips and outcome of ESD.

## Patients and methods

### Patients

We conducted a retrospective review of five patients with superficial neoplastic lesions on the AS after colorectal resection, who underwent ESD at our hospital and affiliated hospitals between July 2007 and March 2017. The ESDs were performed by a single highly experienced endoscopist. A tumor developing on the AS or a lesion spanning into the AS is defined as “a tumor at the AS.” Indications for ESD based on the colorectal ESD/Endoscopic mucosal resection guidelines were issued by the Japan Gastroenterological Endoscopy Society [2]. Informed consent was obtained from all patients before the procedure, after explained patients for the procedure, results, and possible complications such as perforations.

### ESD equipment and procedure

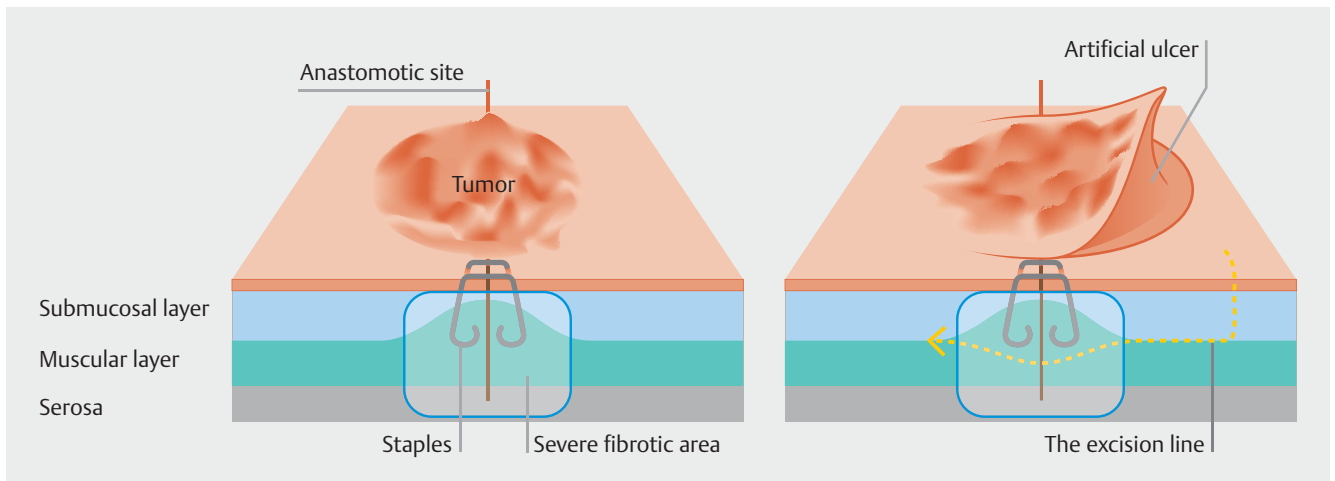
The procedures were performed using a single-channel endoscope (PCF-Q260, GIF-Q240, or GIF-H260; Olympus Corporation, Tokyo, Japan) with FlushKnife BT 1.5 mm (DK2620J-B15S; FTS, Tokyo, Japan) and FlushKnife N 1 mm (DK2620J-N10S; Fujifilm Medical Co., Ltd., Tokyo, Japan). A small-caliber-tip transparent hood (ST Hood) (DH-28GR; Fujifilm Medical Co., Ltd., Tokyo, Japan) or a transparent hood with slit and hole (F-25 or F-40; Top Co., Ltd. Tokyo, Japan) was used to maintain good visibility in the operative field. In all cases, 0.4% sodium hyaluro-

nate (MucoUp, Boston Scientific Co., Tokyo, Japan) was used for submucosal lifting. Procedure time was defined as the time between mucosal injection and complete resection. Four patients underwent ESD under conscious sedation and one patient under general anesthesia.

Mucosal incision started from the anal to oral site of the non-fibrotic area, and the submucosal layer was opened. A mucosal flap of the normal mucosa, which was further from the tumor margin (approximately 5–10 mm) in contrast to that in conventional ESD, was created. Finally, the severely fibrosed part was dissected to connect both ends of the non-fibrotic areas (► **Fig. 1**). Swift Coag Effect 2, 50–100 W or Drycut mode Effect 3, 100 W of VIO 300 D (ERBE Elektromedizin, Tübingen, Germany) was used to dissect the severely fibrotic parts. After exposing, the staples were removed using biopsy forceps to the greatest extent possible, because of a probability of high-frequency current being conducted from the target lesion to the staples, which have a low electrical resistance. In cases where staple removal was difficult, the excision line was made below the staples within the thickened muscularis propria due to anastomosis [8]. This was carefully performed with a FlushKnife N 1.0-mm device, which has the shortest electrode knife, to avoid the damage to the deep muscle layer (► **Fig. 2**).

## Results

ESD was performed in five patients (► **Table 1**) with lesions at the AS. Two patients had residue from surgical resection performed for removal of a superficial rectal neoplasm. The remaining three patients had metachronous lesions that had developed from FAP and UC. R0 en bloc resection was achieved in all cases. No patient had bleeding with need for endoscopic he-



► **Fig. 2** The appropriate excision line for the anastomotic site. The excision line (yellow dash line) at the anastomotic site was made below the staples within the thickened muscle layer.

mostasis or perforations with free intraperitoneal gas that could be detected on a plain radiograph. Mean procedure time was 160.6 minutes. Mean dimensions of the resected specimen and tumor were 52.4×32.8mm and 31.8×18.8 mm, respectively. All patients were discharged to their homes within 1 week after ESD. No recurrence was found during the 1-year surveillance colonoscopy. There was no stenosis after ESD except Case #5 in which the patient had a circumferential lesion. However, the stenosis was improved by weekly balloon dilatation and daily digital self-dilatation after 3 months.

In Case #1, the patient previously underwent laparoscopic right hemicolectomy with low anterior resection for large mucosal neoplasms in the hepatic flexure and rectum. One year later, residual rectal lesions at the AS were detected and removed by two transanal resections. However, two skipped recurrent lesions appeared at the AS. The patient underwent ESD procedure for these lesions. ► **Fig. 3** shows representative endoscopic images from Case #1. ► **Video 1** shows the ESD procedure for Case #1.

## Discussion

After oncologic resection, patients with colorectal cancer still have a high risk of developing recurrent, residual, or metachronous lesions. FAP and UC are notorious for increasing risk of developing colorectal cancer [1,9]. In these cases, we reviewed five patients who underwent ESD for superficial neoplastic lesions at the AS. ESD may be a good treatment option, as it is minimally invasive and can prevent complications from surgery. Re-operation in these patients is technically difficult because of multiple adhesions. Furthermore, four patients had lesions in the narrow pelvic cavity that are difficult to operate on. Ileoanal anastomosis surgery after subtotal colectomy is a common procedure for treatment of UC to prevent cancer recurrence. However, it can affect defecation function and cause significant deterioration in quality of life [10]. Therefore, ESD may be a

better procedure for preserving defecation function compared to reoperation, such as in Case #3.

Two patients underwent subtotal colectomy with ileorectal J-pouch anastomosis, one patient underwent total proctocolectomy, and one patient underwent right hemicolectomy. ESD on the ileal side was difficult because the ileum wall is thinner than the colorectal wall. Particularly, the lesion in Case #2 required careful handling, because it was located at the anastomosis of the transverse colon and the ileum which, if perforated, can lead to leakage into the intraperitoneal cavity [11]. For this case, due to the tumor location, surgery is assumed to be relatively easier and safer compared with cases requiring low rectal anastomosis. Therefore, if it is judged that ESD is technically difficult with some conditions of adhesions and unstable endoscopic maneuverability, surgery should be considered.

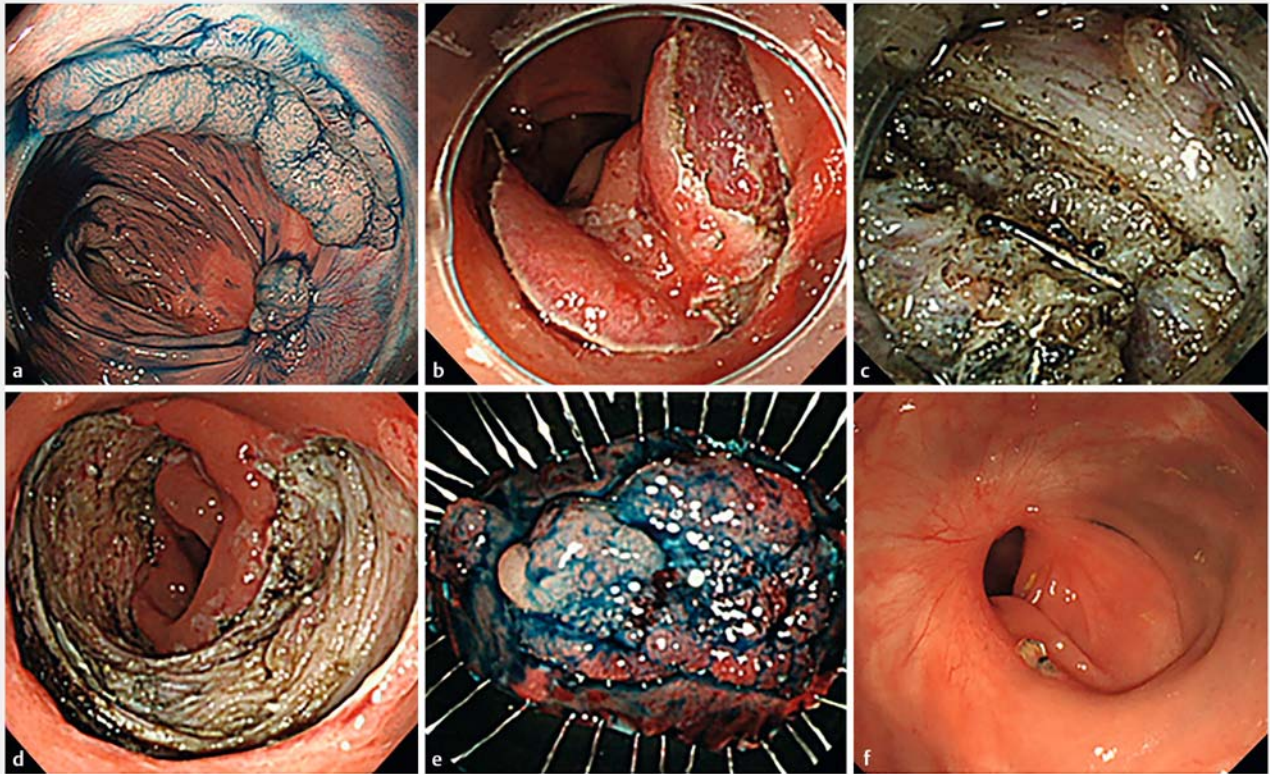
Another treatment options for these cases is transanal endoscopic microsurgery (TEM), which can achieve full-thickness resection. Kawaguti et al. compared ESD and TEM in a single-center study in which local recurrence rates were 9.1% and 18.1% in the ESD and TEM groups. Although no significant differences were found between the two groups, there was a tendency for a higher risk of local recurrence in the TEM group, especially in the case of large lesions [12]. TEM has been speculated to be unsuitable for circumferential lesions [13]. A full-thickness resection using an over the-scope device may be considered as another treatment option, however, R0 resection rate is as low as 58.1% for >2 cm lesions in this study [14]. For lesions >2 cm in our cases, the en bloc resection rate of ESD was 100%, no recurrences were observed after 1-year follow-up, including in cases of recurrent lesions after a TEM procedure (Case #1) and circumferential lesion (Case #5). Therefore, ESD could have more advantages as seen in our cases.

However, our cases have some important limitations. A small number of cases were analyzed, and all procedures were performed by a single experienced endoscopist. The lesions included in our cases were already difficult cases, and the results may not be applicable if the technique is carried out by less ex-

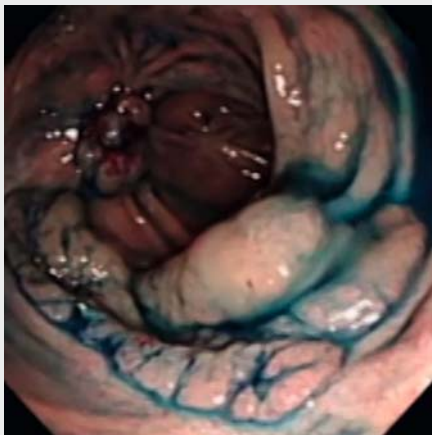
► **Table 1** Clinical characteristics of five patients with a lesion at the anastomotic site.

Case	Age	Sex	Previous surgery	Cause of previous surgery	Morphology	Location	Specimen size (mm)	Tumor size (mm)	Procedure time (mins)	Histopathology	Depth of invasion	R0 resection
1	78	Male	1. Laparoscopic right hemicolectomy and low anterior resection 2. Transanal endoscopic microsurgery for residual tumor at anastomosis	IMCRC	LST-G with sessile polyp	Rectum	67 × 41	42 × 14 12 × 12	226	1. Adenocarcinoma in tubulovillous adenoma 2. Tubulovillous adenoma, high grade	Intramucosal	Y
2	76	Male	Laparoscopic right hemicolectomy	IMCRC	LST-G	Transverse colon	42 × 35	26 × 13	120	Tubular adenoma (high grade)	–	Y
3	72	Male	1. Subtotal colectomy with J-pouch ileorectal anastomosis 2. Piecemeal EMR at anastomosis	UC	LST-G	Rectum	46 × 32	28 × 23	116	Papillary carcinoma with tubular adenoma	Intramucosal	Y
4	29	male	Subtotal colectomy with J-pouch ileorectal anastomosis	FAP	LST-G	Rectum	43 × 32	23 × 18	171	Tubular adenoma (high grade)	–	Y
5	62	Male	Restorative proctocolectomy with ileal pouch-anal anastomosis	FAP	LST-G	Anal canal	64 × 24	60 × 20 (circumferential lesion)	170	Tubulovillous adenoma (low grade dysplasia)	–	Y

IMCRC, mucosal colorectal carcinoma; UC, ulcerative colitis; FAP, familial adenomatous polyposis; LST-G, lateral spreading tumor granular type. R0 resection defined as en bloc resection with tumor-free lateral and vertical margins.



► **Fig. 3** Endoscopic submucosal dissection (ESD) of lesion at the anastomotic site of Case #1. **a** Elevated lesion at the anastomotic site located 5 cm from the anal verge. **b** Left and right mucosal flaps were created directly at the site of the anastomosis scar, starting from the anal site at the normal mucosa. **c** Submucosal dissection on the anastomotic site made underneath the staples. **d, e** Artificial ulcer after ESD and macroscopic view of the resected specimen. **f** No recurrence was seen 1 year after ESD.



► **Video 1** ESD procedure for the lesion at anastomosis site (Case #1).

perienced endoscopists. Therefore, ESD in such cases should only be performed by well-experienced doctors. It should be kept in mind that it could expose patients to risk of adverse events, such as perforation, if it is done by less experienced

endoscopists. In those hospitals without ESD experts, surgery should always be considered as the treatment option.

## Conclusion

In an expert's hands, ESD is a feasible treatment strategy for superficial neoplastic lesions at the AS. En bloc resection can be achieved with this minimally invasive method and decrease risk of anastomosis leakage and possible stoma creation by surgery.

## Competing interests

Takashi Toyonaga invented the FlushKnife and FlushKnife-BT in conjunction with Fujifilm Inc., Tokyo, Japan and receives royalties from its sale.

## References

- [1] Watanabe T, Itabashi M, Shimada Y et al. Japanese Society for Cancer of the Colon and Rectum (JSCCR) Guidelines 2014 for treatment of colorectal cancer. *Int J Clin Oncol* 2015; 20: 207–239

- [2] Tanaka S, Kashida H, Saito Y et al. JGES guidelines for colorectal endoscopic submucosal dissection/endoscopic mucosal resection. *Dig Endosc* 2015; 27: 417–434
- [3] Toyonaga T, Man-i M, East JE et al. 1,635 endoscopic submucosal dissection cases in the esophagus, stomach, and colorectum: complication rates and long-term outcomes. *Surg Endosc* 2013; 27: 1000–1008
- [4] Toyonaga T, Nishino E, Man-i M et al. Principles of quality controlled endoscopic submucosal dissection with appropriate dissection level and high quality resected specimen. *Clin Endosc* 2012; 45: 362–374
- [5] Nakajima T, Saito Y, Tanaka S et al. Current status of endoscopic resection strategy for large, early colorectal neoplasia in Japan. *Surg Endosc* 2013; 27: 3262–3270
- [6] Watanabe D, Toyonaga T, Ooi M et al. Clinical outcomes of deep invasive submucosal colorectal cancer after ESD. *Surg Endosc* 2017; 32: 2123–2130
- [7] Hellinger MD, Santiago CA. Reoperation for recurrent colorectal cancer. *Clin Colon Rectal Surg* 2006; 19: 228–236
- [8] Rojatkar P, Henderson CE, Hall S et al. A novel powered circular stapler designed for creating secure anastomoses. *Med Devices Diagn Eng* 2017; 2: 94–100
- [9] Ishii N, Akiyama H, Suzuki K et al. Endoscopic submucosal dissection for the complete resection of the rectal remnant mucosa in a patient with familial adenomatous polyposis. *ACG Case Report J* 2016; 3: 172–174
- [10] McKenna NP, Mathis KL, Pemberton JH et al. The impact of age at time of ileal pouch anal anastomosis on short and long-term outcomes in adults. *Inflamm Bowel Dis* 2018; 24: 1857–1865
- [11] Takeuchi Y, Iishi H, Tanaka S et al. Factors associated with technical difficulties and adverse events of colorectal endoscopic submucosal dissection: retrospective exploratory factor analysis of a multicenter prospective cohort. *Int J Colorectal Dis* 2014; 29: 1275–1284
- [12] Kawaguti FS, Nahas CS, Marques CF et al. Endoscopic submucosal dissection versus transanal endoscopic microsurgery for the treatment of early rectal cancer. *Surg Endosc* 2014; 28: 1173–1179
- [13] Bignell MB, Ramwell A, Evans JR et al. Complications of transanal endoscopic microsurgery (TEMS): a prospective audit. *Colorectal Dis* 2010; 12: e99–e103
- [14] Schmidt A, Beyna T, Schumacher B et al. Colonoscopic full-thickness resection using an over-the-scope device: a prospective multicentre study in various indications. *Gut* 2018; 67: 1280–1289