

## Endoscopic ultrasound-guided cholecystoduodenostomy for acute cholecystitis with removal of large (missed) cystic duct stones

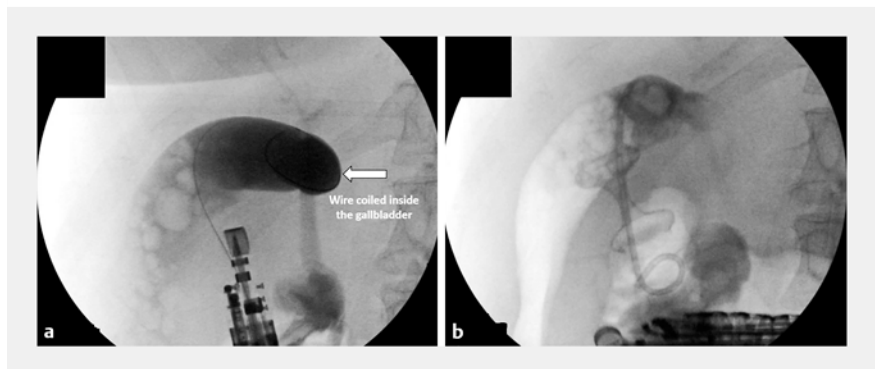
A 64-year-old woman was diagnosed with severe acute calculous cholecystitis. She was not a candidate for surgery because of associated co-morbidities, including idiopathic pulmonary fibrosis and severe aortic stenosis. Magnetic resonance imaging (MRI) showed a distended gallbladder with multiple stones inside but no choledocholithiasis was seen. The decision was made to perform endoscopic ultrasound (EUS)-guided cholecystoduodenostomy to drain the gallbladder.

The gallbladder was identified using a linear echoendoscope (GF-UCT-180; Olympus Optical, Tokyo, Japan) and a suitable site for puncture in the duodenal bulb with no intervening blood vessels was located. The gallbladder was punctured with a 19-gauge fine-needle aspiration (FNA) needle and the position was confirmed by aspiration of bile. A 0.025-inch guidewire was advanced into the gallbladder and coiled under fluoroscopy (► **Fig. 1 a**; ► **Video 1**). A mixture of dilute contrast and saline was injected inside the gallbladder. A 15×10-mm cautery-enhanced lumen-apposing metal stent (LAMS) was advanced to create the fistula tract. The distal flange of the stent was deployed under EUS guidance, whereas the proximal flange was deployed under sonographic and endoscopic guidance. Purulent contents were seen draining from the gallbladder through the LAMS. Finally, a 7-Fr×5-cm double-pigtail plastic stent was placed into the gallbladder through the LAMS (► **Fig. 1 b**). The patient improved clinically and was ultimately discharged after 48 hours.

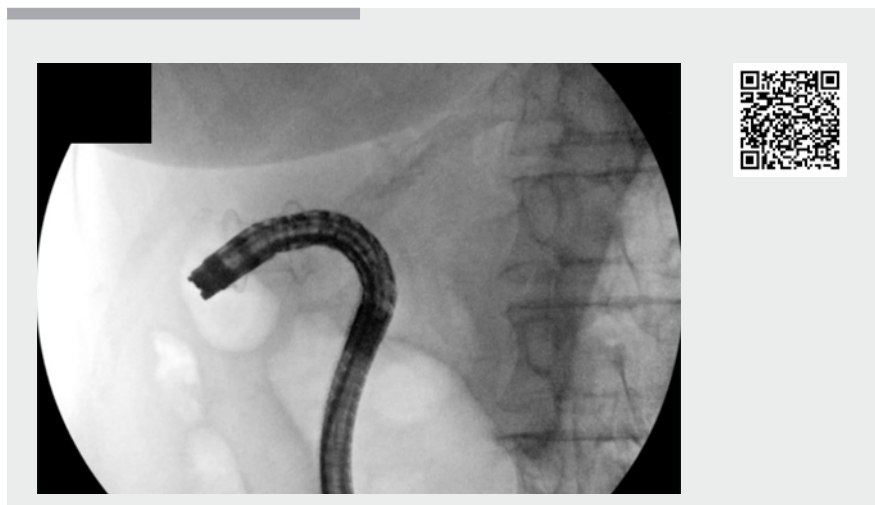The patient returned 4 weeks later for stone clearance and stent removal. A gastroscope was introduced and the double-pigtail stent was removed. Residual gallstones were seen and cleared using a tripod forceps (Polygrab Tripod; Olympus Endoscopy, Center Valley, Pennsylvania, USA) (► **Fig. 2 a**). Cholecystography was then performed; however,

the cystic duct and bile duct could not be visualized. The cystic duct opening was identified using the gastroscope, and after multiple trials with guidewire manipulation, a stone was seen to exit from the cystic duct into the gallbladder lumen. Further examination of this area identified a second large stone that was obstructing the cystic duct (► **Fig. 2 b**). The scope was pressed firmly but cautiously against the gallbladder wall to

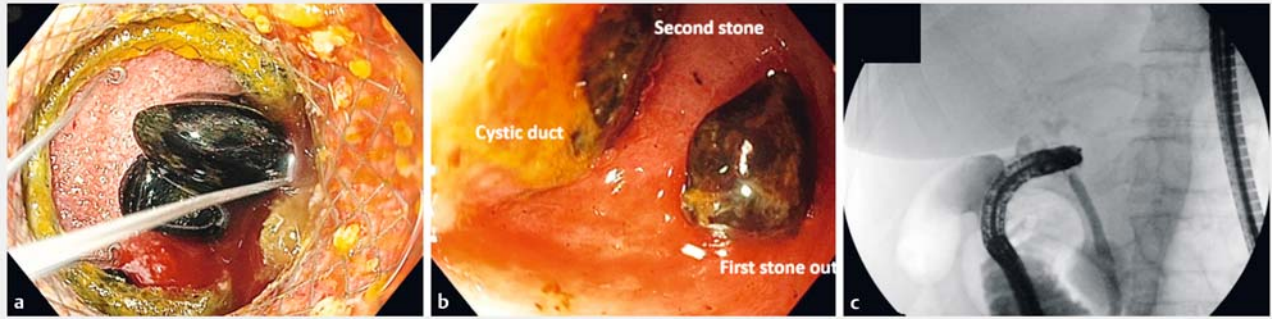
squeeze the stone out of the cystic duct. After several trials the second stone came out of the duct. Repeat contrast injection showed contrast passing from the gallbladder to the cystic and bile ducts (► **Fig. 2 c**). All the stones were then removed from the stomach with use of a Roth net. At the end of the procedure, the LAMS was removed without incident.



► **Fig. 1 a** Fluoroscopic image showing a guidewire passing through the echoendoscope and coiled inside the gallbladder. **b** Fluoroscopic image showing the lumen-apposing metal stent (LAMS) passing from the duodenum to the gallbladder with a double-pigtail plastic stent placed coaxially through the LAMS.



► **Video 1** A 64-year-old patient with acute calculous cholecystitis underwent gallbladder drainage with a lumen-apposing metal stent (LAMS). Endoscopic clearance of the gallstones, including two initially missed stones inside the cystic duct, was performed.



► **Fig. 2** **a** Endoscopic image showing residual gallstones being removed using a tripod forceps. **b** Endoscopic view from inside the gallbladder showing further stones obstructing the cystic duct; one stone has already been retrieved and another larger one is still obstructing the lumen of the duct. **c** Fluoroscopic image after clearance of the gallstones showing contrast passing from the gallbladder to the cystic and bile ducts, with no residual stones seen.

EUS-guided cholecystoduodenostomy is a safe and effective technique for managing patients with acute cholecystitis and cholelithiasis who are not candidates for surgical management. Careful examination of the cystic and bile duct is essential before LAMS removal, to avoid missed stones and recurrence of obstruction.

Endoscopy\_UCTN\_Code\_TTT\_1AS\_2AD

### Competing interests

M. A. Khashab is a consultant for Boston Scientific, Olympus, and Medtronic.

### The authors

**Nader Bakheet, Yervant Ichkhanian, Thomas M. Runge, Kia Vosoughi, Mouen A. Khashab**  
 Division of Gastroenterology and Hepatology, Johns Hopkins Hospital, Baltimore, Maryland, USA

### Corresponding author

**Mouen A. Khashab, MD**  
 Division of Gastroenterology and Hepatology, Johns Hopkins Hospital, Sheikh Zayed building, 1800 Orleans Street, Suite 7125G, Baltimore, MD 21287, USA  
 Fax: 01-443-683-8335  
 mkhasha1@jhmi.edu

### Bibliography

DOI <https://doi.org/10.1055/a-0934-4898>  
 Published online: 1.7.2019  
 Endoscopy 2019; 51: E354–E355  
 © Georg Thieme Verlag KG  
 Stuttgart · New York  
 ISSN 0013-726X

### ENDOSCOPY E-VIDEOS

<https://eref.thieme.de/e-videos>



*Endoscopy E-Videos* is a free access online section, reporting on interesting cases and new techniques in gastroenterological endoscopy. All papers include a high quality video and all contributions are freely accessible online.

This section has its own submission website at <https://mc.manuscriptcentral.com/e-videos>