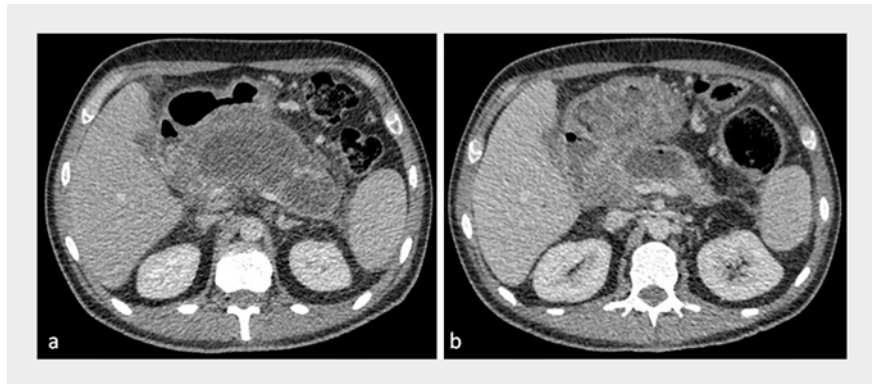


Over-the-scope clip closure of an iatrogenic gastro-colic fistula following maldeployment of a lumen-apposing metal stent

A 44-year-old man with a 3-month history of necrotizing pancreatitis was referred for endoscopic ultrasound (EUS)-guided drainage of infected 12×5 cm symptomatic walled-off necrosis (WON) [1] (► **Fig. 1 a**). At EUS, a large partially cystic/solid lesion, interpreted as the WON, was identified. A 20-mm lumen-apposing metal stent (LAMS; Hot AXIOS, Boston Scientific, Marlborough, Massachusetts, USA) and plastic pigtail stent were deployed through the posterior gastric wall. The patient was well following the procedure. However, computed tomography (CT) revealed that the LAMS had been incorrectly deployed into the colon (► **Fig. 2**), and the WON had spontaneously improved (3×2 cm) (► **Fig. 1 b**). We planned to remove the LAMS endoscopically and close the gastro-colic fistula (GCF) by over-the-scope-clips (OTSCs) [2, 3] (► **Video 1**). Colonic cleansing necessitated a nasojejunal tube to bypass the GCF. Simultaneous upper and lower gastrointestinal endoscopy were performed under general anesthesia. The colonoscope, loaded with a 14-mm OTSC (Ovesco, Tübingen, Germany), was inserted to

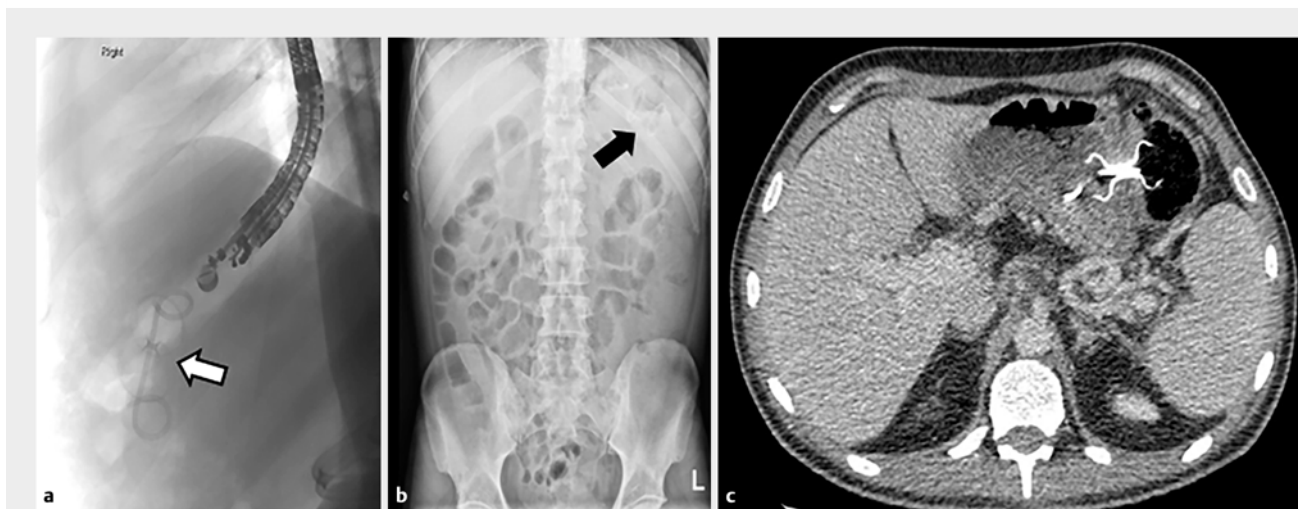

► **Fig. 1** Computed tomography. **a** Symptomatic walled-off necrosis (WON). **b** Spontaneously improved WON.

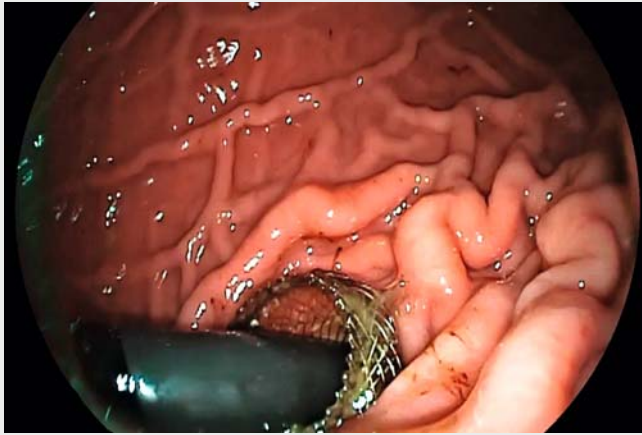
the LAMS at the splenic flexure. The LAMS was removed with the gastroscope. The colonic defect was closed with the OTSC using twin-grasping forceps tissue apposition (► **Fig. 3**), followed by similar closure of the gastric defect with two 12-mm OTSCs. Successful closure was confirmed endoscopically and radiologically with indigo carmine dye and contrast, respectively (► **Fig. 4**). Although the patient developed some delayed localized pain and peritonism 48 hours

after oral intake, repeat contrast CT showed no leakage (► **Fig. 5 a**). Symptoms settled conservatively with antibiotics and temporary intravenous nutrition. The patient was discharged 10 days after the procedure, with a pre-discharge contrast meal re-confirming no leakage (► **Fig. 5 b**).

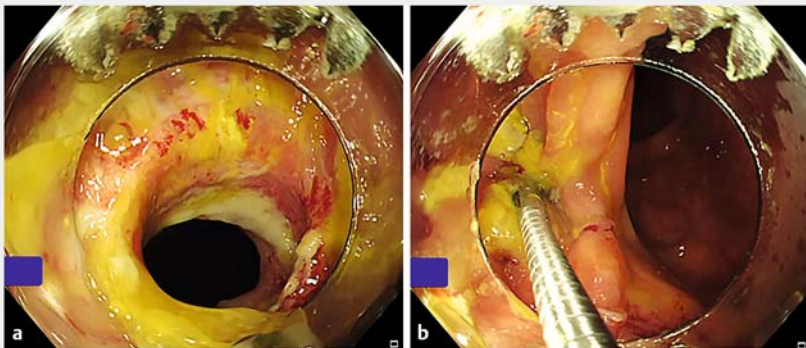
To the best of our knowledge, this is the first case of successful OTSC closure of an acute GCF caused by a maldeployed LAMS, confirming the role of OTSCs in



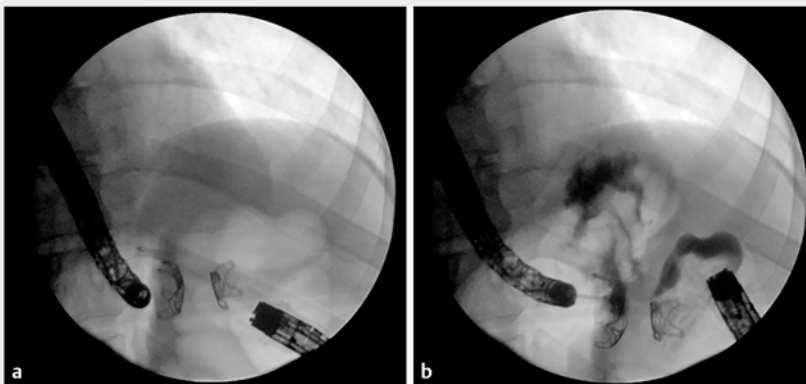
► **Fig. 2** Maldeployed lumen-apposing metal stent (arrows) and plastic pigtail stent. **a, b** X-ray. **c** Computed tomography scan.



▶ Video 1 Over-the-scope clip closure of an iatrogenic gastro-colic fistula following maldeployment of a lumen-apposing metal stent.



▶ Fig. 3 Twin-grasping forceps tissue apposition used to close the colonic defect with the over-the-scope clip.



▶ Fig. 4 Successful closure was confirmed radiologically with contrast.

minimally invasive endoscopic management of such complications.

Endoscopy_UCTN_Code_CPL_1AL_2AG

Competing interests

Edward J. Despott has acted as a consultant for Boston Scientific and Ambu. He has also received academic grants and speaker honoraria from Fujifilm, Aquilant Endoscopy, Norgine and Olympus.

Alberto Murino has acted as a consultant for Boston Scientific and GI supply. He has also received academic grants from Fujifilm, Aquilant Endoscopy, Norgine and Olympus.

Tomonori Yano has received educational and speaker honoraria from Fujifilm corporation. All other authors declare that they have no conflict of interest.

The authors

Edward J. Despott¹, Nikolaos Lazaridis¹, Gavin Johnson^{1,2}, Tomonori Yano^{1,3}, Alberto Murino¹

- 1 Royal Free Unit for Endoscopy and University College London Institute for Liver and Digestive Health, London, United Kingdom
- 2 University College London Hospital, London, United Kingdom
- 3 Division of Gastroenterology, Department of Medicine, Jichi Medical University, Shimotsuke, Japan

Corresponding author

Edward J. Despott, MD, FRCP, FASGE

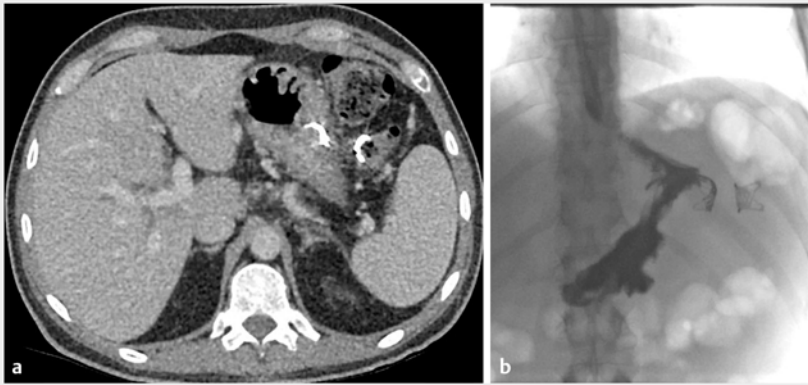
The Royal Free Hospital and University College London Institute for Liver and Digestive Health, Pond Street, Hampstead, London NW3 2QG, United Kingdom

Fax: +44-20-74315261

edespott@doctors.org.uk

References

- [1] Itoi T, Binmoeller KF, Shah J et al. Clinical evaluation of a novel lumen-apposing metal stent for endosonography-guided pancreatic pseudocyst and gallbladder drainage (with videos). *Gastrointest Endosc* 2012; 75: 870–876



► **Fig. 5** Post-procedure tests confirming no leakage. **a** Computed tomography. **b** Barium meal showing no leakage.

[2] Murino A, Despott EJ, Vaizey C et al. First report of endoscopic closure of a gastrocolic fistula using an over-the-scope clip system (with video). *Gastrointest Endosc* 2012; 75: 893–894

[3] Mönkemüller K, Peter S, Alkurdi B et al. Endoscopic closure of a gastrocolic fistula using the over-the-scope-clip-system. *World J Gastrointest Endosc* 2013; 5: 402–406

Bibliography

DOI <https://doi.org/10.1055/a-1085-9343>
 Published online: 21.2.2020
Endoscopy 2020; 52: E300–E302
 © Georg Thieme Verlag KG
 Stuttgart · New York
 ISSN 0013-726X

ENDOSCOPY E-VIDEOS

<https://eref.thieme.de/e-videos>



Endoscopy E-Videos is a free access online section, reporting on interesting cases and new techniques in gastroenterological endoscopy. All papers include a high quality video and all contributions are freely accessible online.

This section has its own submission website at
<https://mc.manuscriptcentral.com/e-videos>