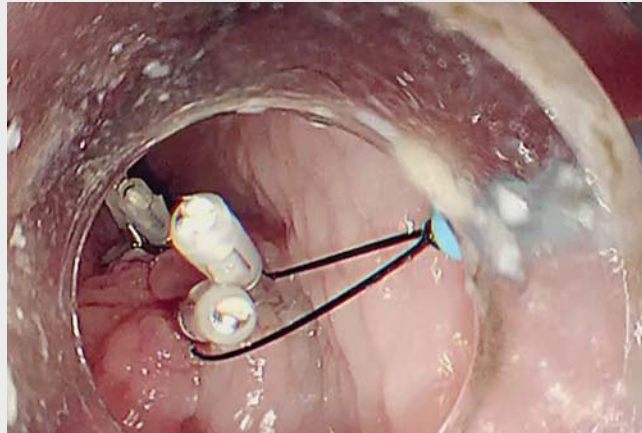


A novel closure technique using the EndoTrac for mucosal incision closure in peroral endoscopic myotomy

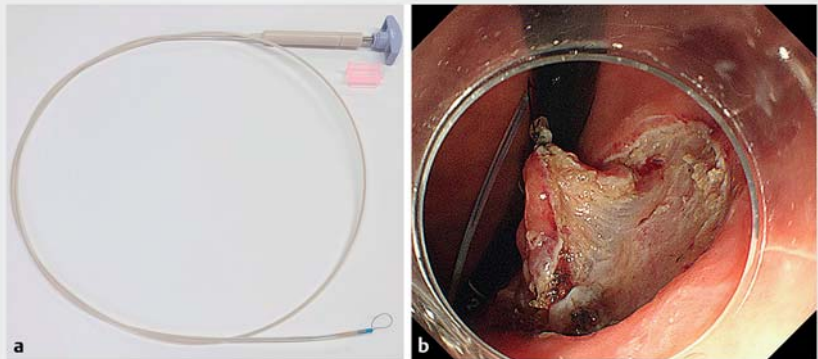
Recently, peroral endoscopic myotomy (POEM) has been reported to be highly effective for treating patients with achalasia [1,2]. In achalasia, patients may have severe esophageal dilatation and thickening of the mucosal layer due to their long history of the disease. Endoclips are usually used for closure of the mucosal incision, but this can be difficult due to the thickness of the mucosal layer. Alternative methods using an Endoloop or Over-The-Scope Clip (OTSC) have been described to manage difficult mucosal incision closure [3], but these methods are complex and require sufficient skill. We present a novel technique using EndoTrac (Top Corporation, Tokyo, Japan) for mucosal incision closure in POEM.

A 41-year-old man with a 10-year history of achalasia underwent POEM successfully without complications. However, we encountered difficulty in closing the incision with endoclips alone due to the extremely thick mucosal layer, so we used the EndoTrac. The EndoTrac is a novel traction device for endoscopic submucosal dissection which allows changes to the direction of traction [4,5]. It has a line with a clinch-knotted loop, a plastic sheath, and a T-shaped handle (► **Fig. 1**). A standard endoscope (GIF-Q260; Olympus Corporation, Tokyo, Japan) was inserted with the EndoTrac running alongside the shaft of the endoscope after hooking the loop onto the jaw of the endoclip. An endoclip was deployed with the loop at the edge on each side of the mucosal incision. The T-shaped handle of the EndoTrac was then pulled, which pushed the knot towards the tip of the sheath and tightened the loop. This brought the opposing mucosal walls together and closed the mucosal incision. This procedure was repeated twice and then further standard endoclips were added to reinforce complete closure (► **Fig. 2**, ► **Video 1**).

This novel technique of mucosal incision closure using Endotrach is highly effective



► **Video 1** Mucosal incision closure technique using the EndoTrac in peroral endoscopic myotomy (POEM).



► **Fig. 1 a, b** The EndoTrac device (Top Corporation, Tokyo, Japan).

and simple. We believe this is a promising technique in cases where closure is difficult with standard endoclips alone.

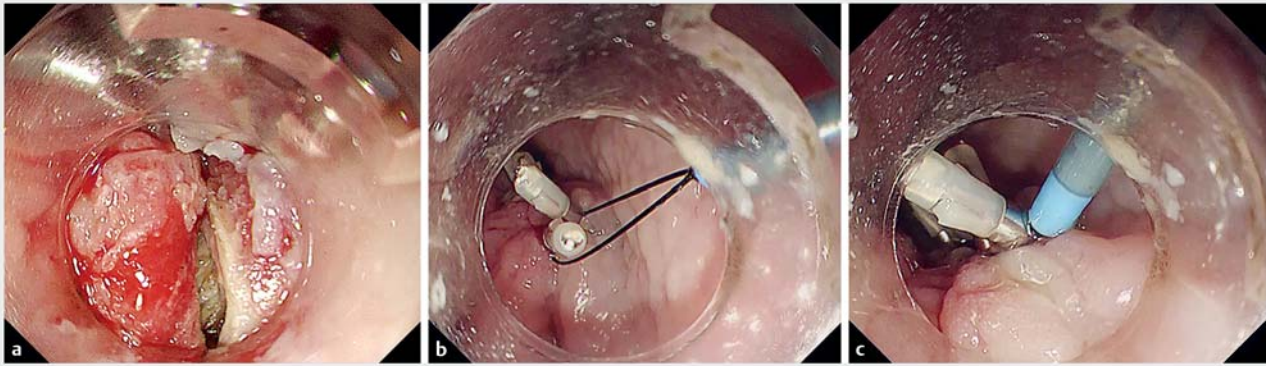
Endoscopy_UCTN_Code_TTT_1AO_2AI

Competing interests

Takashi Toyonaga has received EndoTrac patent royalties from TOP. The other authors declare that they have no conflict of interest.

The authors

Tomoya Sako, Shinwa Tanaka, Takashi Toyonaga, Hirofumi Abe, Hiroya Sakaguchi, Nobuaki Ikezawa, Yuzo Kodama
Division of Gastroenterology, Department of Internal Medicine, Kobe University Graduate School of Medicine, Kobe, Japan



► **Fig. 2** Closure technique using the EndoTrac for mucosal incision closure in peroral endoscopic myotomy (POEM). **a** It was difficult to close the mucosal incision with endoclips alone. **b** An endoclip was deployed with the loop at the edge on each side of the mucosal incision. **c** The knot was pushed towards the tip of the sheath and mucosal incision was closed.

Corresponding author

Shinwa Tanaka, MD, PhD

Division of Gastroenterology, Department of Internal Medicine, Kobe University Graduate School of Medicine, 7-5-1 Chuo-ku, Kusunoki-cho, Kobe, Hyogo 650-0017, Japan
 Fax: +81-78-382-6309
 shinwa1408@gmail.com

References

- [1] Inoue H, Minami H, Kobayashi Y et al. Peroral endoscopic myotomy (POEM) for esophageal achalasia. *Endoscopy* 2010; 42: 265–271
- [2] Werner YB, Hakanson B, Martinek J et al. Endoscopic or surgical myotomy in patients with idiopathic achalasia. *N Engl J Med* 2019; 381: 2219–2229
- [3] Saxena P, Chavez YH, Kord Valeshabad A et al. An alternative method for mucosal flap

closure during peroral endoscopic myotomy using an over-the-scope clipping device. *Endoscopy* 2013; 45: 579–581. doi:10.1055/s-0032-1326398

- [4] Tanaka S, Toyonaga T, Kaku H et al. A novel traction device (EndoTrac) for use during endoscopic submucosal dissection. *Endoscopy* 2019; 51: E90–E91
- [5] Sakaguchi H, Toyonaga T, Kaku H et al. The crane technique: a novel traction method for use during rectal endoscopic submucosal dissection. *Endoscopy* 2019; 51: E88–E89

Bibliography

DOI <https://doi.org/10.1055/a-1109-2301>
 Published online: 17.2.2020
Endoscopy 2020; 52: E291–E292
 © Georg Thieme Verlag KG
 Stuttgart · New York
 ISSN 0013-726X

ENDOSCOPY E-VIDEOS

<https://eref.thieme.de/e-videos>



Endoscopy E-Videos is a free access online section, reporting on interesting cases and new

techniques in gastroenterological endoscopy. All papers include a high quality video and all contributions are freely accessible online.

This section has its own submission website at

<https://mc.manuscriptcentral.com/e-videos>