

# Endoscopic ultrasonography-guided deployment of embolization coils and cyanoacrylate injection in gastric varices versus coiling alone: a randomized trial

## Authors

Carlos Robles-Medranda, Roberto Oleas, Manuel Valero, Miguel Puga-Tejada, Jorge Baquerizo-Burgos, Jesenia Ospina, Hannah Pitanga-Lukashok

## Institution

Instituto Ecuatoriano de Enfermedades Digestivas (IECED), Guayaquil, Ecuador

submitted 18.6.2019

accepted after revision 17.12.2019

## Bibliography

DOI <https://doi.org/10.1055/a-1123-9054>

Published online: 3.3.2020 | Endoscopy 2020; 52: 268–275

© Georg Thieme Verlag KG Stuttgart · New York

ISSN 0013-726X

## Corresponding author

Carlos Robles-Medranda, MD, Endoscopy Division, Instituto Ecuatoriano de Enfermedades Digestivas (IECED), Av. Abel Romero Castillo y Av. Juan Tanca Marengo, Torre Vitalis, Mezzanine 3, Guayaquil, Ecuador  
Fax: +593-4-2109180  
[carlosoakm@yahoo.es](mailto:carlosoakm@yahoo.es)

 Supplementary material

Online content viewable at:

<https://doi.org/10.1055/a-1123-9054>

 Scan this QR-Code for the author commentary.



## ABSTRACT

**Background** Gastric variceal bleeding is a life-threatening condition with challenging management. We aimed to compare the efficacy and safety of endoscopic ultrasono-

graphy (EUS)-guided coil embolization and cyanoacrylate injection versus EUS-guided coil embolization alone in the management of gastric varices.

**Methods** A single-center, parallel-randomized controlled trial involving 60 participants with gastric varices (GOV II and IGV I) who were randomly allocated to EUS-guided coil embolization and cyanoacrylate injection (n=30) or EUS-guided coil embolization alone (n=30). The primary end points were the technical and clinical success rates of both procedures. The secondary end points were the reappearance of gastric varices during follow-up, along with rebleeding, the need for reintervention, and complication and survival rates.

**Results** The technical success rate was 100% in both groups. Immediate disappearance of varices was observed in 86.7% of patients treated with coils and cyanoacrylate, versus 13.3% of patients treated with coils alone ( $P < 0.001$ ). Median survival time was 16.4 months with coils and cyanoacrylate versus 14.2 months with coils alone ( $P = 0.90$ ). Rebleeding occurred in 3.3% of patients treated with combined treatment and 20% of those treated with coils alone ( $P = 0.04$ ). With combined treatment, 83.3% of patients were free from reintervention versus 60% with coils alone (hazard ratio 0.27; 95% confidence interval 0.095–0.797;  $P = 0.01$ ).

**Conclusions** EUS-guided coil embolization with cyanoacrylate injection achieved excellent clinical success, with lower rates of rebleeding and reintervention than coil treatment alone. Multicenter studies are required to define the most appropriate technique for gastric variceal obliteration.

Clinical.Trials.gov

NCT03155256

A single-center, parallel-randomized controlled trial registered under the code NCT03155256 at [clinicaltrials.gov](http://clinicaltrials.gov)

## Introduction

Bleeding from gastric varices is more severe and life-threatening than bleeding from esophageal varices and is associated with high mortality and morbidity rates [1]. Management of bleeding from gastric varices is challenging and requires expertise because aggressive rebleeding can occur [1, 2].

Treatment of varices by injection of cyanoacrylate via standard gastroscopy is associated with a higher hemostasis rate and a lower rebleeding rate than either band ligation or sclerotherapy [3], but has been associated with adverse events, such as pulmonary embolization, bleeding, fever, chest pain, and even death [4–6]. In addition, the endoscopic injection of cyanoacrylate has been shown to result in damage to the working channel of the endoscope [7, 8]. Moreover, complete variceal obliteration is difficult to confirm during the procedure and may require additional therapeutic sessions.

The use of endoscopic ultrasonography (EUS) to guide the cyanoacrylate injection has several advantages over guidance by visible-light endoscopy. These advantages include the precise targeting of the feeder vessel of the gastric varix and the requirement for a lesser amount of cyanoacrylate for obliteration, which is an important consideration because the risk of glue embolization is dependent on the volume of cyanoacrylate injected [9, 10]. In addition, EUS evaluation can confirm obliteration of the varix via Doppler imaging after the procedure [11].

The EUS-guided deployment of embolization coils within gastric varices is associated with fewer adverse events than EUS-guided injection of cyanoacrylate, but has the disadvantages of a lower obliteration rate and a higher cost [12, 13]. The combined injection of coils and cyanoacrylate was first described in 30 patients and resulted in a 95.8% obliteration rate [14]. In a larger cohort of 152 patients, this combined approach showed a 93% obliteration rate with a 3% rebleeding rate; however, in this retrospective study, only 65.7% of patients had an EUS Doppler study performed to evaluate complete obliteration [15].

There is a lack of prospective data comparing EUS-guided coiling and cyanoacrylate injection versus coiling alone, with a focus on the obliteration, rebleeding, and adverse event rates, to define the most appropriate obliteration technique. The objective of the present study was to compare the efficacy and safety of EUS-guided combined deployment of coils and cyanoacrylate injection with EUS-guided coil deployment alone for the management of patients with gastroesophageal varices type II (GOV II) and isolated gastric varices type I (IGV I) in a prospective randomized controlled trial.

## Methods

### Study design

An interventional, parallel-randomized controlled trial was performed at the Instituto Ecuatoriano de Enfermedades Digestivas (IECED), a tertiary referral center in Ecuador, from March 2016 to October 2018. Patients were randomly allocated in a 1:1 manner to either EUS-guided coil deployment or EUS-guided coil deployment and cyanoacrylate injection for the management of gastric varices types GOV II and IGV I.

The study protocol and consent form were approved by the Institutional Review Board, and the study was conducted in accordance with the Declaration of Helsinki. Written informed consent was obtained from all participants or from designated relatives. The study was registered at ClinicalTrials.gov under the code NCT03155256.

### Population selection and inclusion and exclusion criteria

Patients fulfilling the following criteria were considered to be candidates for inclusion: age  $\geq 18$  years, history of liver cirrhosis with endoscopic evidence of GOV II or IGV I in accordance with the Sarin classification [2], and patient preference for EUS-guided therapy. Liver cirrhosis was defined in accordance with the clinical and imaging findings; all patients had a transient elastography (Fibroscan, EchoSens, Paris) consistent with liver cirrhosis. The study population included patients with active bleeding, a history of previous bleeding secondary to gastric varices (secondary prophylaxis), and those eligible for primary prophylaxis in accordance with the Baveno VI consensus [16].

Patients were excluded if they had concurrent hepatorenal syndrome and/or multiorgan failure, were pregnant or nursing, or had suspected splenic or portal vein thrombosis, a platelet count  $< 50\,000/\text{mL}$  or an international normalized ratio (INR)  $\geq 2$ , esophageal stricture, or a known allergy to iodine.

### Study outcomes

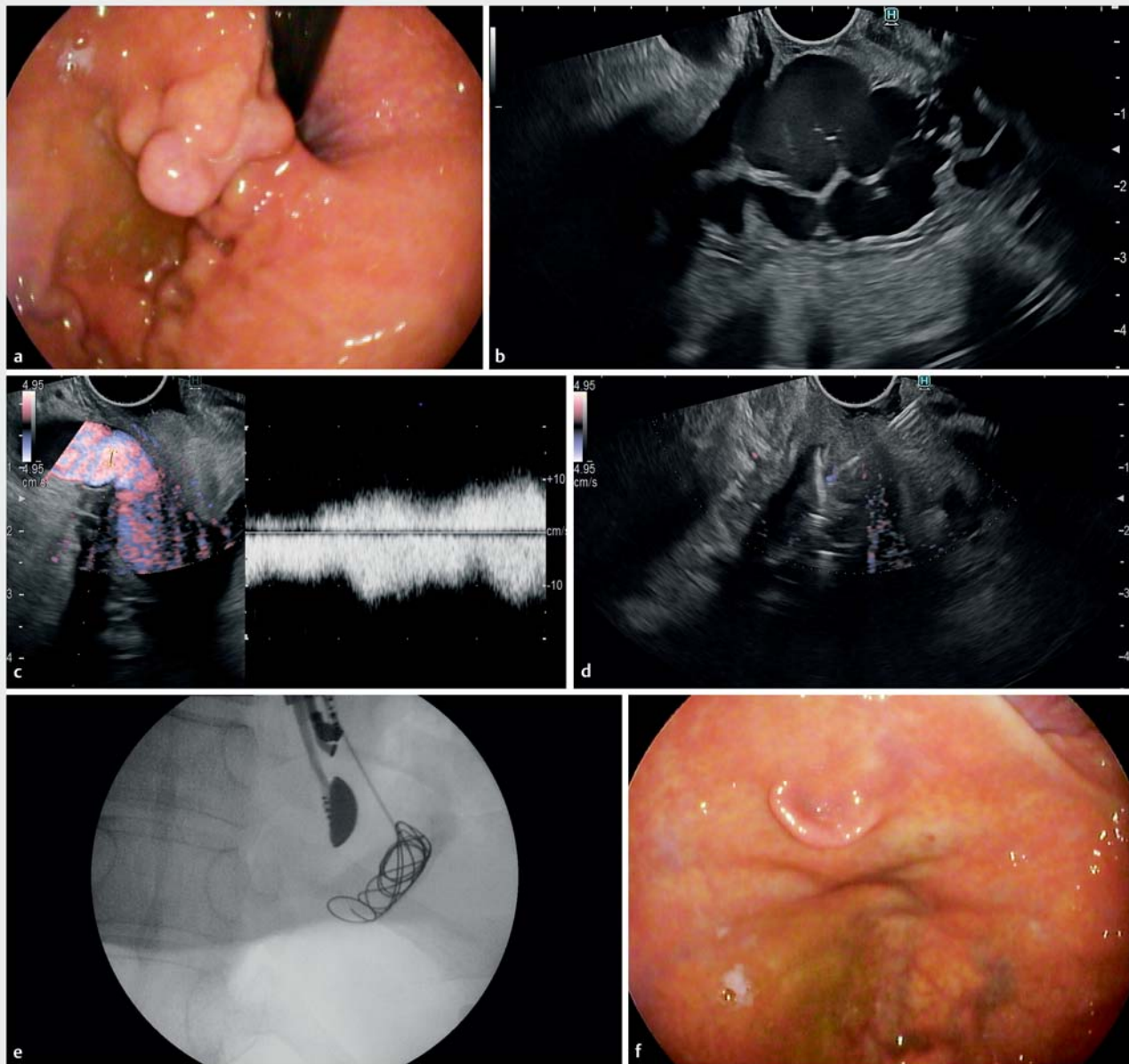
The primary end point of the study was a comparison of the efficacy of the two EUS-guided procedures in terms of their technical and clinical success rates. Technical success was defined as completion of the intended procedure. Clinical success was considered to be complete and immediate obliteration of the varix, evaluated via esophagogastroduodenoscopy (EGD) and the absence of flow during EUS Doppler evaluation.

The secondary end points of the study were the reappearance of gastric varices during follow-up, rebleeding, the need for reintervention, and the complication and survival rates in the two arms of the study.

### Endoscopic procedure and technique

All procedures were performed in a hospital-based interventional endoscopy unit by one endoscopist (C.R.-M.), who was blinded to each patient's medical history. Procedures were performed with the patient under general anesthesia, with tracheal intubation, and in the supine position. All patients received antibiotic prophylaxis with 2 g of ceftriaxone intravenously. The EUS-guided procedure was performed with a linear-array therapeutic echoendoscope (3.8-mm working channel; EG3870UTK; Pentax, Hamburg, Germany) attached to an ultrasonography console (Avius Hitachi, Tokyo, Japan). The echoendoscope was positioned in the distal esophagus at the level of the cardia to enable visualization of the gastric fundus and intramural varices.

After the echoendoscope had been positioned, water was instilled into the gastric fundus to improve acoustic coupling and visualization of the gastric varices. Direct visualization of the blood flow in the varices was evaluated via color Doppler on the ultrasonography console. The offending vessel or vessels



**Fig. 1** Procedure for endoscopic ultrasonography (EUS)-guided deployment of embolization coils and cyanoacrylate injection in gastric varices. **a** Endoscopic view of the gastric varix (type IGV I) before treatment. **b** EUS evaluation of the gastric varices prior to therapy. **c** EUS Doppler evaluation of the feeder vessel for the gastric varices (left panel), showing the flow amplitude wave of the feeder vessel (right panel). **d** EUS-guided deployment of coils and cyanoacrylate injection into the feeder vessel. **e** Fluoroscopic evaluation of the deployed EUS-guided coils. **f** Endoscopic view after combined therapy showing disappearance of the varix.

were followed from the cardia to the proximal part of the esophagus, 2–3 cm above the cardia, to detect the feeding vessel, which was considered to be the convergence of all offending vessels. An EUS-guided fine-needle puncture was performed with a 19-gauge needle (Expect Flexible; Boston Scientific, Marlborough, Massachusetts, USA) to access the feeder vessel; the stylet was withdrawn and a 20-ml negative-pressure syringe was used to evaluate blood return, thereby confirming the intravascular location. To prevent blood clotting in the needle tip, 5 mL of saline solution was instilled. The endoscopist was able to confirm the flow in the gastric varices with B-mode

ultrasonography. Additionally, EUS-guided varicealography was performed to confirm the target vessel and the flow trajectory, as previously described [9].

Immediately following the EUS therapy, EGD was performed to evaluate the disappearance of the gastric varices.

#### EUS-guided coil embolization and cyanoacrylate injection

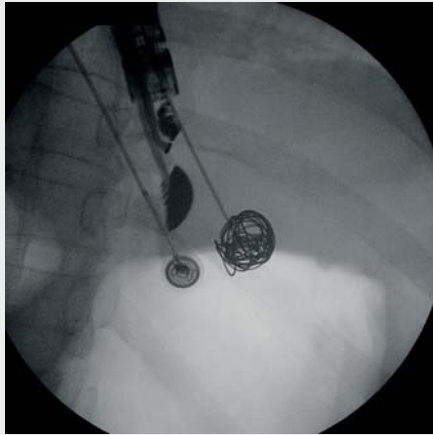
Coils were deployed under EUS guidance, followed (in selected individuals) by injection of 2-octyl-cyanoacrylate (Dermabond; Ethicon, Piscataway, New Jersey, USA). The 0.035-inch diameter

Nester Embolization Coils (Cook Medical, Bloomington, Indiana, USA) were used for intravascular embolization. The coils were 10–16 mm in diameter and 12–20 cm in straight length. Coils were delivered into the vessels through the EUS needle using the stylet to advance them. To minimize the risks of perforation, bleeding, and coil extrusion, and to provide enough space for the coils to curl, care was taken to avoid placing the needle tip on the opposite wall of the varix. The size of the coil chosen was >120% of the varix diameter according to the diameter measured during EUS; coils were deployed in the direction of the portal vein (blood-outflow trajectory).

The cyanoacrylate injection was performed slowly after coil deployment. The volume of the desired cyanoacrylate injection was measured in accordance with the diameter of the vessel (<2.5 mL), and 1 mL of saline solution was used to flush the glue completely through the needle under EUS guidance. After 90–120 seconds, the cyanoacrylate had solidified and the risk of bleeding at the puncture site had decreased, and the needle was withdrawn. ► **Fig. 1** summarizes the procedure for combined coil deployment and cyanoacrylate injection. The steps for the EUS-guided combined coil deployment and cyanoacrylate injection are described in a short procedure video (► **Video 1**).

### EUS-guided coil embolization alone

In patients allocated to undergo EUS-guided coil embolization alone, coil insertion was performed as described above, again using Nester Embolization Coils >120% of the varix diameter.



► **Video 1** Endoscopic ultrasonography (EUS)-guided combined therapy with coil deployment and cyanoacrylate injection with the addition of EUS-guided varicealography. (a) Endoscopic evaluation of gastroesophageal varices type II. (b) Endoscopic ultrasound evaluation of gastric varices and the feeder vessel. (c) EUS-guided varicealography with evaluation of the flow trajectory. (d) EUS-guided deployment of embolization coils with combined cyanoacrylate injection, followed by EUS-guided Doppler evaluation of the feeder vessel and gastric varices for obliteration confirmation. (e) Endoscopic visualization of gastric varices after EUS-guided combined therapy.

Online content viewable at:  
<https://doi.org/10.1055/a-1123-9054>

### Follow-up

Follow-up EGD and an EUS Doppler evaluation were performed 3 months after the initial procedure by a second endoscopist (M.V.), who was blinded to the initial procedure. The reappearance of gastric varices, need for reintervention, and survival rates were evaluated. Patients were followed-up until the date of death or up to 12 months after enrollment via visits to the clinic and review of medical, EGD, and EUS records.

If patients required reintervention secondary to varix reappearance or recurrent bleeding, a second EUS-guided procedure was performed, subject to the endoscopist's preference. All reinterventions were performed in the same endoscopy unit as the index procedure.

### Statistical analysis

A sample size of 30 participants per study group was calculated through a sample size formula to compare two proportions (two-samples, one-sided), on the basis of a 5%  $\alpha$  error, a 20%  $\beta$  error,  $\kappa=1$ , and success rates of 82% for complete obliteration with EUS-guided coil embolization and 53% for EUS-guided cyanoacrylate injection, as described by Romero-Castro et al. [13].

Categorical variables were described as frequencies or proportions (%). Numerical variables were described as mean and standard deviation, or median and minimum to maximum range, according to statistical distribution (Kolmogorov–Smirnov test). Differences between the characteristics of the study groups were established through corresponding hypothesis tests: chi-squared or Fisher's exact test for categorical variables, Student's *t* test for normally distributed numerical variables, Mann–Whitney *U* test for non-normally distributed numerical variables. Hypothesis testing was performed as a one-tailed analysis.

For primary outcome analysis, the effect of combined therapy on immediate disappearance of the varix was estimated through relative risk (RR). For secondary outcome analysis, survival time and reintervention-free time between the two study groups were compared through Long-rank and Gray's test, respectively. The effect of combined therapy on overall survival and reintervention-free survival were estimated through the hazard ratio (HR). A *P* value <0.05 was considered statistically significant.

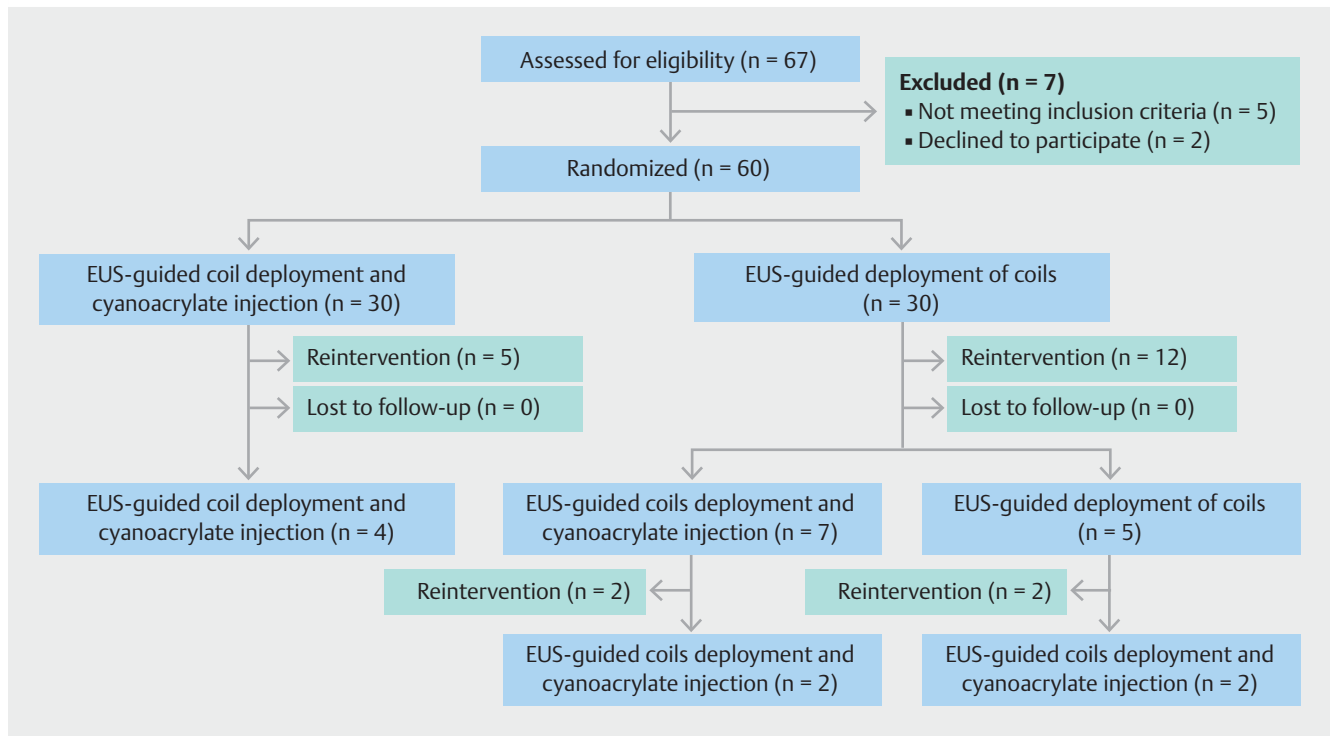
Data analysis was performed using R version 3.4.2 (R Foundation for Statistical Computing; Vienna, Austria).

## Results

### Demographics

A total of 60 patients were enrolled, with 30 assigned to each group (► **Fig. 2**). There were no significant differences in the baseline characteristics between the two groups (► **Table 1**). None of the patients in either group had previous interventions for the management of the gastric varices.

The median number of coils placed per patient was two in the combined treatment group and three in the single treatment group (*P*=0.006), and there was no significant difference between the distributions of coils of different sizes in the two



► **Fig. 2** Flowchart of the management of the study patients. EUS, endoscopic ultrasonography.

groups. After enrollment, patients were evaluated for the initiation of beta-blocker therapy, which was tolerated in 83% and 80% of patients in the combined and coiling alone groups, respectively ( $P=0.74$ ). The characteristics of the gastric varices and procedure, along with the primary outcomes of the study are summarized in ► **Table 2**.

## Outcome results

### Primary end points

Technical success of the intended procedure was achieved in 100% of individuals in both study arms. Complete obliteration as evidenced by EUS Doppler results was observed in 100% of participants with the combined technique and in 90% of those with EUS-guided coil embolization alone ( $P=0.12$ ). Immediate disappearance of the varix under direct visualization by EGD was observed in 26 of the 30 individuals with the combined treatment, but in only four of the 30 individuals with the single treatment (RR 6.5, 95% confidence interval [CI] 2.6–16.4;  $P<0.001$ ).

### Secondary end points

The secondary end points were rebleeding, reappearance of the gastric varices during follow-up, the need for reintervention, and survival rates in the two study arms. The median follow-up duration was 14.5 months (range 0.6–31.2 months). The rebleeding, varix reappearance, and reintervention rates were all significantly lower in the combined treatment group than in the single treatment group (► **Table 3**).

In the combined treatment group, a first reintervention was required in five individuals, four patients were treated with combined coil deployment and cyanoacrylate injection within 3, 6, 14, and 15 months after enrollment. In the group treated with EUS-guided coil embolization alone, 12 patients required a first reintervention for the management of gastric varices: six reinterventions (50%) occurred within 3 months of enrollment, four by completion of the 1-year follow-up period, and two reinterventions were required 13 and 14 months after enrollment. Of these 12 patients, seven were treated for the reappearance of the gastric varix with EUS-guided coil embolization and CYA injection, of these two required a second reintervention with coil embolization and CYA injection. Five individuals were treated with EUS-guided coil embolization alone as the first reintervention; however, two required a second reintervention with coil embolization and CYA injection.

The overall mortality rates were 30% in the combined treatment group and 26.7% in the coil-only group (HR 0.95, 95%CI 0.361–2.532;  $P=0.90$ ). The causes of death in both groups are listed on ► **Table 3**. Five patients in the combined treatment group died from uncontrolled hemorrhage during follow-up (gastric varices [n=2], esophageal varices [n=3]); however, two of these five patients had a concomitant hepatocellular carcinoma and all of the deceased patients were Child–Pugh class C at the date of their death. Five patients in the coiling-alone group also died from uncontrolled hemorrhage during follow-up (gastric varices [n=2], esophageal varices [n=2], and gastric ulcer [n=1]); one patient had a concomitant hepatocellular carcinoma and again all of the deceased patients were Child–Pugh class C at the date of death. The median over-

**► Table 1** Demographic and clinical characteristics of the 60 patients with gastric varices who were treated either by coils and cyanoacrylate injection or by coils alone.

	Coils + CYA (n = 30)	Coils alone (n = 30)	P value
Age, mean (SD), years	61.8 (7.8)	61.6 (12.3)	0.95 <sup>1</sup>
Sex, female, n (%)	14 (46.7)	11 (36.7)	0.43 <sup>2</sup>
Cirrhosis etiology, n (%)			
▪ Alcohol	7 (23.3)	10 (33.3)	0.39 <sup>2</sup>
▪ Nonalcoholic steatohepatitis	23 (76.7)	20 (66.7)	
<b>Cirrhosis severity</b>			
Child–Pugh score, median (range)	6 (5–9)	6 (5–11)	0.29 <sup>3</sup>
Child–Pugh score, n (%)			
▪ A	28 (93.3)	26 (86.7)	0.53 <sup>2</sup>
▪ B	2 (6.7)	3 (10.0)	
▪ C	0	1 (3.3)	
MELD score, median (range)	9.5 (6–13)	9.5 (6–30)	0.46 <sup>3</sup>
<b>Indication, n (%)</b>			
Primary prophylaxis	3 (10.0)	4 (13.3)	0.50 <sup>4</sup>
Active bleeding	1 (3.3)	5 (16.7)	0.09 <sup>4</sup>
Secondary prophylaxis	26 (86.7)	21 (70.0)	0.09 <sup>4</sup>
CYA, 2-octyl-cyanoacrylate; SD, standard deviation; MELD, model of end-stage liver disease.			
<sup>1</sup> Student's <i>t</i> test.			
<sup>2</sup> Chi-squared test.			
<sup>3</sup> Mann–Whitney <i>U</i> test.			
<sup>4</sup> Fisher's exact test.			

all survival period was 16.4 months (0.6–31.2 months) for combined treatment and 14.2 months (0.8–28.2 months) for EUS-guided coil embolization alone ( $P=0.90$ )

In the combined treatment group, 83.3% of individuals were free from reintervention during follow-up, compared with 60% in the single treatment group (HR 0.27, 95%CI 0.095–0.797;  $P=0.01$ ). The median reintervention-free period was 15.8 months (range 0.3–31.2 months) for those who underwent EUS-guided coil embolization with cyanoacrylate injection, compared with 12.5 months (0.1–20.2 months) for those who underwent EUS-guided coil embolization alone ( $P=0.01$ ). A cumulative incidence curve demonstrating the difference in the reintervention rates between the two study groups is shown in ► **Fig. 3**.

### Outcomes subanalysis

In a subanalysis excluding those patients treated with actively bleeding gastric varices, we found a non-statistically significant difference in the rebleeding and reintervention rates; however, we found a higher rate of gastric variceal reappearance in the

**► Table 2** Comparison of variceal and procedural characteristics and primary outcomes of the study.

	Coils + CYA (n = 30)	Coils alone (n = 30)	P value
<b>Variceal and procedural characteristics</b>			
Type, n (%)			
▪ GOV II	19 (63.3)	12 (40.0)	0.07 <sup>1</sup>
▪ IGV I	11 (36.7)	18 (60.0)	
Diameter, median (range), mm	21 (10–32)	25 (10–38)	0.15 <sup>2</sup>
Number of coils placed, median (range)	2 (1–3)	3 (1–7)	0.006 <sup>1</sup>
Size of coils placed, n			
▪ 10 mm	15	20	0.19 <sup>1</sup>
▪ 12 mm	12	14	0.60 <sup>1</sup>
▪ 14 mm	11	13	0.59 <sup>1</sup>
▪ 16 mm	12	13	0.79 <sup>1</sup>
CYA volume, median (range), mL	1.8 (1.2–2.4)	–	n/a
<b>Primary outcomes</b>			
Technical success, n (%)	30 (100.0)	30 (100.0)	n/a
Complete obliteration, n (%)	30 (100.0)	27 (90.0)	0.12 <sup>3</sup>
Immediate varix disappearance, n (%)	26 (86.7)	4 (13.3)	<0.001 <sup>3</sup>
Adverse events, n (%)	2 (6.7)	1 (3.3)	0.50 <sup>3</sup>
Type of adverse event, n (%)			
▪ Pain	1 (50.0)	1 (100.0)	
▪ Fever	1 (50.0)	0	
CYA, 2-octyl-cyanoacrylate; GOV II, gastroesophageal varices type II; IGV I, isolated gastric varices type I.			
<sup>1</sup> Chi-squared test.			
<sup>2</sup> Mann–Whitney <i>U</i> test.			
<sup>3</sup> Fisher's exact test.			

EUS-guided coiling-alone group (**Table 1 s**, available in online-only Supplementary Material).

In contrast, in a subanalysis excluding those patients treated for primary prophylaxis ( $n=7$ ), we found a statistically significant difference in the EUS-guided coiling group, with higher rebleeding, reappearance, and reintervention rates (**Table 2 s**).

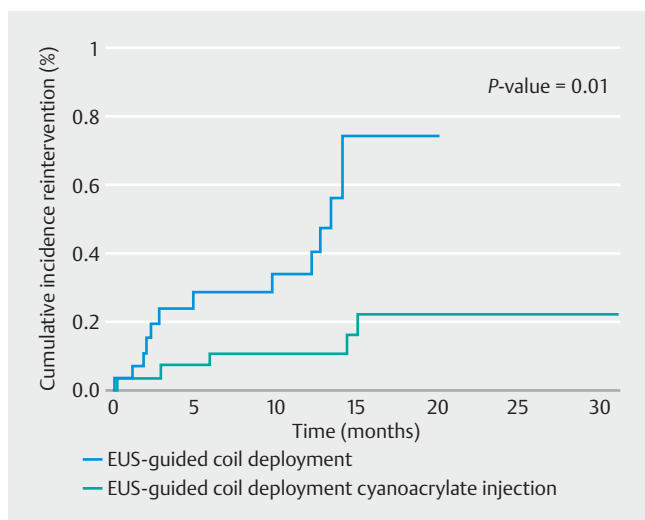
### Discussion

In our study population of patients with GOV II and IGV I, the combined therapy of EUS-guided coil deployment and cyanoacrylate injection resulted in a higher rate of variceal disappearance, a significantly lower rebleeding rate, and a significantly

**► Table 3** Comparison of the secondary outcomes of the study.

	Coils + CYA (n = 30)	Coils alone (n = 30)	P value
Survival time, median (range), months	16.4 (0.6–31.2)	14.2 (0.8–28.2)	0.90 <sup>1</sup>
Mortality rate, n (%)	9/30 (30.0%)	8/30 (26.7)	0.84 <sup>2</sup>
Cause of death, n			
Liver failure	1	0	
Hepatocellular carcinoma	3	2	
Uncontrolled hemorrhage	5	5	
Acute coronary syndrome	0	1	
Rebleeding, n (%)	1 (3.3)	6 (20.0)	0.04 <sup>2</sup>
Varix reappearance, n (%)	4 (13.3)	14 (46.7)	<0.001 <sup>2</sup>
Reintervention-free time, median (range)	15.8 (0.3–31.2)	12.5 (0.1–20.2)	0.01 <sup>3</sup>
Reintervention, n (%)	5 (16.7)	12 (40.0)	0.045 <sup>2</sup>
Type of reintervention, n (%)			0.09 <sup>2</sup>
Coils	0	5 (41.7)	
Coils + CYA	4 (80.0)	7 (58.3)	

CYA, 2-octyl-cyanoacrylate.  
<sup>1</sup> Long-rank test.  
<sup>2</sup> Chi-squared test.  
<sup>3</sup> Gray's test.

**► Fig. 3** Cumulative incidence curve of reintervention among all reinterventions performed. Five patients (16.7%) in the combined treatment group and 12 patients (40%) in the single treatment group underwent reinterventions (hazard ratio 0.27, 95% confidence interval 0.095–0.797;  $P=0.01$ ). Some patients had more than one reintervention.

lower level of reintervention compared with EUS-guided coil deployment alone.

Studies of EUS-guided treatment of gastric varices using cyanoacrylate, coil embolization, and combined cyanoacrylate injection and coil embolization have been conducted previously [9, 12, 14, 15, 17]. EUS-guided injection of cyanoacrylate alone is associated with a higher risk of pulmonary embolization or migration than EUS-guided coil embolization alone [13]. The combined approach, in which EUS-guided coil deployment is combined with cyanoacrylate injection with additional endosonographic varicealography, has been shown to be safe and effective in targeting the feeding vessel for complete variceal obliteration [9]. This method has the benefits of the use of a small volume of glue, with a higher procedural success rate and a high rate of complete gastric variceal disappearance [9, 14].

Here, we compared the combined approach with EUS-guided coil embolization in a parallel-randomized, controlled trial to determine the efficacy, safety, reappearance rate, recurrence of gastric variceal bleeding, and survival rates of both techniques. Previously, N-butyl-cyanoacrylate and 2-octyl-cyanoacrylate have been compared for the treatment of gastric varices, and we used the latter because it eliminates the need to dilute the cyanoacrylate with Lipiodol, which is viscous and makes injection more difficult, and has a longer polymerization time, which reduces the risk of endoscope damage because of glue impaction in the working channel [9, 10].

In our population, the obliteration rate of combined coil and cyanoacrylate embolization was 100%, compared with 90% after coil embolization alone, when confirmation was defined by EUS Doppler; whereas, when evaluating the immediate varix disappearance by endoscopic view, the combined therapy achieved an 86.6% disappearance rate compared with 13.3% in the EUS-guided coiling group. Therefore, EUS Doppler evaluation confirmed a higher obliteration rate for EUS-guided combined therapy more accurately than evaluation of varix disappearance by endoscopic view. EUS Doppler evaluation for defining varix obliteration should therefore be used instead of the endoscopic disappearance of gastric varices during EGD.

Despite the confirmation of gastric variceal obliteration, absence of flow during EUS Doppler was not significantly different between the study groups (100% for combined therapy vs 90% for coil embolization alone); EUS Doppler confirmation of obliteration also did not necessarily predict the need for further reinterventions. However, a higher need for reintervention and a higher rebleeding rate were noted in those patients treated with EUS-guided coiling alone in whom immediate varix disappearance evaluated via EGD was statistically inferior compared with that in the combined therapy group.

Notably, 40% of patients in the single treatment group required additional coil embolization or combined coil and cyanoacrylate embolization during the follow-up period. The high level of reintervention following coil embolization without cyanoacrylate will affect the relative cost-effectiveness of the two techniques, considering that patients initially allocated to combined therapy required fewer reinterventions than those in the EUS-guided coiling-alone group.

A limitation of the present study is the generalizability of these findings because all procedures were performed by a single endoscopist at a single tertiary center. Even though there was no statistically significant difference in the number of patients treated for active bleeding in the two groups, a higher number of patients were treated with EUS-guided coiling alone compared with the combined therapy (16.7% vs. 3.3%;  $P=0.09$ ) and this might have a role in some of the difference in outcomes. Despite the promising results described herein, the generalizability of these findings may depend on the availability of endoscopists trained to offer these EUS interventional procedures. Therefore, a multicenter, superiority, randomized controlled trial should be conducted to clarify the potential real-world clinical impact of EUS-guided placement of coils and cyanoacrylate.

In conclusion, combined EUS-guided coil embolization and cyanoacrylate injection achieved excellent clinical success, with low rates of rebleeding and reintervention, and high reintervention-free time, in patients with GOV II and IGV I.

### Competing interests

The authors declare that they have no conflict of interest.

### References

- [1] Khoury T, Nadella D, Wiles A et al. A review article on gastric varices with focus on the emerging role of endoscopic ultrasound-guided angiotherapy. *Eur J Gastroenterol Hepatol* 2018; 30: 1411–1415
- [2] Sarin SK, Lahoti D, Saxena SP et al. Prevalence, classification and natural history of gastric varices: a long-term follow-up study in 568 portal hypertension patients. *Hepatology* 1992; 16: 1343–1349
- [3] Irani S, Kowdley K, Kozarek R. Gastric varices: an updated review of management. *J Clin Gastroenterol* 2011; 45: 133–148
- [4] Joo HS, Jang JY, Eun SH et al. Long-term results of endoscopic histoacryl (N-butyl-2-cyanoacrylate) injection for treatment of gastric varices—a 10-year experience. *Korean J Gastroenterol* 2007; 49: 320–326
- [5] van Beek AP, van Erpecum KJ. Fatal N-butyl-2-cyanoacrylate pulmonary embolism after sclerotherapy for variceal bleeding. *Endoscopy* 2005; 37: 687
- [6] Hwang SS, Kim HH, Park SH et al. N-butyl-2-cyanoacrylate pulmonary embolism after endoscopic injection sclerotherapy for gastric variceal bleeding. *J Comput Assist Tomogr* 2001; 25: 16–22
- [7] Soetikno R, Asokkumar R, Chang J et al. Improving the technique of N-butyl cyanoacrylate (N-BCA) glue injection into gastric varices. *Gastrointest Endosc* 2016; 83: AB643
- [8] Hill H, Chick JFB, Hage A et al. N-butyl cyanoacrylate embolotherapy: techniques, complications, and management. *Diagn Interv Radiol* 2018; 24: 98–103
- [9] Robles-Medrandra C, Valero M, Nebel JA et al. Endoscopic-ultrasound-guided coil and cyanoacrylate embolization for gastric varices and the roles of endoscopic Doppler and endosonographic varicealography in vascular targeting. *Dig Endosc* 2018; 31: 283–290
- [10] Bick BL, Al-Haddad M, Liangpunsakul S et al. EUS-guided fine needle injection is superior to direct endoscopic injection of 2-octyl cyanoacrylate for the treatment of gastric variceal bleeding. *Surg Endosc* 2019; 33: 1837–1845
- [11] Hikichi T, Obara K, Nakamura S et al. Potential application of interventional endoscopic ultrasonography for the treatment of esophageal and gastric varices. *Dig Endosc* 2015; 27: (Suppl. 01): 17–22
- [12] Romero-Castro R, Pellicer-Bautista F, Giovannini M et al. Endoscopic ultrasound (EUS)-guided coil embolization therapy in gastric varices. *Endoscopy* 2010; 42: (Suppl. 02): E35–E36
- [13] Romero-Castro R, Ellrichmann M, Ortiz-Moyano C et al. EUS-guided coil versus cyanoacrylate therapy for the treatment of gastric varices: a multicenter study (with videos). *Gastrointest Endosc* 2013; 78: 711–721
- [14] Binmoeller KF, Weilert F, Shah JN et al. EUS-guided transesophageal treatment of gastric fundal varices with combined coiling and cyanoacrylate glue injection (with videos). *Gastrointest Endosc* 2011; 74: 1019–1025
- [15] Bhat YM, Weilert F, Fredrick RT et al. EUS-guided treatment of gastric fundal varices with combined injection of coils and cyanoacrylate glue: a large U.S. experience over 6 years (with video). *Gastrointest Endosc* 2016; 83: 1164–1172
- [16] de Franchis R. Baveno VI Faculty. Expanding consensus in portal hypertension: Report of the Baveno VI Consensus Workshop: Stratifying risk and individualizing care for portal hypertension. *J Hepatol* 2015; 63: 743–752
- [17] Romero-Castro R, Pellicer-Bautista F, Jimenez-Saenz M et al. EUS-guided injection of cyanoacrylate in perforating feeding veins in gastric varices: results in 5 cases. *Gastrointest Endosc* 2007; 66: 402–407