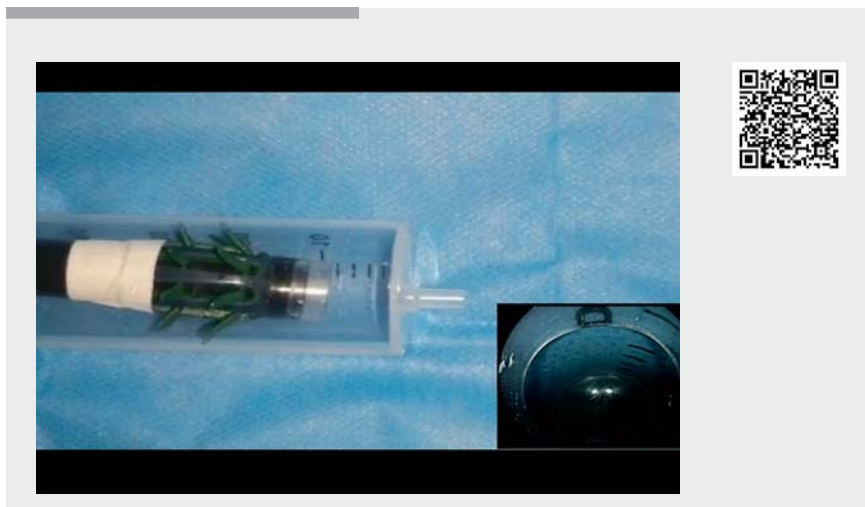


Endocuff combined with buffer-traction: a method to make endoscopic submucosal dissection in proximal colon easy

We have successfully combined an endocuff and buffer-traction for endoscopic submucosal dissection (ESD) in the proximal colon (▶ **Video 1**). This patient had a severe adhesion in the abdominal cavity from previous abdominal surgery. A 3-cm laterally spreading neoplasm was found at 5 cm from the anastomosis.

A circumferential incision of the lesion was performed that was greatly affected by breathing movement. The endocuff was set in the endoscopic tip as an anchor to stabilize the tip, maximally ensuring that the distance between the tip and the lesion was relatively fixed without affecting fine manipulation of the tip in individual mucosal folds. Buffer-traction was completed by using dental floss and a rubber band. Two circles of 3-mm in diameter were made by elastic dental floss and interconnected by a rubber band of approximately 3 mm. One dental floss circle was fixed to the border of the lesion by using 1 to 2 clips; the other floss circle was fixed to the normal intestinal wall opposite the lesion as the patient inhaled.

Gas injection can both stretch and fix the lesion. During ESD, the actions of the endoscope tip can repetitively pull the fixed clips, which were more likely to detach because of the thin colonic mucosa. We therefore used the rubber band to buffer the clips from the pull of the endoscope, and the stability of endoscopic operability was markedly improved. ESD was performed in a relatively distant observation instead of close observation, and the breathing effect was greatly reduced. Finally, the lesion was successfully resected. No perforation or delayed bleeding was observed after ESD. Postoperative pathological examination confirmed the diagnosis of a colonic tubular adenoma with a local high-grade intraepithelial neoplasm. The margin was tumor-cell negative.



▶ **Video 1** Combined endocuff and buffer-traction for endoscopic submucosal dissection in proximal colon.

An endocuff combined with our buffer-traction method can improve poor endoscopic operability, decrease colonic movement with breathing, and increase the success rate of ESD in the proximal colon.

Endoscopy_UCTN_Code_TTT_1AQ_2AD

Competing interests

The authors declare that they have no conflict of interest.

The authors

Xiaotian Sun^{1,2}, Zheng Lu¹

- 1 Liver Cirrhosis Diagnosis and Treatment Center, the Fifth Medical Center of Chinese PLA General Hospital, Beijing 100039, China
- 2 Department of Internal Medicine, Clinic of August First Film Studio, Beijing South Medical District of Chinese PLA General Hospital, Beijing 100161, China

Corresponding author

Zheng Lu, MD

Liver Cirrhosis Diagnosis and Treatment Center, The Fifth Medical Center of Chinese PLA General Hospital, No. 100 Middle Road in Fourth West Ring, Beijing 100039, China
 Fax: +86-10-66823704
 13818223446@163.com

Bibliography

Endoscopy 2021; 53: E54
DOI 10.1055/a-1158-8977
ISSN 0013-726X
published online 19.6.2020
 © 2020. Thieme. All rights reserved.
 Georg Thieme Verlag KG, Rüdigerstraße 14,
 70469 Stuttgart, Germany