

## Endoscopic ultrasound-guided gastroenterostomy with water-jet filling technique through a 19G needle to treat complete malignant duodenal obstruction

Duodenal self-expandable metal stenting is the most common treatment for duodenal malignant obstruction. However, when it is impossible to pass a guidewire through the obstruction, gastroenterostomy using a lumen-apposing metal stent (LAMS) is an effective alternative [1]. Nevertheless, it is commonly necessary to introduce a filling catheter to fill the bowel with water [2] or to place a guidance balloon [3].

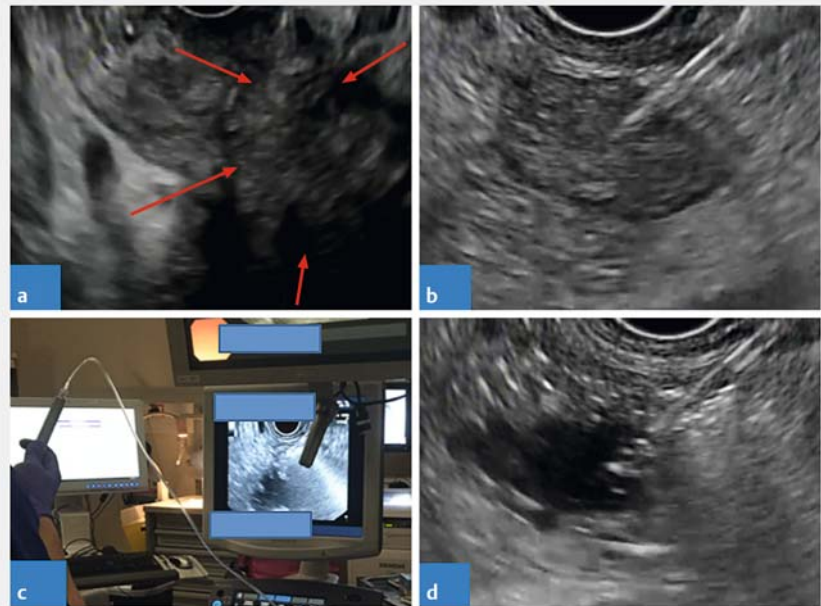
Our case involved an obstruction so severe that even a guidewire could not be passed through the tumor. The patient was a 72-year-old man, with a past history of terminal colostomy for colon cancer, who was referred for a duodenal obstruction due to pancreatic adenocarcinoma. Two attempts at duodenal stenting failed and we decided to perform an endoscopic ultrasound (EUS)-guided gastroenterostomy as an alternative.

EUS-guided identification of the duodenum where it was exiting from the large tumor (► **Fig. 1**; ► **Video 1**) allowed targeted puncture with a 19G needle. To fill the bowel quickly, we first injected contrast and then immediately connected the water pump directly to the 19G needle (► **Fig. 2**) to increase the liquid flow rate in the bowel and obtain a large expansion. When the duodenum was distended, a guidewire was placed and a 20×10-mm LAMS (Axios; Boston Scientific, Marlborough, Massachusetts, USA) was inserted. No leakage was apparent on the radiographic check.

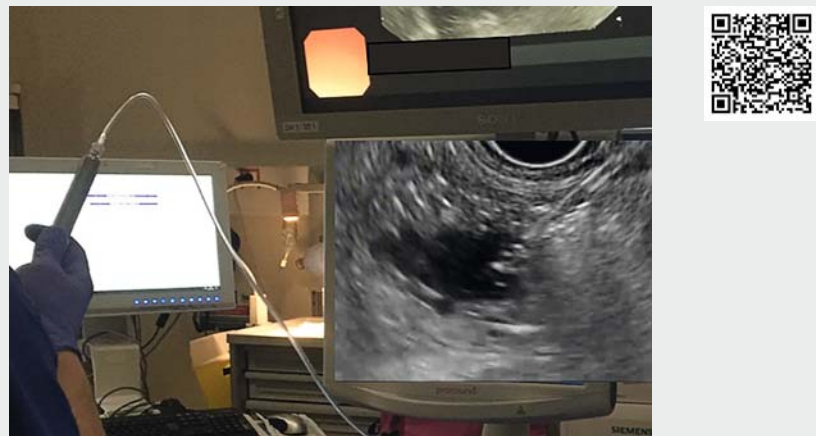The same evening, transit has resumed through the colostomy and, despite initial dietary instructions, the patient left the unit to eat a hamburger.

At 1-month follow-up, no postoperative complications had occurred and the patient had gained 4 kg.

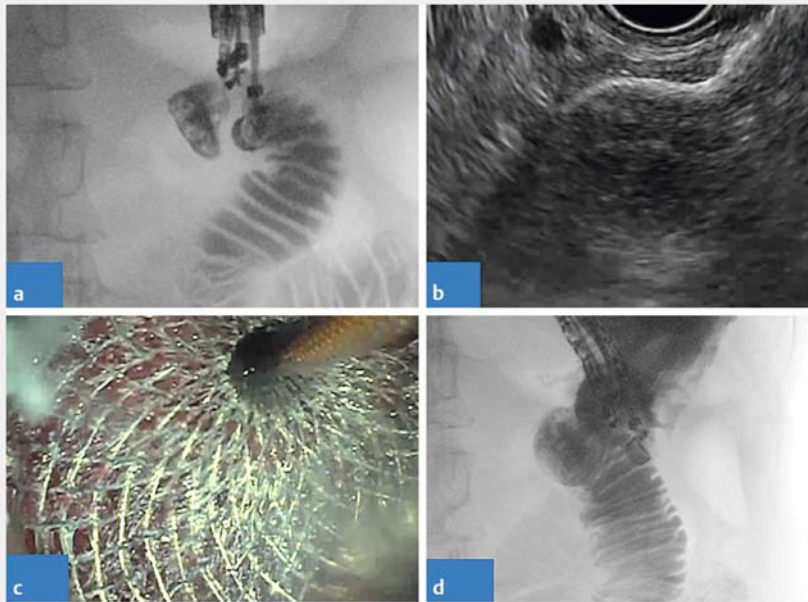
The use of the water pump directly on the needle is a simple technique to obtain bowel filling as quickly as possible, allowing a large distension without multiple manipulations of the syringe.



► **Fig. 1** First part of the procedure of endoscopic ultrasound (EUS)-guided gastroenterostomy. **a, b** EUS images showing: **a** the tumor with the small bowel disappearing into the lesion; **b** the normal appearance of the duodenum beyond the tumor. **c, d** Expansion of the small bowel with rapid water-jet injection of saline and contrast: **c** photograph of the procedure being performed; **d** EUS view of the distended duodenum.



► **Video 1** Endoscopic ultrasound-guided gastroenterostomy with water pump filling to expand the duodenum.



► **Fig. 2** Second part of the procedure with placement of the lumen-apposing metal stent (LAMS). **a** Radiographic image showing opacification with contrast and filling of the small bowel. **b, c** Placement of the LAMS, as shown on: **b** endoscopic ultrasound view; **c** endoscopic view. **d** Fluoroscopic check following LAMS placement showing no leakage of contrast.

Endoscopy\_UCTN\_Code\_TTT\_1AO\_2AH

### Competing interests

The authors declare that they have no conflict of interest.

### The authors

Anaëlle Collin<sup>1</sup>, Sanaa Brahmia<sup>1</sup>, Florian Rostain<sup>1</sup>, Alexandru Lupu<sup>1</sup>, Laura Calavas<sup>2</sup>, Jérémie Jacques<sup>3</sup>, Mathieu Pioche<sup>1,4</sup>

1 Department of Endoscopy and Gastroenterology, Edouard Herriot Hospital, Lyon, France

2 Department of Digestive Oncology, Edouard Herriot Hospital, Lyon, France

3 Department of Endoscopy and Gastroenterology, Dupuytren Hospital, Limoges, France

4 INSERM U1032, LabTau, Lyon, France

### Corresponding author

**Mathieu Pioche, MD**

Endoscopy unit, Digestive Disease department, Pavillon L – Edouard Herriot Hospital, 69437 Lyon, France  
mathieu.pioche@chu-lyon.fr

### References

- [1] Chen Y-I, Itoi T, Baron TH et al. EUS-guided gastroenterostomy is comparable to enteral stenting with fewer re-interventions in malignant gastric outlet obstruction. *Surg Endosc* 2017; 31: 2946–2952
- [2] Schaefer M, Taibi A, Lepetit H et al. A naso-biliary drain connected to a waterjet system to facilitate endoscopic ultrasound-guided gastrojejunostomy. *Endoscopy* 2019; 51: E158–E159
- [3] Itoi T, Baron TH, Khashab MA et al. Technical review of endoscopic ultrasonography-guided gastroenterostomy in 2017. *Dig Endosc* 2017; 29: 495–502

### Bibliography

*Endoscopy* 2021; 53: E7–E8

DOI 10.1055/a-1167-8099

ISSN 0013-726X

published online 19.5.2020

© 2020, Thieme. All rights reserved.

Georg Thieme Verlag KG, Rüdigerstraße 14, 70469 Stuttgart, Germany

### ENDOSCOPY E-VIDEOS

<https://eref.thieme.de/e-videos>



*Endoscopy E-Videos* is a free access online section, reporting on interesting cases and new

techniques in gastroenterological endoscopy. All papers include a high quality video and all contributions are freely accessible online.

This section has its own submission website at

<https://mc.manuscriptcentral.com/e-videos>