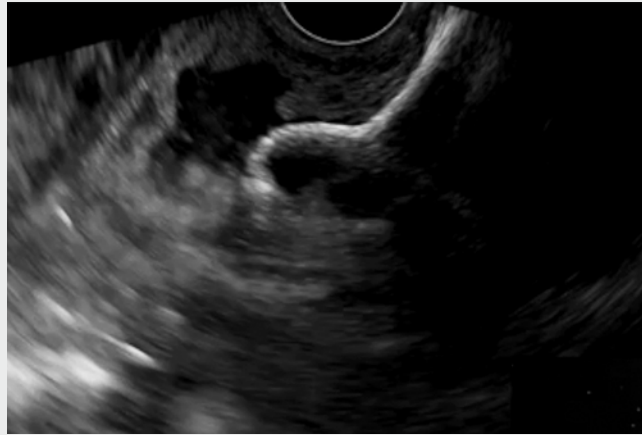

## Endoscopic ultrasound-guided colojejunal anastomosis: new treatment management for enteral occlusion

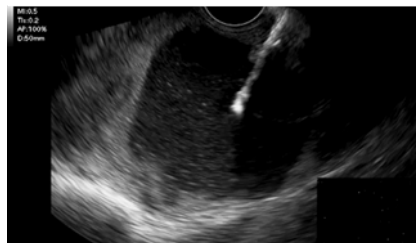Digestive obstruction can be the final issue arising from digestive carcinoma with peritoneal carcinomatosis [1]. Endoscopic ultrasound (EUS)-guided gastrointestinal anastomosis has been developed to manage malignant gastric outlet obstruction with clinical results similar to that of surgical laparoscopy or endoscopic endoluminal stenting [2–4]. In some patients with advanced digestive adenocarcinoma, the development of peritoneal carcinomatosis can lead to local obstruction, sometimes located in the small bowel with upstream dilatation that can be treated neither endoscopically nor surgically [1]. Here we present an endoscopic technique that allows bypassing the distal bowel obstruction by performing an EUS-guided colojejunal anastomosis with a lumen-apposing metal stent (LAMS).

A 46-year-old man with an adenocarcinoma of the small bowel resulting in enteral occlusion had undergone a surgical resection 2 years prior. At that time, 30 cm of the small bowel was resected, and pathological examination showed a well-differentiated pT4N0R0 adenocarcinoma. He was referred 6 months later for tumor recurrence presenting with peritoneal carcinomatosis. He was treated with chemotherapy and then hyperthermic intraperitoneal chemotherapy. He developed peritoneal recurrence of the tumor 10 months later, which was again managed with systemic chemotherapy. He then presented with bowel obstructive syndrome on computed tomography (CT) scan with mesenteric lymph nodes and dilated small bowel limbs in the left flank close to the descending colon.

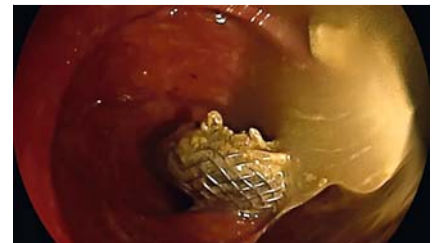We decided to perform EUS-guided colojejunal anastomosis (▶ **Video 1**). After placing the EUS scope (Pentax, Japan) within the left colon, we localized the closer dilated small bowel limb under EUS



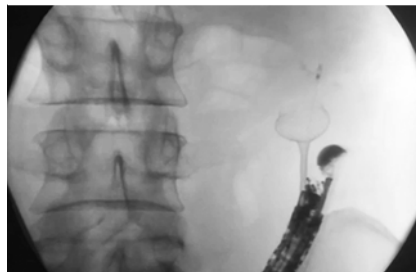
▶ **Video 1** Endoscopic ultrasound-guided colojejunal anastomosis for enteral occlusion.



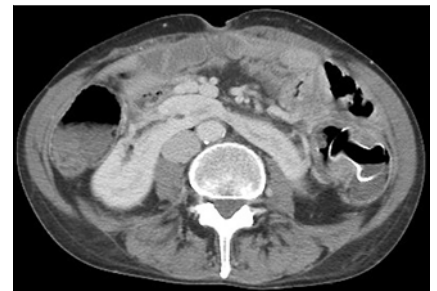
▶ **Fig. 1** Insertion of the lumen-apposing metal stent into the jejunum through the descending colon.



▶ **Fig. 3** Endoscopic view of the proximal flange release.



▶ **Fig. 2** X-ray view of the distal flange release.



▶ **Fig. 4** Computed tomography scan of the colojejunal anastomosis with lumen-apposing metal stent.

guidance with X-ray control. Then we directly placed a 20-mm LAMS (► **Fig. 1**, ► **Fig. 2**), connecting the small bowel upstream of the obstruction to the left colon (► **Fig. 3**). The post-operative course was uneventful (► **Fig. 4**) with complete recovery of the patient, who resumed the chemotherapy protocol.

Endoscopy\_UCTN\_Code\_TTT\_1AS\_2AG

### Competing interests

Dr. Barthet and Dr. Gonzalez are consultants for Boston Scientific. None of the other authors have any conflict of interest to declare.

### The authors

**Mohamed Gasmı, Jean-Michel Gonzalez, Arthur Falque, Marc Barthet**

Department of Hepatogastroenterology, Assistance Publique des Hôpitaux de Marseille, Aix-Marseille Université, Hôpital Nord, Marseille, France

### Corresponding author

**Marc Barthet, MD**

Department of Hepatogastroenterology, AP-HM, Aix-Marseille Université, Hôpital Nord, Chemin des Bourrelly 13015 Marseille, France  
 Fax: +33-4-91968737  
 marc.barthet@ap-hm.fr

### References

- [1] Lambert LA, Hendrix RJ. Palliative management of advanced peritoneal carcinomatosis. *Surg Oncol Clin N Am* 2018; 27: 585–602
- [2] Irani S, Itoi T, Baron TH et al. EUS-guided gastroenterostomy: techniques from East to West. *Video GIE* 2019; 5: 48–50
- [3] Chen YI, Itoi T, Baron TH et al. EUS-guided gastroenterostomy is comparable to enteral stenting with fewer re-interventions in malignant gastric outlet obstructions. *Surg Endosc* 2017; 31: 2946–2952
- [4] Perez-Miranda M, Tyberg A, Poletto D et al. EUS-guided gastrojejunostomy versus laparoscopic gastrojejunostomy: an international collaborative study. *J Clin Gastroenterol* 2017; 51: 896–899

### Bibliography

Endoscopy 2021; 53: E23–E24  
**DOI** 10.1055/a-1173-7584  
**ISSN** 0013-726X  
**published online** 29.5.2020  
 © 2020. Thieme. All rights reserved.  
 Georg Thieme Verlag KG, Rüdigerstraße 14, 70469 Stuttgart, Germany

### ENDOSCOPY E-VIDEOS

<https://eref.thieme.de/e-videos>



*Endoscopy E-Videos* is a free access online section, reporting on interesting cases and new techniques in gastroenterological endoscopy. All papers include a high quality video and all contributions are freely accessible online.

This section has its own submission website at <https://mc.manuscriptcentral.com/e-videos>