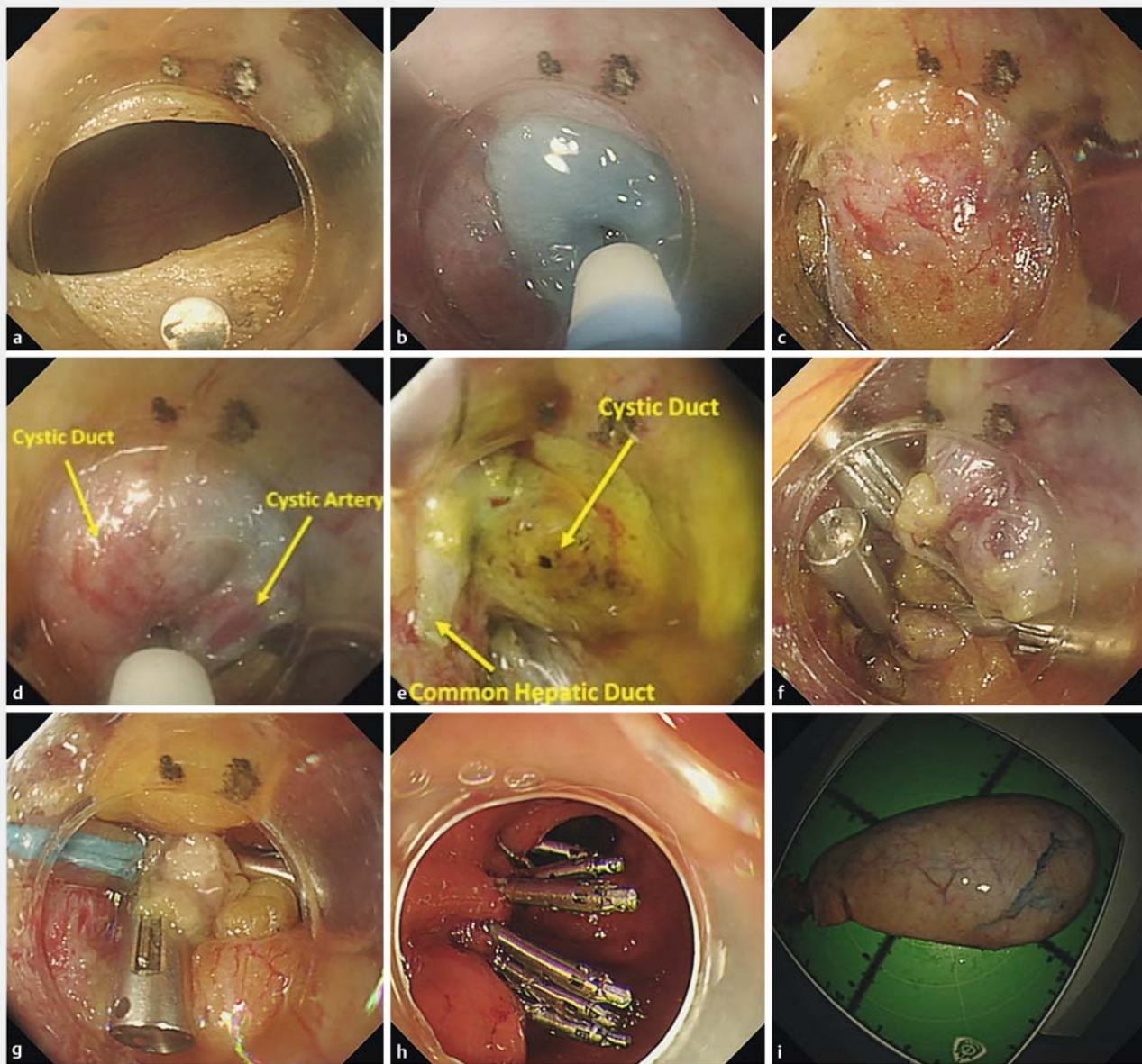


Endoscopic transgastric cholecystectomy: a novel approach for minimally invasive cholecystectomy

Natural-orifice transluminal endoscopic surgery (NOTES) has been developed as a step towards less invasive procedures. Transvaginal, transgastric, and transcolonic cholecystectomy have been de-

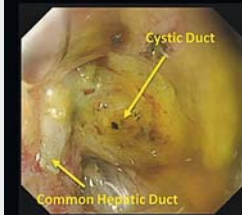
scribed, but mostly carried out with the assistance of laparoscopic guidance, or with another device for extraction, such as a second endoscope or transabdominal instrument [1–3]. We report a novel

technique called endoscopic transgastric cholecystectomy (ETGC) that is carried out with a single scope and without laparoscopic guidance or other transabdominal instruments.

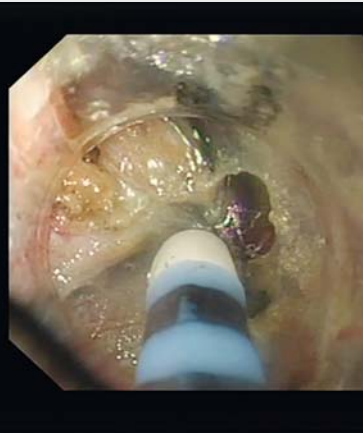

► **Fig. 1** Endoscopic transgastric cholecystectomy in a 55-year-old gentleman. **a** Active perforation of the anterior wall of the gastric antrum. **b** Dissection of the fundus of the gallbladder. **c** Dissection of the neck of the gallbladder. **d** Dissection and electrocoagulation of the cystic artery. **e** Dissection of the hepatocystic triangle. **f** Clipping and incision of the cystic duct. **g** Ligation of the cystic duct stump. **h** Closure of the gastric wall. **i** En bloc resection of the gallbladder.

Dissection of the hepatocystic triangle



"critical view of safety"



Video 1 Endoscopic transgastric cholecystectomy in a 55-year-old gentleman.

The anterior wall of the gastric antrum is actively perforated with a sterile colonoscope. The gallbladder is then exposed and dissected from the fundus to the neck. Intermittent injection of normal saline to the connective tissues is necessary to create working space. Then, a thorough dissection of the hepatocystic triangle is performed to obtain the "critical view of safety." The cystic artery is dissected and electrocoagulated. Once the cystic duct is fully dissected, it is closed with clips and then incised, and the gallbladder is extracted with a snare. To prevent bile leakage, the cystic duct stump is ligated. Careful hemostasis and scope reflection should be carried out to check for potential bleeding in the serosa of the gastric wall. Finally, the gastric wall is closed with clips or purse suture techniques (► **Fig. 1**; ► **Video 1**).

Between March 2019 and December 2019, eight patients underwent ETGC in our center. All the procedures were successful and there were no procedure-related adverse events. The median operation time was 4 h. The patients all had an uneventful course after the procedure. Median hospital stay was 2.5 days. ETGC offers the potential for performance of truly scarless cholecystectomy and reduces pain. At the current stage the procedure should only be performed on selected patients without severe inflammation or abdominal adhesion, by experienced hands and with surgeons on standby. Innovations in endoscopic

instruments will likely yield better outcomes.

Endoscopy_UCTN_Code_TTT_1AR_2AK

Acknowledgments

This study was supported by grants from the National Natural Science Foundation of China (81873552 and 81670483), Major Project of Shanghai Municipal Science and Technology Committee (18ZR1406700 and 16DZ2280900), Shanghai Sailing Program of Shanghai Municipal Science and Technology Committee (2018YF1403700), Shanghai Rising-Star Program (19QA1401900), Chen Guang Program of Shanghai Municipal Education Commission (15CG04, 18CG07), and Outstanding Young Doctor Training Project of Shanghai Municipal Commission of Health and Family Planning (2017YQ026).

Competing interests

The authors declare that they have no conflict of interest.

The authors

Xin-Yang Liu, Quan-Lin Li, Xiao-Yue Xu, Jia-Xin Xu, Ming-Yan Cai, Ping Wang, Ping-Hong Zhou

Endoscopy Center and Endoscopy Research Institute, Zhongshan Hospital, Fudan University, Shanghai, China

Corresponding author

Ping-Hong Zhou, MD, PhD, FASGE

Endoscopy Center and Endoscopy Research Institute, Zhongshan Hospital, Fudan University, Shanghai, China
Fax: +86-21-64038472
zhou.pinghong@zs-hospital.sh.cn

References

- [1] Gaillard M, Tranchart H, Lainas P et al. New minimally invasive approaches for cholecystectomy: review of literature. *World J Gastrointest Surg* 2015; 7: 243–248
- [2] Park PO, Bergstrom M, Ikeda K et al. Experimental studies of transgastric gallbladder surgery: cholecystectomy and cholecystogastric anastomosis (videos). *Gastrointest Endosc* 2005; 61: 601–606
- [3] Gumbs AA, Fowler D, Milone L et al. Transvaginal natural orifice transluminal endoscopic surgery cholecystectomy: early evolution of the technique. *Ann Surg* 2009; 249: 908–912

Bibliography

Endoscopy 2021; 53: E50–E51

DOI 10.1055/a-1180-7661

ISSN 0013-726X

published online 5.6.2020

© 2020. Thieme. All rights reserved.

Georg Thieme Verlag KG, Rüdigerstraße 14, 70469 Stuttgart, Germany

ENDOSCOPY E-VIDEOS

<https://eref.thieme.de/e-videos>



Endoscopy E-Videos is a free access online section, reporting on interesting cases and new

techniques in gastroenterological endoscopy. All papers include a high quality video and all contributions are freely accessible online.

This section has its own submission website at

<https://mc.manuscriptcentral.com/e-videos>