

Treatment of Ipsilateral Breast Cancer Recurrence (IBCR) after Breast Conservation Therapy (BCT)

Therapie des ipsilateralen in-Brust-Rezidivs (IBR) nach brusterhaltender Therapie (BET)



Authors

Bernd Gerber, Steffi Hartmann, Angrit Stachs

Affiliation

Department of Obstetrics and Gynaecology,
Klinikum Südstadt Hansesstadt Rostock

Key words

breast cancer, ipsilateral breast recurrence, second primary breast cancer, repeat lumpectomy, salvage mastectomy

Schlüsselwörter

Brustkrebs, In-Brust-Rezidiv, Zweitkarzinom, erneute Brusterhaltung, Salvagemastektomie

published online 18.03.2021

Bibliography

Senologie 2021; 18: 126–135

DOI 10.1055/a-1196-2951

ISSN 1611-6453

© 2021. The Author(s).

This is an open access article published by Thieme under the terms of the Creative Commons Attribution-NonDerivative-NonCommercial License, permitting copying and reproduction so long as the original work is given appropriate credit. Contents may not be used for commercial purposes, or adapted, remixed, transformed or built upon. (<https://creativecommons.org/licenses/by-nc-nd/4.0/>)

Georg Thieme Verlag KG, Rüdigerstraße 14,
70469 Stuttgart, Germany

Correspondence

Prof. Bernd Gerber, M.D., Ph.D.

Department of Obstetrics and Gynaecology, Rostock
University Medical Centre, Südtring 81, 18059 Rostock,
Germany

bernd.gerber@med.uni-rostock.de

ABSTRACT

In-breast recurrence or ipsilateral breast cancer recurrence (IBCR) suspected by imaging or palpation, second primary

carcinoma and any distant metastases should be ruled out by core biopsy prior to breast surgery. The surgical standard in IBCR management is salvage mastectomy. Increasingly, however, patients express a justified desire for breast conservation in IBCR. In favourable relations of tumour and breast size, long interval between primary disease and IBCR recurrence, favourable tumour biology and ruled out distant metastases, re-BCT may be an option. As patients usually have undergone adjuvant radiotherapy already, re-radiotherapy (brachytherapy/percutaneous RT) should be explored. Systemic management must be based on tumour biology and prior treatment. While the risk of local recurrence increases following re-BCT, overall survival is not compromised.

ZUSAMMENFASSUNG

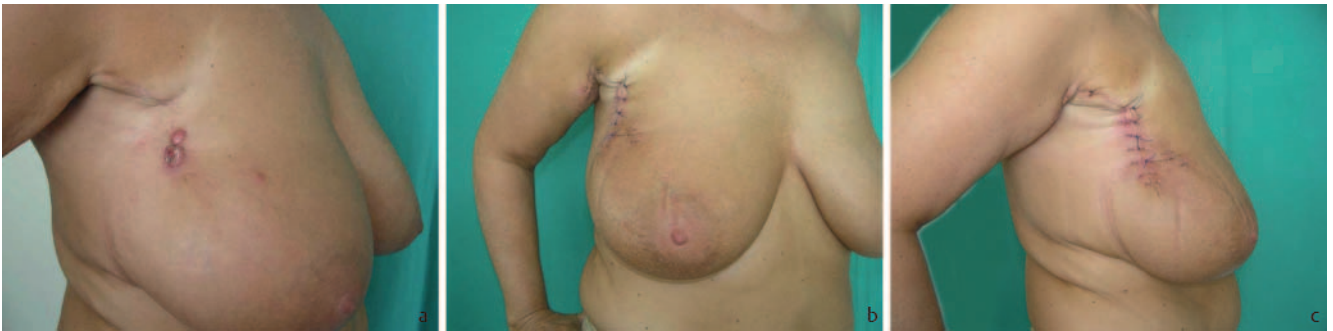Bei einem durch bildgebende Verfahren oder Tastbefund vermuteten In-Brust-Rezidiv (IBR) sollten vor der Brustoperation durch Stanzbiopsie ein Zweitkarzinom und das Vorliegen von Fernmetastasen ausgeschlossen werden. Den operativen Standard in der Behandlung eines IBR stellt die Salvagemastektomie dar. Immer häufiger wird jedoch der berechtigte Wunsch nach Brusterhaltung geäußert. Bei entsprechendem Wunsch, günstiger Rezidivtumorgroße zur Brustgröße, langem zeitlichem Intervall zur Primärerkrankung, günstiger Tumorbiologie und Ausschluss von Fernmetastasen kann auch eine Re-BET erfolgen. Da in der Regel bereits eine adjuvante Strahlentherapie erfolgt ist, sollte die erneute Bestrahlung (Brachytherapie/perkutane RT) geprüft werden. Die Systemtherapie muss sich an der Tumorbiologie und den Vortherapien orientieren. Nach einer Re-BET ist das erneute lokale Rezidivrisiko zwar erhöht, das Gesamtüberleben wird aber nicht verschlechtert.

Introduction

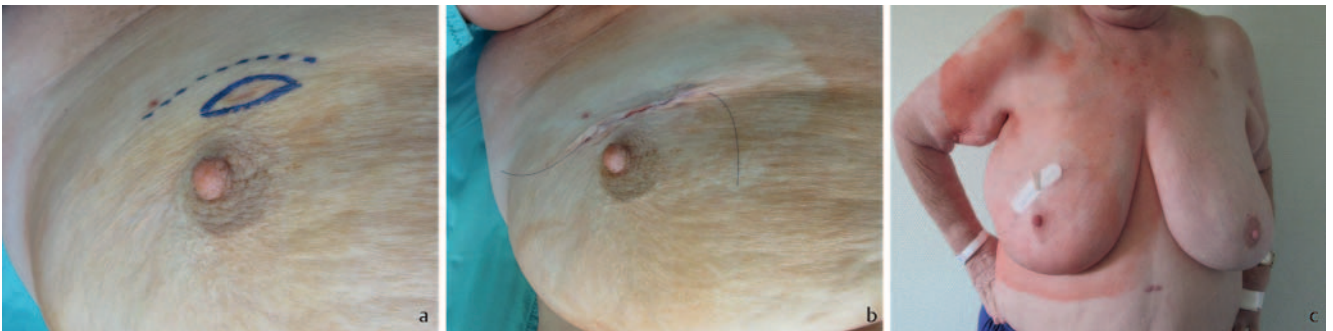With the increasing understanding of the tumour biology in breast cancer, surgery has also changed. In 2017, 86 % of patients with pT1 breast cancer and 71 % with pT2 tumours underwent

breast-conserving surgery (<https://www.onkozeit.de/2019/03/21/jahresberichte-der-zertifizierungssysteme-2019/>).

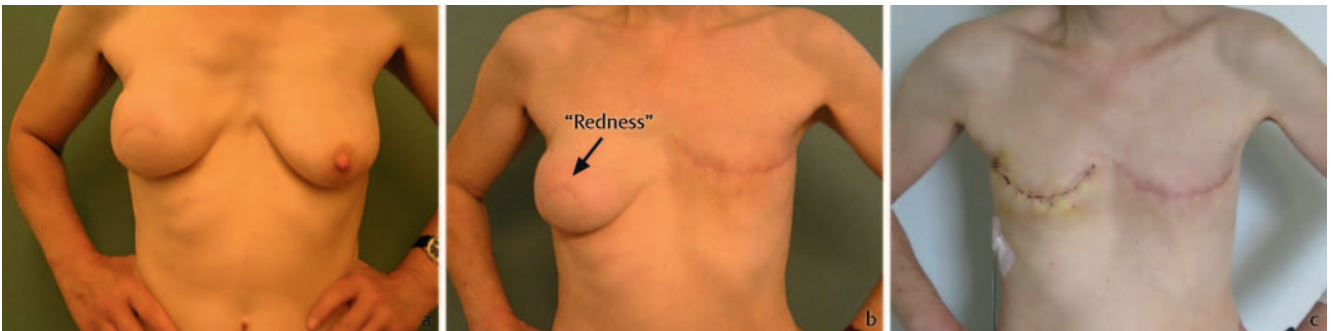
Locoregional recurrence is defined as the recurrence of invasive or non-invasive breast cancer in the [1, 2]:



► **Fig. 1** 58-year-old female with prior NAST and BCT for invasive ductal breast cancer ypT1c (10 mm) ypN0 (0/2 sn) cM0 R0; G3, L0 V0, TNBC, Ki-67 40%; status post radiation **a** after 4.5 years cutaneous recurrence (“ipsilateral breast cancer recurrence”), no IBCR on imaging, cN0 cM0; **b, c** after re-BCT.



► **Fig. 2** 70-year-old female with prior BET for invasive ductal right breast cancer pT2 (30 mm) pN0 (0/2 sn) cM0; G2, L0 V0, ER-ICA 12/12, PgR-ICA 10/12, Ki-67 20%; status post irradiation **a** 2 years later cutaneous metastasis “ipsilateral breast cancer recurrence” cN0 cM0, dashed line old scar, solid line cutaneous recurrence; **b, c** After re-BET, (better excision of cutaneous metastasis).



► **Fig. 3** 45-year-old female with **a** prior SSM with LADO flap and prosthetic reconstruction for invasive right ductal breast cancer pT1c (m: 20, 13, 6 mm) pN0 (0/1 sn) cM0; G1, L0 V0, ER-ICA 10/12, PgR-ICA 10/12, HER2 negative, Ki-67 20 %; 4 years of tamoxifen **b** 6 years later contralateral multifocal DCIS, mastectomy; **c** after 6.5 years right lymphangial carcinomatosis (redness arrow), **d** after right salvage mastectomy.

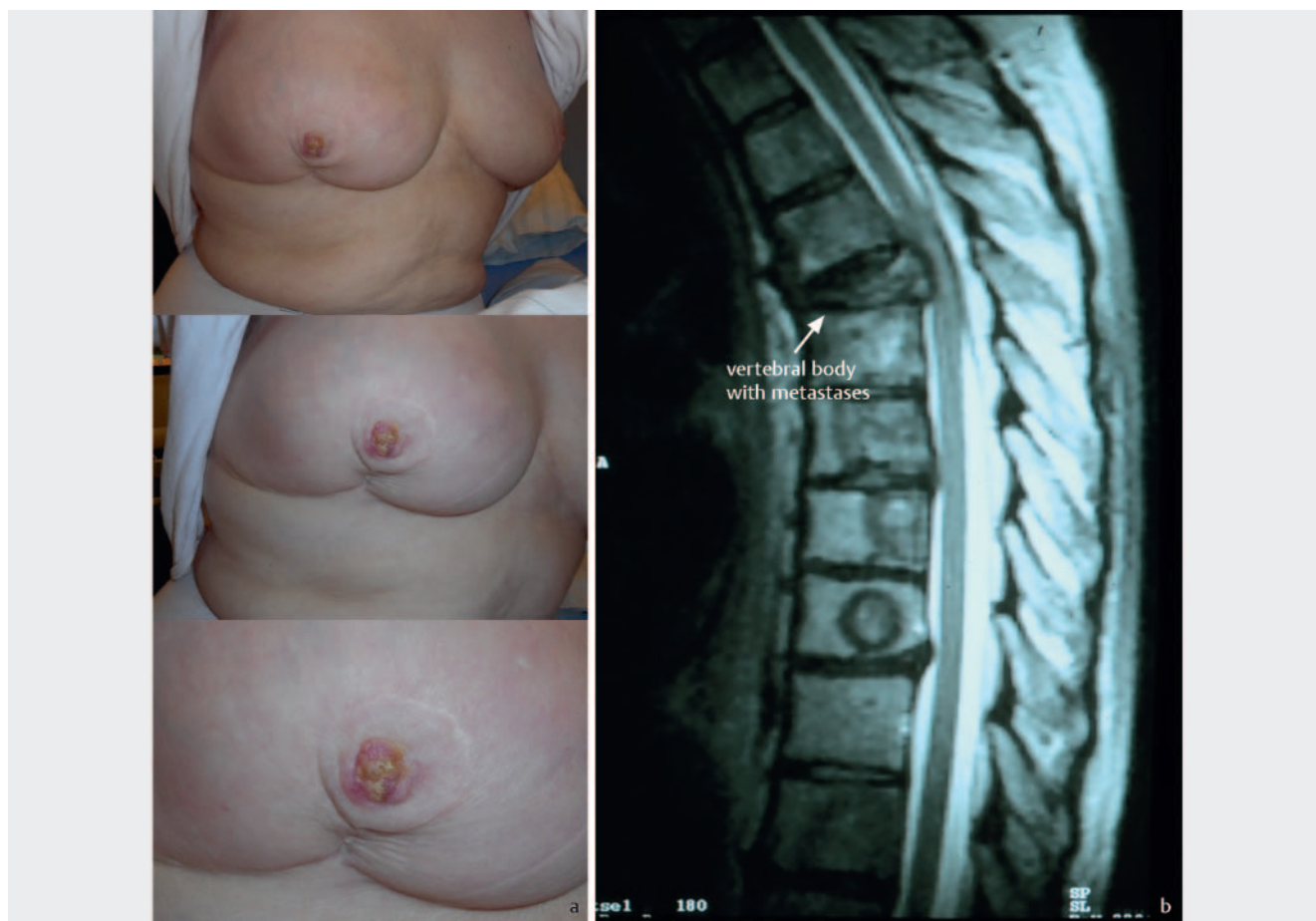- ipsilateral breast (ipsilateral breast cancer recurrence, IBCR),
- the skin or subcutaneous soft tissue of the ipsilateral chest wall (chest wall recurrence; CWR) or
- ipsilateral lymph nodes of the axilla and around the clavicle (regional recurrence).

Nevertheless, not all recurrences, e. g. in the skin of the breast after BCT or breast reconstruction, can be definitively assigned to one of these classifications (► **Fig. 1–4**).

Early detection of locoregional recurrence is considered an essential prerequisite for a curative treatment approach. Therefore,

one essential component in follow-up is the early detection of locoregional recurrences by clinical examination, mammography, breast ultrasonography and, if necessary, breast MRI.

Diagnostic workup (mammography, ultrasonography, possibly MRI), histological confirmation by core biopsy with repeat receptor testing (ER, PgR, HER2) in IBCR is performed the same as in the initial setting [3]. The significance of grading and Ki-67 testing in recurrence is unclear but may indirectly reflect the aggressiveness of the recurrence.



► **Fig. 4** 57-year-old patient 8 years post BET (invasive right ductal breast cancer pT2 (25 mm) pN1 (1/1 sn) cM0; G1, L0 V0, ER-ICA 12/12, PgR-ICA 16/12, HER2 negative, Ki-67 10%; 6 years of tamoxifen/aromatase inhibitors). **a** Paget disease secondary to central IBCR with caudal skin infiltration. **b** Staging: osseous metastases.

In locoregional recurrence, preoperative staging to rule out distant metastases should always be performed. Depending on the localisation and extent, these are usually more relevant for further management and the course of the disease than the local recurrence itself. For example, in a population of 11 046 patients with breast-conserving surgery within 5 years Neuman et al. found 454 IBCRs [4]. In 27% of these patients, asymptomatic distant metastases were also detected. Already 35% of these patients were node positive in the primary situation (► **Fig. 4**). Local management of locoregional recurrence should be guided by the prognosis of the distant metastases.

Incidence and prognosis

Valid data on the incidence of locoregional recurrences is rather limited. Most of the data (► **Table 1**) refers to publications that refer to regimens from more than 20 years ago and is therefore no longer up to date. For example, since these publications appeared, nationwide mammography screening has resulted in the detection of smaller tumours with less common nodal involvement, and neoadjuvant systemic therapy is an established standard of treatment. In addition, surgery, especially the resection

► **Table 1** Incidence and prognosis of locoregional recurrences [2, 5–7].

location	percentage (%)	5-year survival (%)
ipsilateral breast cancer recurrence (IBCR) ▪ after BCT & radiotherapy	10 (2–20)	65 (45–9)
chest wall (CWR) ▪ after mastectomy	4 (2–20)	50 (24–78)
supraclavicular region/axilla ▪ after ALND	34 1 (0.1–8)	49 (3-year survival) 55 (31–77)
▪ after SLNE	1	93
multiple locations	16 (8–9)	21 (18–23)

margin, the systemic therapy and also the radiotherapy concepts (partial breast irradiation, hypofractionation) have changed.

In a meta-analysis of 20 qualitatively “proper” trials from around 7000 trials/reports, the incidence of IBCR and contralateral second cancers (CBC) was reported to be 25% overall [8]. The duration of the follow-up was decisive, as IBCR and especially CBC can still devel-

op even after many years. After staged adjuvant treatment of early breast cancer (pT1–2 N0 M0), the annual incidence of IBCR was 0.6% (range 0.4–1.1) and of CBC 0.5% (range 0.2–0.7). However, even in this meta-analysis, the tumour biology and adjuvant therapy actually performed were not known in all patients. Other trials have identified simultaneous CBC in 5% of patients with IBCR [9].

Risk factors in locoregional recurrence

The development of locoregional recurrence largely depends on the tumour biology – regardless of the location. For example, triple-negative cancers have a 6–8-fold higher risk of local recurrence compared to luminal A-like breast cancers [10, 11]. The tumour biology of the recurrence itself determines the further prognosis after the locoregional recurrence [12, 13]. In this respect, tumour biology should also be included in the discussion of possible re-BCT.

Risk factors for locoregional recurrence include [10, 11, 14–16]:

- Tumour biology
- Tumour size
- Node status
- Young age
- R1/2 resection
- In-site components, and
- inadequate adjuvant therapy.

In a EBCTCG meta-analysis comparing adjuvant versus neoadjuvant systemic therapy with 10 trials from 1983–2002, a significant rise in local recurrence incidence (RR 1.37, 95%CI 1.17–1.61; $p=0.0001$) was found for neoadjuvant versus adjuvant therapy, but this did not affect distant metastasis-free survival and overall survival [17]. A recent GBG meta-analysis with more than 10 000 neoadjuvant patients revealed a significantly lower risk of local recurrence (RR 0.50, 95%CI 0.39–0.62; $p=0.001$) for patients with pathological complete remission (pCR) compared to patients without pCR, which was independent of the type of surgery [18].

Risk factors following locoregional recurrence

For further disease-free survival and also overall survival after locoregional recurrence, in addition to the risk factors already mentioned for developing recurrence, the time from initial surgery, and the location were crucial [19]. Other important factors are adequate radiotherapy and systemic therapy after re-BCT of an IBCR.

Differential diagnosis of IBCR vs. second primary cancer

The differentiation of IBCR versus true second primary cancer is of considerable clinical significance but can be difficult in some cases (► Table 2; ► Fig. 5, 6).

“Genuine” second primary cancer again can undergo breast-conserving surgery and adjuvant therapy according to the tumour biology, just as in primary cancer. The prior treatment modalities

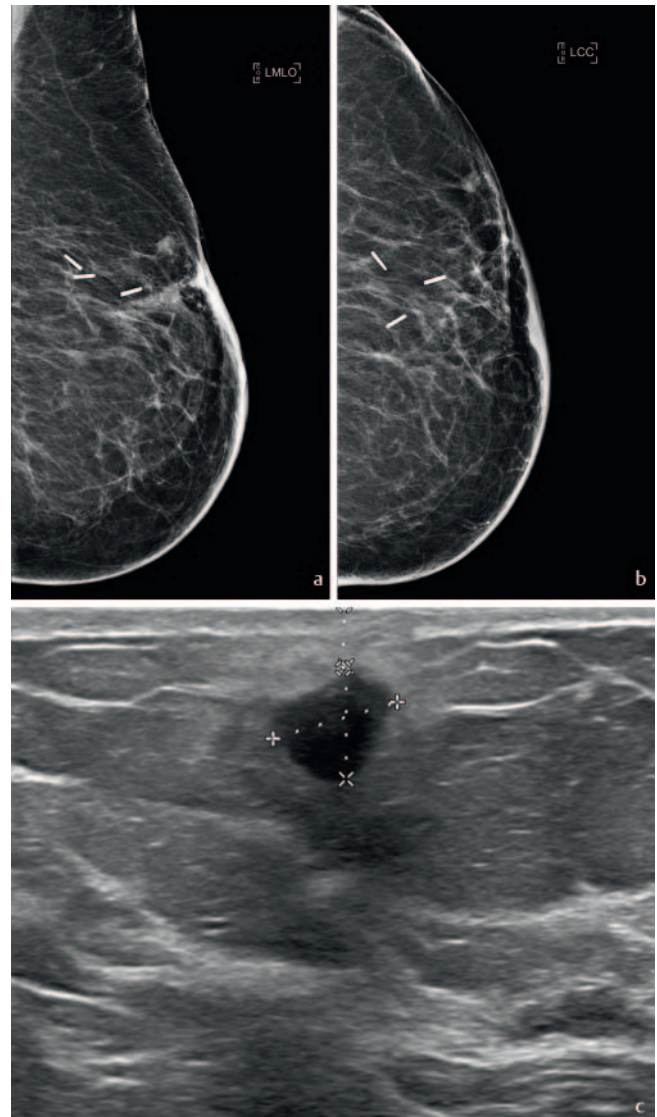
► **Table 2** Criteria for differentiating IBCR and second primary cancer after BCT.

ipsilateral breast cancer recurrence:

- 80%–90% of all IBCR
- close to primary location
- similar tumour biology
- inadequate adjuvant therapy
- early occurrence
- treatment as in recurrence

ipsilateral second primary cancer:

- 10%–20% of all “recurrences”
- distant from primary location
- different tumour biology
- adequate adjuvant therapy
- long time interval
- treatment as in primary disease



► **Fig. 5 a–c** 79-year-old patient with prior left BCT (invasive solid-left ductal breast cancer craniolateral pT2 (23 mm) pN0 (sn0/2; n 0/6) cM0 V0 L0 R0 G2, ER IRS 12, PR IRS 12 HER2 negative Ki67 18%. As part of the follow-up 18 months later: Local left recurrence rcT1b (8 mm) with same tumour biology as primary cancer.

(systemic treatment, radiotherapy) must be considered. The extent to which neoadjuvant therapy is beneficial, e. g., in the case

of new triple-negative and/or HER2-positive cancer, is unclear. However, in some cases this is an alternative to improve the surgical options, e. g., if the size of the tumour and the volume of the breast differ considerably.

Surgery in IBCR

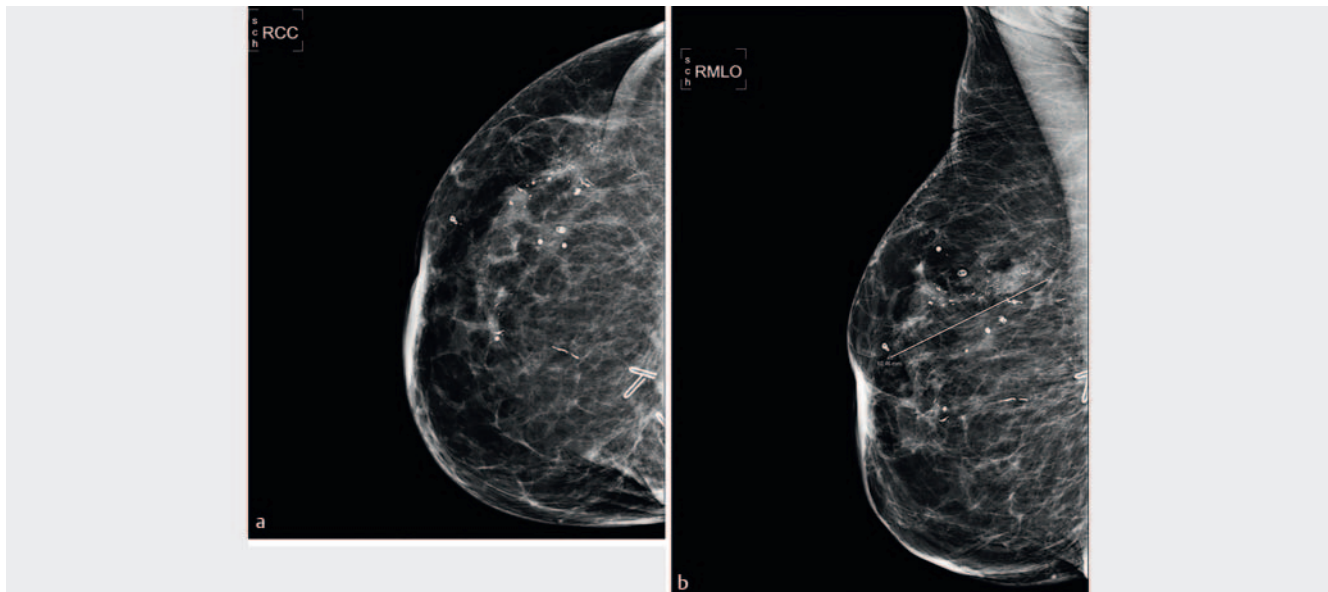
Increasingly, women with prior breast-conserving therapy for breast cancer and IBCR want to have another breast-conserving operation (re-BCT). However, due to the lack of prospective randomised trials, the data on oncological safety is inadequate [20].

For ethical reasons, it will also not be possible to randomise patients with IBCR, different recurrence and breast sizes, time intervals, tumour biology, surgical options and particularly the personal wishes of the patients, into prospective trials. Most knowledge is therefore based on experience, observational and retrospective analysis, with considerable bias. Fittingly, a statement from the

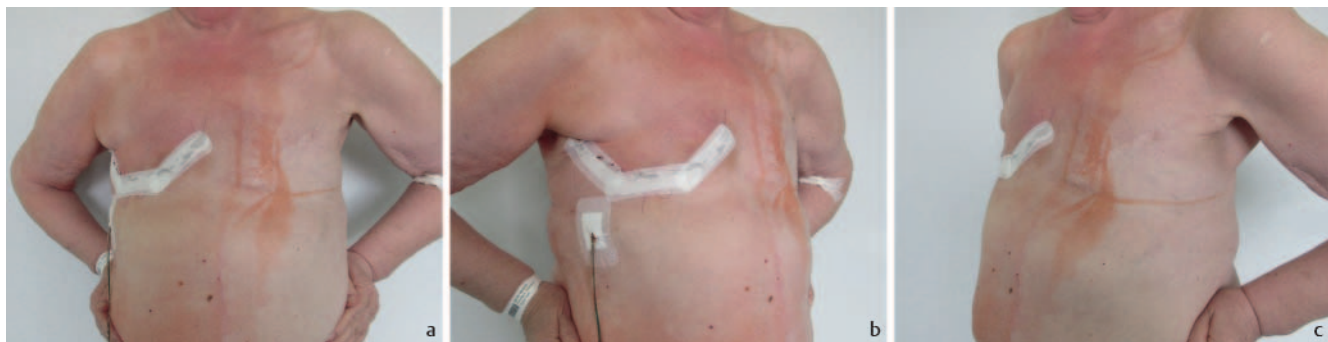American College of Radiology reads: "... where evidence is lacking or inconclusive, expert opinion should be provided as a recommendation ..." [21].

The standard treatment for IBCR today is (still) salvage mastectomy (► Fig. 3, 7) [10]. In the current guidelines and therapy recommendations (AGO, S3 guideline, NCCN), breast-conserving repeat surgery with consideration of repeat radiotherapy reserve is recommended as an option according to the "expert consensus" [22–24].

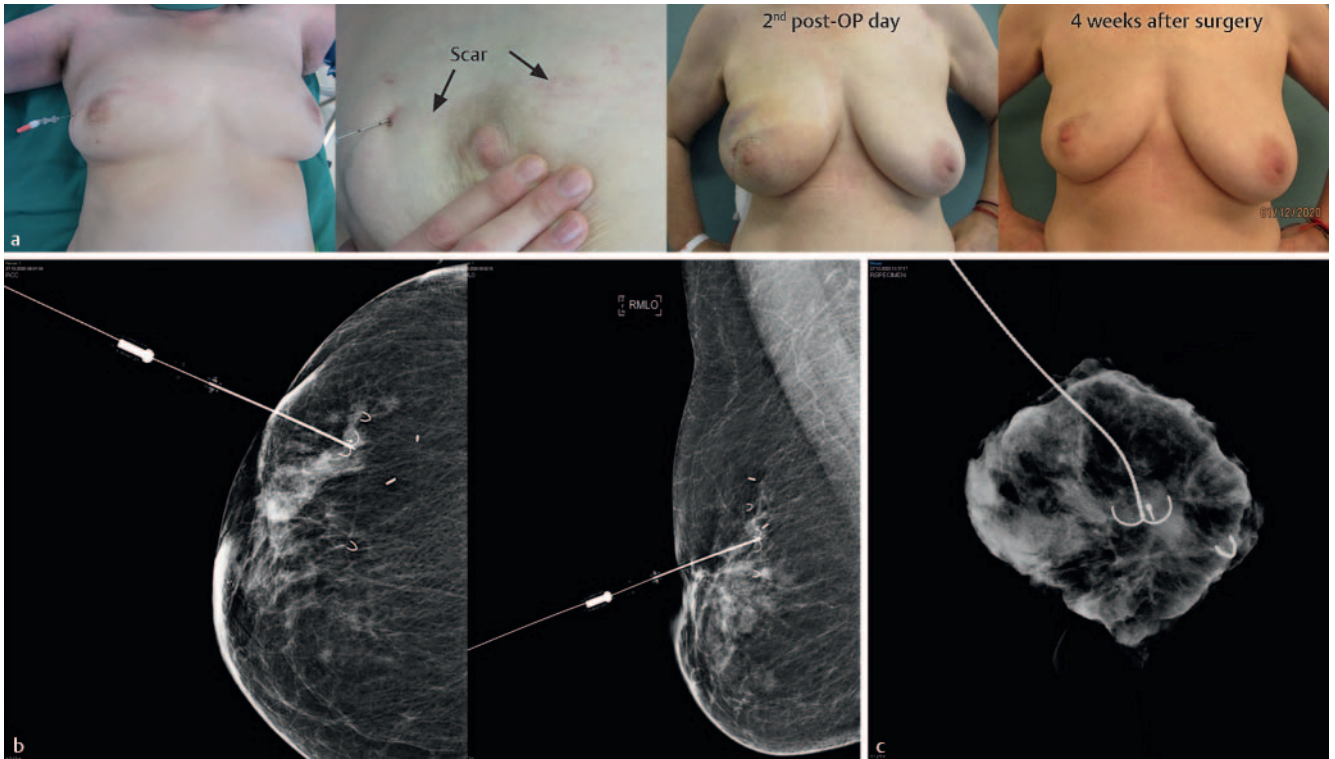
If the patient requests re-BCT, she should be informed that because of the R1/2 resection the risk of a second operation increases compared to salvage mastectomy (► Fig. 7). Detailed counselling regarding renewed IBCR after re-BCT is therefore mandatory. In principle, however, a resection is also possible within the framework of re-BCT. From the point of view of a possible resection, it should be noted that these are often "older" women, or women with comorbidities, who request rapid and permanent surgical treatment of



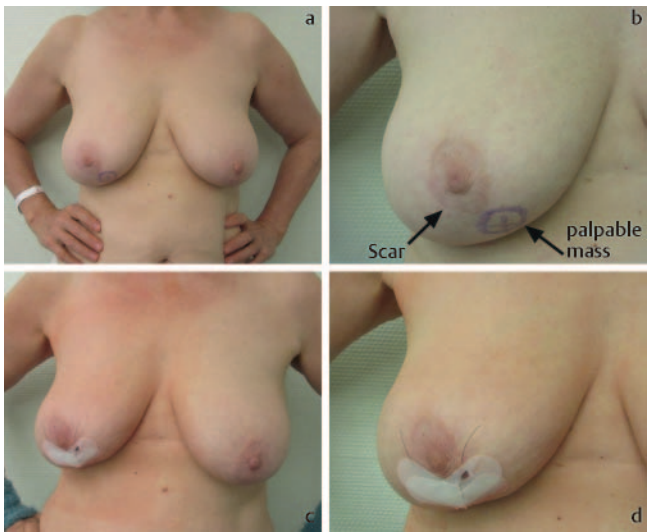
► Fig. 6 a, b 71-year-old female with prior right BCT 7 years earlier for invasive ductal Ma-Ca pT2 (29 mm) pN0 (sn0/3) cM0 V0 L0 R0 G1, ER-IRS 12/12, PgR-IRS 12/12, HER2 negative Ki-67 18%. Mammogram of right breast showing extensive new microcalcifications distant from the primary tumour. Core biopsy of high-grade DCIS with invasive ductal components G3, ER-IRS 4/12, PgR-IRS 0, HER2 negative Ki-67 34% (second primary cancer).



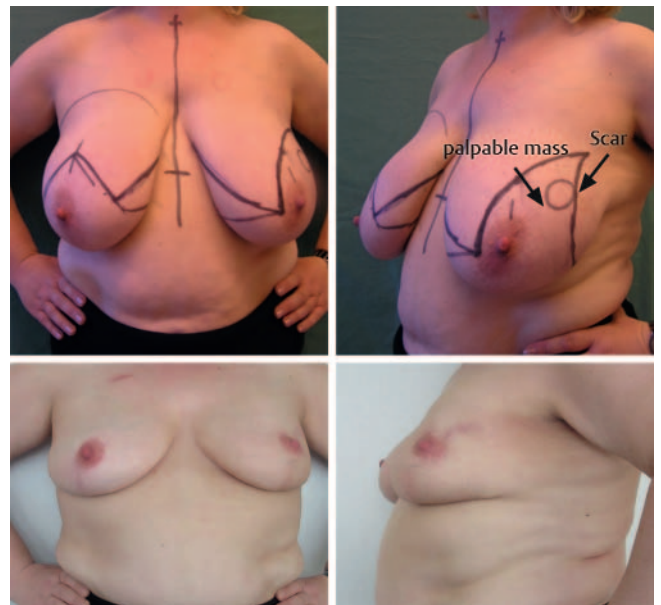
► Fig. 7 a–c 70-year-old female with invasive IBCR after DCIS on the right 13 years after mastectomy for breast cancer on the left. Salvage mastectomy was performed another 13 year later after re-BCT with SLNB on the right and R1 resection.



► **Fig. 8** 48-year-old female with invasive IBCR after breast cancer on the right and BCT (caution: incision!) in another hospital. Refusal of radiotherapy and systemic therapy. After 22 months invasive IBCR at the same location and re-BCT. **a** patient images, **b** mammography findings, **c** specimen radiography re-BCT.



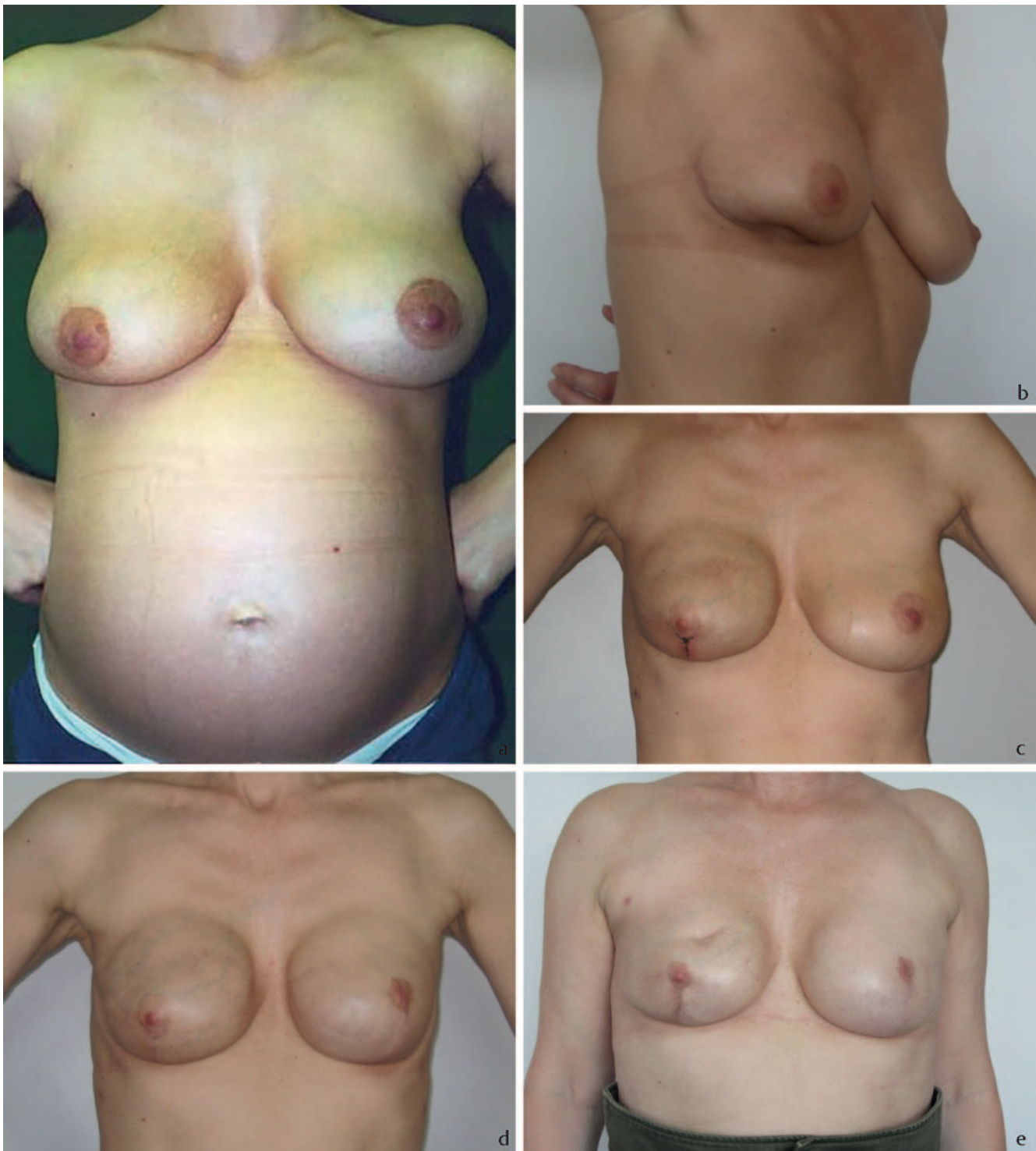► **Fig. 9** 49-year-old female with invasive IBCR after breast cancer on the right (BCT 50 months ago) and re-BCT.



► **Fig. 10 a-d** 48-year-old female with invasive IBCR (close to the skin) after BCT LUOQ 4 years ago. Request for breast conservation. In bilateral macromastia, tumour-site adapted breast reduction surgery on the left and adaptation on the right (cost reimbursement confirmed by health insurance provider).

their IBCR. These women often also refuse repeat radiotherapy and systemic therapy, thereby worsening their overall survival.

If a patient wishes to undergo re-BCT, the local conditions (e.g., radiotherapy, relation of tumour size to breast size, concomitant diseases) and the prognosis must be considered. The surgical technique of re-BCT is identical to primary BCT, where ideally the old incision should be used (► **Fig. 8, 9**). In the

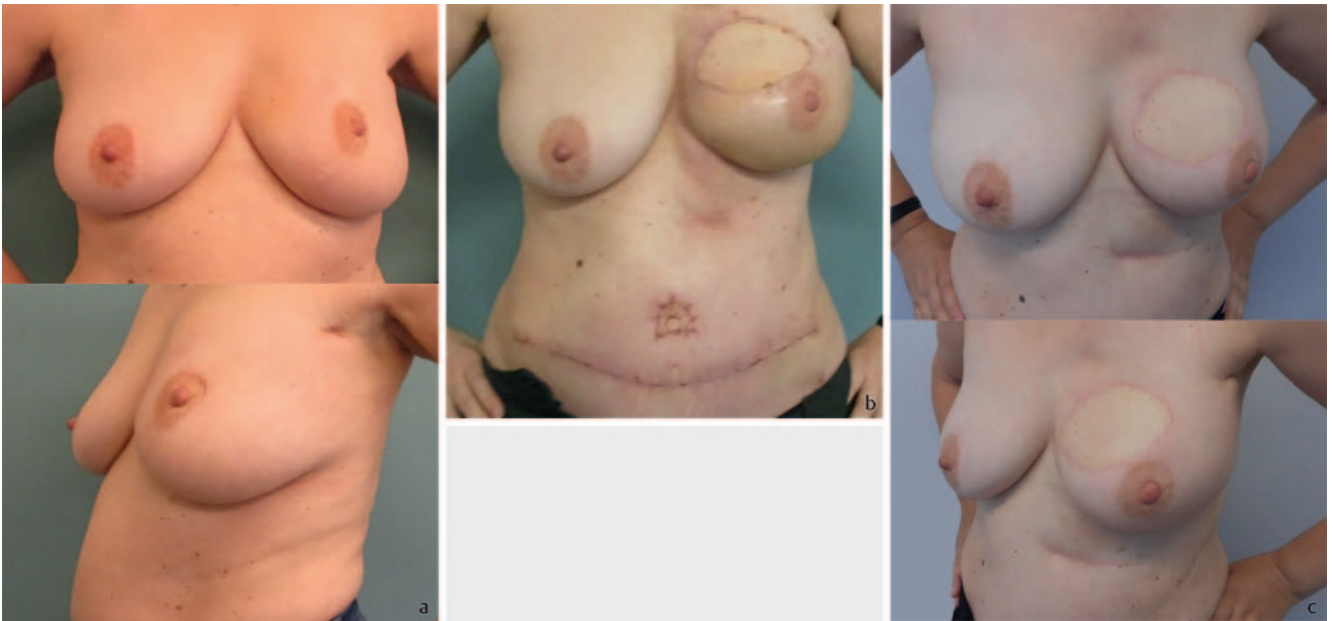


► **Fig. 11** a 26-year-old female with right breast cancer in pregnancy. b after 15,5 years: right IBCR and re-BCT. c another 4,5 years later: 2. IBCR and NSM with prosthetic reconstruction. d Contralateral breast cancer with NSM and prosthetic reconstruction on request. e another 5,5 years later: right axillary recurrence.

case of “large” breast volume, tumour-site adapted breast reduction may be contemplated (► **Fig. 10**). It should be noted, however, that the patients had already prior radiotherapy and therefore wound healing and cosmetic results are worse than after

primary surgery. Before surgery on the contralateral breast, the health insurance provider should confirm cost reimbursement.

In some cases – again considering prior treatment, tumour biology and the patient’s wishes – a nipple/skin sparing mastectomy with prosthetic reconstruction may also be performed. Espe-



► **Fig. 12** 52-year-old female **a** 4 years after NAST (pCR) and BCT LUOQ for TNBC, now with ipsilateral second primary cancer pT2 (23 mm, 60 mm is) cNOMO G1, L0 V0, ER-ICA 8/12, PgR-ICA 8/12, HER2 negative, Ki-67 20% UIQ **b, c** after SSM and TRAM reconstruction.

cially in slim patients with prior radiations, the cosmetic results are somewhat disappointing (► **Fig. 11**). Autologous reconstruction in IBCR is possible in principle, but the risks and benefits, follow-up treatment and the prognosis of the recurrence should be assessed in advance (► **Fig. 12**).

There is practically no data for a second re-BCT, but according to our own experience this can be performed on a case-by-case basis with the patient's consent.

With the surgical treatment of IBCR, the question arises as to how to proceed in the axilla. Axillary intervention (ALND or SLNE) is not indicated in clinically (palpatory and ultrasonographical) unremarkable lymph nodes. Only if no SLNE had been performed so far – e. g., invasive IBCR after prior DCIS – can SLNE be performed in a cN0 cM0 situation. The rate of false negative SLNE in IBCR is reported to be less than 10% even in re-SLNE [25]. The clinical benefit for further treatment planning and the clinical outcome of the patient has not been established [26]. Clinically suspect or positive lymph nodes, on the other hand, should be resected as a debulking procedure.

Breasts with autologous or heterologous reconstruction present a special problem. Most of these cases present with prior “mastectomy”. This is basically the same situation as with patients with prior mastectomy, in other words the resection must have a safe margin. As a rule, this means salvage mastectomy including the autologous tissue or implant (► **Fig. 3**); in some cases, R0 resection with preservation of the reconstructed breast may be performed.

There is no data on the potential of “preoperative” systemic therapy (chemotherapy, hormone/anti-HER2 therapy, etc.) – analogous to neoadjuvant systemic therapy – in operable IBCR. All guidelines agree that R0 resection in IBCR should be followed by adequate systemic therapy [22, 27].

From an oncological point of view, re-BCT in radiotherapy-induced sarcoma of the breast post BCT must be avoided at all costs [28, 29].

Outcome after re-BET in IBCR

All guidelines confirm that the local risk of recurrence increases following re-BCT, but overall survival does not deteriorate [30]. The cosmetic outcome (retractions, dents, asymmetry, etc.) is usually less favourable following re-BCT and radiotherapy than after primary surgery (► **Fig. 11b**). In contrast, complications post re-BCT tend to be lower (19.2%) compared to mastectomy with or without reconstruction (30.8% and 34.3%, respectively) [30].

A US observational study analysed 166 ipsilateral IBCRs following breast-conserving therapy in 2038 patients [31]. Salvage mastectomy was performed in 116 of the 166 patients, while 50 patients underwent re-BCT. At 64.5% (mastectomy) there was no significant statistical difference in 10-year overall survival compared to 58% (re-BCT). However, the authors also point to biases such as time interval to first surgery, tumour size, nodal status, tumour biology, patient wishes, and other prognostic parameters that were considered in the decision for re-BCT. The authors therefore announced a prospective randomised trial comparing salvage mastectomy with re-BCT and breast radiotherapy as early as 2005. Such a trial is still not underway today and the authors regard it as ethically untenable!

The question of oncological safety of re-BCT in IBCR is addressed by a strikingly large number of trials from the Asian region [32]. In an analysis from China of 2075 patients with BCT, 475 (22.9%) underwent re-BCT, while 1600 (77.1%) underwent mastectomy [33]. After a median follow-up of more than 10 years,

breast cancer-specific survival (BCSS) and overall survival (OAS) did not differ significantly between the two groups before and also after statistical matching of both collectives. In multivariate analysis, AJCC (American Joint Committee on Cancer) stage, size of recurrence, tumour biology, and re-radiotherapy were independent predictors of BCSS and OAS. In a similar trial from Korea with 335 IBCR patients, 90 matched patients were treated by re-BET or mastectomy [34]. After a median follow-up of more than 10 years, no significant differences were found for the 10-year OAS (hazard ratio [HR] 1.08, 95 % confidence interval [CI] 0.49–2.39) and BCSS (HR 0.83, 95 % CI 0.35–1.95).

Radiotherapy of the tumour bed following re-BCT seems to be crucial. If re-BCT is not followed by partial breast radiotherapy, the overall survival is significantly worse compared to re-BCT plus radiotherapy, but also compared to mastectomy alone [35, 36].

CONCLUSION

In summary, the following can be stated for ipsilateral breast cancer recurrence:

- Differential diagnosis IBCR or second primary cancer
- Salvage mastectomy is standard
- Re-BCT is possible in selected cases (caution: breast and recurrence size, time interval to primary disease, tumour biology, surgical options, and patient preferences)
- Preoperative restaging to exclude distant metastases
- Check possibility of re-radiotherapy, systemic therapy depending on tumour biology
- Higher risk of local recurrence following re-BCT, but no decline in overall survival

Umberto Veronesi, a pioneer of de-escalation of therapy in breast cancer, said back in 2005: *“In-breast-recurrences or second ipsilateral carcinoma of restricted size can be treated with a second conservative surgery.”* [37]

Conflict of Interest

The authors declare that they have no conflict of interest.

References

- [1] Moossdorff M, van Roozendaal LM, Strobbe LJ et al. Maastricht Delphi consensus on event definitions for classification of recurrence in breast cancer research. *J Natl Cancer Inst* 2014; 106 (12): dju288. doi:10.1093/jnci/dju288. Print 2014 Dec. PMID: 25381395
- [2] Wapnir IL, Anderson SJ, Mamounas EP et al. Prognosis after ipsilateral breast tumor recurrence and locoregional recurrences in five National Surgical Adjuvant Breast and Bowel Project node-positive adjuvant breast cancer trials. *J Clin Oncol* 2006; 24: 2028–2037
- [3] Cardoso F, Costa A, Senkus E et al. 3rd ESO-ESMO International Consensus Guidelines for Advanced Breast Cancer (ABC 3). *Ann Oncol* 2017; 28: 3111
- [4] Neuman HB, Schumacher JR, Francescatti AB et al. Risk of Synchronous Distant Recurrence at Time of Locoregional Recurrence in Patients With Stage II and III Breast Cancer (AFT-01). *J Clin Oncol* 2018; 36: 975–980
- [5] Haffty BG, Fischer D, Beinfeld M et al. Prognosis following local recurrence in the conservatively treated breast cancer patient. *Int J Radiat Oncol Biol Phys* 1991; 21: 293–298
- [6] Reddy JP, Levy L, Oh JL et al. Long-term outcomes in patients with isolated supraclavicular nodal recurrence after mastectomy and doxorubicin-based chemotherapy for breast cancer. *Int J Radiat Oncol Biol Phys* 2011; 80: 1453–1457
- [7] Andersson Y, de Boniface J, Jönsson PE et al. Axillary recurrence rate 5 years after negative sentinel node biopsy for breast cancer. *Br J Surg* 2012; 99: 226–231
- [8] Spronk I, Schellevis FG, Burgers JS et al. Incidence of isolated local breast cancer recurrence and contralateral breast cancer: A systematic review. *Breast* 2018; 39: 70–79
- [9] Walstra C, Schipper RJ, Winter-Warnars GA et al. Local staging of ipsilateral breast tumor recurrence: mammography, ultrasound, or MRI? *Breast Cancer Res Treat* 2020; 184: 385–395
- [10] Belkacemi Y, Hanna NE, Besnard C et al. Local and Regional Breast Cancer Recurrences: Salvage Therapy Options in the New Era of Molecular Subtypes. *Front Oncol* 2018; 8: 112
- [11] McGuire A, Lowery AJ, Kell MR et al. Locoregional Recurrence Following Breast Cancer Surgery in the Trastuzumab Era: A Systematic Review by Subtype. *Ann Surg Oncol* 2017; 24: 3124–3132
- [12] Kast K, Link T, Friedrich K et al. Impact of breast cancer subtypes and patterns of metastasis on outcome. *Breast Cancer Res Treat* 2015; 150: 621–629
- [13] Metzger-Filho O, de Azambuja E, Bradbury I et al. Analysis of regional timelines to set up a global phase III clinical trial in breast cancer: the adjuvant lapatinib and/or trastuzumab treatment optimization experience. *Oncologist* 2013; 18: 134–140
- [14] Fragomeni SM, Sciallis A, Jeruss JS. Molecular Subtypes and Local-Regional Control of Breast Cancer. *Surg Oncol Clin N Am* 2018; 27: 95–120
- [15] Voduc KD, Cheang MC, Tyldesley S et al. Breast cancer subtypes and the risk of local and regional relapse. *J Clin Oncol* 2010; 28: 1684–1691
- [16] Karlsson P, Cole BF, Chua BH et al. Patterns and risk factors for locoregional failures after mastectomy for breast cancer: an International Breast Cancer Study Group report. *Ann Oncol* 2012; 23: 2852–2858
- [17] Long-term outcomes for neoadjuvant versus adjuvant chemotherapy in early breast cancer: meta-analysis of individual patient data from ten randomised trials. *Lancet Oncol* 2018; 19: 27–39
- [18] Werutsky G, Untch M, Hanusch C et al. Locoregional recurrence risk after neoadjuvant chemotherapy: A pooled analysis of nine prospective neoadjuvant breast cancer trials. *Eur J Cancer* 2020; 130: 92–101
- [19] Lee JH, Lee SK, Park SM et al. Independent Prognostic Factors for Overall Survival after Salvage Operation for Ipsilateral Breast Tumor Recurrence Following Breast-Conserving Surgery. *J Breast Cancer* 2015; 18: 386–393
- [20] Winters ZE, Horsnell J, Elvers KT et al. Systematic review of the impact of breast-conserving surgery on cancer outcomes of multiple ipsilateral breast cancers. *BJS Open* 2018; 2: 162–174
- [21] Halyard MY, Wasif N, Harris EE et al. ACR Appropriateness Criteria(R) local-regional recurrence (LR) and salvage surgery: breast cancer. *Am J Clin Oncol* 2012; 35: 178–182
- [22] AGO. Diagnostic and treatment of early and metastatic breast cancer. 2020 <http://www.ago-online.org>
- [23] DGS. Deutsche Gesellschaft für Senologie: Interdisziplinäre S3-Leitlinie für die Diagnostik, Therapie und Nachsorge des Mammakarzinoms. 2017
- [24] NCCN. National Comprehensive Cancer Network: Practice Guidelines in Oncology: Breast Cancer. 2020 <http://www.nccn.org>
- [25] Yoon CI, Ahn SG, Kim D et al. Repeat Sentinel Lymph Node Biopsy for Ipsilateral Breast Tumor Recurrence After Breast Conserving Surgery With Sentinel Lymph Node Biopsy: Pooled Analysis Using Data From a Systematic Review and Two Institutions. *Front Oncol* 2020; 10: 518568

- [26] McGinity AC, Lautner MA, Jatoi I. Management of the clinically node-negative axilla in primary and locally recurrent breast cancer. *Surg Oncol Clin N Am* 2014; 23: 463–471
- [27] Wapnir IL, Price KN, Anderson SJ et al. Efficacy of Chemotherapy for ER-Negative and ER-Positive Isolated Locoregional Recurrence of Breast Cancer: Final Analysis of the CALOR Trial. *J Clin Oncol* 2018; 36: 1073–1079
- [28] Duncan MA, Lautner MA. Sarcomas of the Breast. *Surg Clin North Am* 2018; 98: 869–876
- [29] Dogan A, Kern P, Schultheis B et al. Radiogenic angiosarcoma of the breast: case report and systematic review of the literature. *BMC Cancer* 2018; 18: 463
- [30] Elfgen C, Güth U, Gruber G et al. Breast-conserving surgery with intraoperative radiotherapy in recurrent breast cancer: the patient's perspective. *Breast Cancer* 2020; 27: 1107–1113
- [31] Alpert TE, Kuerer HM, Arthur DW et al. Ipsilateral breast tumor recurrence after breast conservation therapy: outcomes of salvage mastectomy vs. salvage breast-conserving surgery and prognostic factors for salvage breast preservation. *Int J Radiat Oncol Biol Phys* 2005; 63: 845–851
- [32] Yoshida A, Takahashi O, Okumura Y et al. Prognosis after mastectomy versus repeat lumpectomy in patients with ipsilateral breast cancer recurrence: A propensity score analysis. *Eur J Surg Oncol* 2016; 42: 474–480
- [33] Wu Y, Shi X, Li J et al. Prognosis of Surgical Treatment After Ipsilateral Breast Tumor Recurrence. *J Surg Res* 2020; 258: 23–37
- [34] Baek SY, Kim J, Chung IY et al. Long-term survival outcomes of repeat lumpectomy for ipsilateral breast tumor recurrence: a propensity score-matched analysis. *Breast Cancer Res Treat* 2020; 185: 155–164
- [35] Su Y, Guo R, Xue J et al. Increased Mortality with Repeat Lumpectomy Alone After Ipsilateral Breast Tumor Recurrence. *Oncologist* 2019; 24: e818–e827
- [36] Leonardi MC, Tomio L, Radice D et al. Local Failure After Accelerated Partial Breast Irradiation with Intraoperative Radiotherapy with Electrons: An Insight into Management and Outcome from an Italian Multicentric Study. *Ann Surg Oncol* 2020; 27: 752–762
- [37] Veronesi U, Boyle P, Goldhirsch A et al. Breast cancer. *Lancet* 2005; 365: 1727–1741