

## Screening, Management and Delivery in Twin Pregnancy

### Überwachung und Betreuung von Zwillingsschwangerschaften (AWMF 015-087 S2e-Leitlinie)

#### Authors

Constantin von Kaisenberg<sup>1\*</sup>, Philipp Klaritsch<sup>2\*</sup>, Nicole Ochsenbein-Kölble<sup>3</sup>, Markus Eugen Hodel<sup>4</sup>, Monika Nothacker<sup>5</sup>, Kurt Hecher<sup>6</sup>

#### Affiliations

- 1 Obstetrics and Gynecology, Hannover Medical School, Hannover, Germany
- 2 Department of Obstetrics and Gynecology, Medical University Graz, Austria
- 3 Department of Obstetrics, University Hospital Zürich, Zürich, Switzerland
- 4 Obstetrics, Luzerner Kantonsspital, Lucerne, Switzerland
- 5 AWMF-Institut für Medizinisches Wissensmanagement (AWMF-IMWi), University of Marburg, Germany
- 6 Department of Obstetrics and Fetal Medicine, University Hospital Hamburg-Eppendorf, Hamburg, Germany

#### Key words

twins, monochorionic, dichorionic, monoamniotic, TTTS

received 29.05.2020

accepted 09.08.2020

published online 05.10.2020

#### Bibliography

Ultraschall in Med 2021; 41: 367–377

DOI 10.1055/a-1248-8896

ISSN 0172-4614

© 2020, Thieme. All rights reserved.

Georg Thieme Verlag KG, Rüdigerstraße 14, 70469 Stuttgart, Germany

#### Correspondence

Prof. Constantin von Kaisenberg

Obstetrics and Gynecology, Hannover Medical School,

Carl-Neuberg-Str. 1, 30625 Hannover, Germany

Tel.: ++49/1 76/15 32 34 54

Fax: ++49/51 15 32 61 45

vonkaisenberg.constantin@mh-hannover.de

#### ABSTRACT

The following AWMF guideline (DGGG/AGG & DEGUM responsible) deals with the diagnosis, screening and management of twins as well as the timing and mode of birth.

Twin pregnancies can be classified as dichorionic diamniotic (DC DA), monochorionic diamniotic (MC DA) and monochorionic monoamniotic (MC MA) which are always monochorionic.

Twin pregnancies can be concordant (both twins are affected) or discordant (only one twin is affected) for chromosomal defects, malformations, growth restriction and hemodynamic disorders. Chorionicity is the prognostically most significant parameter. Monochorionic twins have significantly higher risks of intrauterine morbidity and mortality compared to dichorionic twins. In particular, general aspects of twin pregnancies such as dating, determination of chorionicity and amnionity, the labeling of twin fetuses and the perinatal switch phenomenon are discussed.

Routine monitoring of MC and DC twin pregnancies with ultrasound at 11–13<sup>+6</sup> weeks of gestation for chromosomal defects, invasive prenatal diagnosis, first-trimester NT or CRL discrepancies, early diagnosis of fetal anatomical defects, and management of twins with abnormalities, including selective fetocide, is described.

Second trimester screening and management for preterm birth, intrauterine selective growth restriction (sFGR), classification of monochorionic twins with sFGR, and management of the surviving twin after the death of the co-twin are described. Complications exclusively affecting MC twins include Twin to Twin Transfusion Syndrome (TTTS) with the important topics screening, prognosis, complications of laser therapy, timing of delivery, risks for brain abnormalities and delayed neurological development, Twin Anemia-Polycythemia Sequence (TAPS) and Twin Reversed Arterial Perfusion (TRAP) Sequence. This also includes MC MA twins as well as conjoined twins. Finally, the birth mode and time for DC and MC twin pregnancies are described.

The information is summarized in 62 recommendations for action, 4 tables and 8 illustrations with comprehensive background texts.

The guideline is an international guideline adaptation (ISUOG, NICE) as well as a systematic literature search and is up-to-date.

#### ZUSAMMENFASSUNG

In der folgenden AWMF-Leitlinie (DGGG/AGG & DEGUM federführend) werden die Diagnostik, das Screening und Management von Zwillingen sowie Zeitpunkt und Modus der Geburt behandelt.

Zwillingsschwangerschaften können in dichorial-diamniotale (DC DA), monochorial-diamniotale (MC DA) und monoamniotale (MC MA) – welche immer monochorial sind – unterteilt werden.

\* Constantin von Kaisenberg and Philipp Klaritsch share first authorship.

Zwillingsschwangerschaften können für Chromosomenstörungen, Fehlbildungen, Wachstumsretardierung und hämodynamische Störungen konkordant (beide sind betroffen) oder diskordant sein (hier ist nur einer von beiden betroffen). Der prognostisch bedeutsamste Parameter ist die Chorionizität. Monochoriale Zwillinge weisen deutlich höhere Risiken für eine intrauterine Morbidität und Mortalität auf als dichoriale Zwillinge.

Im Einzelnen wird Allgemeines zu Zwillingsschwangerschaften wie Datierung, Bestimmung der Chorionizität und Amnionizität, die Bezeichnung von Zwillingseten und das perinatale Switch-Phänomen diskutiert.

Das Routine-Monitoring von MC- und DC-Zwillingsschwangerschaften mit Ultraschall zwischen 11 und 13<sup>+6</sup> Schwangerschaftswochen auf Chromosomenstörungen, die invasive Pränataldiagnostik, Diskordanzen der NT oder SSL im ersten Trimenon, die frühe strukturierte Fehlbildungsdiagnostik sowie das Management bei für fetale Fehlbildungen diskordanten Zwillingen einschließlich des selektiven Fetozids werden beschrieben.

Das Zweittrimester-Screening und Management auf Frühgeburt und auf intrauterine selektive Wachstumsrestriktion (sFGR), die Klassifikation monochorialischer Zwillinge mit sFGR und das Management des überlebenden Zwilling nach Fruchttod des Co-Zwilling werden behandelt.

Ausschließlich MC-Zwillinge betreffende Komplikationen sind das Zwillingstransfusionssyndrom (TTTS) mit den wichtigen Themen Screening, Prognose, Komplikationen der Lasertherapie, Entbindungszeitpunkt, Risiken für Gehirnanomalien und neurologische Entwicklungsverzögerung, die Twin Anemia-Polycythemia Sequence (TAPS) und die Twin Reversed Arterial Perfusion (TRAP) Sequence. Hierzu gehören auch die MC-MA-Zwillinge einschließlich der siamesischen Zwillinge.

Zuletzt werden der Geburtsmodus und -zeitpunkt von DC- und MC-Zwillingsschwangerschaften beschrieben.

Die Informationen sind in 62 Handlungsempfehlungen, 4 Tabellen und 8 Abbildungen mit umfassenden Hintergrundtexten zusammengefasst.

Die Leitlinie ist eine internationale LL-Adaptation (ISUOG, NICE) sowie eine systematische Literaturrecherche und ist up to date.

## Introduction

### Issues and Objectives, Identification and Evaluation of the Evidence

#### Recommendations

This is a brief version of the AWMF S2e guideline “Monitoring and Management of Twin Pregnancies” (<https://www.awmf.org/leitlinien/detail/II/015-087.html>).

The AWMF guideline is an adaptation of the ISUOG and NICE guidelines [1–3] as well as systematic literature research. It was written to create a very condensed readable practical version and to make the guideline known.

Twin pregnancies can be classified as **dichorionic diamniotic (DC DA)**, **monochorionic diamniotic (MC DA)** and **monochorionic monoamniotic (MC MA)**.

Twin pregnancies can be concordant (both twins are affected) or discordant (only one twin is affected) for chromosomal defects, malformations, growth restriction and hemodynamic disorders.

Chorionicity is the prognostically most significant parameter. MC twins have significantly higher risks of intrauterine morbidity and mortality than DC twins.

## General Information regarding Twin Pregnancies

### Dating of Twin Pregnancies

- The gestational age of twin pregnancies should be determined at a crown-rump length (CRL) of 45–84 mm (11<sup>+0</sup> to 13<sup>+6</sup> weeks of gestation) [4].

- For spontaneously conceived twins, the larger CRL should be used to estimate the gestational age [5].
- Twin pregnancies conceived after in vitro fertilization should be determined based on the date of egg collection – or the age of the embryo (in days) at implantation [4].

### Determination of Chorionicity and Amnionicity of Twin Pregnancies

Prior to 13<sup>+6</sup> weeks of gestation, chorionicity should be determined by

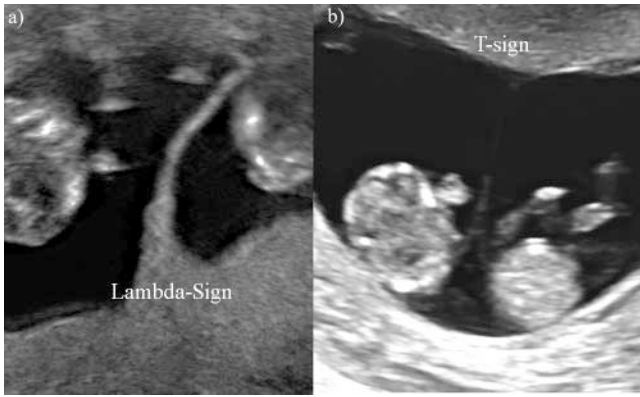
- assessment of the membrane thickness at the site of insertion of the amniotic membrane into the placenta,
- idetermination of the T-sign or lambda sign,
- as well as the number of placenta masses.

An ultrasound image showing chorionicity should be archived in the records for future reference [2, 6].

- The second opinion of a specialized center should be obtained if it is not possible to determine chorionicity in a routine setting by transabdominal or transvaginal ultrasound.
- If the determination of chorionicity is also not possible there, the pregnancy should be treated as an MC pregnancy [2].
- Amnionicity should also be determined and documented when chorionicity is established.
- MC MA pregnancies should be referred to a specialized center with related management experience [1] (► Fig. 1).

### Twin Fetus Labeling

- The labeling of twin fetuses should follow a reliable and uniform strategy and be clearly documented (maternity log, patient documentation).



► **Fig. 1** First-trimester ultrasound images of: **a** dichorionic diamniotic twin pregnancy, in which the twins are separated by a thick layer of fused chorionic membranes, and **b** a monochorionic diamniotic twin pregnancy in which the twins are separated only by two thin amniotic membranes. Source: Arbeitsgemeinschaft der Wissenschaftlichen Medizinischen Fachgesellschaften e.V (AWMF). Leitlinie zur Überwachung und Betreuung von Zwillingsschwangerschaften. Online: <https://www.awmf.org/leitlinien/detail/ll/015-087.html>; Stand: 05.10.2020. [rerif]

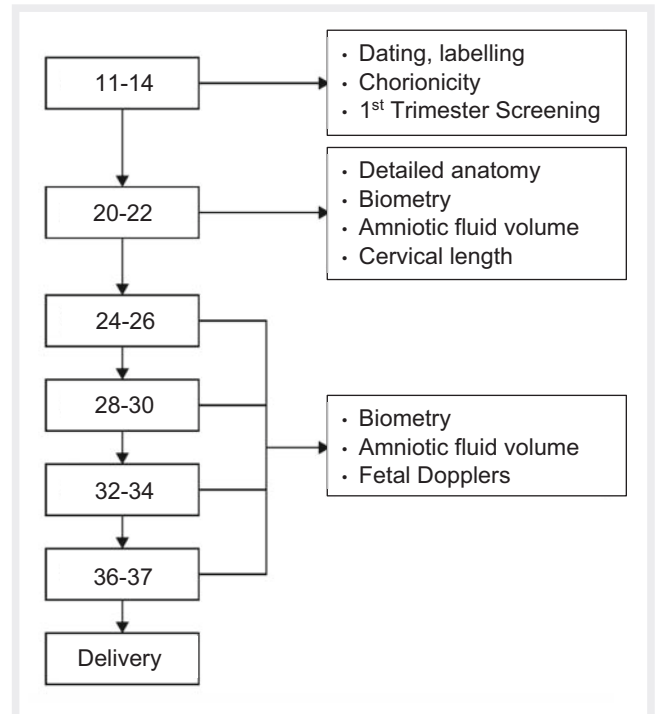
- Several parameters should be used for this (e. g. which is to the front, the side, the position, the location of the placenta and umbilical insertion, and the sex) [3, 7].

### The Perinatal Switch Phenomenon

Not all clearly labeled fetuses are actually delivered in that order (switch phenomenon).

## Routine Monitoring of Twin Pregnancies using Ultrasound

- In any general ultrasound examination of twins, the following parameters should be assessed in both twins with 20 weeks or more of gestational age:
  - biometry, estimated weight and difference of estimated fetal weights (%), amniotic fluid volume (deepest vertical pocket, DVP) and umbilical artery Doppler.
  - An estimated weight difference  $\geq 25\%$  indicates selective fetal growth restriction, sFGR, for which referral to a specialized center is indicated [8].
- Uncomplicated twin pregnancies should receive first-trimester screening, a detailed second-trimester malformation ultrasound (organ screening), and subsequently serial growth measurements and Doppler ultrasound examinations every 4 weeks.
- Complicated DC twins should be examined more often, depending on the circumstances and their severity [3].
- Uncomplicated MC twin pregnancies should receive first-trimester screening and a detailed second-trimester malformation ultrasound (organ screening) and, from 16 weeks of gestation onwards, examined serially every 2 weeks with growth measurements, amniotic fluid volume determination (DVP) and Doppler ultrasound.

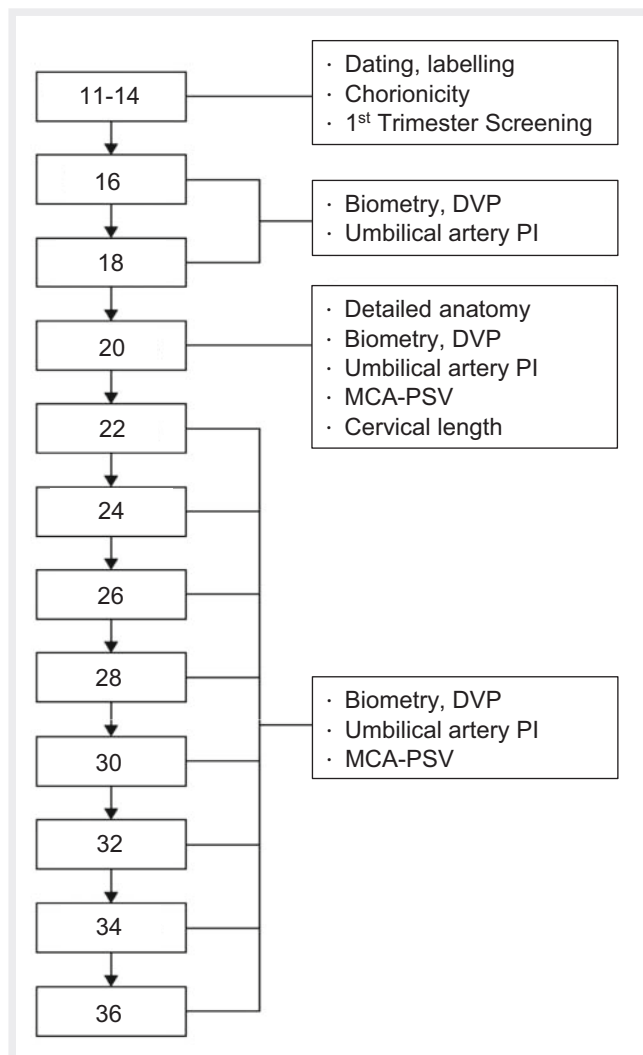


► **Fig. 2** Algorithm of ultrasound monitoring (completed weeks of pregnancy) for uncomplicated dichorial twin pregnancies. Source: Arbeitsgemeinschaft der Wissenschaftlichen Medizinischen Fachgesellschaften e.V (AWMF). Leitlinie zur Überwachung und Betreuung von Zwillingsschwangerschaften. Online: <https://www.awmf.org/leitlinien/detail/ll/015-087.html>; Stand: 05.10.2020. [rerif]

- Depending on the circumstances and their severity complicated MC twins should be examined more frequently [3, 9, 10] (► **Fig. 2, 3**).

## Screening for Chromosomal Abnormalities in Twin Pregnancy

- First-trimester screening for chromosomal abnormalities in twins should include maternal age, nuchal translucency (NT) and serum biochemistry (free beta-hCG and PAPP-A).
- If necessary, it should be combined with sonographic markers for chromosomal defects such as the nasal bone, tricuspid regurgitation and ductus venosus (NB, TR, DV) [2, 11–13].
- In the case of a “vanishing twin”, first-trimester screening for fetal trisomy should take into account maternal age, fetal NT measurement and serum beta-hCG (without PAPP-A) level.
- PAPP-A should only be used if it has been adjusted for the interval between the estimated gestational age at fetal death and blood collection [14].
- First-trimester screening for chromosomal defects in twins may include cell-free fetal (placental) DNA.
- However, the detection rates of the non-invasive prenatal test (NIPT) for chromosomal defects in twins are lower than for single pregnancies [2, 15].



► **Fig. 3** Algorithm of ultrasound monitoring (completed weeks of pregnancy) for uncomplicated monochorionic twin pregnancies. DVP: deepest vertical pocket; PI: pulsatility index; MCA-PSV: peak systolic velocity ( $V_{max}$  of middle cerebral artery); A. umb: umbilical artery; MCA: middle cerebral artery; EFW: estimated fetal weight. Source: Arbeitsgemeinschaft der Wissenschaftlichen Medizinischen Fachgesellschaften e.V. (AWMF). Leitlinie zur Überwachung und Betreuung von Zwillingschwangerschaften. Online: <https://www.awmf.org/leitlinien/detail/ll/015-087.html>; Stand: 05.10.2020. [rerif]

- Ultrasound between 11–13<sup>+6</sup> weeks of pregnancy should include early structured malformation diagnosis including NT [16, 17].
- Twins are more likely to have an increased risk of chromosomal abnormalities after first-trimester screening (combined test) than singletons.

### Invasive prenatal Diagnosis in Twin Pregnancy

- The abortion rate after invasive diagnostics is about 2–3.8 % for CVS and 1.5–3.1 % for AC [18–21].
- Screening and invasive diagnostic procedures are more complex for twins compared to singletons;

- therefore such procedures should be performed by experienced physicians.
- The consultation should include the risks of puncture, possible discordance for aneuploidy, potential management strategies and the risks of embryo reduction or selective fetocide [1, 3].
- CVS should be the preferred method for DC twins as it can be employed earlier than amniocentesis.
- Early diagnosis of aneuploidy is particularly important in twin pregnancies, as the risk of selective fetocide is lower in the first trimester than in the second [22].
- The localization of the fetuses and placentas should be carefully mapped in order to allow clear assignment.
- DC twins should be sampled individually.
- If MC twins are also sampled separately, a heterokaryotype can be detected in the case of discordant chromosomal defects (e. g. for trisomies 21, 18, 13, Turner syndrome and triploidy described above).

### Implications of NT or CRL Discordance in the first Trimester

- The management of twin pregnancies with NT discordance  $\geq 20\%$  or CRL discordance  $\geq 10\%$  between 11–13<sup>+6</sup> of gestation should be discussed with experts in fetal medicine [23, 24].

### Ultrasound Screening for structural Anomalies in Twin Pregnancy

- Twin fetuses are to be examined for the presence of severe malformations during first-trimester ultrasound.
- Organ screening should be performed at about 20 (18–22) weeks of gestation [2, 17, 25], including fetal echocardiography [26, 27].

### Management of Twin Pregnancy discordant for Fetal Anomaly

- Twin pregnancies discordant for fetal anomaly should be referred to a fetal medicine center [2].

### Selective Fetocide in Twin Pregnancy

- In the case of anomalies in a discordant DC twin pregnancy, embryo reduction can be performed, preferably in the first trimester, by ultrasound-guided intracardiac injection of potassium chloride or lidocaine [22].
- When the diagnosis is made in the second trimester, women might opt for late selective termination in the third trimester, if legally possible, in order not to endanger the survivor in case of preterm birth [1].
- Selective fetocide in monochorionic twins is performed by cord occlusion, intrafetal laser ablation or radiofrequency ablation [1, 2, 22, 28–30].

## Screening for Risk of Preterm Birth in Twin Pregnancy

- Ultrasound cervical length measurement is the preferred screening method for preterm birth of twins;
- a cervix length of <25 cm in the second trimester should be used as a cut-off [1, 31].

## Fetal Growth Restriction

Fetal Growth Restriction (FGR, Intrauterine Growth Restriction, IUGR) in twins is found in both MC and DC twins.

Complications frequently affecting MC twins with FGR are Twin to Twin Transfusion Syndrome (TTTS), Twin Reversed Arterial Perfusion Sequence (TRAP) and Twin Anemia Polycythemia Sequence (TAPS).

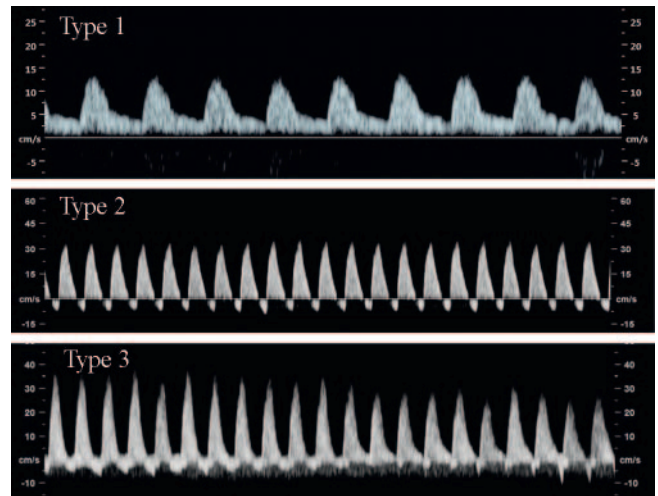
## Screening, Diagnosis and Management of Fetal Growth Restriction

### Diagnostic Criteria and Investigations for selective Fetal Growth Restriction (sFGR)

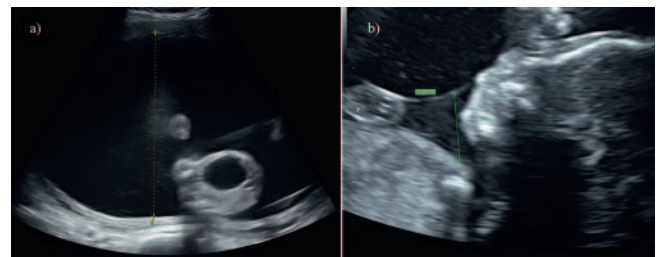
- A single estimated weight <3<sup>rd</sup> percentile in a twin, independent of chorionicity defines sFGR.
- At least 2 of the following 4 parameters must be met for MC twins (fetal weight of one fetus <10<sup>th</sup> percentile, abdominal circumference <10<sup>th</sup> percentile, EFW difference  $\geq$  25 %, umbilical artery PI of the smaller fetus >95<sup>th</sup> percentile).
- For DC twins, at least 2 of the following 3 parameters must be met (fetal weight of one fetus <10<sup>th</sup> percentile, EFW differential  $\geq$  25 %, umbilical artery PI of the smaller fetus >95<sup>th</sup> percentile) [32].
- Monitoring should be intensified in MC twins with a weight discrepancy  $\geq$  20 % as this is associated with increased intrauterine mortality and perinatal morbidity [33, 34].
- The estimated weight discordance should be calculated using the following formula:
- $(\text{weight of the larger twin} - \text{weight of the smaller twin}) \times 100 / \text{weight of the larger twin}$  [1].
- A search for the underlying causes of sFGR should include the following examinations: ultrasound scan, Doppler sonography, genetic family history and testing, infection screening [35].
- In MC twin pregnancies, sFGR is mainly due to unequal placental sharing [36].

### Screening for FGR in Twin Pregnancy

- A combination of head, abdomen and femur measurements is best used to estimate fetal weight [37].
- If the difference in the estimated fetal weights is  $\geq$  25 %, the patient should be referred to a Level 1 Perinatal Medicine Center [1].



► **Fig. 4** Classification of selective fetal growth restriction in mono-chorionic twin pregnancies. In Type I, the umbilical artery waveform shows a positive end-diastolic flow, while in Type II there is persistent absent or reverse end-diastolic flow (AREDF). In Type III there is a cyclical/intermittent AREDF pattern alternating with positive flow. Source: Arbeitsgemeinschaft der Wissenschaftlichen Medizinischen Fachgesellschaften e.V. (AWMF). Leitlinie zur Überwachung und Betreuung von Zwillingsschwangerschaften. Online: <https://www.awmf.org/leitlinien/detail/ll/015-087.html>; Stand: 05.10.2020. [rerif]



► **Fig. 5** Sonographic image of TTTS with **a** polyhydramnion of the recipient and **b** oligohydramnios of the donor. Source: Arbeitsgemeinschaft der Wissenschaftlichen Medizinischen Fachgesellschaften e.V. (AWMF). Leitlinie zur Überwachung und Betreuung von Zwillingsschwangerschaften. Online: <https://www.awmf.org/leitlinien/detail/ll/015-087.html>; Stand: 05.10.2020. [rerif]

### Classification of sFGR in MC Twin Pregnancy

In MC DA twins sFGR is classified based on the end-diastolic flow profile of the umbilical arteries: [38].

- Type I: EDF-positive
- Type II AREDF
- Type III: cyclical/intermittent AREDF

EDF: end-diastolic flow

AREDF: absent or reversed end diastolic flow (► **Fig. 4**)

### Management of Twin Pregnancy complicated by sFGR

- DC twin pregnancies with sFGR should be monitored like singletons with FGR [1].



- There is limited evidence available to guide the management of MC twins affected by sFGR.
- Possible options include: conservative management followed by early delivery, laser ablation, or cord occlusion of the growth-restricting twin (in order to protect the other twin) [39].

### Follow-up of Twin Pregnancy complicated by sFGR

- In DC twin pregnancy complicated by sFGR, fetal Doppler examinations should be performed approximately every two weeks.
- Fetal Doppler examinations should be performed at least every week for MC twin pregnancies.
- Management of MC DA twin pregnancies affected by sFGR is complex and should be performed at a Perinatal Center [39].
- The timing of delivery should be based on the evaluation of interval growth, fetal Doppler findings and/or CTG and, if available, computerized CTG analysis [1].

### Management of the surviving Twin after Demise of the Cotwin

- When a single intrauterine demise occurs in an MC pregnancy, the woman should be referred to a Perinatal center,
- A Doppler examination of the middle cerebral artery should be performed with measurement of maximum velocity ( $V_{max}$ ) in order to estimate the probability of fetal anemia [1, 40].

When one MC twin dies *in utero*, the surviving twin may then lose part of its circulating volume to the dead twin, leading to potentially severe hypotension in the survivor, which can lead to hypoperfusion of the brain and other organs, potentially causing brain damage or death [41].

The following complications can occur after a single intrauterine demise of an MC or DC twin [41, 42]:

- Death of a cotwin 15 % and 3 %
- Preterm delivery 68 % and 3 %
- Abnormal cranial image of the cotwin 34 % and 16 %
- Neurodevelopmental impairment of the surviving cotwin 26 % and 2 %
- Brain damage is usually the result of a hypoxic-ischemic lesion that results in the development of cystic periventricular leukomalacia, infarction of the middle cerebral artery, or damage to the basal ganglia, thalamus and/or cortex.
- Pre- and postnatal imaging including high-resolution ultrasound and, if necessary, an MRI should be performed.
- Additionally, there should be long-term pediatric follow-up [43].
- If there is strong suspicion that the surviving twin may have suffered serious neurological damage, late termination of pregnancy should be considered as an option [1].

### Complications unique to Monochorionic Twin Pregnancy

Complications that occur exclusively in MC twin pregnancies are TTTs, TAPS and TRAP sequence, monoamniotic pregnancies and conjoined twins.

► **Table 1** Staging system modified according to Quintero [44].

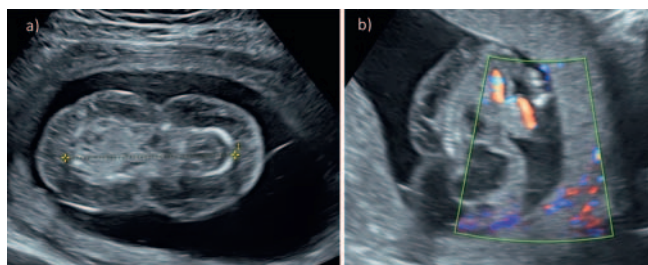
stage	classification
I	oligohydramnios-polyhydramnios sequence <ul style="list-style-type: none"> <li>donor: DVP &lt; 2 cm</li> <li>recipient: DVP &gt; 8 cm (≤ 20 weeks gestation), &gt; 10 cm (&gt; 20 weeks gestation)</li> </ul>
II	<ul style="list-style-type: none"> <li>donor: urinary bladder not visible in ultrasound</li> </ul>
III	<ul style="list-style-type: none"> <li>absent or reversed umbilical-arterial diastolic flow</li> <li>absent or reversed a-wave in ductus venosus</li> <li>pulsatile umbilical-venous flow in one of the twins</li> </ul>
IV	<ul style="list-style-type: none"> <li>hydrops in one or both twins</li> </ul>

DVP, deepest vertical pocket (amniotic fluid depot).

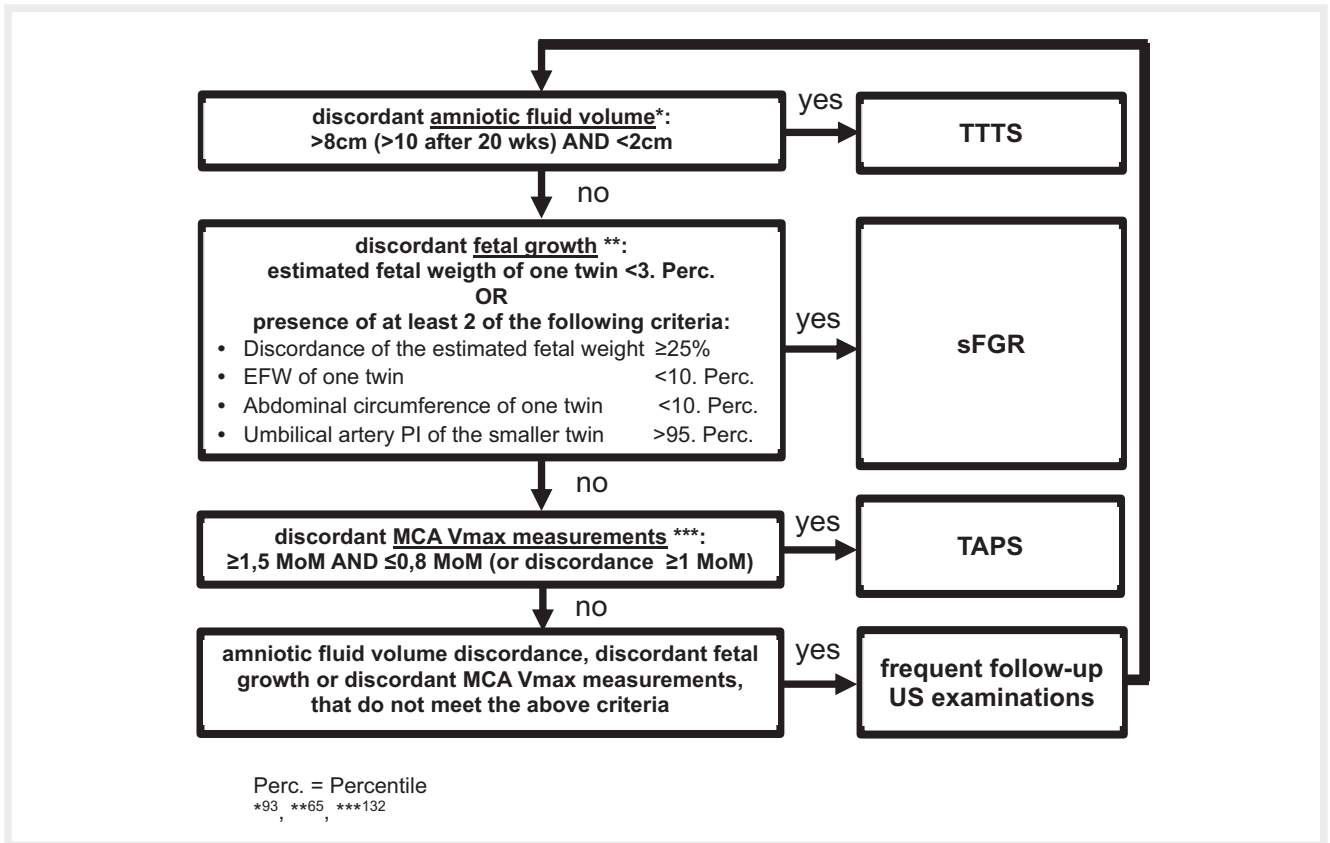
► **Table 2** Antenatal and postnatal stage classification of the Twin Anemia Polycythemia Sequence (TAPS), modified according to Slaghekke and Lopriore [54, 55].

stage	antenatal staging	postnatal staging interfetal Hb differential (g/dL)
1	MCA-PSV donor 1.5 MoM and recipient < 1.0 MoM, without other signs of fetal compromise	> 8.0
2	MCA-PSV donor 1.7 MoM and recipient < 0.8 MoM, without other signs of fetal compromise	> 11.0
3	stage 1 or 2 with donor cardiac compromise umbilical artery AREDF, umbilical vein pulsatile, DV PVIV raised/ a-wave negative	> 14.0
4	donor hydrops	> 17.0

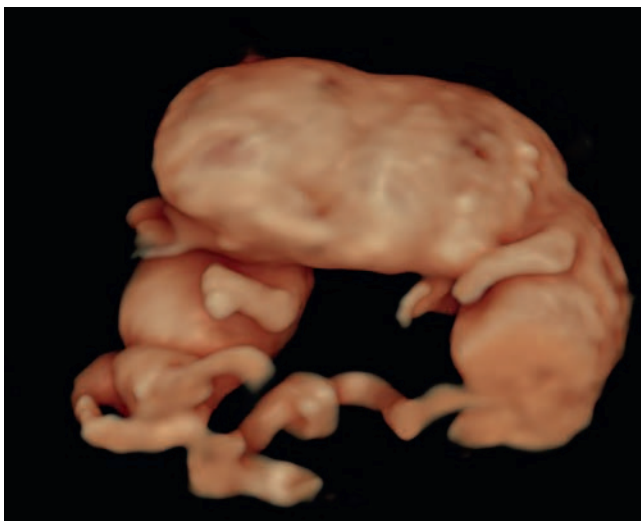
Hb: hemoglobin; MCA: middle cerebral artery; MoM: multiple of median value; PSV: peak systolic velocity ( $V_{max}$  of middle cerebral artery).



► **Fig. 6** a Sagittal visualization of a TRAP fetus, b visualization of retrograde blood flow in the TRAP fetus. Source: Arbeitsgemeinschaft der Wissenschaftlichen Medizinischen Fachgesellschaften e.V. (AWMF). Leitlinie zur Überwachung und Betreuung von Zwillingsschwangerschaften. Online: <https://www.awmf.org/leitlinien/detail/II/015-087.html>; Stand: 05.10.2020. [rerif]



► **Fig. 7** Diagnostic algorithm for monochorionic-diamniotic twins with discordant findings. Source: Arbeitsgemeinschaft der Wissenschaftlichen Medizinischen Fachgesellschaften e.V (AWMF). Leitlinie zur Überwachung und Betreuung von Zwillingschwangerschaften. Online: <https://www.awmf.org/leitlinien/detail/II/015-087.html>; Stand: 05.10.2020. [rerif]



► **Fig. 8** Three-dimensional ultrasound image of a cephalopagus at 10 weeks of gestation. Source: Arbeitsgemeinschaft der Wissenschaftlichen Medizinischen Fachgesellschaften e.V (AWMF). Leitlinie zur Überwachung und Betreuung von Zwillingschwangerschaften. Online: <https://www.awmf.org/leitlinien/detail/II/015-087.html>; Stand: 05.10.2020. [rerif]

## Twin-to-Twin-Transfusion Syndrome (TTTS)

### TTTS Staging

- The Quintero staging system is the most widely used classification system of TTTS [44].
- This system is not always predictive of the outcome and is not always chronological, e. g. Stage I can lead directly to Stage III or intrauterine fetal death [1] (► **Fig. 5**, ► **Table 1**).

### Screening for TTTS

- In MC twin pregnancy, screening for TTTS should start at 16 weeks of gestation, with scans repeated every 2 weeks thereafter [1].
- If TTTS is diagnosed, the patient should be referred to a specialized center as soon as the following criteria are met:
  - Donor: DVP <2 cm
  - Recipient: DVP >8 cm (≤20 weeks gestation) or >10 cm (>20 weeks gestation) [1, 3]
- MC twin pregnancies with amniotic fluid discordance should be checked on a weekly basis to rule out progression to TTTS [1].

► **Table 3** Recommended time of birth of uncomplicated dichorial (DC), monochorionic diamniotic (MC DA) and monochorionic monoamniotic (MC MA) twins according to international guidelines [3, 67–70].

professional Society	DC twins	MC DA twins	MC MA twins
National Guideline Alliance (UK). Twin and Triplet Pregnancy. London: National Institute for Health and Care Excellence (UK); 2019 [3]	37 <sup>+0</sup> – 37 <sup>+6</sup>	36 <sup>+0</sup> – 36 <sup>+6</sup> (after LMI)	32 <sup>+0</sup> – 33 <sup>+6</sup>
Royal College of Obstetricians and Gynaecologists (RCOG) [67]	–	from 36 <sup>+0</sup> (after LMI)	32 <sup>+0</sup> – 34 <sup>+6</sup>
American College of Obstetricians and Gynecologists (ACOG) [68]	38	34 <sup>+0</sup> – 37 <sup>+6</sup>	32–34
Royal Australian and New Zealand College of Obstetricians and Gynecologists (RANZ-COG) [69]	–	up to 37	–
French College of Gynaecologists and Obstetricians (CNGOF) [70]	38 – <40	36 – <38 <sup>+6</sup>	32 – <36

LMI = Lung Maturation Induction; GW = gestation weeks (completed weeks and additional days).

► **Table 4** Overview of recommendations of national professional societies on the delivery mode in uncomplicated dichorial, monochorial and monoamniotic twins [3, 67–70].

professional Society	DC DA twins	MC DA twins	MC MA twins
National Guideline Alliance (UK). Twin and Triplet Pregnancy. London: National Institute for Health and Care Excellence (UK); 2019 [3]	vaginal delivery under the the following conditions: <ul style="list-style-type: none"> <li>uncomplicated pregnancy</li> <li>&gt; 32 weeks of gestation</li> <li>no contraindications</li> <li>first child in cephalic position</li> <li>no significance discordance in EFW</li> </ul>	vaginal delivery under the the following conditions: <ul style="list-style-type: none"> <li>uncomplicated pregnancy</li> <li>&gt; 32 weeks of gestation</li> <li>no contraindications</li> <li>first child in cephalic position</li> <li>no significance discordance in EFW</li> </ul>	primary C-section
Royal College of Obstetricians and Gynaecologists (RCOG) [67]	–	planned vaginal birth	primary C-section
American College of Obstetricians and Gynecologists (ACOG) [68]	planned vaginal birth > 32 <sup>+0</sup> GW regardless whether twin II in cephalic or breech presentation	planned vaginal birth > 32 <sup>+0</sup> GW regardless whether twin II in cephalic or breech presentation	primary C-section
Royal Australian and New Zealand College of Obstetricians and Gynecologists (RANZ-COG) [69]	planned vaginal birth only when sufficient infrastructure available for continuous fetal monitoring or emergency C-section	planned vaginal birth only when sufficient infrastructure available for continuous fetal monitoring or emergency C-section	–
French College of Gynaecologists and Obstetricians (CNGOF) [70]	vaginal birth regardless of gestational age and child presentation	vaginal birth regardless of gestational age and child presentation	–

### TTTS Therapy

- Laser ablation is the treatment of choice for TTTS.
- Patients with TTTS should be referred promptly to a center providing this therapy [45–47].
- Conservative management with close monitoring may be considered for Quintero Stage I without maternal complications due to a massive polyhydramnion or short cervix [1, 48].
- After laser therapy, further ultrasound examinations should initially be performed weekly and every two weeks if symptoms subside [1].

### Neurological follow-up for TTTS

MC twin pregnancies with TTTS have an increased risk of brain abnormalities and delayed neurological development. Both donor and recipient are at increased risk for ischemic or hemorrhagic le-

sions. The risk for neurological developmental disorders after laser therapy is between 4% and 13% and is thus about half as low as after amniotic reduction [49].

### Twin Anemia-Polycythemia Sequence (TAPS)

- TAPS is based on the findings of discordant systolic  $V_{max}$  values of the middle cerebral artery in both fetuses [1, 50, 51].
- There is limited evidence regarding the outcome and optimal management of TAPS; therefore treatment options should be individualized and discussed with the parents [1].
- MC twins with TAPS have an increased risk of delayed neurological development.
- Cerebral imaging in the third trimester and a developmental neurological examination at the age of 2 years is recommended [52, 53] (► **Table 2**).



## Twin Reversed Arterial Perfusion (TRAP) Sequence

- The chances of survival of the pumping twin can be increased by using minimally invasive techniques (e. g. laser coagulation of the anastomoses as well as intrafetal methods, umbilical cord coagulation), if necessary even before 16 weeks [1, 56–58] (► Fig. 6, 7).

## MC MA Twins

- Umbilical cord entanglement is almost always present in MC MA twins and does not appear to contribute essentially to morbidity and mortality [59].

## Conjoined Twins

Conjoined twins are very rare and are always MC MA pregnancies. Ultrasound diagnosis in the first trimester is now common by visualization of near and fixed fetal bodies with partial fusion of the bodies (► Fig. 8).

## Time of birth for twin pregnancies

### Time of Birth of uncomplicated DC DA and MC DA Twins

- Uncomplicated DC twins should be delivered at between 37<sup>+0</sup>–38<sup>+0</sup> weeks of gestation.
- Uncomplicated MC DA twins should be delivered at between 36<sup>+0</sup>–37<sup>+0</sup> weeks of gestation [60–64].

### Time of Birth of uncomplicated MC MA Twins

- Uncomplicated MC MA twins should be delivered at between 32<sup>+0</sup>–32<sup>+6</sup> weeks of gestation [3, 65, 66].

The decision to deliver uncomplicated MC MA twins between 32<sup>+0</sup>–32<sup>+6</sup> weeks of gestation is based on the observation that intrauterine mortality doubles subsequently [65, 66].

The recommendation on the time of birth for MC MA twins was adopted by expert consensus due to the lack of randomized trials (► Table 3).

## Delivery Mode for Twin Pregnancies

### Delivery Mode for uncomplicated DC and MC DA Twins > 32 Weeks of Gestation

- Uncomplicated twins > 32 weeks of gestation, first twin in cephalic position, without contraindications or growth discordance, can be delivered vaginally or by C-section.
- Chorionicity plays no role in delivery mode [71–78].

### Delivery Mode for uncomplicated DC and MC DA Twins < 32 Weeks of Gestation

- There is insufficient evidence available to offer a firm recommendation for the delivery of uncomplicated twins < 32 weeks of gestation [79, 80].

## Delivery Mode for uncomplicated MC MA Twins

The recommendation on the delivery mode for MC MA twins was adopted by expert consensus due to the lack of randomized studies.

- MC MA twins should be delivered by C-section [3] (► Table 4).

## Funding

Deutsche Stiftung Frauengesundheit, Deutsche Gesellschaft für Gynäkologie und Geburtshilfe (DGGG), Deutsche Gesellschaft für Ultraschall in der Medizin (DEGUM).

## Conflict of Interest

The authors declare that they have no conflict of interest.

## References

- [1] Khalil A, Rodgers M, Baschat A et al. ISUOG Practice Guidelines: role of ultrasound in twin pregnancy. *Ultrasound Obstet Gynecol* 2016; 47: 247–263
- [2] NICE. National Institute for Health and Care Excellence Clinical Guideline 129: Multiple Pregnancy – The Management of Twin and Triplet Pregnancies in the Antenatal Period. London, 2011. In, *Multiple Pregnancy: The Management of Twin and Triplet Pregnancies in the Antenatal Period*
- [3] NICE. National Institute for Health and Care Excellence Guideline 137: Twin and Triplet Pregnancy. London, 2019
- [4] Dias T, Mahsud-Dornan S, Thilaganathan B et al. First-trimester ultrasound dating of twin pregnancy: are singleton charts reliable? *BJOG* 2010; 117: 979–984
- [5] Salomon LJ, Cavicchioni O, Bernard JP et al. Growth discrepancy in twins in the first trimester of pregnancy. *Ultrasound Obstet Gynecol* 2005; 26: 512–516
- [6] Maruotti GM, Saccone G, Morlando M et al. First-trimester ultrasound determination of chorionicity in twin gestations using the lambda sign: a systematic review and meta-analysis. *Eur J Obstet Gynecol Reprod Biol* 2016; 202: 66–70
- [7] Dias T, Ladd S, Mahsud-Dornan S et al. Systematic labeling of twin pregnancies on ultrasound. *Ultrasound Obstet Gynecol* 2011; 38: 130–133
- [8] D'Antonio F, Khalil A, Thilaganathan B et al. Second-trimester discordance and adverse perinatal outcome in twins: the STORK multiple pregnancy cohort. *BJOG* 2014; 121: 422–429
- [9] Sueters M, Middeldorp JM, Lopriore E et al. Timely diagnosis of twin-to-twin transfusion syndrome in monochorionic twin pregnancies by bi-weekly sonography combined with patient instruction to report onset of symptoms. *Ultrasound Obstet Gynecol* 2006; 28: 659–664
- [10] de Villiers SF, Slaghekke F, Middeldorp JM et al. Placental characteristics in monochorionic twins with spontaneous versus post-laser twin anemia-polycythemia sequence. *Placenta* 2013; 34: 456–459
- [11] Prats P, Rodriguez I, Comas C et al. Systematic review of screening for trisomy 21 in twin pregnancies in first trimester combining nuchal translucency and biochemical markers: a meta-analysis. *Prenat Diagn* 2014; 34: 1077–1083
- [12] Kagan KO, Sonek J, Wagner P et al. Principles of first trimester screening in the age of non-invasive prenatal diagnosis: screening for other major defects and pregnancy complications. *Arch Gynecol Obstet* 2017; 296: 635–643
- [13] Dagklis T, Plascencia W, Maiz N et al. Choroid plexus cyst, intracardiac echogenic focus, hyperechogenic bowel and hydronephrosis in screening for trisomy 21 at 11 + 0 to 13 + 6 weeks. *Ultrasound Obstet Gynecol* 2008; 31: 132–135

- [14] Chaveeva P, Wright A, Syngelaki A et al. First-trimester screening for trisomies in pregnancies with vanishing twin. *Ultrasound Obstet Gynecol* 2020; 55: 326–331
- [15] Gil MM, Accurti V, Santacruz B et al. Analysis of cell-free DNA in maternal blood in screening for aneuploidies: updated meta-analysis. *Ultrasound Obstet Gynecol* 2017; 50: 302–314
- [16] Salomon LJ, Alfirevic Z, Bilardo CM et al. ISUOG practice guidelines: performance of first-trimester fetal ultrasound scan. *Ultrasound Obstet Gynecol* 2013; 41: 102–113
- [17] von Kaisenberg C, Chaoui R, Häusler M et al. Qualitätsanforderungen an die Ultraschalluntersuchung in der Frühschwangerschaft (DEGUM-Stufe I) zwischen 4+0 und 13+6 Schwangerschaftswochen. *Ultraschall in Med* 2016; 37: 297–302
- [18] Agarwal K, Alfirevic Z. Pregnancy loss after chorionic villus sampling and genetic amniocentesis in twin pregnancies: a systematic review. *Ultrasound Obstet Gynecol* 2012; 40: 128–134
- [19] Gallot D, Velemir L, Delabaere A et al. [Which invasive diagnostic procedure should we use for twin pregnancies: chorionic villous sampling or amniocentesis?]. *J Gynecol Obstet Biol Reprod (Paris)* 2009; 38: S39–S44
- [20] Hansen M, Kurinczuk JJ, Milne E et al. Assisted reproductive technology and birth defects: a systematic review and meta-analysis. *Hum Reprod Update* 2013; 19: 330–353
- [21] Ghi T, Sotiriadis A, Calda P et al. ISUOG Practice Guidelines: invasive procedures for prenatal diagnosis. *Ultrasound Obstet Gynecol* 2016; 48: 256–268
- [22] Evans MI, Goldberg JD, Horenstein J et al. Selective termination for structural, chromosomal, and mendelian anomalies: international experience. *Am J Obstet Gynecol* 1999; 181: 893–897
- [23] Kagan KO, Gazzoni A, Sepulveda-Gonzalez G et al. Discordance in nuchal translucency thickness in the prediction of severe twin-to-twin transfusion syndrome. *Ultrasound Obstet Gynecol* 2007; 29: 527–532
- [24] Mackie FL, Hall MJ, Morris RK et al. Early prognostic factors of outcomes in monochorionic twin pregnancy: systematic review and meta-analysis. *Am J Obstet Gynecol* 2018; 219: 436–446
- [25] Merz E, Eichhorn KH, von Kaisenberg C et al. Aktualisierte Qualitätsanforderungen an die weiterführende differenzierte Ultraschalluntersuchung in der pränatalen Diagnostik (= DEGUM-Stufe II) im Zeitraum von 18+0 bis 21+6 Schwangerschaftswochen. *Ultraschall in Med* 2012; 33: 593–596
- [26] Carvalho JS. Gynecology ISOiOa, Gynecology et al. ISUOG Practice Guidelines (updated): sonographic screening examination of the fetal heart. *Ultrasound Obstet Gynecol* 2013; 41: 348–359
- [27] Chaoui R, Heling K, Mielke G et al. Qualitätsanforderungen der DEGUM zur Durchführung der fetalen Echokardiografie. *Ultraschall in Med* 2008; 29: 197–200
- [28] Machin G. Non-identical monozygotic twins, intermediate twin types, zygosity testing, and the non-random nature of monozygotic twinning: a review. *Am J Med Genet C Semin Med Genet* 2009; 151C: 110–127
- [29] Lewi L, Blickstein I, Van Schoubroeck D et al. Diagnosis and management of heterokaryotypic monochorionic twins. *Am J Med Genet A* 2006; 140: 272–275
- [30] Lewi L, Gratacos E, Ortibus E et al. Pregnancy and infant outcome of 80 consecutive cord coagulations in complicated monochorionic multiple pregnancies. *Am J Obstet Gynecol* 2006; 194: 782–789
- [31] Conde-Agudelo A, Romero R, Hassan SS et al. Transvaginal sonographic cervical length for the prediction of spontaneous preterm birth in twin pregnancies: a systematic review and metaanalysis. *Am J Obstet Gynecol* 2010; 203: 128e121–112
- [32] Khalil A, Beune I, Hecher K et al. Consensus definition and essential reporting parameters of selective fetal growth restriction in twin pregnancy: a Delphi procedure. *Ultrasound Obstet Gynecol* 2019; 53: 47–54
- [33] Leombroni M, Liberati M, Fanfani F et al. Diagnostic accuracy of ultrasound in predicting birth-weight discordance in twin pregnancy: systematic review and meta-analysis. *Ultrasound Obstet Gynecol* 2017; 50: 442–450
- [34] D'Antonio F, Odibo AO, Prefumo F et al. Weight discordance and perinatal mortality in twin pregnancy: systematic review and meta-analysis. *Ultrasound Obstet Gynecol* 2018; 52: 11–23
- [35] Sueters M, Oepkes D. Diagnosis of twin-to-twin transfusion syndrome, selective fetal growth restriction, twin anaemia-polycythaemia sequence, and twin reversed arterial perfusion sequence. *Best Pract Res Clin Obstet Gynaecol* 2014; 28: 215–226
- [36] Lewi L, Gucciardo L, Huber A et al. Clinical outcome and placental characteristics of monochorionic diamniotic twin pairs with early- and late-onset discordant growth. *Am J Obstet Gynecol* 2008; 199: 511e511–e517
- [37] Khalil A, D'Antonio F, Dias T et al. Ultrasound estimation of birth weight in twin pregnancy: comparison of biometry algorithms in the STORK multiple pregnancy cohort. *Ultrasound Obstet Gynecol* 2014; 44: 210–220
- [38] Gratacos E, Lewi L, Munoz B et al. A classification system for selective intrauterine growth restriction in monochorionic pregnancies according to umbilical artery Doppler flow in the smaller twin. *Ultrasound Obstet Gynecol* 2007; 30: 28–34
- [39] Chalouhi GE, Marangoni MA, Quibel T et al. Active management of selective intrauterine growth restriction with abnormal Doppler in monochorionic diamniotic twin pregnancies diagnosed in the second trimester of pregnancy. *Prenat Diagn* 2013; 33: 109–115
- [40] Senat MV, Loizeau S, Couderc S et al. The value of middle cerebral artery peak systolic velocity in the diagnosis of fetal anemia after intrauterine death of one monochorionic twin. *Am J Obstet Gynecol* 2003; 189: 1320–1324
- [41] Hillman SC, Morris RK, Kilby MD. Co-twin prognosis after single fetal death: a systematic review and meta-analysis. *Obstet Gynecol* 2011; 118: 928–940
- [42] Ong SS, Zamora J, Khan KS et al. Prognosis for the co-twin following single-twin death: a systematic review. *BJOG* 2006; 113: 992–998
- [43] van Klink JM, van Steenis A, Steggerda SJ et al. Single fetal demise in monochorionic pregnancies: incidence and patterns of cerebral injury. *Ultrasound Obstet Gynecol* 2015; 45: 294–300
- [44] Quintero RA, Morales WJ, Allen MH et al. Staging of twin-twin transfusion syndrome. *J Perinatol* 1999; 19: 550–555
- [45] Roberts D, Neilson JP, Kilby MD et al. Interventions for the treatment of twin-twin transfusion syndrome. *Cochrane Database Syst Rev* 2014. doi:10.1002/14651858.CD002073.pub3:CD002073
- [46] Senat MV, Deprest J, Boulvain M et al. Endoscopic laser surgery versus serial amnioreduction for severe twin-to-twin transfusion syndrome. *N Engl J Med* 2004; 351: 136–144
- [47] Diehl W, Diemert A, Grasso D et al. Fetoscopic laser coagulation in 1020 pregnancies with twin-twin transfusion syndrome demonstrates improvement in double-twin survival rate. *Ultrasound Obstet Gynecol* 2017; 50: 728–735
- [48] Khalil A, Cooper E, Townsend R et al. Evolution of Stage 1 Twin-to-Twin Transfusion Syndrome (TTTS): Systematic Review and Meta-Analysis. *Twin Res Hum Genet* 2016; 19: 207–216
- [49] Hecher K, Gardiner HM, Diemert A et al. Long-term outcomes for monochorionic twins after laser therapy in twin-to-twin transfusion syndrome. *Lancet Child Adolesc Health* 2018; 2: 525–535
- [50] Khalil A, Gordijn S, Ganzevoort W et al. Consensus diagnostic criteria and monitoring of twin anemia polycythemia sequence: a Delphi procedure. *Ultrasound Obstet Gynecol* 2019. doi:10.1002/uog.21882

- [51] Tavares de Sousa M, Fonseca A, Hecher K. Role of fetal intertwin difference in middle cerebral artery peak systolic velocity in predicting neonatal twin anemia-polycythemia sequence. *Ultrasound Obstet Gynecol* 2019; 53: 794–797
- [52] Slaghekke F, van Klink JM, Koopman HM et al. Neurodevelopmental outcome in twin anemia-polycythemia sequence after laser surgery for twin-twin transfusion syndrome. *Ultrasound Obstet Gynecol* 2014; 44: 316–321
- [53] Tollenaar LSA, Lopriore E, Slaghekke F et al. High risk of long-term neurodevelopmental impairment in donor twins with spontaneous twin anemia-polycythemia sequence. *Ultrasound Obstet Gynecol* 2020; 55: 39–46
- [54] Slaghekke F, Kist WJ, Oepkes D et al. Twin anemia-polycythemia sequence: diagnostic criteria, classification, perinatal management and outcome. *Fetal Diagn Ther* 2010; 27: 181–190
- [55] Lopriore E, Slaghekke F, Oepkes D et al. Hematological characteristics in neonates with twin anemia-polycythemia sequence (TAPS). *Prenat Diagn* 2010; 30: 251–255
- [56] Hecher K, Lewi L, Gratacos E et al. Twin reversed arterial perfusion: fetoscopic laser coagulation of placental anastomoses or the umbilical cord. *Ultrasound Obstet Gynecol* 2006; 28: 688–691
- [57] Pagani G, D'Antonio F, Khalil A et al. Intrafetal laser treatment for twin reversed arterial perfusion sequence: cohort study and meta-analysis. *Ultrasound Obstet Gynecol* 2013; 42: 6–14
- [58] Tavares de Sousa M, Glosemeyer P, Diemert A et al. First-trimester intervention in twin reversed arterial perfusion sequence. *Ultrasound Obstet Gynecol* 2020; 55: 47–49
- [59] Rossi AC, Prefumo F. Impact of cord entanglement on perinatal outcome of monoamniotic twins: a systematic review of the literature. *Ultrasound Obstet Gynecol* 2013; 41: 131–135
- [60] Dodd JM, Deussen AR, Grivell RM et al. Elective birth at 37 weeks' gestation for women with an uncomplicated twin pregnancy. *Cochrane Database Syst Rev* 2014. doi:10.1002/14651858.CD003582.pub2: CD003582
- [61] Saccone G, Berghella V. Planned delivery at 37 weeks in twins: a systematic review and meta-analysis of randomized controlled trials. *J Matern Fetal Neonatal Med* 2016; 29: 685–689
- [62] Cheong-See F, Schuit E, Arroyo-Manzano D et al. Prospective risk of stillbirth and neonatal complications in twin pregnancies: systematic review and meta-analysis. *BMJ* 2016; 354: i4353
- [63] Danon D, Sekar R, Hack KE et al. Increased stillbirth in uncomplicated monoamniotic twin pregnancies: a systematic review and meta-analysis. *Obstet Gynecol* 2013; 121: 1318–1326
- [64] Page JM, Pilliod RA, Snowden JM et al. The risk of stillbirth and infant death by each additional week of expectant management in twin pregnancies. *Am J Obstet Gynecol* 2015; 212: 630e631–637
- [65] D'Antonio F, Odibo A, Berghella V et al. Perinatal mortality, timing of delivery and prenatal management of monoamniotic twin pregnancy: systematic review and meta-analysis. *Ultrasound Obstet Gynecol* 2019; 53: 166–174
- [66] Van Mieghem T, De Heus R, Lewi L et al. Prenatal management of monoamniotic twin pregnancies. *Obstet Gynecol* 2014; 124: 498–506
- [67] Kilby M, Bricker LobotRCOaG. Management of Monochorionic Twin Pregnancy: Green-top Guideline No. 51. *BJOG* 2017; 124: e1–e45
- [68] Committee on Practice B-O, Society for Maternal-Fetal M. Practice Bulletin No. 169: Multifetal Gestations: Twin, Triplet, and Higher-Order Multifetal Pregnancies. *Obstet Gynecol* 2016; 128: e131–e146
- [69] RANZCOG, Board, Council. Management of monochorionic twin pregnancy. College Statement 42 2011. [https://ranzocg.edu.au/RANZCOG\\_SITE/media/RANZCOG-MEDIA/Women%27s%20Health/Statement%20and%20guidelines/Clinical-Obstetrics/Management-of-Monochorionic-Twins-\(C-Obs-42\)-review-July-2017.pdf?ext=.pdf](https://ranzocg.edu.au/RANZCOG_SITE/media/RANZCOG-MEDIA/Women%27s%20Health/Statement%20and%20guidelines/Clinical-Obstetrics/Management-of-Monochorionic-Twins-(C-Obs-42)-review-July-2017.pdf?ext=.pdf)
- [70] Vayssiere C, Benoist G, Blondel B et al. Twin pregnancies: guidelines for clinical practice from the French College of Gynaecologists and Obstetricians (CNGOF). *Eur J Obstet Gynecol Reprod Biol* 2011; 156: 12–17
- [71] Barrett JF, Hannah ME, Hutton EK et al. A randomized trial of planned cesarean or vaginal delivery for twin pregnancy. *N Engl J Med* 2013; 369: 1295–1305
- [72] Hofmeyr GJ, Barrett JF, Crowther CA. Planned caesarean section for women with a twin pregnancy. *Cochrane Database Syst Rev* 2015. doi:10.1002/14651858.CD006553.pub3:CD006553
- [73] Asztalos EV, Hannah ME, Hutton EK et al. Twin Birth Study: 2-year neurodevelopmental follow-up of the randomized trial of planned cesarean or planned vaginal delivery for twin pregnancy. *Am J Obstet Gynecol* 2016; 214: 371e371–371, e319
- [74] Hutton EK, Hannah ME, Ross S et al. Maternal outcomes at 3 months after planned cesarean section versus planned vaginal birth for twin pregnancies in the Twin Birth Study: a randomised controlled trial. *BJOG* 2015; 122: 1653–1662
- [75] Schmitz T, Korb D, Battie C et al. Neonatal morbidity associated with vaginal delivery of noncephalic second twins. *Am J Obstet Gynecol* 2018; 218: 449e441–449, e413
- [76] Schmitz T, Prunet C, Azria E et al. Association Between Planned Cesarean Delivery and Neonatal Mortality and Morbidity in Twin Pregnancies. *Obstet Gynecol* 2017; 129: 986–995
- [77] Goossens S, Ensing S, van der Hoeven M et al. Comparison of planned cesarean delivery and planned vaginal delivery in women with a twin pregnancy: A nation wide cohort study. *Eur J Obstet Gynecol Reprod Biol* 2018; 221: 97–104
- [78] Korb D, Deneux-Tharaux C, Seco A et al. Risk of Severe Acute Maternal Morbidity According to Planned Mode of Delivery in Twin Pregnancies. *Obstet Gynecol* 2018; 132: 647–655
- [79] Dagenais C, Lewis-Mikhael AM, Grabovac M et al. What is the safest mode of delivery for extremely preterm cephalic/non-cephalic twin pairs? A systematic review and meta-analyses. *BMC Pregnancy Childbirth* 2017; 17: 397
- [80] Sentilhes L, Oppenheimer A, Bouhours AC et al. Neonatal outcome of very preterm twins: policy of planned vaginal or cesarean delivery. *Am J Obstet Gynecol* 2015; 213: 73e71–73, e77