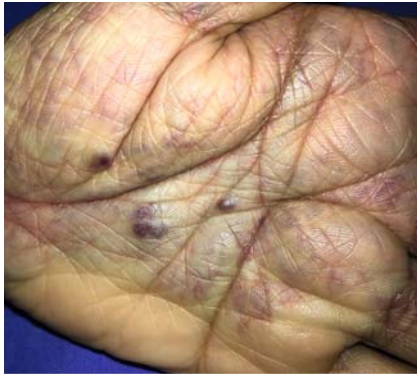
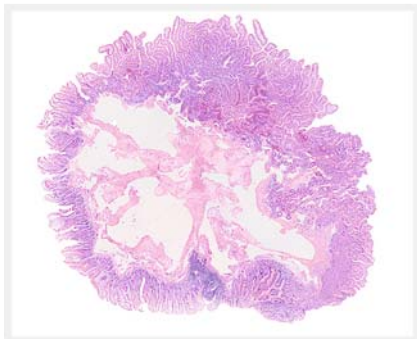


An endoscopic multimodal approach in a patient with blue rubber bleb nevus syndrome and acute bleeding

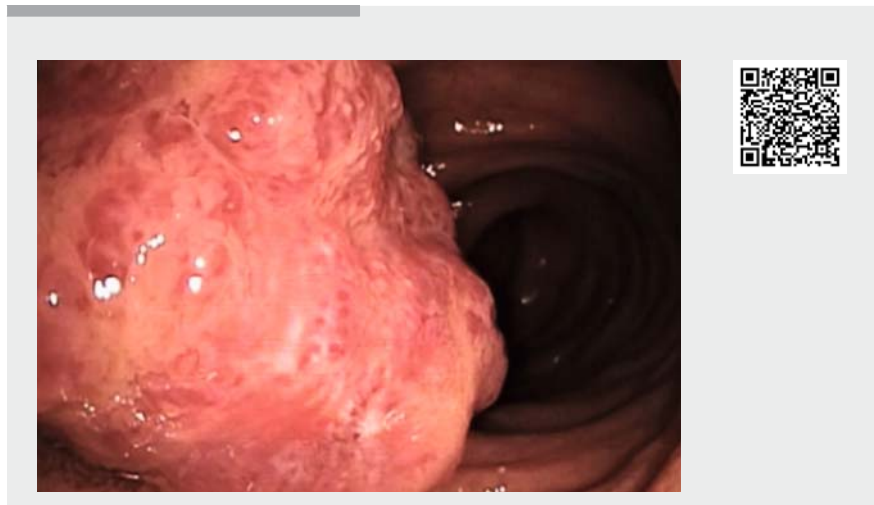

► **Fig. 1** Violaceous soft papules in the hand, lesions that are characteristic of blue rubber bleb nevus syndrome.



► **Fig. 2** Histopathology of the resected lesion showing tortuous, ectatic vessels with red blood cells, lined by a single layer of endothelium, compatible with a hemangioma.

Blue rubber bleb nevus syndrome is a rare disease characterized by multiple venous malformations found in various organs, among which the gastrointestinal (GI) tract stands out [1]. Patients frequently suffer GI bleeding and iron deficiency anemia. Many endoscopic therapeutic options have been implemented for treatment of this syndrome, such as endoscopic sclerotherapy [2, 3], endoscopic band ligation, detachable snare [4], and even endoscopic submucosal dissection [5].



► **Video 1** Venous malformation in the jejunum. **a** Endoscopic capsule. **b** Single-session multimodal approach in blue rubber bleb nevus syndrome. **c** Follow-up enteroscopy.

Herein we present the case of a 44-year-old man with a diagnosis of blue rubber bleb nevus syndrome (► **Fig. 1**) who arrived at the emergency department after 2 days with melena. Laboratory findings on admission reported microcytic anemia (hemoglobin 8.9 g/dl, mean corpuscular volume 77 fl) and mild thrombocytopenia (138 K/uL). Upper endoscopy disclosed purplish lesions on the hypopharynx, esophagus, stomach, and duodenum without signs of active or recent bleeding. A colonoscopy showed hemangiomas in the left colon and the rectum without signs of active or recent bleeding. An endoscopic capsule revealed purplish blebs larger than 10 mm at the proximal jejunum with active bleeding (► **Video 1**). Finally, an antegrade enteroscopy was performed showing 8 hemangiomas in the jejunum. Cyanoacrylate was applied in a large lesion (>2 cm), a snare resection was performed in two lesions, and a detachable snare was inserted in another (► **Fig. 2**, ► **Video 1**). The patient remained without clinical or laboratory signs of gastrointestinal

bleeding, therefore he was discharged without further complications. A follow-up enteroscopy was performed 14 weeks after his discharge, which showed adequate scarring. Signs of neovascularization were observed in the sites of snare resection and detachable snare insertion, with the application of argon plasma in the site of snare resection being necessary (► **Video 1**).

In conclusion, there is no technique of choice for endoscopic management of the blue rubber bleb nevus syndrome; however an endoscopic multimodal approach is effective in the treatment of acute bleeding in these patients.

Endoscopy_UCTN_Code_TTT_1AP_2AD

Competing interests

The authors declare that they have no conflict of interest.

The authors

Alejandro Campos-Murguía¹, Luis Eduardo Zamora-Nava²

- 1 Department of Gastroenterology, Instituto Nacional de Ciencias Médicas y Nutrición Salvador Zubirán, Mexico City, Mexico
- 2 Department of Gastrointestinal Endoscopy, Instituto Nacional de Ciencias Médicas y Nutrición Salvador Zubirán, Mexico City, Mexico

Corresponding author

Dr. Luis Eduardo Zamora-Nava, MD

Department of Gastrointestinal Endoscopy, Instituto Nacional de Ciencias Médicas y Nutrición Salvador Zubirán, Vasco de Quiroga 15, Belisario Domínguez Secc 16, Tlalpan, 14080 Mexico City, Mexico
luiseduardozn@gmail.com

References

- [1] Jin XL, Wang ZH, Xiao XB et al. Blue rubber bleb nevus syndrome: a case report and literature review. *World J Gastroenterol* 2014; 20: 17254–17259
- [2] Dwivedi M, Misra SP. Blue rubber bleb nevus syndrome causing upper GI hemorrhage: a novel management approach and review. *Gastrointest Endosc* 2002; 55: 943–946
- [3] Mavrogenis G, Coumaros D, Tzilves D et al. Cyanoacrylate glue in the management of blue rubber bleb nevus syndrome. *Endoscopy* 2011; 43: 291–292
- [4] Jin J, Pan J, Zhu L. Therapy for hemangiomas of blue rubber bleb nevus syndrome in the small intestine with single balloon endoscopy. *Dig Endosc* 2015; 27: 780
- [5] Chen W, Chen H, Shan G et al. Blue rubber bleb nevus syndrome: our experience and new endoscopic management. *Medicine (Baltimore)* 2017; 96: 7792

Bibliography

Endoscopy 2021; 53: E338–E339

DOI 10.1055/a-1287-8987

ISSN 0013-726X

published online 11.11.2020

© 2020. Thieme. All rights reserved.

Georg Thieme Verlag KG, Rüdigerstraße 14, 70469 Stuttgart, Germany

ENDOSCOPY E-VIDEOS

<https://eref.thieme.de/e-videos>



Endoscopy E-Videos is a free access online section, reporting on interesting cases and new techniques in gastroenterological endoscopy. All papers include a high quality video and all contributions are freely accessible online.

This section has its own submission website at

<https://mc.manuscriptcentral.com/e-videos>