

# Magnet-assisted endoscopic diverticulotomy for an esophageal diverticulum after anterior cervical spine surgery: First case report




## Authors

Flavio Hiroshi Ananias Morita<sup>1</sup>, Helio Bergantini Neto<sup>2</sup>, Paulo Sakai<sup>3</sup>, Gilberto Borges Brito<sup>4</sup>, Shinhiti Morita<sup>4</sup>

## Institutions

- 1 Medicine School of Sao Jose do Rio Preto, General Surgery Department
- 2 Medicine School of Sao Jose do Rio Preto, Academic
- 3 Sao Paulo University Faculty of Medicine, GI Endoscopy Unit, Sao Paulo, Brazil
- 4 Medicine School of Sao Jose do Rio Preto, General Surgery Department

submitted 24.9.2020

accepted after revision 7.12.2020

## Bibliography

Endosc Int Open 2021; 09: E824–E827

DOI 10.1055/a-1339-0953

ISSN 2364-3722

© 2021. The Author(s).

This is an open access article published by Thieme under the terms of the Creative Commons Attribution-NonDerivative-NonCommercial License, permitting copying and reproduction so long as the original work is given appropriate credit. Contents may not be used for commercial purposes, or adapted, remixed, transformed or built upon. (<https://creativecommons.org/licenses/by-nc-nd/4.0/>)

Georg Thieme Verlag KG, Rüdigerstraße 14,  
70469 Stuttgart, Germany

## Corresponding author

Flavio Hiroshi Ananias Morita, Medicine School of Sao Jose do Rio Preto, General Surgery Department, Las Vegas Street 444, São José do Rio Preto, São Paulo, Brazil 15093-010

Fax: +551732015000

flaviomorita@hotmail.com

## Introduction

The anterior approach to the cervical spine is used in surgical treatment of several diseases in this region. As a late complication, a true traction diverticulum can be formed in the pharyngo-esophageal region [1]. First described by Goffart et al. in 1991, this complication is rare, and is most frequently associated with C5-C6 involvement [2].

Among the various etiologies, this diverticulum is mostly likely caused by inflammation with scar retraction of the surrounding tissues, which is inherent in surgical manipulation itself; this exerts traction on the wall of the pharynx and esophagus, leading to its formation. Others causes, including possible accidental injury of the pharynx and esophagus during the procedure and compression and friction of the posterior wall of the pharynx and esophagus by the plate and screws, among others, also have been discussed [3–5]. The main symptoms are dysphagia, weight loss, regurgitation, and halitosis and others symptoms associated with aspiration or perforation, such as fever, cough, odynophagia, and breathlessness [1, 5].

There is no study in the literature that compares the various treatment modalities for pharyngo-esophageal diverticulum after an anterior approach to the cervical spine. In most of the cases reported, conventional surgery was performed and was very effective [6, 7]. There are few published cases on endo-

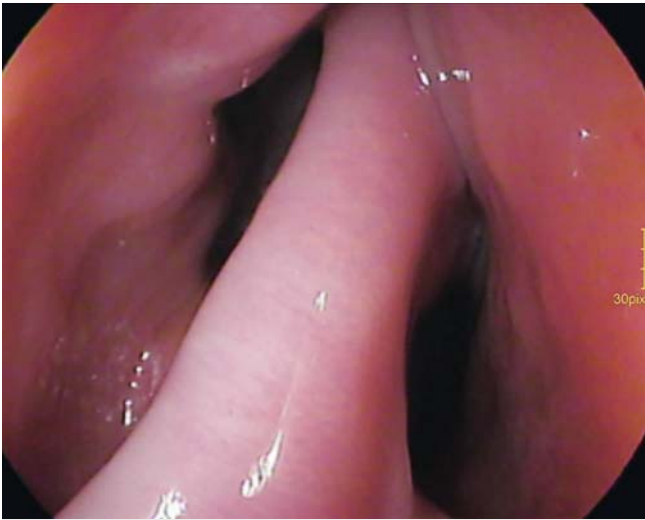
scopic treatment of this diverticulum. The techniques that have been used were septal stapling [1, 5] and conventional septotomy [1]; no report using magnets was found in our review.

Magnetic compression has been used in the digestive tract to create solid anastomotic connections. Regarding the procedure, two magnets are positioned to carry the apposition of two structures, which as a result of the pressure exerted on their walls, creates an inflammatory process, leading to adherence between them, followed by necrosis and consequent communication. Several diseases have been treated using this principle [8–10].

The objective of this paper was to report the first case of esophageal diverticulum post-anterior cervical spine surgery treated by endoscopy using magnets and septotomy.

## Patients and methods

This case involved a 51-year-old male patient with a 21-year history of raquimedular trauma with C6 and C7 fractures who was referred for surgical fixation with plates and screws after presenting with paraplegia and hoarseness. He had been well until 1 year before, when he began to have swallowing difficulties associated with regurgitation and halitosis, with progres-



► **Fig. 1** Upper digestive endoscopy showing septum and diverticular ostium 2 cm below the cricopharyngeal muscle.

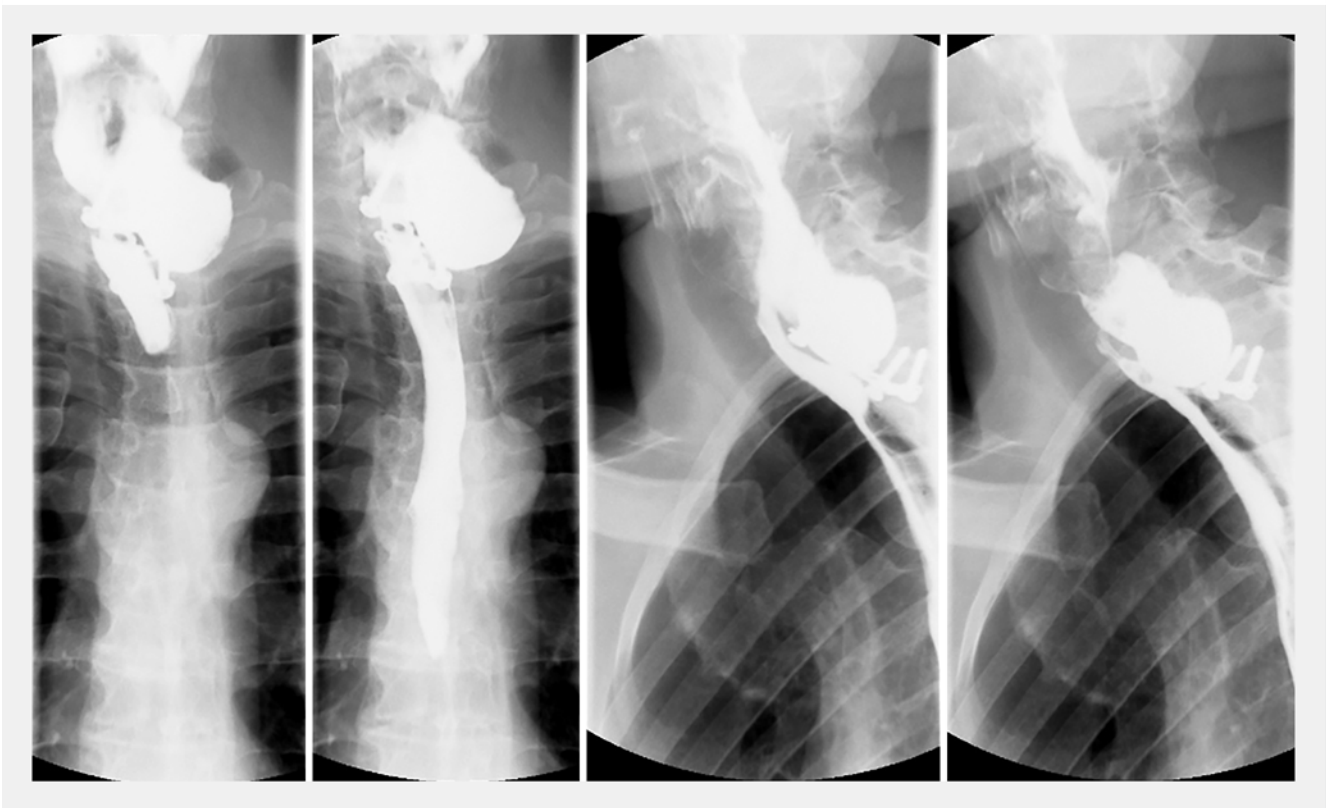
sive worsening of the symptoms. He reported a 12-kg weight loss in the last 6 months.

On physical examination, the patient presented with a right cervical scar and medium paralysis of the unilateral vocal fold. On upper digestive endoscopy and contrast-enhanced examination of the esophagus, a diverticulum measuring 7 cm was


observed, located on the left posterolateral wall with a septum 2 cm below the cricopharyngeal muscle (► **Fig. 1** and ► **Fig. 2**).

Treatment was performed using two circular neodymium magnets, 1.5 cm in diameter and 3 mm thick, with 7 mm fenestrae in their centers. One magnet was placed in the esophagus and the other at the bottom of the diverticulum. Two nasogastric probes were used to place the magnets, through which a wire loop bearing the magnets was passed through their fenestrae (► **Fig. 3**). With the aid of radioscopy and direct endoscopic vision, one magnet was first placed in the stomach and the other in the bottom of the diverticulum, guided by the nasogastric probe. Afterwards, the stomach magnet was pulled through the esophageal lumen until it was attracted by the magnet at the bottom of the diverticulum. Careful removal of the nasogastric probe and wire was performed by pulling one of its legs.

The patient underwent the procedure as an outpatient. He reported that he experienced intense local discomfort the first week. Three weeks after the initial procedure, we performed an endoscopic review and a diverticulous-esophageal fistula measuring approximately 8 mm in diameter was observed at the bottom of the diverticulum. At that time, we had chose to section the remaining septum above the fistula. For the procedure, a diverticulotome was used, which was partially fixed due to deviation from the rotational axis of the diverticulum. Initially, to avoid bleeding and possible perforation, we chose to place a clip on each side of the septum and cut between them. However, due to the thickness of the septum, the clips were sponta-



► **Fig. 2** Barium esophagography revealing a 7-cm diverticulum in the cervical esophagus.

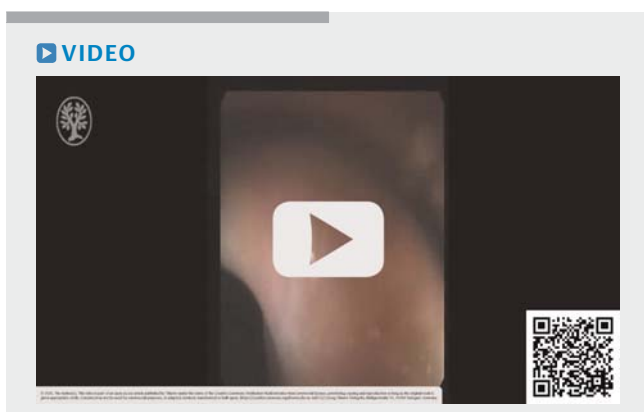


► **Fig. 3** Fenestrated magnet attached to the probe by loop wire.

neously released. The septum was then sectioned by layers until the remaining septum above the fistula was completely separated (► **Video 1**). The patient's progress was favorable with no complications, and he has remained asymptomatic for 6 months.

## Discussion

Diverticula in the region of the pharynx and esophagus are formed by abnormal forces, either of pulse or traction. Those due to traction are formed due to traction placed on pharynx and esophagus by external forces [7] as a result of a local inflammatory process, with consequential scar retraction. This inflammation can be triggered by surgical manipulation of sur-



► **Video 1** Upper gastrointestinal endoscopy showing the presence of a diverticulous-esophageal fistula and the septum sectioned by layers, until the complete separation. Note the clips were spontaneously released.

rounding tissues [1], local infection, or even by friction from displaced or loose plates and screws in the cervical spine [2].

Reports of similar cases are found in the literature and were classified by the authors as Zenker's diverticulum [2, 4, 11]. Considering the physiopathology of Zenker's diverticulum, we believe that this diverticulum cannot be classified as such. This difference is important because in an attempt to perform an endoscopic diverticulotomy, the absence of the hypertonic cricopharyngeal muscle and/or the uncoordinated contractions during swallowing would increase the risk of perforation and simple sectioning of the local musculature without a complete septotomy would not improve the symptoms.

Like the endoscopic treatments used for middle and distal esophageal diverticula, to perform an endoscopic diverticulotomy, the "clip and cut" method should be used, aiming at greater extension of the diverticulotomy without perforation. However, even with this method, complete marsupialization of the diverticulum can hardly be achieved [9]. In addition, as we have seen in our case, due to the significant overall thickness of the diverticulum walls as well as the esophagus, conventional clips would not be effective in keeping them attached.

Septotomy using a stapler appears to be effective in theory, but several technical difficulties are observed in practice. Among them are the lack of mobility of the cervical spine and the small opening of the mouth, which can make it difficult or even impossible to place the stapler. In a series of seven cases published by Rippentropp et al., in three patients (42.9%), endoscopic treatment was not possible due to such difficulties. In addition, clamping failure may occur due to the thickness and hardness of the tissue.

Compared with conventional surgery, endoscopic treatments for a diverticulum in the pharynx and proximal esophagus require less time for the procedure and hospitalization and allowing for an earlier return to an oral diet [5, 9]. In cases of post-anterior approaches to the cervical spine, the endoluminal approach also avoids the difficulty of access to the diverticulum in conventional surgery. This difficulty occurs due to the presence of adhesions resulting from previous surgical manipulation [3]. In this context, an increasing risk of inadvertent injury of other structures is expected, such as recurrent injury to the laryngeal nerve. In the present case, the patient showed signs of unilateral injury of this nerve, manifested by hoarseness and unilateral paralysis of the vocal fold. Injury of the contralateral nerve could result in great morbidity, such as the need for definitive tracheostomy by bilateral paralysis of the vocal folds.

Diverticulotomy using magnets has some advantages over conventional endoscopic diverticulotomy. It allows the performance of a complete septotomy in a simple and safe way, even for large or recidivated diverticula, after a conventional endoscopic diverticulotomy [8, 11]. Regarding diverticulotomy with a stapler, the technique using magnets does not depend on cervical mobility or a large mouth opening, making the technique more feasible.

In our patient, due to the large size of the diverticulum, the diverticulous-esophageal fistula was not sufficient to make the patient asymptomatic; therefore, complementary therapy was necessary. For such a case, another session of magnetic or

endoscopic septotomy could be performed. We believe that endoscopic septotomy to complement magnetic diverticulotomy is safe because the inflammation caused by magnetic compression would lead to an adhesion between the wall of the esophagus and the diverticulum, avoiding perforation during the procedure. However, it should be performed with caution because there are no studies on this.

The disadvantages of endoscopic treatment are as follows. It does not allow the removal of the plate and screws. In addition, in patients who already have a fistula and an infection of the surrounding tissues [6], the endoscopic pathway may not allow for adequate debridement to control and resolve the infection. We believe that in the absence of fistula or a local infection, when the plate and screws are not displaced or loose, their removal is not imperative. Once they are located and attached, their presence should not cause additional stress to the diverticulum in relation to the spine itself, but further studies are needed to define the best treatment in these cases.

## Conclusion

We have reported the first case of postsurgical treatment of esophageal diverticulum with an anterior approach to the cervical spine using endoscopy with magnets and septotomy. This limited experience combined with a review of the literature suggests that magnetic anastomosis followed by septotomy is an effective and safe technique. We have demonstrated in detail a low-cost and affordable way to place the magnets.

## Competing interests

The authors declare that they have no conflict of interest.

## References

- [1] Rippentropp SM, Miller FR. Hypopharyngeal diverticulum after cervical spine surgery; the role of endoscopic management. *Am J Otolaryngol* 2013; 34: 216–218
- [2] Dobran M, Gladi M, Mancini F et al. Rare case of anterior cervical discectomy and fusion complication in a patient with Zenker's diverticulum. *BMJ Case Rep* 2018; 11: e226022
- [3] Sadrizadeh A, Soltani E, Abili M et al. Delayed esophageal pseudodiverticulum after anterior cervical spine fixation: report of 2 cases. *Iran J Otorhinolaryngology* 2015; 27: 155–158
- [4] Ünal ZK, Umay E, Gündoğdu İ et al. A rarely seen complication that causes increase in morbidity in tetraplegic patients: Zenker diverticula. *Am J Phys Med Rehabil* 2017; 96: e166–e169
- [5] Al-Khudari S, Succar E, Standring R et al. Delayed failure after endoscopic staple repair of an anterior spine surgery related pharyngeal diverticulum. *Case Rep Med* 2013; 2013: 281547
- [6] Volkow-Fernández P, Islas-Muñoz B, Santillán-Doherty P et al. Successive complications after anterior cervical fixation: pharyngo-esophageal diverticulum, fistulization, and cervical spondylitis by *Streptococcus milleri* - case report and literature review. *J Med Case Rep* 2019; 13: 129
- [7] Goffart Y, Moreau P, Lenelle J et al. Traction diverticulum of the hypopharynx following anterior cervical spine surgery. *Case report and review. Ann Otol Rhinol Laryngol* 1991; 100: 852–855
- [8] Ye L, Zeng H, Wang S et al. Magnet-assisted diverticuloplasty for treatment of Zenker's diverticulum. *Endoscopy* 2018; 50: E170–E171
- [9] Bouchard S, Huberty V, Blero D et al. Magnetic compression for treatment of large oesophageal diverticula: a new endoscopic approach for a risky surgical disease? *Gut* 2015; 64: 1678–1679
- [10] Bouchard S, Huberty V, Blero D et al. Endoscopic treatment of large esophageal diverticula using a magnetic anastomosis device: report of three cases. *Gastrointest Endosc* 2015; 81
- [11] Bhargav PR, Kumar CH, Kumar AV et al. A unusual case of complicated Zenker's diverticulum. *Indian J Surg* 2013; 75: 30–32