

Salvage, reloading, and deployment of a metal biliary stent using an improvised delivery catheter

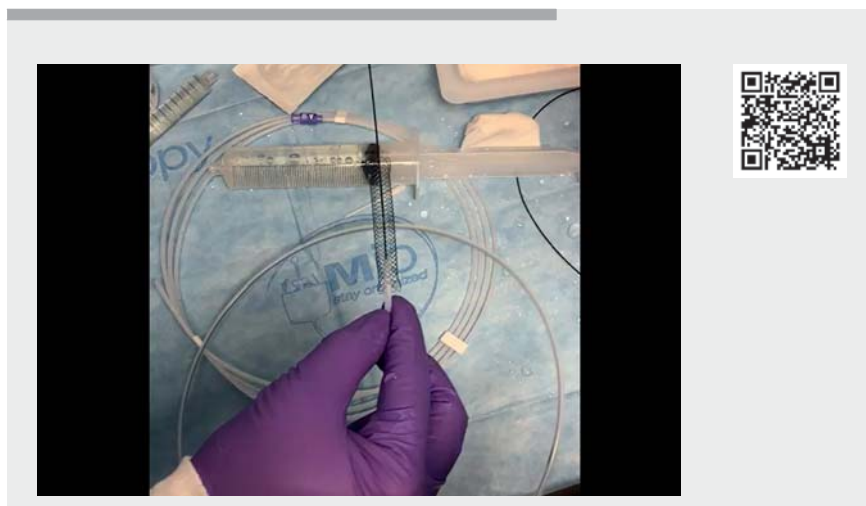
A 55-year-old man with known pancreatic adenocarcinoma presented for an outpatient biliary stent change. Two previously placed plastic stents were removed. Endoscopic retrograde cholangiography showed a moderate-grade 2.5-cm biliary stricture with upstream biliary dilation. A 10-mm × 60-mm transpapillary uncovered metal stent (Wallflex Biliary RX; Boston Scientific, Marlborough, Massachusetts, USA) was placed across the stricture into the common hepatic duct but ended up more proximal in the duct. Attempts to reposition the stent to allow for stent foreshortening after expansion resulted in inadvertent partial dislodgment into the duodenal lumen.

By this time the stent delivery catheter had been discarded. In order to avoid the cost associated with a new metal stent, we decided to salvage this stent using an improvised stent delivery system (► **Video 1**).

The dislodged biliary stent was removed from the patient. A 0.035-inch angled Glidewire (Terumo Corporation, Tokyo, Japan) was passed through a 10-Fr pushing catheter (Cook Medical Inc., Bloomington, Indiana, USA). The biliary stent was placed over the guidewire, and the stent was then manually compressed and inserted into the distal portion of the 10-Fr pushing catheter.

Subsequently, the bile duct was cannulated using this catheter with the preloaded stent, and the Glidewire was advanced into the bile duct. The stent-containing portion of the catheter was adequately positioned across the stricture under fluoroscopic guidance.

Next a 7-Fr pushing catheter (Cook Medical Inc.) was passed over the guidewire into the 10-Fr catheter to act as a pusher. The stent was redeployed by pulling back the 10-Fr catheter while simultaneously



► Video 1 Video demonstrating the salvage, reloading, and deployment of a malpositioned metal biliary stent using an improvised stent delivery system.

pushing the 7-Fr catheter forward to push out and deploy the stent. The stent was deployed in an adequate position and the catheters and guidewire were removed.

Although unorthodox, this method helped to salvage a malpositioned stent that would have been wasted, resulting in unnecessary healthcare cost.

Endoscopy_UCTN_Code_CPL_1AK_2AD

Competing interests

TR is a consultant for Boston Scientific Inc.

The authors

Zain A. Sobani , **Tarun Rustagi**

Division of Gastroenterology and Hepatology, University of New Mexico, Albuquerque, New Mexico, USA

Corresponding author

Tarun Rustagi, MD

Division of Gastroenterology and Hepatology, University of New Mexico School of Medicine, 1 University of New Mexico, MSC10-5550, Albuquerque, NM 87131, USA
Fax: +1-505-272-6839
tarunrustagi06@gmail.com

Bibliography

Endoscopy 2022; 54: E46
DOI 10.1055/a-1376-5964
ISSN 0013-726X
published online 5.3.2021
© 2021. Thieme. All rights reserved.
Georg Thieme Verlag KG, Rüdigerstraße 14, 70469 Stuttgart, Germany