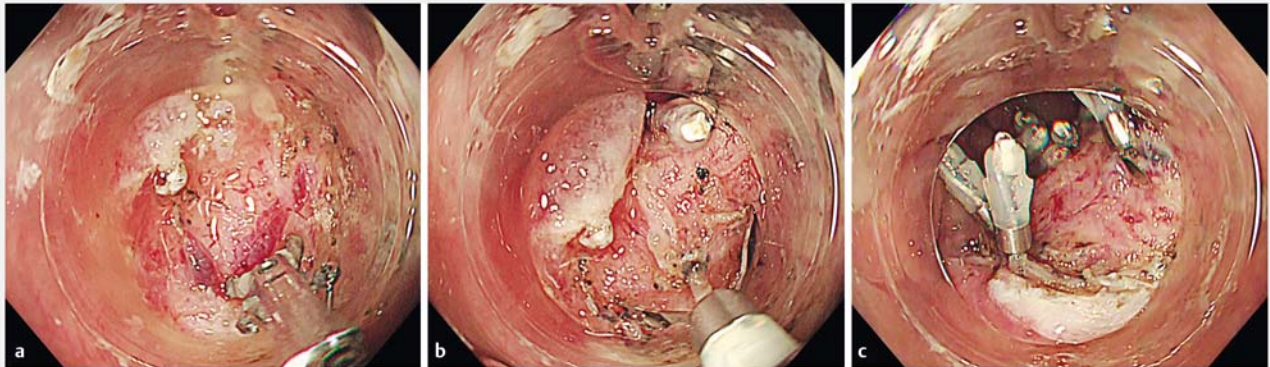


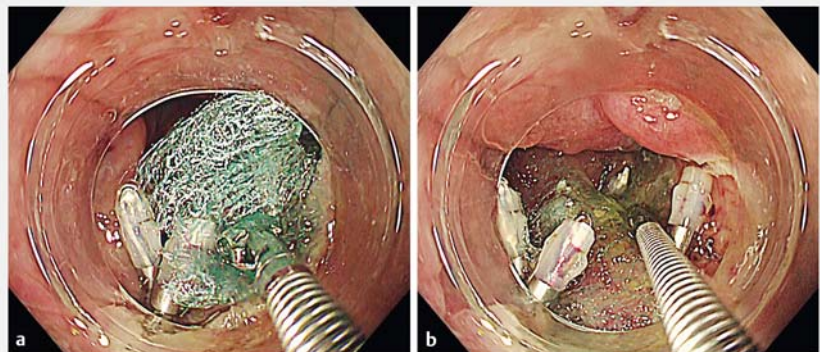
## Modified search, coagulation, and clipping with polyglycolic acid sheet and fibrin glue to reduce delayed bleeding risk after endoscopic submucosal dissection near the dentate line



► **Fig. 1** Endoscopic images of the modified search, coagulation, and clipping (MSCC) method for the prevention of delayed bleeding after colorectal endoscopic submucosal dissection near the dentate line showing: **a** coagulation being performed after lesion resection, particularly for vessels at the margin of the ulcer base near the dentate line; **b** perforator vessels emerging between muscle layers being identified and clipped using hemoclips, along with clipping in carbonized areas of the ulcer base where perforator vessels may also be present, this being the MSCC approach; **c** the appearance on completion of the procedure.

A randomized trial of patients with large nonpedunculated colorectal lesions undergoing endoscopic resection showed that clip closure of mucosal defects in patients with a risk of bleeding could reduce delayed bleeding [1]. However, empirically, lesions near the dentate line are considered to display less wall mobility, and endoscopic ligation is difficult. In post-gastric endoscopic submucosal dissection (ESD) ulcers, which are similarly difficult to close by endoscopic ligation, we have used a modified search, coagulation, and clipping (MSCC) method using polyglycolic acid sheets (PGA) and fibrin glue (PMSCC) for patients at high risk of delayed bleeding [2], and reported good results with no delayed bleeding among nine patients [3]. We therefore devised a new strategy using PMSCC for patients at high risk of delayed bleeding after colorectal ESD near the dentate line.

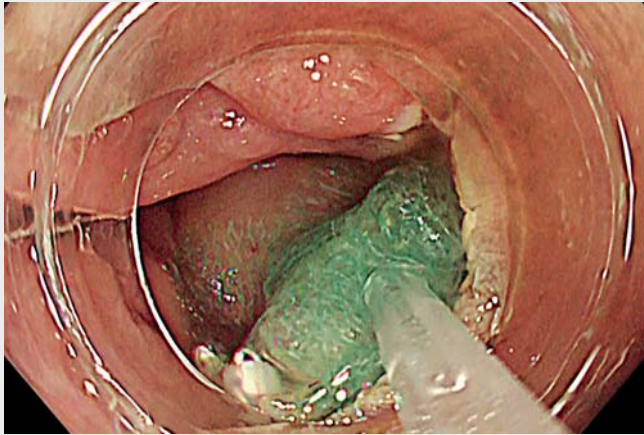
A coagulation procedure was performed after lesion resection, mainly for the vessels at the margin of the ulcer base near the dentate line. Perforators emerging between the muscle layers were identi-



► **Fig. 2** Endoscopic images showing small polyglycolic acid sheets (2 × 1 cm) being placed using forceps after the modified search, coagulation, and clipping method had been performed to prevent delayed bleeding after colorectal endoscopic submucosal dissection near the dentate line.

fied and clipped using hemoclips. Because perforators may also be present in carbonized areas of the ulcer base, clipping was also performed in such areas, constituting the MSCC method (► **Fig. 1**). Several small PGA sheets were then placed (based on the size of the ulcer base) using the method proposed by Takimoto et al. [4] (► **Fig. 2**). Finally, fibrin

glue was sprayed. These steps constitute the PMSCC method for patients at high risk of delayed bleeding after colorectal ESD near the dentate line. ► **Video 1** shows the method being used in an 80-year-old man with a high risk of delayed bleeding because of oral administration of direct oral anticoagulants.



**Video 1** The polyglycolic acid sheet, fibrin glue, and modified search, coagulation, and clipping (PMSCC) method for prevention of delayed bleeding in a high risk patient after colorectal endoscopic submucosal dissection near the dentate line.

Use of the PMSCC method may prevent post-ESD bleeding in patients at high risk of delayed bleeding after colorectal ESD near the dentate line.

Endoscopy\_UCTN\_Code\_TTT\_1AQ\_2AZ

### Acknowledgments

We express our deep gratitude to Soichiro Oda, Akimitsu Meno, Akane Shido, and Sonoe Yoshida in the Department of Gastroenterology at Kushiro Rosai Hospital and Risako Kohya, Masayuki Higashino, Kazuharu Suzuki, Ryo Sugiura, Shuichi Miyamoto, Kenji Kinoshita, Kazuteru Hatanaka, Yoshiya Yamamoto, and Hirohito Naruse in the Department of Gastroenterology, Hakodate Municipal Hospital for their kind support and advice. We are very grateful to the wonderful staff in the endoscopic room and ward of Kushiro Rosai Hospital and Hakodate Municipal Hospital.

### Competing interests

The authors declare that they have no conflict of interest.

### The authors

**Satoshi Abiko**<sup>1,2</sup>, **Ayumu Yoshikawa**<sup>1</sup>, **Kazuaki Harada**<sup>1</sup>, **Naoki Kawagishi**<sup>1</sup>, **Itsuki Sano**<sup>1</sup>, **Hisashi Oda**<sup>1</sup>, **Takuto Miyagishima**<sup>1</sup>

- 1 Department of Gastroenterology, Kushiro Rosai Hospital, Kushiro, Japan
- 2 Department of Gastroenterology and Hepatology, Hakodate Municipal Hospital, Hakodate, Japan

### Corresponding author

**Satoshi Abiko, MD, PhD**

Department of Gastroenterology and Hepatology, Hakodate Municipal Hospital, 1-10-1, Minato-cho, Hakodate, 041-8680, Japan  
abiko1982@gmail.com

### References

- [1] Albéniz E, Álvarez MA, Espinós JC et al. Clip closure after resection of large colorectal lesions with substantial risk of bleeding. *Gastroenterology* 2019; 157: 1213–1221
- [2] Abiko S, Yoshikawa A, Harada K et al. Combination of search, coagulation, clipping, and polyglycolic acid sheet to prevent delayed bleeding after gastric endoscopic submucosal dissection. *Endoscopy* 2020; 52: E344–E345
- [3] Abiko S, Oda S, Meno A et al. Feasibility of a modified search, coagulation, and clipping method with and without the use of polyglycolic acid sheets and fibrin glue for preventing delayed bleeding after gastric endoscopic submucosal dissection. *BMC Gastroenterol* 2021; 21: 63
- [4] Takimoto K, Toyonaga T, Matsuyama K. Endoscopic tissue shielding to prevent delayed perforation associated with endoscopic submucosal dissection for duodenal neoplasms. *Endoscopy* 2012; 44: E414–E415

### Bibliography

*Endoscopy* 2022; 54: E125–E126

DOI 10.1055/a-1422-2510

ISSN 0013-726X

published online 16.4.2021

© 2021. Thieme. All rights reserved.

Georg Thieme Verlag KG, Rüdigerstraße 14, 70469 Stuttgart, Germany

### ENDOSCOPY E-VIDEOS

<https://eref.thieme.de/e-videos>



*Endoscopy E-Videos* is an open access online section, reporting on interesting cases and new techniques in gastroenterological endoscopy. All papers include a high quality video and all contributions are freely accessible online. Processing charges apply (currently EUR 375), discounts and waivers acc. to HINARI are available.

This section has its own submission website at

<https://mc.manuscriptcentral.com/e-videos>