

# Video clips compared with high-definition still images for characterization of colorectal neoplastic lesions: a randomized comparative prospective study



## Authors

Lucile Héroin<sup>1</sup>, Jérôme Rivory<sup>2</sup>, Thierry Ponchon<sup>2</sup>, Romain Legros<sup>3</sup>, Jérémie Albouys<sup>3</sup>, Stanislas Chaussade<sup>4</sup>, Olivier Gronier<sup>5</sup>, Jean-Marie Reimund<sup>1</sup>, Thibaut Fabacher<sup>6</sup>, Denis Sautereau<sup>3</sup>, Franck Dumeirain<sup>3</sup>, Mathieu Pioche<sup>\*.2</sup>, Jérémie Jacques<sup>\*.3</sup>, and the French Society of Digestive Endoscopy (SFED)

## Institutions

- 1 Department of Gastroenterology, Hôpitaux Universitaires de Strasbourg, Strasbourg, France
- 2 Endoscopy and Gastroenterology Unit, Edouard Herriot Hospital, Hospices Civils de Lyon, Lyon, France
- 3 Gastroenterology and Endoscopy Unit, Dupuytren University Hospital, Limoges, France
- 4 Department of Gastroenterology, Cochin Hospital, Paris, France
- 5 Endoscopy and Gastroenterology Unit, Clinique Sainte Barbe, Groupe Hospitalier Saint-Vincent, Strasbourg, France
- 6 Department of Public Health, Hôpitaux Universitaires de Strasbourg, Strasbourg, France

submitted 17.12.2020

accepted after revision 14.3.2021

## Bibliography

Endosc Int Open 2021; 09: E1255–E1263

DOI 10.1055/a-1487-5628

ISSN 2364-3722

© 2021. The Author(s).

This is an open access article published by Thieme under the terms of the Creative Commons Attribution-NonDerivative-NonCommercial License, permitting copying and reproduction so long as the original work is given appropriate credit. Contents may not be used for commercial purposes, or adapted, remixed, transformed or built upon. (<https://creativecommons.org/licenses/by-nc-nd/4.0/>)

Georg Thieme Verlag KG, Rüdigerstraße 14,  
70469 Stuttgart, Germany

## Corresponding author

Lucile Héroin, MD, Gastroenterology and Hepatology,  
University Hospitals Strasbourg, 1 quai Louis Pasteur,  
Strasbourg 67000, France  
Fax: +33-3-88116768  
lucileheroin@gmail.com

## ABSTRACT

**Background and study aims** Accurate real-time characterization of colorectal neoplastic lesions (CNLs) during colonoscopy is important for deciding appropriate treatment. No studies have evaluated whether still images or video clips are better for characterization. We compared histological predictions and size estimations of CNLs between two groups of gastroenterologists: one viewing still images and the other viewing video clips.

**Materials and methods** Participants were shown 20 CNLs as either 3–5 still images or a video clip. Three endoscopy experts obtained the images using high-definition white light and virtual chromoendoscopy without magnification. Stratified randomization was performed according to experience. For each lesion, participants assessed the size and histological subtype according to the CONECCT classification (hyperplastic polyp [IH], sessile serrated lesion [IS], adenoma [IIA], high-risk adenoma or superficial adenocarcinoma [IIC], or deeply invasive adenocarcinoma [III]). The correct histological status and size were defined by the pathology reports or combined criteria between histology and expert opinion for high-risk adenoma or superficial adenocarcinoma (CONECCT IIC).

**Results** 332 participants were randomized and 233 performed the characterization. Participants comprised 118 residents, 75 gastroenterologists, and 40 endoscopy experts; 47.6% were shown still images and 52.4% viewed video clips. There was no statistically significant difference between the two groups in histological prediction, our primary end point. However, the lesion size was better assessed using still images than video clips ( $P=0.03$ ).

**Conclusions** Video clips did not improve the histological prediction of CNLs compared with still images. Size was better assessed using still images.

\* Co-last authors

## Introduction

During colonoscopy, endoscopic characterization of colorectal neoplastic lesions (CNLs) must be done in real time to determine the subsequent resection method. This characterization takes into account histological prediction using various endoscopic classifications and size estimation.

To improve practices, one can now attend characterization courses, but the image support may vary (still images or video clips of varying quality). Video clips are a dynamic support that may improve real-time histological prediction compared with still images. Now that expert advice regarding the best treatment strategy for colorectal superficial lesions is becoming more frequent, it is important to determine whether video clips or still images are better for CNL characterization. If video clips are superior, all endoscopy operating rooms should be equipped with video recorders and data storage software.

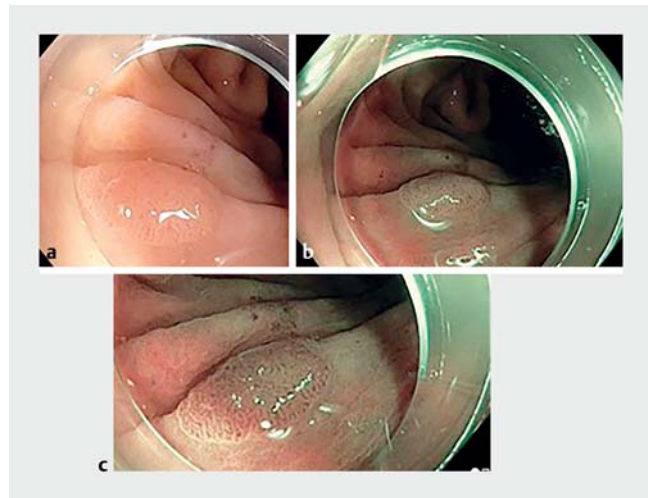
Despite the number of studies on CNL characterization, none has evaluated the best method between video clips and still images. As such, we performed a randomized trial to compare the histological prediction of CNLs between two groups of gastroenterologists: one group characterized CNLs using still images and the other group viewed video clips of the same lesions.

## Materials and methods

### Image characteristics

This was a comparative prospective study involving two groups of gastroenterologists who characterized 20 CNLs. In the still image group (Group A), participants characterized the lesions using 3–5 still images. At least one image was captured using white-light imaging and one image was captured using virtual chromoendoscopy (► **Fig. 1**). There was a transparent hood in every image of lesions larger than 5 mm, as resection was planned; no hood was present in the image for polyps less than 5 mm in size. In the video clip group (Group B), participants characterized the same 20 CNLs from video clip format, which included both white-light imaging and virtual chromoendoscopy. The video clips lasted from 12.7 to 69.6 seconds with a mean of 39.7 seconds. The short video clips were shown twice. The images or video clips for each lesion were displayed for the same time duration, with a total duration of 30 minutes for the whole session for both groups. The number of still images and the duration of the video clip were adapted to the size of the lesion displayed.

Three endoscopy experts from two academic centers (Lyon and Limoges) provided the images in high-definition white light and virtual chromoendoscopy (narrow-band imaging or blue-light imaging) without optical zoom. The images were recorded with Olympus CF-HQ190L/I (Olympus, Tokyo, Japan) and Fujinon EC-760R (Fujifilm, Tokyo, Japan) colonoscopes. Images of areas with endoscopic features of concern were provided to the two groups.



► **Fig. 1** Examples of still images shown to participants. 6 mm sessile adenoma (CONECCT IIA) seen in: **a** white-light imaging; **b** narrow-band imaging; **c** narrow-band imaging with near focus.

### Study design

The study was divided into two parts involving different participants.

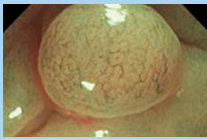


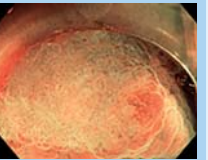

#### Nonexperts

The first part of the study took place from 18–21 June 2019 during an annual national hands-on training course in Limoges, France, organized by the French Society of Digestive Endoscopy (SFED) and the Institut de Formation et de Recherche en Endoscopie Digestive. The participants comprised 276 residents and gastroenterologists from community and academic practice.

Participants were randomized 1:1 into the two groups and were stratified based on their experience (resident vs. gastroenterologists in academic or community practice). During a 30-minute supervised test, the participants were instructed to characterize the 20 abovementioned CNLs using either still images (Group A) or video clips (Group B). The duration of the test was controlled to 30 minutes in both groups. Participants were not allowed to leave the room, and late participants were not accepted. Participants recorded their predictions on a Google form (Google, Mountain View, California, USA) and validated their answers at the end of the session. If a participant did not own a smart phone or did not feel comfortable completing an online form, they received a paper form that was identical in presentation to the Google form.

#### Experts

The second part of the study was conducted from July to September 2019 after selecting a group of 56 French endoscopy experts who were recognized for their optical diagnosis and endoscopic resection skills. They had not participated in the first part of the study as trainers. After stratification based on their experience, the experts were randomized 1:1 into the two groups. They participated in the test individually without supervision. They downloaded a PowerPoint presentation (Mi-

CONECCT	IH Hyperplastic polyp	IS Sessile serrated lesion	IIA Adenoma	IIC High-risk adenoma or superficial adenocarcinoma	III Deeply invasive adenocarcinoma
Macroscopic aspect	Often small <10 mm Paris IIa	Paris IIa or IIb Cloud aspect Unclear margins	Paris Ip, Is or IIa Rarely depressed	Often IIC or IIa + IIC Or nongranular LST Or presence of a macronodule (>10 mm) on a granular LST	Often III or IIC with a nodule in a depressed area <b>Spontaneous bleeding</b>
Color (virtual chromoendoscopy)	Light color or equivalent to the background	Variable Yellow mucus (red in NBI)	Darker than the background	Often dark	Heterogeneous, lighter or darker in an amorphous area
Vessel pattern (virtual chromoendoscopy)	None Or thin vessels across the lesion, not following the pits	Sometimes absent Dark spots at the bottom of the pits	<b>Regular</b> Following the elongated pits	<b>Irregular</b> but persistent No avascular region	Irregular, large interrupted vessels or avascular areas
Pits (virtual chromoendoscopy)	Round shape, whitish pits	Round shape Dark dots (NBI)	Elongated or branched crypts, cerebriform aspect	<b>Irregular but persistent</b> No amorphous area	<b>Absent, amorphous, destroyed</b> or irregular (clear demarcation)
Resection method	No resection 	<b>EN BLOC R0 if possible but piecemeal ok</b> 		EN BLOC R0 (EMR or ESD if >20 mm) 	Surgery with lymphadenectomy 

► **Fig. 2** The CONECCT Classification. EMR, endoscopic mucosal resection; ESD, endoscopic submucosal dissection; LST, laterally spreading tumor; NBI, narrow-band imaging.

crosoft, Redmond, Washington, USA) that was sent to them by email according to their randomization group. The presentation consisted of still images (Group A) or video clips (Group B) of the same 20 lesions. The duration of the examination could not be controlled. The experts were instructed to complete the same Google form used in the first session and to validate their answers at the end of the session.

### Data collection

The questionnaire comprised three parts. The first part consisted of questions about the participants and their previous experience. The next questions were as follows: What is your age? What city do you come from? What is your experience in endoscopy? Are you a resident, gastroenterologist, or expert? What endoscopic classifications do you use? Then, the participants characterized the histological subtypes of the lesions according to the recently published CONECCT classification (► **Fig. 2**) [1]: hyperplastic polyp (CONECCT IH), sessile serrated lesion (SSL, CONECCT IS), low-risk adenoma (CONECCT IIA), high-risk adenoma or superficial adenocarcinoma (CONECCT

IIC), or deeply invasive adenocarcinoma (CONECCT III). This classification was created using a combination of criteria used in the existing endoscopic classifications by physicians from the research and development committee of the SFED, in order to simplify the characterization process and assess the submucosal invasion risk. The classification has been previously validated during a teaching program, and the inter- and intraobserver validation are currently under review for publication. Characterization of the lesions is based on the macroscopic aspect, the color in virtual chromoendoscopy, vessel pattern, and pit pattern. This classification is useful as it predicts the histology and the most appropriate treatment: no resection for hyperplastic polyps, en bloc or piecemeal resection for SSLs or low-risk adenomas, en bloc endoscopic mucosal resection (EMR) or endoscopic submucosal dissection (ESD) for high-risk adenomas or superficial adenocarcinomas, and surgery with lymphadenectomy for deeply invasive adenocarcinomas.

After characterization, the participants predicted the lesion size (<5, 6–10, 11–20, 21–40, 41–80, or >80 mm). Four lesions from each of the five subgroups were presented for a total of 20

► **Table 1** Characteristics of colorectal neoplastic lesions.

Characteristic	%
Histology subgroup	
▪ Hyperplastic polyp	20
▪ Sessile serrated lesion	20
▪ Low-risk adenoma	20
▪ High-risk adenoma or superficial adenocarcinoma	20
▪ Deeply invasive adenocarcinoma	20
Size, mm	
▪ <5	25
▪ 6–10	15
▪ 11–20	25
▪ 21–40	25
▪ 41–80	10
▪ >80	0
Location	
▪ Ascending colon	50
▪ Transverse colon	5
▪ Descending colon	5
▪ Rectum	20
▪ Unknown	20
Morphology	
▪ Sessile	40
▪ Pedunculated	0
▪ Superficial elevated	10
▪ Superficial flat	5
▪ Superficial depressed	5
▪ Ulcerated	5
▪ Granular laterally spreading tumor	15
▪ Nongranular laterally spreading tumor	20
Virtual chromoendoscopy	
▪ Blue-light imaging	45
▪ Narrow-band imaging	55

lesions (40 responses: 20 for histological features and 20 for size). The characteristics of the CNLs are summarized in ► **Table 1**.

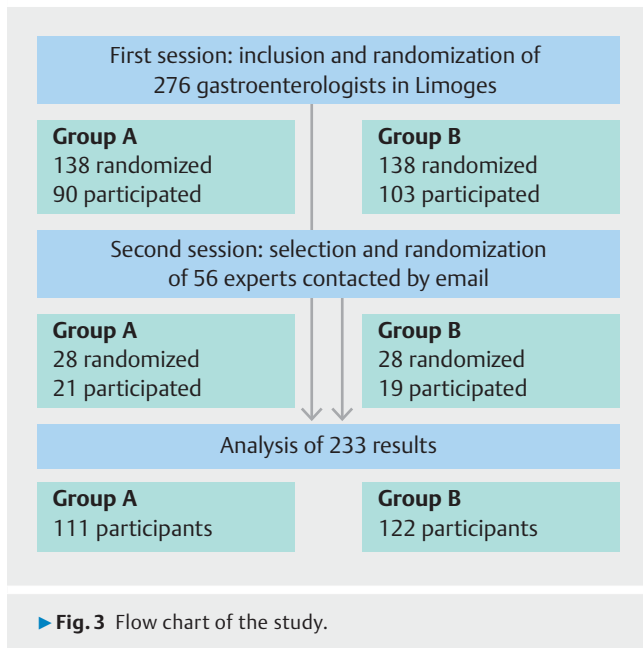
The following subjective questions were asked at the end of the test: Did you like the course? Have you ever attended a characterization course before? Do you think characterization is better assessed using still images or video clips? Those who used the Google form were asked to validate their answers at the end of the session before sending their final responses to the data manager.

## Outcomes

The primary outcome was correct prediction of the CNL histological subtype, which was determined by the pathology reports, using the Japanese classification of superficial colorectal lesions as a gold standard for histology. Two experts in gastrointestinal pathology (one from Lyon and one from Limoges), who were nationally renowned for their expertise, analyzed the specimens. Nevertheless, for high-risk adenomas or superficial adenocarcinoma lesions (CONECCT IIC), we used criteria combining histological and endoscopic features, according to the European Society of Gastrointestinal Endoscopy (ESGE) guidelines [2, 3]; these lesions were defined as either a histologically proven intramucosal adenocarcinoma, an adenocarcinoma with shallow submucosal invasion (<1000 µm), or an adenoma with the endoscopic risk features of adenocarcinomas, such as macroscopic granular laterally spreading tumors (LSTs) with one or more nodules over 1 cm, nongranular flat or pseudodepressed LSTs [4], the presence of a Kudo Vi pit pattern [5], a Sano IIIA [6] or JNET IIB vessel pattern [7], or a depressed area (Paris 0–IIc [8]). There was consensus among the three endoscopy experts regarding the characterization of high-risk adenomas or superficial adenocarcinoma lesions (CONECCT IIC), pictures of which were provided for proper classification. The low-risk adenomas were lacking any of the criteria seen in high-risk adenomas or superficial adenocarcinomas (CONECCT IIC) and in deeply invasive carcinomas (CONECCT III).

Secondary outcomes included correct size prediction, histological and size predictions according to histological subtype, and histological and size predictions according to the experience of the physician (resident, gastroenterologist, or expert). As the low-risk adenomas and high-risk adenomas should both be removed endoscopically, the histological prediction mixing CONECCT IIA and IIC lesions was also compared between the two groups, in the same histological prediction subgroup called CONECCT IIA + IIC. In this analysis, the answer was considered correct if CONECCT IIA or IIC was proposed for a lesion with a final histology of adenoma or superficial adenocarcinoma. Size was also determined by the pathology reports; it was estimated endoscopically in case of piecemeal resections, with consensus among the three endoscopy experts, and compared with pathology reports.

When the histological prediction was incorrect, an additional analysis was performed to determine whether the lesion was overestimated or underestimated compared with the anatomopathological analysis. An adenoma was considered underestimated if predicted to be a hyperplastic polyp and overestimated if predicted to be a high-risk adenoma, superficial adenocarcinoma, or deeply invasive adenocarcinoma. SSLs were overestimated/underestimated in the same way as for adenomas. High-risk adenomas and superficial adenocarcinomas were underestimated if they were classified as hyperplastic polyp, SSL, or adenoma, and overestimated if they were classified as deeply invasive adenocarcinoma.



► **Table 2** Characteristics of the participants.

	Group A <sup>1</sup> (n = 111)	Group B <sup>2</sup> (n = 122)
Status, n (%)		
▪ Resident	60 (54.1)	58 (47.5)
▪ Gastroenterologist	30 (27.0)	45 (36.9)
▪ Expert	21 (18.9)	19 (15.6)
Endoscopy experience in years, n (%)		
▪ 0	0 (0)	1 (0.82)
▪ <5	75 (67.6)	68 (55.7)
▪ 5–9	8 (7.2)	22 (18.0)
▪ 10–14	8 (7.2)	15 (12.3)
▪ 15–20	10 (9.0)	8 (6.6)
▪ >20	10 (9.0)	8 (6.6)
Age, mean, years	33	34

<sup>1</sup> Still images.  
<sup>2</sup> Video clips.

## Statistical analysis

Based on the results of our previous trial regarding characterization [1], we assumed that 60% of the histological predictions would be correct in the still image group. We estimated that the use of video clips would result in an increase in correct histological predictions from 60% to 75%; therefore, it was calculated that 113 participants would be needed per group for a power of 80% and a two-sided alpha of 5%.

For the descriptive analyses, the continuous variables are presented as the mean, median, variance, and minimum and maximum values, and quantitative variables are presented as the frequency and percentage of each modality. Differences between the two groups were determined using Fisher's exact test for the categorical variables and the Mann–Whitney–Wilcoxon test or *t* test, depending on the application conditions, for the quantitative variables. The alpha risk was set to 5%. Statistical analyses were performed using R-3.6 software (R Foundation for Statistical Computing, Vienna, Austria. <https://www.R-project.org/>).

## Results

### Participant characteristics

Of the 276 randomized participants (138 in Group A using still images, and 138 in Group B using video clips), 193 (90 in Group A and 103 in Group B) had complete responses with validation. Of the 56 French endoscopy experts (28 in Group A and 28 in Group B) who were selected and invited, 40 (21 in Group A and 19 in Group B) participated (► **Fig. 3**). Among all 233 participants, comprising 111 (47.6%) in Group A and 122 (52.4%) in Group B, 118 were residents, 75 were gastroenterologists, and 40 were endoscopy experts (► **Table 2**). Of the total forms administered, 90.1% were completed. Groups A and B were homogeneous. Regarding endoscopy experience, 61.4% of the participants (n = 143) had less than 5 years of experience, and

7.7% had more than 20 years of experience (n = 18). The mean age of the participants was 33.7 years.

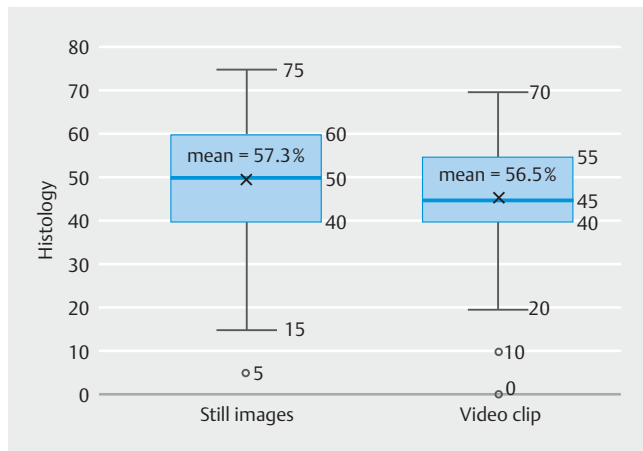
Participants were questioned about their use of published classifications during routine practice: 12.0% of participants did not use any, 28.8% used one, 20.6% used two, 12.9% used three, 12.0% used four, and 13.7% used five or more. The classifications used included: Paris [8] (82.8% of cases), Kudo [5] (37.0%), LST [4] (31.8%), CONECCCT [1] (31.3%), NICE [9] (29.0%), Sano [6] (18.0%), and WASP [10] (8.2%). In total, 58.0% of the participants had already attended a characterization course. In response to the question “Do you think characterization is better assessed using still images or video clips?” 87.0% answered video clips (82.2% of residents, 76.0% of gastroenterologists, and 95.0% of experts).

### Primary end point

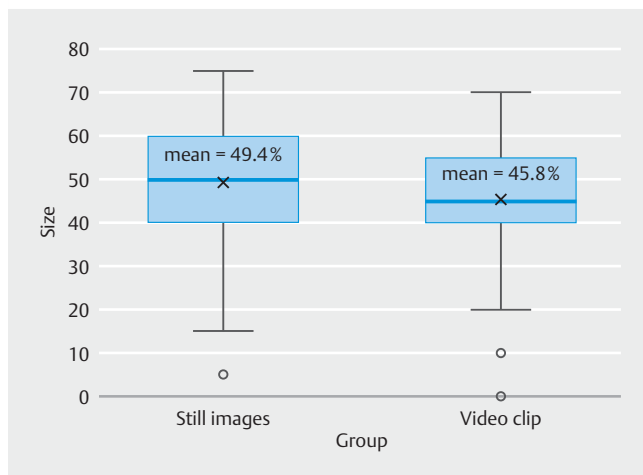
The histological predictions were correct in 57.3% of the still image group assessments and 56.5% of the video clip group assessments. There was no statistically significant difference between the two groups ( $P=0.70$ ) (► **Fig. 4**). Overall, histological predictions were correct in 56.9% of cases.

### Secondary end points

Lesion size was better assessed using still images than using video clips (49.4% vs. 45.8% correct answers;  $P=0.03$ ) (► **Fig. 5**). Overall, size estimation was correct in 47.5% of cases. In the remaining cases, lesion size was underestimated and overestimated in 19.7% and 31.6%, respectively; there was no answer in 1.2%. The histology assessment was most accurate for small (<5 mm) polyps and large (41–81 mm) lesions (74.0% of correct answers for each), then for polyps of 6–10 mm (56.0%). There was no statistically significant difference between the still image and video clip groups.



► Fig. 4 Histological prediction results.



► Fig. 5 Size estimation results.

The percentage of correct answers according to histological type was 81.8% for hyperplastic polyps, 53.4% for SSLs, 46.3% for adenomas, 50.7% for high-risk adenomas or superficial adenocarcinomas, and 52.5% for deeply invasive adenocarcinomas. In the expert group, the percentage of correct answers

was 91.3% for hyperplastic polyps and 75.0% for adenomas (► Table 3). In the gastroenterologist subgroup, the percentage of correct answers was 76.7% for hyperplastic polyps and 46.0% for adenomas. In the resident subgroup, the percentage of correct answers was 86.4% for hyperplastic polyps and 37.1% for adenomas. When mixing CONECCT IIA and IIC lesions in the same histological prediction subgroup, the percentage of correct answers did not differ between still images (65.1%) and video clips (66.4%;  $P=0.51$ ).

Characterization of deeply invasive adenocarcinomas was better using still images (56.3% of correct answers) than using video clips (49.2%;  $P=0.01$ ) (► Fig. 6). There was a strong tendency for better prediction of the histology of adenomas using video clips (50.4% of correct answers) than using still images (42.1%;  $P=0.051$ ).

Hyperplastic polyps were misclassified as an overestimated histological prediction in 18.2% of cases, SSLs in 22.4%, and adenomas in 23.7%. High-risk adenomas and superficial adenocarcinomas were underestimated in 28.3% of cases (to adenomas in 14.4% of cases and SSLs in 12.6% of cases) and overestimated to deeply invasive adenocarcinomas in 21% of cases (► Fig. 7).

## Physician experience

### Status

Regarding gastroenterologist experience, no statistically significant difference was found in histological prediction or lesion size between the residents and experts in Groups A and B. However, gastroenterologists achieved better size estimations using still images (51.2% of correct responses) than using video clips (44.3%;  $P=0.03$ ), but not better histological predictions.

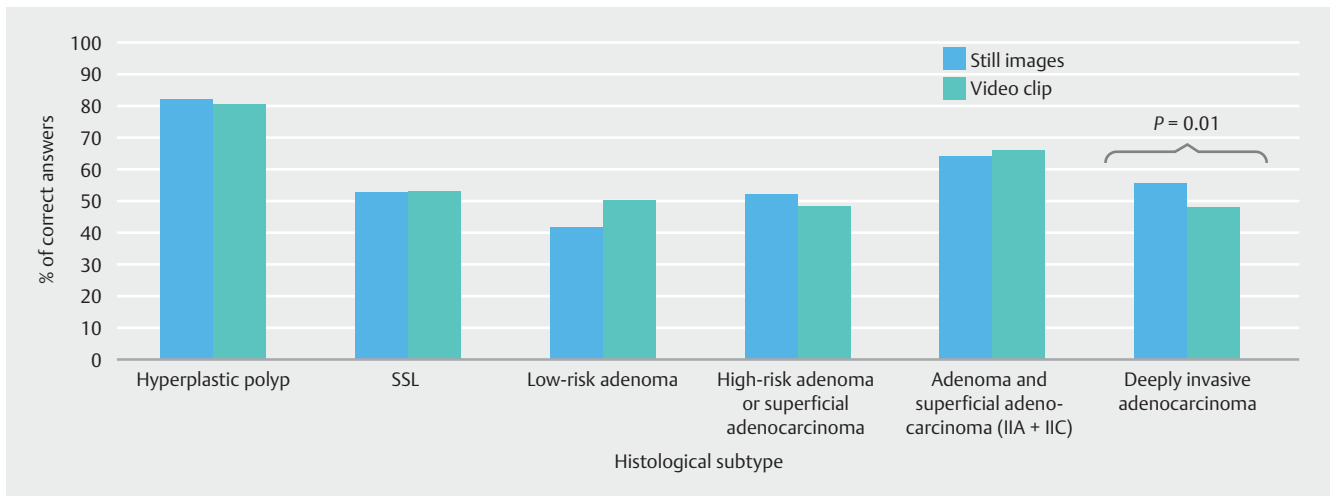
## Discussion

Contrary to our initial assumption and the subjective impression of 87.0% of participants, our results indicated that video clips were not superior to still images for histological prediction of CNLs. In the subgroup of deeply invasive adenocarcinoma, histology prediction was better using still images than using video clips. To explain these results, several assumptions can

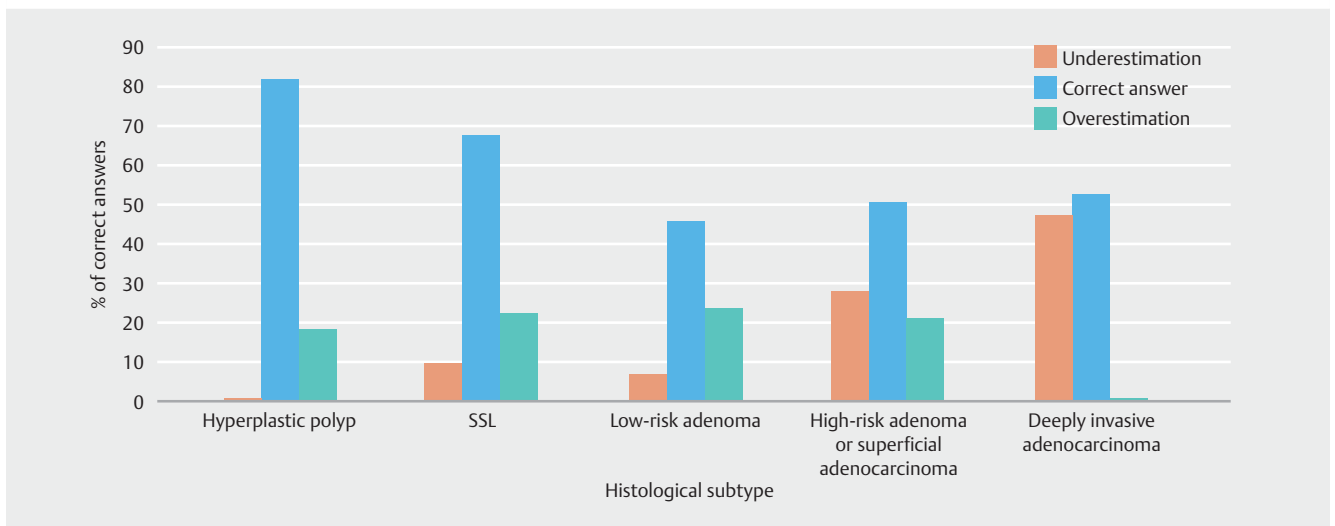
► Table 3 Histological subtype predictions according to participant experience.

Histology	% of correct answers			
	Overall	Experts	Gastroenterologists	Residents
Hyperplastic polyp	81.8	91.3	76.7	86.4
SSL	53.4	86.3	52.0	43.2
Adenoma	46.3	75.0	46.0	37.1
High-risk adenoma or superficial adenocarcinoma	50.7	67.5	48.3	45.7
Deeply invasive adenocarcinoma	52.5	59.4	44.0	55.7
Total	56.9	75.9	53.4	53.6

SSL, sessile serrated lesion.



► **Fig. 6** Group comparison for correct histological predictions regarding histological subtype. SSL, sessile serrated lesion.



► **Fig. 7** Underestimated, correct, and overestimated histological predictions regarding histological subtype. SSL, sessile serrated lesion.

be made. First, endoscopy experts prepared the still images and video clips, and both formats presented endoscopic features of concern when such features existed within a lesion; they were therefore clearly shown. In practice, however, it is the endoscopist who identifies these features after complete analysis of a lesion. This process was easier in the still image group because of the limited number of images. In the video clip group, the endoscopic features of concern had to be observed by the participant during the video clip, even if it was guided by the expert. Second, the participants had more time to evaluate the areas of concern using still images because they remained on the screen for longer compared with video clips, which consisted of approximately 60 images per second. However, the videos selected were of high quality with a longer focus on the areas of concern to minimize this bias. Finally, the limited number of pictures in the still image group could have led to simplification of the histological prediction process for residents and nonexpert academic and community gastroenterologists. This

hypothesis is supported by the statistically significant difference in the prediction of deeply invasive adenocarcinomas, which are lesions containing suspicious areas, but not adenomas or SSLs, which are benign and lack suspicious areas.

Although difficult to realize in clinical practice, a similar study could be conducted using images produced by nonexpert gastroenterologists to assess whether still or dynamic pictures provide better characterization. Such a study might also help to determine whether gastroenterologists who refer CNL patients to expert centers should provide still images or video clips for best prediction of histology and size for determining procedure length.

Another hypothesis is that there may be negative effects of dynamic picture flow compared with still images. Previous studies on vision analysis have found that different image characteristics (color, shape, depth, and movement) are processed by different regions of the brain [11]. The addition of motion, another feature that must be processed by the brain, may im-

pair the ability of the participant to assess the image characteristics. This is worrying in some ways because in clinical practice, gastroenterologists analyze dynamic images rather than still images. The various training studies based on still images may overestimate the characterization capabilities of operators in dynamic clinical situations. If our results are confirmed, video clips should be used for training in endoscopic characterization of CNLs to better replicate clinical practice.

Regarding histological prediction, the baseline level of characterization was low compared with previous studies, including our own [1, 12–14], as only 56.9% of the predictions were correct. This low level may be explained by the large numbers of gastroenterologists in search of training and residents with little experience who participated in the Limoges annual national hands-on training. Another important limitation that could explain the low results is the fact that we decided to show 20 different CNLs (4 of each CONECCCT subgroup), due to the time limitation of the course and the attention of the participants, who had to answer 40 questions. This small sample size may make it more difficult for our results to be extrapolated. In addition, the lack of use of optical zoom can be criticized; however, we decided not to use this function because it is not regularly used in routine screening colonoscopy. In our opinion, a careful examination without optical zoom can accurately estimate the pit and vessel pattern and is more applicable to the daily practice of gastroenterologists. Nevertheless, this is the largest study ever conducted in terms of the number of participants and implies that smaller studies are biased owing to their small numbers of participants.

Emphasis needs to be made on the following points. The prediction of deeply invasive adenocarcinomas was correct in only 52.5% of cases, which is an extremely low rate. This diagnostic accuracy is too low and is lower than in the original CONECCCT study. It may be explained by the fact that deep submucosal invasion features may be small in size or subtle, such as a focal disappearing of the vessel or pit pattern. Such features were present in two deeply invasive adenocarcinomas viewed by participants. Thus, a careful analysis of all CNLs, especially the larger ones, is important for the detection of deep submucosal invasion features. Furthermore, the predictions of hyperplastic polyps and adenomas were correct in 81.8% and less than 50% of cases, respectively. These rates do not permit implementation of the “diagnose and leave” or the “resect and discard” strategies, in which the characterization threshold is set to at least 90% [15, 16]. Additional training actions involving intensive training, either online or in person, with an emphasis on histological characterization and size, are needed to improve these rates.

Our expert definition might seem imprecise but experts who participated in the study were nationally renowned for their expertise in optical diagnosis and endoscopic resection skills. Among them, 75.9% of the histological predictions were correct in the entire cohort. Nevertheless, the ESGE and American Society for Gastrointestinal Endoscopy objectives of a  $\geq 90\%$  rate of correct histological prediction were achieved only by experts and only for hyperplastic polyps (91.3%) and not adenomas (75.0%); residents and gastroenterologists did not achieve

this rate. The three endoscopy experts who selected the CNLs for the study treated mostly patients eligible for advanced endoscopic resection; therefore, the lesions could have been more difficult to characterize than lesions identified in regular colonoscopy practice, which were used in previous studies.

The size estimations were similar to published data and were overestimated in approximately 30% of cases [1, 13, 17]. The best predictions were made for lesions  $< 1$  cm, which are seen most often in practice. The results for lesions 41–80 mm must be handled with caution because there were only two lesions in this size range. It must be mentioned as well that we did not include images in which the tumor and the entire lumen could be observed simultaneously for every lesion, so the field of view may have been too small to properly determine the size of the lesions. Size is critical, as it determines the surveillance interval, the best endoscopic resection procedure, and the success and complications of endoscopic resection procedures such as piecemeal EMR [18] and ESD. It also directly determines the duration of the endoscopic resection procedure, which is important for planning the endoscopy schedule. New tools that accurately predict the size of superficial lesions are urgently needed.

Our results confirm that despite 10 years of training, histological prediction based on endoscopic characterization is difficult, and assistance is needed. More than a third of participants used only the Paris classification during their routine practice, suggesting difficulty with pit and vessel pattern characterization in a real-life setting. Optical zoom could improve the characterization of CNLs, but unfortunately it is not routinely used during screening colonoscopies. Artificial intelligence may be the future for real-time detection and characterization of CNLs. Many methods are being tested, most of which involve computer-aided diagnosis; unfortunately, current investigations involve only retrospective studies of limited quality [19]. Indeed, the lack of real-time randomized prospective trials does not allow definitive approval of artificial intelligence for the detection and characterization of CNLs in daily practice [3]; therefore, training cannot be bypassed for the time being.

To summarize, in this study, the use of video clips did not predict histology more adequately than the use of still images. Surprisingly, still images allowed better prediction of deeply invasive adenocarcinomas and estimation of lesion size. However, current clinical characterization is based on analysis of dynamic colonoscopy pictures rather than still images. Further studies are needed to confirm these results in a more experienced sample of physicians.

### Competing interests

The authors declare that they have no conflict of interest.

### References

- [1] Fabritius M, Gonzalez J-M, Becq A et al. A simplified table using validated diagnostic criteria is effective to improve characterization of colorectal polyps: the CONECCCT teaching program. *Endosc Int Open* 2019; 7: E1197–E1206



- [2] Ferlitsch M, Moss A, Hassan C et al. Colorectal polypectomy and endoscopic mucosal resection (EMR): European Society of Gastrointestinal Endoscopy (ESGE) Clinical Guideline. *Endoscopy* 2017; 49: 270–297
- [3] Bisschops R, East JE, Hassan C et al. Advanced imaging for detection and differentiation of colorectal neoplasia: European Society of Gastrointestinal Endoscopy (ESGE) Guideline – Update 2019. *Endoscopy* 2019; 51: 1155–1179
- [4] Oka S, Tanaka S, Kanao H et al. Therapeutic strategy for colorectal laterally spreading tumor. *Dig Endosc* 2009; 21: (Suppl. 01): S43–46
- [5] Kudo S, Tamura S, Nakajima T et al. Diagnosis of colorectal tumorous lesions by magnifying endoscopy. *Gastrointest Endosc* 1996; 44: 8–14
- [6] Uraoka T, Saito Y, Ikematsu H et al. Sano’s capillary pattern classification for narrow-band imaging of early colorectal lesions. *Dig Endosc* 2011; 23: (Suppl. 01): 112–115
- [7] Sano Y, Tanaka S, Kudo S-E et al. Narrow-band imaging (NBI) magnifying endoscopic classification of colorectal tumors proposed by the Japan NBI Expert Team. *Dig Endosc* 2016; 28: 526–533
- [8] Participants in the Paris Workshop. The Paris endoscopic classification of superficial neoplastic lesions: esophagus, stomach, and colon. *Gastrointest Endosc* 2003; 58: S3–S43
- [9] Hayashi N, Tanaka S, Hewett DG et al. Endoscopic prediction of deep submucosal invasive carcinoma: validation of the narrow-band imaging international colorectal endoscopic (NICE) classification. *Gastrointest Endosc* 2013; 78: 625–632
- [10] IJspeert JEG, Bastiaansen BAJ, van Leerdam ME et al. Development and validation of the WASP classification system for optical diagnosis of adenomas, hyperplastic polyps and sessile serrated adenomas/polyps. *Gut* 2016; 65: 963–970
- [11] Livingstone M, Hubel D. Segregation of form, color, movement, and depth: anatomy, physiology, and perception. *Science* 1988; 240: 740–749
- [12] Rastogi A, Rao DS, Gupta N et al. Impact of a computer-based teaching module on characterization of diminutive colon polyps by using narrow-band imaging by non-experts in academic and community practice: a video-based study. *Gastrointest Endosc* 2014; 79: 390–398
- [13] Kaz AM, Anwar A, O’Neill DR et al. Use of a novel polyp “ruler snare” improves estimation of colon polyp size. *Gastrointest Endosc* 2016; 83: 812–816
- [14] Basford P, Brown J, Cooper S et al. Endoscopic characterization of small colonic polyps: baseline performance of experienced endoscopists is no different to that of medical students. *Endosc Int Open* 2019; 7: E403–E411
- [15] Pimentel-Nunes P, Dinis-Ribeiro M, Ponchon T et al. Endoscopic submucosal dissection: European Society of Gastrointestinal Endoscopy (ESGE) Guideline. *Endoscopy* 2015; 47: 829–854
- [16] Abu Dayyeh BK, Thosani N, Konda V et al. ASGE Technology Committee systematic review and meta-analysis assessing the ASGE PIVI thresholds for adopting real-time endoscopic assessment of the histology of diminutive colorectal polyps. *Gastrointest Endosc* 2015; 81: 502.e1–502.e16
- [17] Chaptini L, Chaaya A, Depalma F et al. Variation in polyp size estimation among endoscopists and impact on surveillance intervals. *Gastrointest Endosc* 2014; 80: 652–659
- [18] Sidhu M, Tate DJ, Desomer L et al. The size, morphology, site, and access score predicts critical outcomes of endoscopic mucosal resection in the colon. *Endoscopy* 2018; 50: 684–692
- [19] Kudo S-E, Misawa M, Mori Y et al. Artificial intelligence-assisted system improves endoscopic identification of colorectal neoplasms. *Clin Gastroenterol Hepatol* 2020; 18: 1874–1881