

Huge pedunculate esophageal submucosal tumor resected under endoscopy with peduncle ligation

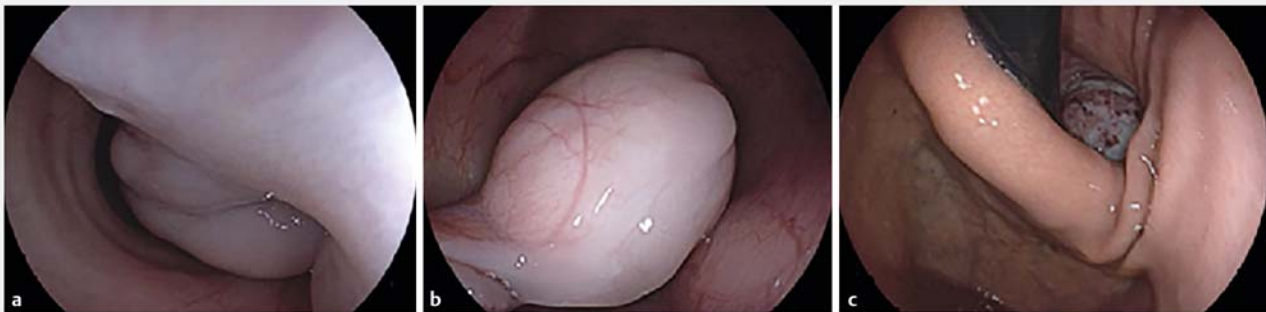Esophageal submucosal tumors can be treated by endoscopic resection [1–3]. However, resection of large submucosal tumors is difficult due to the narrow cavity of the esophagus. Here, we present a case of huge pedunculate esophageal submucosal tumor resected under endoscopy with innovative peduncle ligation.

A 29-year-old man presented with a history of progressive dysphagia for 1 year and moderate fever for 1 week; he was admitted to the hospital. Esophagogastroduodenoscopy showed a huge

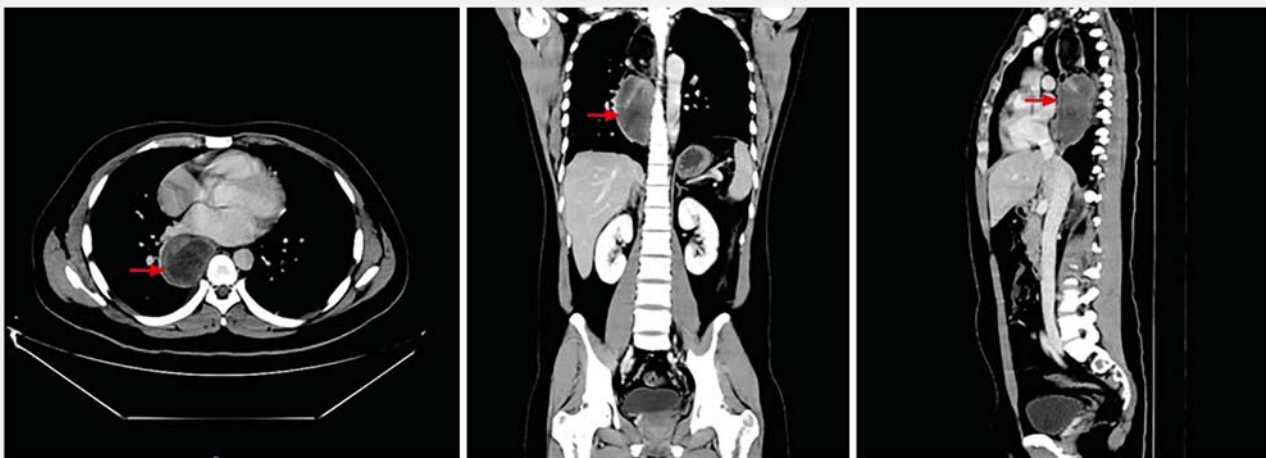pedunculate esophageal submucosal tumor with partial erosion on the surface. The root of the peduncle was located in the anterior wall at 20 cm from the incisors (► Fig. 1). Computed tomography showed a huge intraluminal mass (5.6×4.4×14.7 cm) (► Fig. 2).

After multidisciplinary team discussion, endoscopic resection was considered. A 0 PDS II suture (Johnson & Johnson, New Brunswick, New Jersey, USA) was brought into the esophageal cavity through the gastroscope (Olympus GIF Q260 J; Olympus, Tokyo, Japan) and placed around the

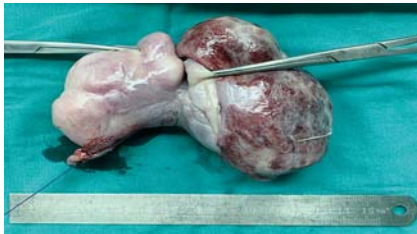peduncle. A knot was tied in vitro and pushed into the esophageal cavity using a laparoscopic knot pusher. The root of the peduncle was ligated by three sutures and then resected using a HookKnife (Olympus) between the ligations. The specimen could not be retrieved through the mouth and was instead pushed into the stomach. The tumor was removed by incision of the stomach through a single-port laparoscope (► Fig. 3, ► Video 1). The patient resumed a liquid diet 3 days after surgery and body temperature returned to normal.



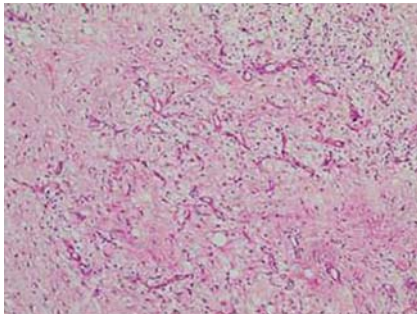
► Fig. 1 Esophagogastroduodenoscopy showed a huge pedunculate submucosal tumor in the esophagus. a The root of the peduncle. b The body of the tumor. c Partial erosion on the surface of the tumor (retroflexed endoscopic view).



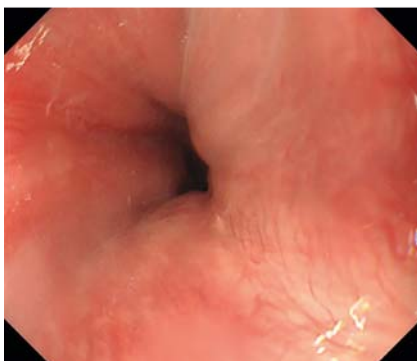
► Fig. 2 Computed tomography scan showed a huge (5.6×4.4×14.7 cm) intraluminal mass (arrows) in the esophagus.



► **Fig. 3** The resected tumor specimen.

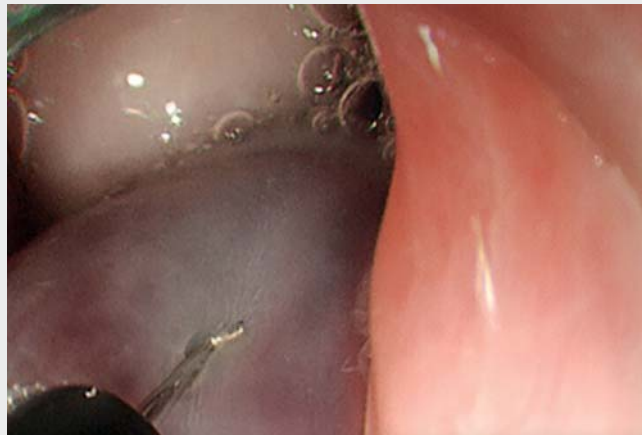

► **Fig. 4** Histopathology revealed spindle cell tumor, without mitosis.



► **Fig. 5** No residual or recurrent tumor was found and wound healing was satisfactory at surveillance endoscopy after 3 months.

Histopathology revealed spindle cell tumor, without mitosis (► **Fig. 4**). Immunohistochemistry showed Dog (–), Desmin (partial +), Actin (partial +), CD117 (–), S-100 (–). A diagnosis of inflammatory fibrous polyp was made. No residual or recurrent tumor was found at surveillance endoscopy 3 months post-procedure and wound healing was satisfactory (► **Fig. 5**). Peduncle ligation provides a new approach to the endoscopic resection of pedunculate submucosal tumors in the esophagus.



► **Video 1** Endoscopic peduncle ligation of huge pedunculate esophageal submucosal tumor.

Endoscopy_UCTN_Code_TTT_1AO_2AG

Acknowledgments

This study was supported by National Key Clinical Discipline and the Six Affiliated Hospital of Sun Yat-sen University Clinical Research 1010 Program (grant numbers 1010PY(2020)-63).

Funding

National Key Clinical Discipline; the Six Affiliated Hospital of Sun Yat-sen University Clinical Research 1010 Program 1010PY(2020)-63

Competing interests

The authors declare that they have no conflict of interest.

The authors

Jiancong Hu^{1,2*}, Wei Liu^{1,2*}, Shi Chen^{2,3}, Junjie Liu^{2,3}, Junsheng Peng^{2,3}

- 1 Department of Endoscopic Surgery, The Sixth Affiliated Hospital, Sun Yat-sen University, Guangzhou, Guangdong, China
- 2 Guangdong Provincial Key Laboratory of Colorectal and Pelvic Floor Diseases, The Sixth Affiliated Hospital, Sun Yat-sen University, Guangzhou, Guangdong, China
- 3 Department of Gastric Surgery, The Sixth Affiliated Hospital, Sun Yat-sen University, Guangzhou, Guangdong, China

Corresponding author

Junsheng Peng, MD

Department of Gastric Surgery, The Sixth Affiliated Hospital, Sun Yat-sen University, 26 Yuancun Erheng Road, Guangzhou 510655, Guangdong, China
pengjsh@mail.sysu.edu.cn

References

- [1] Chen T, Zhou P-H, Chu Y et al. Long-term outcomes of submucosal tunneling endoscopic resection for upper gastrointestinal submucosal tumors. *Ann Surg* 2017; 265: 363–369
- [2] Tang X, Tan Y, Lv L et al. Submucosal tunneling endoscopic resection for seven esophageal leiomyomas. *Endoscopy* 2018; 50: 59–60
- [3] Ye L, Sharma M, Yang D et al. Open dissection for resection of a large submucosal tumor in the esophagus. *Endoscopy* 2019; 51: 243–244

Bibliography

Endoscopy 2022; 54: E654–E655

DOI 10.1055/a-1662-3738

ISSN 0013-726X

published online 15.2.2022

© 2022. Thieme. All rights reserved.

Georg Thieme Verlag KG, Rüdigerstraße 14, 70469 Stuttgart, Germany

* These authors contributed equally to this work.