


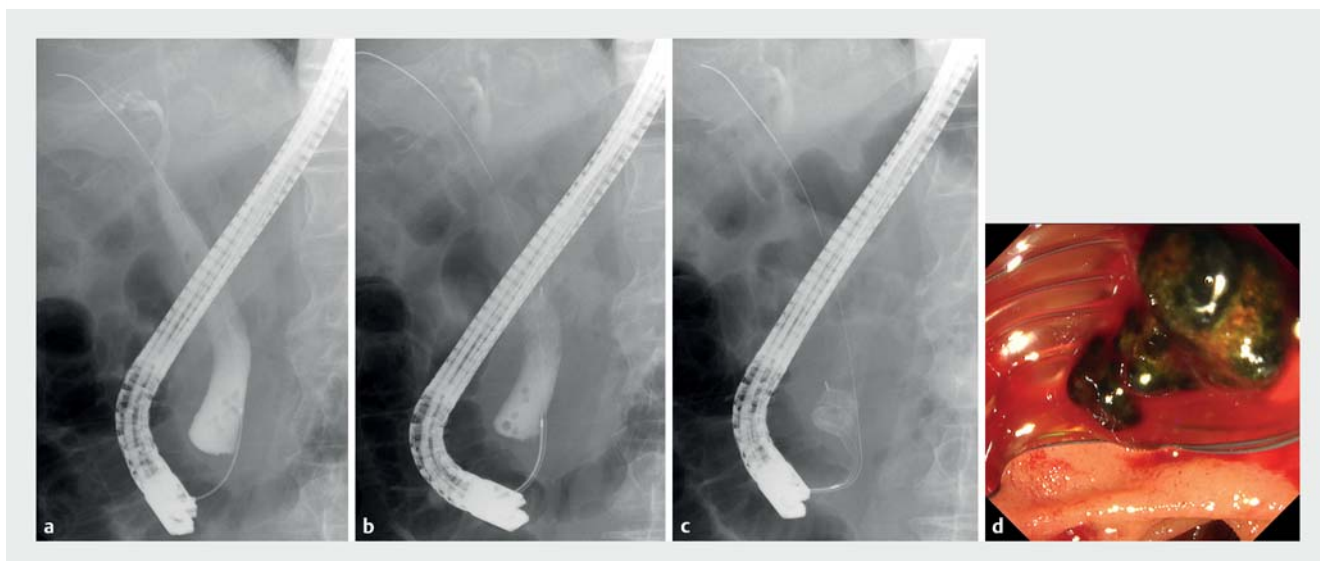
Novel helical eight-wire basket for retrieving small bile duct stones in the corner pocket of the lower bile duct ▶

OPEN
ACCESS

Extraction with a basket or balloon catheter under endoscopic retrograde cholangiography guidance is the standard treatment for small bile duct stones [1]. However, it is a demanding procedure in patients with a substantial lower bile duct corner pocket, in whom small stones are likely to escape and undergo impaction. A novel helical eight-wire basket (RASEN; Kaneka Medix, Osaka, Japan) (▶ **Fig. 1**) has a pre-curved delivery sheath, facilitating easier bile duct insertion and enabling positioning of the basket toward the right side of the body. Moreover, the process of winding the wire differs between the distal and proximal sides. The wire overlap is denser on the distal and sparser at the proximal side. Thus, the maximum expansion of the distal side of the basket is maintained even when the proximal part shrinks. These features are especially beneficial for approaching impacted and escaped small stones in the lower corner pocket. An 83-year-old man developed cholangitis due to bile duct stones. Endoscopic

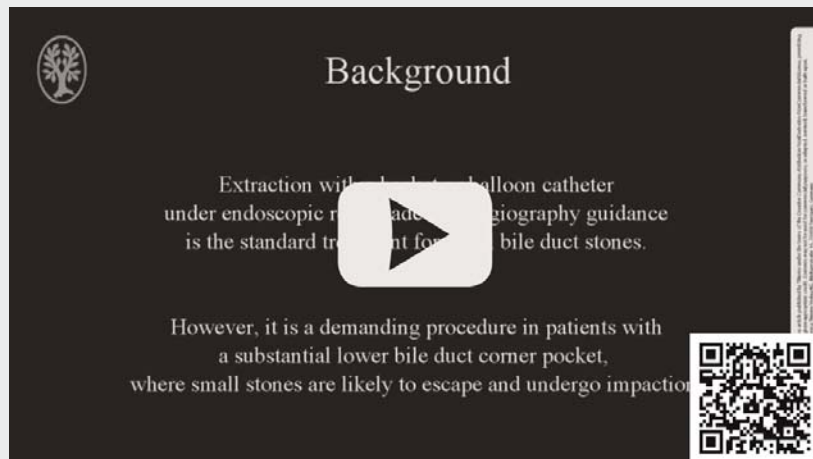


▶ **Fig. 1** **a** The novel helical eight-wire basket (RASEN; Kaneka Medix, Osaka, Japan) has a pre-curved delivery sheath, which facilitates easy insertion to the bile duct and turns the basket toward the right side of the body. **b** The wire overlap is denser at the distal and sparser at the proximal side of the basket; thus, the maximum expansion of the distal side of the basket is maintained even when the proximal part shrinks.



▶ **Fig. 2** **a** There was a significant corner pocket in the lower bile duct. **b** A few stones escaped into the lower corner pocket and could not be removed using a balloon catheter. **c** The novel basket was positioned to the lower corner pocket to enable catching of the stones. **d** Successful retrieval of all stones was achieved.

VIDEO



► **Video 1** Retrieval of bile duct stones in the lower corner pocket using the novel helical eight-wire basket.

retrograde cholangiography revealed multiple small stones in the common bile duct. Stone extraction was attempted with a balloon catheter, following endoscopic sphincterotomy and papillary balloon dilation. Most of the stones were removed, but a few escaped into the lower corner pocket and could not be removed. Consequently, the novel basket was used to remove them. After inserting the basket catheter sheath, the basket was opened in the bile duct. Subsequently, the basket was pulled toward the lower bile duct and rotated by the handle to fit the corner pocket. All the stones were successfully caught and retrieved (► **Fig. 2** and ► **Video 1**). The patient's symptoms improved after the procedure, and no adverse events occurred.

Competing interests

The authors declare that they have no conflict of interest.

The authors

Tadahisa Inoue, Mayu Ibusuki, Rena Kitano, Yuji Kobayashi, Kiyooki Ito, Masashi Yoneda
Department of Gastroenterology, Aichi Medical University, Nagakute, Aichi, Japan

Corresponding author

Tadahisa Inoue, MD, PhD

Department of Gastroenterology, Aichi Medical University, 1-1 Yazakokarimata, Nagakute, Aichi 480-1195, Japan
Fax: +81 561 63 3208
tinoue-tag@umin.ac.jp

Reference

- [1] Manes G, Paspatis G, Aabakken L et al. Endoscopic management of common bile duct stones: European Society of Gastrointestinal Endoscopy (ESGE) guideline. *Endoscopy* 2019; 51: 472–491

Bibliography

Endosc Int Open 2022; 10: E222–E223

DOI 10.1055/a-1675-2524

ISSN 2364-3722

© 2022. The Author(s).

This is an open access article published by Thieme under the terms of the Creative Commons Attribution-NonDerivative-NonCommercial License, permitting copying and reproduction so long as the original work is given appropriate credit. Contents may not be used for commercial purposes, or adapted, remixed, transformed or built upon. (<https://creativecommons.org/licenses/by-nc-nd/4.0/>)

Georg Thieme Verlag KG, Rüdigerstraße 14, 70469 Stuttgart, Germany

