

# New endoscopic capsule vs upper gastrointestinal endoscopy in preoperative work-up of obese candidate for bariatric surgery: Relevance of a pilot study in the COVID-19 era




## Authors

Giuseppe Galloro<sup>1</sup>, Mario Musella<sup>2</sup>, Saverio Siciliano<sup>1</sup>, Giovanna Berardi<sup>2</sup>, Antonio Vitiello<sup>2</sup>, Nunzio Velotti<sup>2</sup>, Fernando Rizzello<sup>3</sup>, Paolo Gionchetti<sup>3</sup>, Carlo Calabrese<sup>3</sup>

## Institutions

- 1 University of Naples Federico II – School of Medicine, Department of Clinical Medicine and Surgery – Surgical Endoscopy Unit, Naples, Italy
- 2 University of Naples Federico II – School of Medicine, Department of Advanced Biomedical Sciences – Bariatric and Metabolic Surgery Unit, Naples, Italy
- 3 University of Bologna Alma Mater – School of Medicine, Department of Medical and Surgical Sciences – Regional Referral Center for IBD, Bologna, Italy

submitted 10.5.2021

accepted after revision 19.10.2021

## Bibliography

Endosc Int Open 2022; 10: E183–E191

DOI 10.1055/a-1723-3109

ISSN 2364-3722

© 2022. The Author(s).

This is an open access article published by Thieme under the terms of the Creative Commons Attribution-NonDerivative-NonCommercial License, permitting copying and reproduction so long as the original work is given appropriate credit. Contents may not be used for commercial purposes, or adapted, remixed, transformed or built upon. (<https://creativecommons.org/licenses/by-nc-nd/4.0/>)

Georg Thieme Verlag KG, Rüdigerstraße 14,  
70469 Stuttgart, Germany

## Corresponding author

Prof. Giuseppe Galloro, University of Naples Federico II – School of Medicine, Via S. Pansini 5, 80131 Naples, Italy  
Fax: +39-081-7462815  
[giuseppe.galloro@unina.it](mailto:giuseppe.galloro@unina.it)

## ABSTRACT

**Background and study aims** Obesity represents a major health concern; bariatric surgery is the most effective treatment reducing and maintaining weight loss. The role of a routine esophagogastroduodenoscopy (EGD) prior bariatric surgery is still debated. Moreover, in this scenario of COVID-19 pandemic, EGD is even more questionable due to the procedural risk of viral transmission. A new model of video-endoscopic capsule (VEC) recently has been introduced as a good alternative to the EGD. The aim of this study was to determine if this new capsule is an adequate diagnostic alternative to EGD in the work-up of patients selected for bariatric surgery, particularly in the setting of COVID-19.

**Patients and methods** From January to November 2020, 27 patients selected for bariatric surgery were enrolled in this pilot study to assess for noninferiority of VEC compared to EGD in detection of upper gastrointestinal disease.

**Results** VEC had sensitivity, specificity, and positive and negative predictive values in identification of significant lesions of 91.3%, 83.33%, 98.01%, and 51.57%, respectively, compared with EGD as the standard criterion. The accuracy was 90.51% (95% CI, 73.75%–98.18%) and the chi-square statistic is 0.1153 ( $P=0.73$ ).

**Conclusions** Our report confirms the diagnostic noninferiority of VEC in preoperative work-up of patients selected for bariatric surgery, compared to EGD. This is very important, particularly during the COVID-19 pandemic, given the high risk of contamination with EGD. Larger multicenter studies are required to confirm our preliminary results.

## Introduction

Obesity represents a major health concern [1] leading to an increased risk of cardio-vascular, pulmonary, metabolic, and gallbladder disease and certain cancers, with a significant health care cost burden [2,3]. Bariatric surgery is the most effective treatment to date for reducing weight and maintaining the loss and resolving several comorbidities [4].

Preoperative diagnostic work-up of obese patients selected for bariatric surgery includes assessments by several health professionals, but the role of routine esophagogastroduodenoscopy (EGD) is still debated [5–8]. The rationale for performing EGD is to detect and treat lesions that could potentially affect the intervention being performed and which would result in complications or symptoms postoperatively [6,7]. Moreover,

endoscopic findings may guide therapeutic decisions, such as the choice of intervention [8].

In spite of this, EGD may carry higher risks in obese patients, especially individuals with morbid obesity, because of the high rates of respiratory problems, such as sleep apnea, respiratory decompensation, and oxygen desaturation during sedation [4–6]. For these reasons, it is very important to correctly assess the real benefits of EGD and to determine whether they balance or outweigh the potential risks of the procedure in this group of patients.

Moreover, during the ongoing COVID-19 pandemic, the role of endoscopy is even more questionable, given the high risk of viral transmission related to the air droplets spread during the procedure [9]. Indeed, most international scientific societies have recommended avoiding non-urgent endoscopies; during the COVID-19 outbreak, a significant drop in the number of all kinds of endoscopies has been reported [10].

Recently, a new model of video-endoscopic capsule (VEC) has been introduced for the study of the upper gastrointestinal tract [11], presented as a comfortable, noninvasive, well-tolerated, and well-performing alternative to an upper endoscopy, which allows EGD to be performed on a select minority of patients who really need it for biopsies or treatment.

The aim of this study was to determine if a kind of new upper gastrointestinal VEC is an adequate diagnostic alternative to EGD in preoperative work-up of obese patients selected for bariatric surgery, particularly in the setting of COVID-19.

## Patients and methods

### Study design and population

This was a pilot, prospective, comparative, double-blind, noninferiority study carried out from January to November 2020. During that period, all patients selected for bariatric surgery at our university hospital were asked to undergo an upper gastrointestinal VEC evaluation and an EGD the next day. This sequence was chosen to avoid misinterpretation during VEC of mucosal traumas from an endoscope touching or sucking possible vascular lesions.

Images from each upper gastrointestinal VEC procedure were interpreted by two medical experts, separately and blinded to each other, to reach a higher level of agreement. For the same reason, the data from each EGD were analyzed by two expert endoscopists, separately and blinded to each other: the first during the endoscopic of the procedure; the second one subsequently, by viewing the recorded file of the procedure.

Finally, the four reports (two from the upper gastrointestinal VEC and two from the EGD) were compared to evaluate the eventual noninferiority of the VEC compared with the EGD, in describing the endoscopic findings diagnosed.

Primary endpoint of the study was to define a noninferiority of upper gastrointestinal VEC compared to EGD in detecting upper gastrointestinal diseases or focal lesions in obese patients prior to bariatric surgery. The secondary endpoint was a comparison of the two procedures in terms of length of stay in the endoscopy room, total amount of drugs used, number of staff members involved, technical problems during the proce-

dures; visual analog scale (VAS) discomfort gradation, and global cost of the procedures.

Inclusion criteria were age between 18 and 65 years, body mass index (BMI)  $\geq 35$  kg/m<sup>2</sup> with obesity-related diseases or BMI  $\geq 40$ , scheduled bariatric surgery intervention, and signing an informed consent.

Exclusion criteria were pregnancy, breastfeeding, use of alcohol/drugs, psychiatric disorders, and patients unwilling to undergo the procedures.

A full and informed consent was obtained from all participants before enrollment. At any time, patients could leave the protocol. All investigations complied with the principles of the Declaration of Helsinki (64th WMA General Assembly, Fortaleza, Brazil, October 2013).

### Sample size calculation and statistical analysis

Assuming a diagnostic yield of 80% and 50% for EGD and VEC, respectively, as previously assessed [12, 13], a sample size of 25 patients would be needed to demonstrate a statistically significant difference in diagnostic yield between the two modalities with 80% power and 5% two-sided significance [14, 15].

Parametric continuous data (Shapiro-Wilk test,  $P = .05$ ) are presented as means  $\pm$  standard deviation and nonparametric continuous data (Shapiro-Wilk test,  $P < .05$ ) as median and interquartile range (IQR). A rank-based nonparametric comparison was performed using the Kruskal-Wallis H test. Categorical data are presented as an absolute number percentage (%), and the McNemar test was used for comparison. Statistical significance was defined as  $P < .05$  in this study.

The SPSS 20.0 software package for Windows (IBM, Chicago, Illinois, United States) and GraphPad Prism 3.0 for Windows (GraphPad Software, San Diego California, United States) were used for statistical analysis.

### Endoscopic procedures

To optimize visualization of the digestive mucosa, 20 minutes before the upper gastrointestinal VEC and the EGD, all patients drank a liquid preparation (water 100 mL, acetylcysteine 6 mL, simethicone 5 mL), already validated to eliminate foam, bubbles, and mucus [16, 17].

For both procedures, the stomach study was evaluated separately in the three segments: fundus, body, and antrum.

Endoscopic images were documented using, for both procedures, a predefined diagnostic score for reporting endoscopic findings listed in ► **Table 1**.

### Upper Gastrointestinal VEC

The positioning of VEC was performed in the endoscopy unit by a nurse experienced in digestive endoscopy and highly trained for capsule procedures. Immediately before swallowing the capsule, 20 mg of hyoscine butyl-bromide was given intramuscularly to reduce peristalsis and optimize esophageal and gastric views. Therefore, the patients swallowed, with a sip of water, the upper gastrointestinal VEC (PillCam upper gastrointestinal, Medtronic Ltd, Saint Peter's, Dublin, Ireland). A portable data recorder (PillCam Recorder DR3, Medtronic Ltd, Saint Peter's, Dublin, Ireland) permitted acquisition of images from a

► **Table 1** Endoscopic images, with respective scores, used to describe the findings of upper gastrointestinal VEC and EGD.

Score	Endoscopic findings	Details
0	Normal	
1	Schatzki ring	Narrowing fold of the lower esophagus partially blocking the lumen
2	Esophagitis	According to the Los Angeles classification [18]
3	Suspected Barrett's esophagus	Salmon-pink colored extension of mucosa growing into the esophagus above the esophageal gastric junction
4	Hiatal hernia	Anterograde picture of trans-cardiac prolapse of gastric folds; retroversion picture of the sub-cardia area in which the endoscope is not tightly gripped by the tissue or the lumen of the esophagus is open, often allowing the squamous epithelium to be viewed from below (respectively grade iii and grade iv according to the hill classification) [44]
5	Gastric biliary reflux	Presence of bile in the stomach
6	Esophageal varices	According to the Baveno criteria [19]
7	Gastric varices	According to the Baveno criteria [19]
8	Congestive gastropathy	Gastric mucosal mosaic like appearance, resembling snake-skin
9	Chronic gastropathy	Edema, linear erythema, erosions, hemorrhage
10	Neoplasm	Polypoid or nonpolypoid lesions according to Paris classification, endoluminal masses
11	Vascular anomaly	Telangiectasia, angiodysplasia
12	Erosion	Superficial mucosal defect, linear or rounded in shape, covered or not with fibrin
13	Ulcer	Break in the digestive wall, linear or rounded in shape, bleeding or not, covered or not with fibrin

double camera system (one for each capsule tip) with a frame rate per second (FRS) from 18 to 35 pictures. A small monitor in the recorder allowed real-time viewing. Once the capsule was swallowed, patients were placed lying supine on the bed, with the trunk tilted 30 degrees for 5 minutes, to decrease the speed of the esophageal transit. Then, they were discharged and returned the next day for the EGD. At the end of the procedure the recorder was removed, and patient discharged. The data were downloaded on the RAPID workstation (Medtronic Ltd, Saint Peter's, Dublin, Ireland) by RAPID Reader v. 9 software (Medtronic Ltd, Saint Peter's, Dublin, Ireland) and then analyzed by an endoscopist skilled in capsule procedures.

## EGD

All the EGDs were performed with a standard gastroscope (GIF HQ-190 Olympus, Shinjuku, Tokyo, Japan) by an endoscopist and a nurse both experienced in bariatric endoscopy, in standard sedation (midazolam 5–10 mg and hyoscine butyl-bromide 20 mg IV); when necessary, because of the psychomotor agitation or respiratory problems of the patients, an anesthesiologist was involved for the use of propofol and orotracheal intubation.

## Evaluation of discomfort of VEC and EGD

To evaluate the general discomfort evoked during upper gastrointestinal VEC and EGD, a questionnaire was administered after each procedure. Patient discomfort was evaluated on a VAS. The VAS consisted of a 100-mm long horizontal straight line defined by anchors with verbal labels, the left end point (0 mm) indicating no discomfort and the right end point (100 mm) in-

► **Table 2** Demographic and clinical characteristics of the study group.

Female/male, n	18/8
Age (y; mean ± SD)	37 ± 8,7
BMI (± SD)	46,88 (± 6,56)
Comorbidity, n (%)	
▪ Diabetes	9 (34,6)
▪ Depression	4 (11,1)

dicating overwhelming discomfort. We determined the VAS score (1 mm = 1) by measuring the distance from the left end point to the mark made by the patient.

## Results

Twenty-seven individuals were initially enrolled in our study, but one withdrew consent; therefore, 26 subjects underwent upper gastrointestinal VEC plus EGD examination. The sample consisted of eight men (30.8%) and 18 women (69.2%); mean age was 37 ± 8.7 years, with a mean BMI of 46.88 ± 6.56 kg/m<sup>2</sup>. Nine patients (34.6%) had type 2 diabetes mellitus (T2DM).

► **Table 2** summarizes baseline demographics.

► **Table 3** Number of upper gastrointestinal pathologies detected by VEC and EGD.

Pathology	Total number	Pathologies detected by both upper gastrointestinal VEC and EGD	Pathologies detected only by upper gastrointestinal VEC	Pathologies detected only by EGD
Hiatal hernia	18	16		2
Esophagitis	9	9		
Gastric erythema	8	8		
Gastric erosion	6	4	2	
Gastric angioectasia	5	4	1	
Gastric polyp	1	1		
Hyperplastic polyp	1			1
Duodenitis	2	2		
Normal appearance	5	4		1

VEC, video-endoscopic capsule; EGD, esophagogastroduodenoscopy

## Upper gastrointestinal VEC

Complete examination of the second duodenum (D2) was achieved in all patients. The mean ( $\pm$ SD) time of capsule transit in the esophagus, stomach, and duodenum was 29 seconds ( $\pm$ 98), 65 minutes ( $\pm$ 21), and 12 minutes ( $\pm$ 16), respectively. The transit time of the capsule through the esophagus, stomach, and duodenum was irrelevant to the aims of the study, as transit occurred while the patient was discharged. For this reason, the transit time was not calculated. Mean residence time in the endoscopic room was 7.27 minutes ( $\pm$ 1.43) for activation of capsule endoscopy.

The mean reading time for capsule video was 46 minutes ( $\pm$ 15) with standard mode. The long average reading time was due to the use of a new device, specific for upper gastrointestinal assessment, and the readers had experience with the ileum and colon capsule. This was the first study that evaluated bariatric patients with a new, specific device, and for this reason, the reading time was longer. No specific challenges were reported.

Pathologies detected by upper gastrointestinal VEC included 16 hiatal hernias, nine esophagitis, eight gastric erythemas, six gastric erosions, five vascular alterations, and two duodenitis; four examinations were normal (► **Table 3**). The degree of satisfaction of the readers was complete.

In our experience, there was a significant interoperator agreement in terms of visibility score both at all sites of the stomach (fundus, body, antrum) ( $r=0.69-0.85$ ,  $P<0.001$ ) and in all explored tracts ( $r=0.75-0.89$ ,  $P<0.001$ ).

## EGD

There were no adverse events during any examinations; in one case orotracheal intubation was required. In nine patients, the endoscopic intubation was regular, in six patients it was difficult, and eight patients were agitated during the examination despite premedication. In three other patients, anesthetic assistance was requested.

Mean residence time in the endoscopic room was 38.8 minutes ( $\pm$ 5.7), of which, 13.4 minutes ( $\pm$ 1.33) was for endoscopy.

Pathologies detected by EGD included 18 hiatal hernias, nine esophagitis, eight gastric erythemas, four gastric erosions, four vascular alterations, one hyperplastic polyp, and two duodenitis; five examinations were normal (► **Table 3**).

We found significant interoperator agreement in terms of visibility score at all sites in the stomach ( $r=0.63-0.81$ ,  $P<0.001$ ). Considering the global evaluation of all explored tracts, the correlations between the two endoscopists were even higher ( $r=0.81-0.97$ ,  $P<0.001$ ).

## Diagnostic yield of upper gastrointestinal VEC vs EGD (primary endpoint)

Considering the primary endpoint, upper gastrointestinal VEC detected 47 upper gastrointestinal pathologies and EGD detected 47 (► **Table 3**). There was no difference in detection of significant lesions.

EGD and VEC concomitantly identified hiatal hernia ( $n=16$ ), esophagitis ( $n=9$ ), gastric erythema ( $n=8$ ), and erosive duodenitis ( $n=4$ ).

VEC alone additionally identified two cases of gastric erosions and one of angioectasia. However, EGD alone identified two additional hiatal hernias and one hyperplastic polyp.

In detail, for the gastric evaluation, fundus, body, and antrum were separately assessed. No gastric fundal lesions were revealed by VEC or EGD; EGD missed erosions in two patients and one vascular lesion detected by VEC in the body. Moreover, EGD revealed one hyperplastic polyp of the body missed by VEC. No differences were noted for antrum evaluation with two techniques.

VEC had sensitivity, specificity, and positive and negative predictive values for identifying significant lesions of 91.3% (95% confidence interval [CI], 71.96%-98.93%), 83.33% (95% CI, 35.88%-99.58%), 98.01% (95% CI, 89.13%-99.66%), and 51.57% (95% CI, 21.77%-80.76%), respectively, compared with EGD as the standard criterion.

The accuracy was 90.51% (95% CI, 73.75%-98.18%) and the chi-square statistic was 0.1153 ( $P=0.73$ ).

### Clinical outcomes of VEC vs EGD (secondary endpoint)

Based on the findings from VEC, all 26 patients were identified as potentially being safe to undergo surgery as well as EGD. No complications were seen with VEC or EGD. Mean residence time in the endoscopic room was 7.27 minutes ( $\pm 1.43$ ) and 38.8 minutes ( $\pm 5.7$ ) for upper gastrointestinal VEC and EGD, respectively ( $P<0.05$ ). All upper gastrointestinal VEC procedures were conducted with only one experienced nurse while EGDs required a mean of 3.2 staff members (1 nurse, 1 endoscopist, and 1 anesthetist in some described cases).

Furthermore, considering patient-reported discomfort, VAS for VEC was significantly lower compared to that of EGD ( $0.27 \pm 0.7$  vs  $5 \pm 1.98$ , respectively  $P<0.001$ ).

Finally, concerning global costs of the procedures, EGD was significantly cheaper than VEC ( $122.82 \pm 4.01$  vs  $596$  €,  $P<0.001$ ).

## Discussion

The role of routine EGD in preoperative assessment of obese patients selected for bariatric surgery has changed over time, and today, it is still debated [5–8].

Some studies suggest that EGD can identify patients with asymptomatic findings that may change surgical planning [18]. Moreover, patients with symptoms of gastroesophageal reflux disease (GERD) or who chronically take antisecretory drugs should undergo EGD [21]. Although most patients with abnormalities in these studies were asymptomatic, endoscopic findings definitively modified the surgical approach only 1% to 9% of cases [8, 18–20].

In 2005, guidelines from the European Association for Endoscopic Surgery (EAES), strongly recommended EGD for all bariatric procedures [7]. However, in the 2020 update of these guidelines [8], EAES recognized that endoscopy might be more appropriate only in selected patients with upper gastrointestinal symptoms, stating that the desirable effects of adhering to the recommendation probably outweighed the undesirable effects, even if there was a lack of confidence about these trade-offs.

Similarly, the American Society of Gastrointestinal Endoscopy and the American Society for Metabolic and Bariatric Surgery recommend that EGD be performed in patients scheduled for bariatric surgery only after a thorough discussion with the surgeon about the type of bariatric procedure and that individual patient's symptoms [6, 21, 22].

In contrast, in Japan, because of the very high incidence of gastric cancer, atrophic gastritis (precancerous status), and *Helicobacter pylori* infection [23], routine EGD is considered necessary before bariatric surgery [24]. In a Japanese series [25], 66% of preoperative EGDs revealed abnormal findings and, subsequently, perioperative management was changed in more than 10% of patients.

The main reason for the more prudent attitude and individualization of indications for each patient with a trend toward preoperative EGD in Western countries is the poor respiratory performance of obese patients during upper endoscopy; macroglossia, sleep apnea, reduced oropharyngeal space by the endoscope, and impaired lung expansion often evolve into dangerous oxygen desaturation [25, 26]. Moreover, because of their low compliance, morbidly obese patients frequently need higher doses of sedation managed by the anesthesiologist, which is a high technical risk, with increased time and costs for endoscopic procedures [23, 24, 26–28].

From the perspective of standardizing preoperative work-up, new upper gastrointestinal VEC could be a valid alternative as a first-line test for endoscopic assessment of obese patients prior to bariatric surgery, with EGD reserved only for cases in which surgery may be contraindicated or delayed after appropriate therapy.

The diagnostic advantages of the new upper gastrointestinal VEC already have been validated in several papers and its technical features make it suitable studying different upper digestive diseases. Among possible preoperative findings, those of particular interest in patients with morbid obesity selected for bariatric surgery are esophagitis, Barrett's esophagus (BE), hiatal hernia, and esophagogastric varices [29, 30].

Previous experience has shown that esophageal transit time was just 2 seconds and the gastroesophageal junction (GEJ) was visualized in only 24% of patients using old-generation, single-headed, small-bowel capsules, with two FRS [31]. Obviously, this kind of capsule is not suitable for esophageal imaging [32].

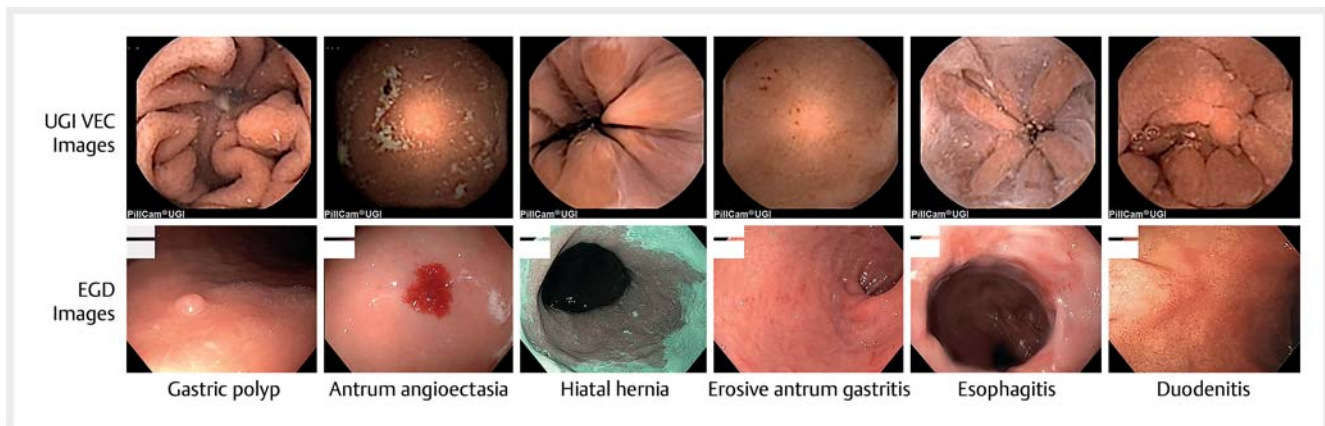
A first-generation, twin-headed, dual-camera esophageal video capsule with an FRS of four pictures was developed specifically for visualization of the GEJ and showed good results in identification of esophagitis, but only moderate or barely acceptable sensitivity and specificity for identifying BE [33–36]. Subsequently, a second-generation esophageal capsule with a higher FRS of 14 pictures showed very high-quality esophageal and GEJ images, excellent visualization of the Z line, and good results for diagnosing erosive esophagitis and suspected BE [37–40].

The new upper gastrointestinal VEC system features innovative technology, operating at 35 FRS for the first 10 minutes of the procedure and 18 FRS for the last 80 minutes, with excellent performance in identifying esophagitis and suspicion of BE [31, 39].

Identification of hiatal hernia often leads to modification of the surgical bariatric strategy, given the risk of postoperative development or worsening of preoperative symptoms [40].

The competence of the mechanical anti-reflux barrier, as an expression of a hiatal hernia, can be evaluated endoscopically in two ways. The most often used is measurement of the axial length between the hiatus and the GEJ. During EGD, the hiatus is represented by the diaphragmatic pinch and the GEJ is defined by the proximal margin of the gastric folds [41]. Given the physiologic dynamics in this area, it can be very difficult to measure the length of a hiatal hernia [42] and interobserver agreement about endoscopic measurement is poor even under ideal conditions [43].





► **Fig. 1** Comparison of upper gastrointestinal VEC images with those for EGD.

The second way to assess a hiatal hernia is by grading the gastroesophageal flap valve using the Hill classification [44], in retroversion position. Many studies show an association between higher Hill grades with GERD [45, 46], low levels of lower esophageal sphincter pressure, and increased prevalence of hiatal hernia [47, 48]. The Hill classification is reproducible and provides useful information for evaluation of patients with suspected GERD who are undergoing endoscopy [45].

A paper comparing these two methods concluded that Hill classification is superior to measurement of the axial length for diagnosis of hiatal hernia [49]. From that perspective, upper gastrointestinal VEC (with its twin-headed, dual cameras, and high FRS) can generate pictures simulating the endoscopic intragastric retroversion visualization according to the Hill classification, with optimal reliability for diagnosing a hiatal hernia.

Because bariatric surgery in obese patients with cirrhosis should only be performed on those with compensated disease, after careful evaluation, by an experienced surgeon at a high-volume bariatric center, preoperative identification of esophago-gastric varices represents an important goal [50]. A systematic review with meta-analysis confirms the feasibility, safety, and tolerance of capsule endoscopy in diagnosis and grading of esophageal varices, with a diagnostic accuracy of 92% [51]. Another multicenter study showed high sensitivity and specificity for detection and grading of esophageal varices and detection of hypertension gastropathy [52].

Our experience confirms the data in the literature and underscores the reliability of upper gastrointestinal VEC for diagnosing esophagitis and hiatal hernia with high sensitivity and specificity. No cases suspected of BE or esophago-gastric/hypertension gastropathy varices occurred in our series. ► **Fig. 1** shows a comparison of upper gastrointestinal VEC images and those from EGD.

All our statistical evaluations showed diagnostic noninferiority of upper gastrointestinal VEC compared with EGD and our results confirmed the advantages of VEC in terms of operative time (with quicker availability of the endoscopic room for other procedures), number of health workers involved [9, 50], and total amount of needed drugs (saving time and money and reducing the rate of AEs to the drugs).

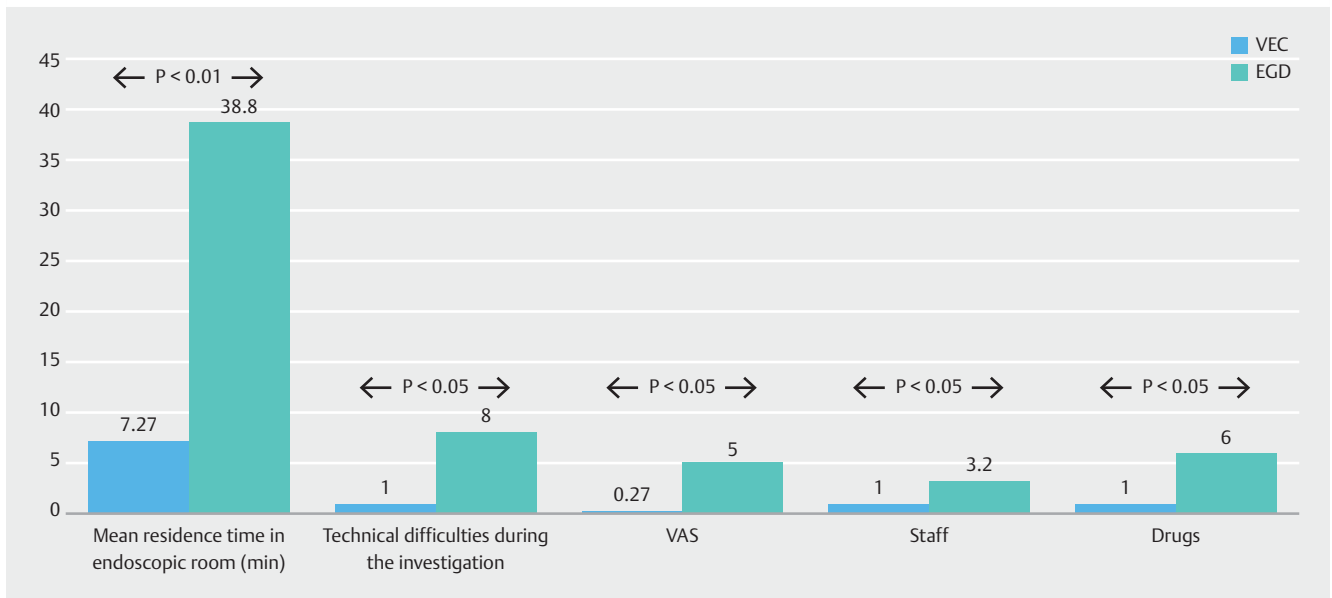
Upper gastrointestinal VEC was associated with a lower rate of technical problems during the procedure and also was well accepted by our cohort of patients, with a lower average score of “no discomfort” on the VAS, compared with EGD, and a greater willingness to repeat the procedure, if necessary. All these data are summarized in ► **Fig. 2**.

Our study also underscores that patients undergoing upper gastrointestinal VEC entered and exited the endoscopy unit on their own. Conversely, with EGD, patients they were transported in an ambulance by a stretcher-bearer because of the premedication that was required. Therefore, that aspect also favors the upper gastrointestinal VEC.

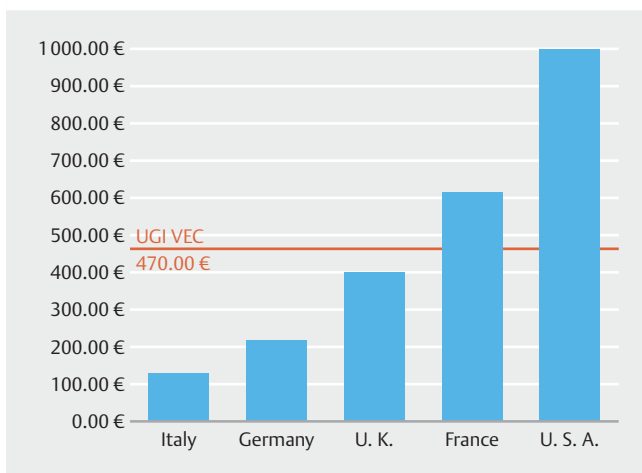
The cost issue, in our experience, is the main disadvantage of the capsule, but we must make a few comments about it. First, upper gastrointestinal VEC is a new device, just recently introduced, with a price not yet corresponding to an established market. As shown in ► **Fig. 3**, in some countries (Italy for example), EGD is cheaper than VEC. On the other hand, in other countries where bariatric surgery is widely performed, the prices are similar or EGD is more expensive than VEC [53–57]. At present, it seems difficult to unequivocally make pharmacoeconomic determinations. Moreover, we must consider that in this particular patient population, use of upper gastrointestinal VEC offers undeniable clinical and organizational advantages, regardless of the costs.

Finally, the COVID-19 pandemic has brought attention to another concern regarding preoperative upper endoscopy, which is airborne transmission of SARS-CoV-2 infection. Dispersion of air droplets is well known during EGD, and therefore, it is considered a high-risk procedure for healthcare workers [58]. Several scientific societies have released guidelines on how to reduce risks in the endoscopy room [9, 59], but it is undeniable that upper gastrointestinal VEC carries lower risks than traditional EGD. In 2020, given the fear of catching COVID-19, many patients cancelled their endoscopy appointments, which resulted in significant and worrying delay in endoscopic diagnosis of gastrointestinal cancer [60].

Although our pilot study was launched before the COVID-19 pandemic, we found our experience particularly important for safe endoscopy in a COVID-19 setting.



► Fig. 2 Results of secondary endpoints of the study.



► Fig. 3 Comparison of costs for upper gastrointestinal VEC versus EGD in some Western countries (in €).

### Strengths and limitations

The strengths of our study are that both EGD and upper gastrointestinal VEC were blindly reviewed by two separate endoscopists and this was the first pilot study investigating the usefulness of upper gastrointestinal VEC in patients with morbid obesity undergoing bariatric surgery.

The main limitation of our study is that it was carried out in a single center with a relatively small sample. However, as has been noted previously, our sample size guarantees a statistical power of 80%.

### Conclusions

In conclusion, our report seems to confirm that upper gastrointestinal VEC, compared with EGD, shows diagnostic noninferiority in detecting significant lesions in preoperative work-up of obese patients prior to bariatric surgery. These results lead us to propose that upper gastrointestinal VEC could be the real first-line endoscopic diagnostic test in obese asymptomatic patients selected for bariatric surgery. From that perspective, EGD could be reserved only for patients suspected to have specific pathologies for whom surgery could be contraindicated or delayed after appropriate therapy, reducing the number of EGDs performed. This point is very important, particularly during the COVID-19 pandemic, because EGD is a high-risk contamination procedure [9, 10,61]. A multicenter experience, in a larger sample of patients, is required to confirm our preliminary results.

### Competing interests

The authors declare that they have no conflict of interest

### References

- [1] Ogden CL, Carroll MD, Kit BK et al. Prevalence of childhood and adult obesity in the United States, 2011–2012. *JAMA* 2014; 311: 806–814
- [2] Ng M, Fleming T, Robinson M et al. Global, regional, and national prevalence of overweight and obesity in children and adults during 1980–2013: a systematic analysis for the Global Burden of Disease Study 2013. *Lancet* 2014; 384: 766–781
- [3] Ozeki KA, Tran AS, Cheung R et al. Preoperative endoscopic findings in veterans undergoing bariatric surgery: prevalence and predictors of Barrett's esophagus. *Obes Surg* 2020; 30: 657–663

- [4] Fernandes SR, Meireles LC, Carrilho-Ribeiro L et al. The role of routine upper gastrointestinal endoscopy before bariatric surgery. *Obes Surg* 2016; 26: 2105–2110
- [5] SAGES Guidelines Committee. SAGES guideline for clinical application of laparoscopic bariatric surgery. *Surg Endosc* 2008; 22: 2281–2300
- [6] Evans JA, Muthusamy VR, Acosta RD et al. The role of endoscopy in the bariatric surgery patient. *Gastrointest Endosc* 2015; 81: 1063–1072
- [7] Sauerland S, Angrisani L, Belachew M et al. Obesity surgery. Evidence-based guidelines of the European Association for Endoscopic Surgery (E.A.E.S.). *Surg Endosc* 2005; 19: 200–221
- [8] Di Lorenzo N, Antoniou SA, Batterham RL et al. Clinical practice guidelines of the European Association for Endoscopic Surgery (EAES) on bariatric surgery: update 2020 endorsed by IFSO? EC, EASO and ESPCOP *Surg Endosc* 2020; 34: 2332–2358
- [9] Galloro G, Pisani A, Zagari RM et al. Safety in digestive endoscopy procedures in the covid era recommendations in progress of the Italian society of digestive endoscopy. *Dig Liver Dis* 2020; 52: 800–807
- [10] Sultan S, Lim JK, Altayar O et al. AGA Rapid Recommendations for Gastrointestinal Procedures During the COVID-19 Pandemic. *Gastroenterology* 2020; 159: 739–758.e4
- [11] Ching HL, Healy A, Thurston V et al. Upper gastrointestinal tract capsule endoscopy using a nurse-led protocol: first reported experience. *World J Gastroenterol* 2018; 14: 2893–2901
- [12] Aljebreen AM, Alswat K, Almadi MA. Appropriateness and diagnostic yield of upper gastrointestinal endoscopy in an open-access endoscopy system. *Saudi J Gastroenterol* 2013; 19: 219–222
- [13] Song HJ, Shim KN. Current status and future perspectives of capsule endoscopy. *Intest Res* 2016; 14: 21–29
- [14] Gralnek IM, Ching JY, Maza I et al. Capsule endoscopy in acute upper gastrointestinal hemorrhage: a prospective cohort study. *Endoscopy* 2013; 45: 12–19
- [15] Blackwelder WC. Proving the null hypothesis in clinical trials. *Control Clin Trials* 1982; 3: 345–353
- [16] Kuo CH, Sheu BS, Kao AW et al. A defoaming agent should be used with pronase premedication to improve visibility in upper gastrointestinal endoscopy. *Endoscopy* 2002; 34: 531–534
- [17] Woo JG, Kim TO, Kim HJ et al. Determination of the optimal time for premedication with pronase, dimethylpolysiloxane, and sodium bicarbonate for upper gastrointestinal endoscopy. *J Clin Gastroenterol* 2013; 47: 389–392
- [18] Korenkov M, Sauerland S, Shah S et al. Is routine preoperative upper endoscopy in gastric banding patients really necessary? *Obes Surg* 2006; 16: 45–47
- [19] Hampel H, Abraham NS, El-Serag HB. Meta-analysis: obesity and the risk for gastroesophageal reflux disease and its complications. *Ann Intern Med* 2005; 143: 199–211
- [20] Loewen M, Giovanni J, Barba C. Screening endoscopy before bariatric surgery: a series of 448 patients. *Surg Obes Relat Dis* 2008; 4: 709–712
- [21] Parikh M, Liu J, Vieira D et al. Preoperative endoscopy prior to bariatric surgery: a systematic review and meta-analysis of the literature. *Obes Surg* 2016; 26: 2961–2966
- [22] Mechanick JL, Apovian C, Brethauer S et al. Clinical practice guidelines for the perioperative nutrition, metabolic, and nonsurgical support of patients undergoing bariatric procedures – 2019 update: cosponsored by American Association of Clinical Endocrinologists/American College of Endocrinology, The Obesity Society, American Society for Metabolic & Bariatric Surgery, Obesity Medicine Association, and American Society of Anesthesiologists. *Surg Obes Relat Dis* 2020; 16: 175–247
- [23] Tsuda M, Asaka M, Kato M et al. Effect on *Helicobacter pylori* eradication therapy against gastric cancer in Japan. *Helicobacter* 2017; 22: e12415
- [24] Asaka M, Kato M, Graham DY. Strategy for eliminating gastric cancer in Japan. *Helicobacter* 2010; 16: 486–490
- [25] Endo Y, Ohta M, Tada K et al. Clinical significance of upper gastrointestinal endoscopy before laparoscopic bariatric procedures in Japanese patients. *Surgery Today* 2019; 49: 27–31
- [26] Balachandran JS, Masa JF, Mokhlesi B. Obesity hypoventilation syndrome: epidemiology and diagnosis. *Sleep Med Clin* 2014; 9: 341–347
- [27] Mokhlesi B, Masa JF, Brozek JL et al. Evaluation and management of obesity hypoventilation syndrome: an official American Thoracic Society clinical practice guideline. *Am J Respir Crit Care Med* 2019; 200: e6–e24
- [28] Galloro G, Sivero S, Magno L et al. New technique for endoscopic removal of intragastric balloon placed for treatment of morbid obesity. *Obes Surg* 2007; 17: 658–662
- [29] Armstrong D, Bennett JR, Blum AL et al. The endoscopic assessment of esophagitis: a progress report on observer agreement. *Gastroenterology* 1996; 111: 85–92
- [30] Augustin S, Pons M, Maurice JB et al. Expanding the Baveno VI criteria for the screening of varices in patients with compensated advanced chronic liver disease. *Hepatology* 2017; 66: 1980–1988
- [31] Neu B, Wettschureck E, Rösch T. Is esophageal capsule endoscopy feasible? Results of a pilot Endoscopy 2003; 35: 957–961
- [32] Schnoll-Sussman F, Hernandez AB, Shah T. Capsule endoscopy: can it replace upper endoscopy to screen for Barrett's? *Gastrointest Endosc* 2004; 59: AB263
- [33] Eliakim R, Yassin K, Shlomi I et al. A novel diagnostic tool for detecting oesophageal pathology: the PillCam oesophageal video capsule. *Aliment Pharmacol Ther* 2004; 20: 1083–1089
- [34] Lin OS, Schembre DB, Mergener K et al. Blinded comparison of esophageal capsule endoscopy versus conventional endoscopy for a diagnosis of Barrett's esophagus in patients with chronic gastroesophageal reflux. *Gastrointest Endosc* 2007; 65: 577–583
- [35] Galmiche JP, Sacher-Huvelin S, Coron E et al. Screening for esophagitis and Barrett's esophagus with wireless esophageal capsule endoscopy: a multicenter prospective trial in patients with reflux symptoms. *Am J Gastroenterol* 2008; 103: 538–545
- [36] Sharma P, Wani S, Rastogi A et al. The diagnostic accuracy of esophageal capsule endoscopy in patients with gastroesophageal reflux disease and Barrett's esophagus: a blinded, prospective study. *Am J Gastroenterol* 2008; 103: 525–532
- [37] Granlek IM, Adler SN, Yassin K et al. Detecting esophageal disease with second-generation capsule endoscopy: initial evaluation of the PillCam ESO 2. *Endoscopy* 2008; 40: 275–279
- [38] Offman J, Fitzgerald RC. Alternatives to traditional per oral endoscopy for screening. *Gastrointest Endosc Clin N Am* 2017; 27: 379–396
- [39] Ciocirlan M. Endoscopic screening for Barrett's esophagus: while we're in, do we also need to see the stomach and the duodenum? *Endosc Int Open* 2017; 05: E345–E347
- [40] Musella M, Vitiello A, Berardi G et al. Evaluation of reflux following sleeve gastrectomy and one anastomosis gastric bypass: 1-year results from a randomized open-label controlled trial. *Surg Endosc* 2021; 35: 6777–6785.i
- [41] Wallner B. Endoscopically defined gastroesophageal junction coincides with the anatomical gastroesophageal junction. *Surg Endosc* 2009; 23: 2155–2158
- [42] Kahrilas PJ, Kim HC, Pandolfino JE. Approaches to the diagnosis and grading of hiatal hernia. *Best Pract Res Clin Gastroenterol* 2008; 22: 601–616



- [43] Guda N, Partington S, Vakil NB. Inter- and intra-observer variability in the measurement of length at endoscopy: Implications for the measurement of Barrett's esophagus. *Gastrointest Endosc* 2004; 59: 655–658
- [44] Hill LD, Kozarek RA, Kraemer SJM et al. The gastroesophageal flap valve: in vitro and in vivo observations. *Gastrointest Endosc* 1996; 44: 541–547
- [45] Kim GH, Kang DH, Song GA et al. Gastroesophageal flap valve is associated with gastroesophageal and gastropharyngeal reflux. *J Gastroenterol* 2006; 41: 654–661
- [46] Koch OO, Spaun G, Antoniou SA et al. Endoscopic grading of the gastroesophageal flap valve is correlated with reflux activity and can predict the size of the esophageal hiatus in patients with gastroesophageal reflux disease. *Surg Endosc* 2013; 27: 4590–4595
- [47] Navarathne NMM, Abey Suriya V, Ileperuma A et al. Endoscopic observations around the gastroesophageal junction in patients with symptomatic gastroesophageal reflux disease in South Asia. *Indian J Gastroenterol* 2010; 29: 184–186
- [48] Cheong JH, Kim GH, Lee BE et al. Endoscopic grading of gastroesophageal flap valve helps predict proton pump inhibitor response in patients with gastroesophageal reflux disease. *Scand J Gastroenterol* 2011; 46: 789–796
- [49] Hansdotter I, Björ O, Andreasson A et al. Hill classification is superior to the axial length of a hiatal hernia for assessment of the mechanical anti-reflux barrier at the gastroesophageal junction. *Endoscopy International Open* 2016; 4: E311–E317
- [50] Patton H, Heimbach J, McCullough A. AGA Clinical Practice Update on Bariatric Surgery in Cirrhosis: Expert Review. *Clin Gastroenterol Hepatol* 2021; 19: 436–445
- [51] McCarty TR, Afinogenova Y, Njei B. Use of wireless capsule endoscopy for the diagnosis and grading of esophageal varices in patients with portal hypertension: a systematic review and meta-analysis. *J Clin Gastroenterol* 2017; 51: 174–182
- [52] Cardey J, Le Gall C, Michaud L et al. Screening of esophageal varices in children using esophageal capsule endoscopy: a multicenter prospective study. *Endoscopy* 2019; 51: 10–17
- [53] Meltzer AC, Ward MJ, Gralnek IM et al. The cost-effectiveness analysis of video capsule endoscopy compared to other strategies to manage acute upper gastrointestinal hemorrhage in the ED. *Am J Emerg Med* 2014; 32: 823–832
- [54] Rathmayer M, Heinlein W, Reiß C et al. Cost assessment for endoscopic procedures in the German diagnosis-related-group (DRG) system – 5 years cost data analysis of the German Society of Gastroenterology project. *Z Gastroenterol* 2017; 55: 1038–1051
- [55] <https://improvement.nhs.uk/resources/national-tariff/>
- [56] [https://www.atih.sante.fr/sites/default/files/public/content/2563/rapport\\_couts\\_de\\_prise\\_en\\_charge\\_2012.pdf](https://www.atih.sante.fr/sites/default/files/public/content/2563/rapport_couts_de_prise_en_charge_2012.pdf)
- [57] <https://www.healthcost.com/services/browse/Upper%20Endoscopy/43235>
- [58] Rana SS. Risk of COVID-19 Transmission During Gastrointestinal Endoscopy. *Journal of Digestive Endoscopy* 2020; 11 : 27–30
- [59] Gralnek IM, Hassan C, Beilenhoff U et al. ESGE and ESGENA Position Statement on gastrointestinal endoscopy and the COVID-19 pandemic. *Endoscopy* 2020; 52: 483–490
- [60] Maringe C, Spicer J, Morris M et al. The impact of the COVID-19 pandemic on cancer deaths due to delays in diagnosis in England, UK: a national, population-based, modelling study. *Lancet Oncol* 2020; 21: 1023–1034
- [61] McAlindon M. COVID-19: impetus to the adoption of capsule endoscopy as a primary diagnostic tool? *Frontline Gastroenterol* 2021; 12: 263–264