

Endoscopic ultrasound-guided radiofrequency ablation of recurrent cervical cancer in the pelvis untreatable by radiation therapy

A 75-year-old woman with a history of squamous cell carcinoma of the cervix (FIGO staging IIa: T2a, N0, M0) was treated with neoadjuvant platinum-based chemotherapy, followed by laparoscopic bilateral hysterectomy and bilateral pelvic lymphadenectomy. One year later, recurrent disease at the vaginal dome was detected and treated with cisplatin chemotherapy and radiotherapy (4500 Gy total), with a complete response. After 2 years, she developed additional lesions at the right iliac fossa for which cisplatin and topotecan were administered, with a partial response. The patient was subsequently enrolled in an experimental trial and received 10 cycles of atezolizumab and tiragolumab. One year later, two solid lesions were de-

tected close to the posterior (25 mm) and lateral (35 mm) bladder walls. The former lesion was treated with radiation therapy, but the second lesion could not be treated owing to close proximity to the bladder (► **Fig. 1 a, b**).

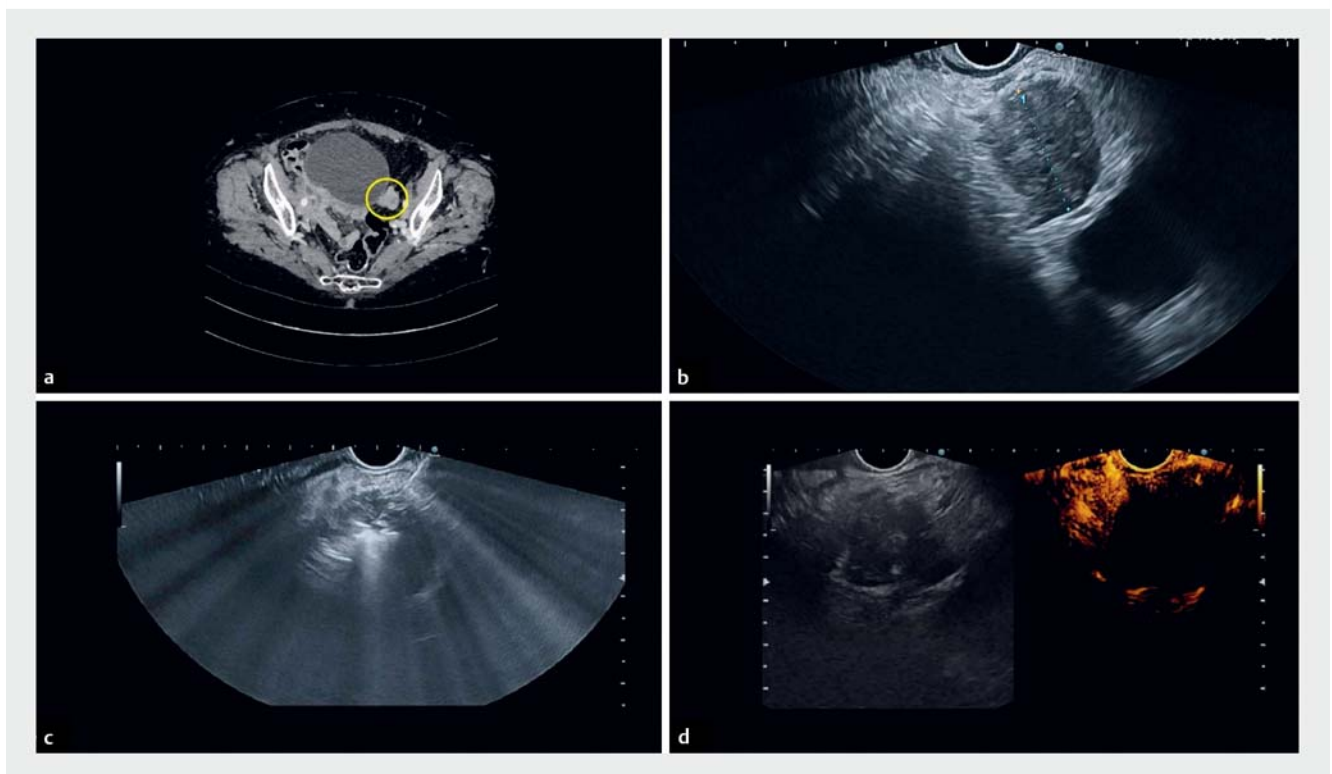
Endoscopic ultrasound (EUS)-guided radiofrequency ablation (RFA) of the peri-bladder nodule was offered to the patient and scheduled. Contrast-enhanced EUS showed some degree of contrast enhancement of the untreated nodule (► **Video 1**). The 19 G RFA needle was inserted into the lesion and radiofrequency current was administered at 50 W until increase of impedance on the RFA generator (► **Fig. 1 c**). In total, five RFA treatments were delivered to cover the lesion. Post-RFA contrast-enhanced EUS

showed absence of any residual enhancement (► **Fig. 1 d**).

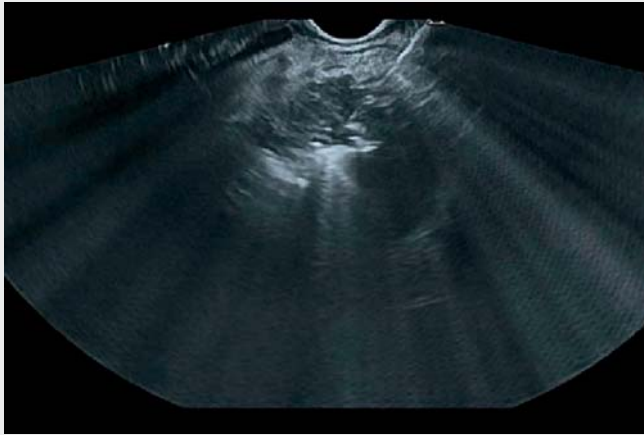
Computed tomography 1 month later showed complete response of the treated nodule by modified RECIST criteria, with a size reduction (► **Video 1**).

This is the first report of the feasibility of EUS-RFA for treatment of a recurrent cervical tumor in the pelvis, for which no more treatment options were available. If proved safe, EUS-RFA alone or in combination with other treatment modalities, can become part of the therapeutic armamentarium for locally recurrent gynecologic cancers that respond poorly to standard approaches [1–4].

Endoscopy_UCTN_Code_TTT_1AS_2AG



► **Fig. 1** Computed tomography (CT) and endoscopic ultrasound (EUS) images. **a** CT image showing the recurrent pelvic lesion adjacent to the bladder. **b** EUS image of the recurrent pelvic lesion adjacent, but a few centimeters distant, from the bladder. **c** EUS image of the pelvic lesion with the radiofrequency ablation needle inside, surrounded by hyperechoic halos due to tumor ablation, with tissue necrosis. **d** Contrast-enhanced EUS evaluation after lesion ablation, showing complete lack of contrast uptake.



Video 1 Endoscopic ultrasound-guided radiofrequency ablation of recurrent cervical cancer in the pelvis, untreatable by radiation therapy.

- [4] Ding T, Tang D, Xi M. The survival outcome and complication of secondary cytoreductive surgery plus chemotherapy in recurrent ovarian cancer: a systematic review and meta-analysis. *J Ovarian Res* 2021; 14: 93

Bibliography

Endoscopy 2022; 54: E639–E640

DOI 10.1055/a-1730-4346

ISSN 0013-726X

published online 4.2.2022

© 2022. Thieme. All rights reserved.

Georg Thieme Verlag KG, Rüdigerstraße 14, 70469 Stuttgart, Germany

ENDOSCOPY E-VIDEOS

<https://eref.thieme.de/e-videos>



Endoscopy E-Videos is an open access online section, reporting on interesting cases

and new techniques in gastroenterological endoscopy. All papers include a high quality video and all contributions are freely accessible online. Processing charges apply (currently EUR 375), discounts and waivers acc. to HINARI are available.

This section has its own submission website at

<https://mc.manuscriptcentral.com/e-videos>

Competing interests

A. Larghi is a consultant for Boston Scientific and Pentax Medical. He has received research grant from Medtronic.

The authors

Vanda Salutati¹, Mario Gagliardi², Gianenrico Rizzatti², Francesca Ciccarone¹, Eugenia D'Angeli¹, Giovanni Scambia^{1,3}, Alberto Larghi²

- 1 Division of Gynecological Oncology, Department for the Protection of Women's and Children's Health and Public Health, Fondazione Policlinico Universitario A. Gemelli IRCCS, Rome, Italy
- 2 Digestive Endoscopy Unit, Fondazione Policlinico Universitario A. Gemelli IRCCS, Rome, Italy
- 3 Università Cattolica del Sacro Cuore, Rome, Italy

Corresponding author

Alberto Larghi, MD, PhD

Digestive Endoscopy Unit, Fondazione Policlinico Universitario A. Gemelli IRCCS, Largo A. Gemelli 8, 00136 Rome, Italy
alberto.larghi@policlinicogemelli.it

References

- [1] Lee YY, Choi MC, Park JY et al. Major clinical research advances in gynecologic cancer in 2020. *J Gynecol Oncol* 2021; 32: e53
- [2] Hamilton CA, Pothuri B, Arend RC et al. Endometrial cancer: a Society of Gynecologic Oncology evidence-based review and recommendations. *Gynecol Oncol* 2021; 160: 817–826
- [3] Ngu SF, Ngan HY, Chan KK. Role of adjuvant and post-surgical treatment in gynaecological cancer. *Best Pract Res Clin Obstet Gynaecol* 2022; 78: 2–13