

Pinch Anatomy of Forehead: An Injection Guide for Forehead Filler Treatment

Krishan M. Kapoor, MS, MCh, DNB^{1,2} Vandana Chatrath, MD³ Chris Q. Li⁴ Dario Bertossi, MD, PhD^{5,6}

¹ Anticlock Clinic, Chandigarh, India

² Department of Plastic Surgery, Fortis Hospital, Mohali, Punjab, India

³ Vanila Dermologie, New Delhi, India

⁴ Angel Swan Clinic, Shanghai, People's Republic of China

⁵ Maxillo-Facial Surgery, University of Verona, Verona, Italy

⁶ Maxillofacial Plastic Surgery Unit, Policlinico G.B. Rossi Piazzale L.A. Scuro, Verona, Italy

Address for correspondence Krishan M. Kapoor, MS, MCh, DNB, no. 1508, Sector 33 D, Chandigarh 160022, India (e-mail: kmkapoor@gmail.com).

Facial Plast Surg 2022;38:156–162.

Abstract

Keywords

- ▶ pinch anatomy
- ▶ fillers
- ▶ dermal filler
- ▶ filler injection
- ▶ facial anatomy
- ▶ injection anatomy
- ▶ hyaluronic acid
- ▶ filler complications
- ▶ filler technique
- ▶ forehead fillers

Filler injections have become very popular in recent years, and injectors globally use them for facial shaping and reversing age-related changes. Detailed knowledge about important vessels' and tissue planes' anatomy is essential for injectors. While giving the filler injections, injectors tend to gently pinch or pull the tissue fold with the nondominant hand during the procedure. The deformational forces cause some changes in the anatomy of tissue layers held in a pinch. During the pinch and “pinch and pull” maneuver, the crucial vessels in the area can get pulled up in the tissue layers in a pinch or stay in their position unaffected depending on the force applied. The “pinch and pull” maneuver also increases the tissue space for injections by moving the mobile tissue layers away from the fixed ones. The injector can use knowledge of the “pinch anatomy” in the forehead to avoid important arteries and place filler in the correct plane. With the understanding of the anatomical changes occurring during the pinched state of tissue layers, filler injection can be performed in the right and safer tissue plane in the forehead. This study reflects level of evidence V.

Soft tissue augmentation with fillers is a minimally invasive procedure that provides a quick and satisfying esthetic outcome with reasonably good predictability. Minimally invasive esthetic procedures, especially filler injections, have seen increasing popularity in the last decade. As per the statistics given by the American Society for Aesthetic Plastic Surgery (ASAPS) for the top five nonsurgical esthetic procedures performed in 2016, hyaluronic acid dermal fillers ranked second to botulinum toxin injections with 2.49 million procedures in the United States alone.¹ This exponential demand has necessitated that more injectors do this procedure and learn the injection skills.

During training for fillers, much emphasis is given on teaching the facial anatomy concerning injections, that is, the injection anatomy.² However, changes in the tissue layers' anatomy due to their manipulation during filler injection

have not been discussed in detail. The anatomical change of these tissue layers during pinching or pulling has been studied as “pinch anatomy.”^{3,4}

The Concept of “Pinch Anatomy”

Various facial structures are shown in their natural, rested appearance in the images of cadaver dissections or medical illustrations. They are shown without any distortion caused by pinching or pinching with pulling. Commonly, clinicians perform filler injections with their dominant hand while pinching and pulling the skin fold with their nondominant hand. During pinching, the anatomy of tissue layers, known as “pinch anatomy,” becomes different from their natural appearance externally and internally.⁵ While the external changes caused by pinching on the skin are visible on the skin surface, the injectors

published online
January 4, 2022

Issue Theme Nonsurgical Facial
Treatments; Guest Editor: Dario Bertossi,
MD, PhD

© 2022, Thieme. All rights reserved.
Thieme Medical Publishers, Inc.,
333 Seventh Avenue, 18th Floor,
New York, NY 10001, USA

DOI <https://doi.org/10.1055/a-1730-8436>.
ISSN 0736-6825.

should be aware of the changes caused by these deformational forces in the deeper tissue layers. In understanding the concept of “pinch anatomy,” it is essential to know the terms like “pinch,” “pinch and pull,” and “gliding plane.”

A “pinch” can be described as a maneuver using the thumb and adjoining fingers to hold the tissue layers as a fold. As per the Oxford Dictionary, the word “Pinch” means “to grip (something, typically a person’s flesh) tightly and sharply between finger and thumb.”

While pinching bunches up the skin in a fold, the potential space under the pinch is still limited. However, simultaneous “pinch and pull”⁶ movement or a deep pinch can change this limited space into a much larger space between the layers at the level of the glide plane. The “pinch and pull” maneuver has also been described earlier as pinching or tenting⁷ method for filler injection.

The term “glide plane” can be described as a plane between the tissue layers, allowing easy movement of superficial tissue layers over the deeper layers.⁸ This plane is also important during the “pinch and pull” maneuver as the mobile superficial layers get pulled up over relatively fixed deeper layers. This plane is a potential space that gets increased during the pulling up of superficial tissue layers.

“Pinch Anatomy” of the Forehead Tissue Layers

The forehead consists of a thick layer of skin that overlies a subcutaneous fat layer to which it is firmly attached. Just deep to the subcutaneous fat layer is the galea aponeurosis. This layer of the forehead envelopes a pair of frontalis muscles. Deep to the galeal layer is the loose areolar tissue lying between the galeal layer and the pericranium. The musculoaponeurotic layer is attached to the skin by retinacular cutis fibers passing within the subcutaneous fat layer. The outer three layers are fused in a functional unit, separated from the periosteum, and bone by the loose areolar tissue layer.⁹ With the frontalis muscle contraction, the three superficial layers of the forehead glide for short distances over the underlying periosteum with loose areolar tissue providing the glide plane.^{10,11} This glide plane of galea moving over the periosteum influences the aging process and allows surgeons to rejuvenate the upper face by elevating the sagging soft tissues. The scalp flap can be easily dissected during plastic surgery procedures because the loose areolar tissue allows easy gliding movement of the composite scalp over the fixed layers underneath, that is, periosteum and bone.¹²

When the gentle pinch is applied to the tissue layers in the forehead, the skin and subcutaneous fat layer constitute the tissue layers in a pinch (►Fig. 1). The frontal branch of superficial temporal artery (STA) and its transverse branch run on the superficial surface of the galea aponeurotica layer¹³ (►Fig. 2), and the layers in the gentle pinch are just superficial to these important vessels. This change is quite similar to the changes induced by gentle pinching in the temple. The supraorbital and supratrochlear vessels are found on the galeal surface of the upper two-thirds of the forehead after becoming superficial from their deep location

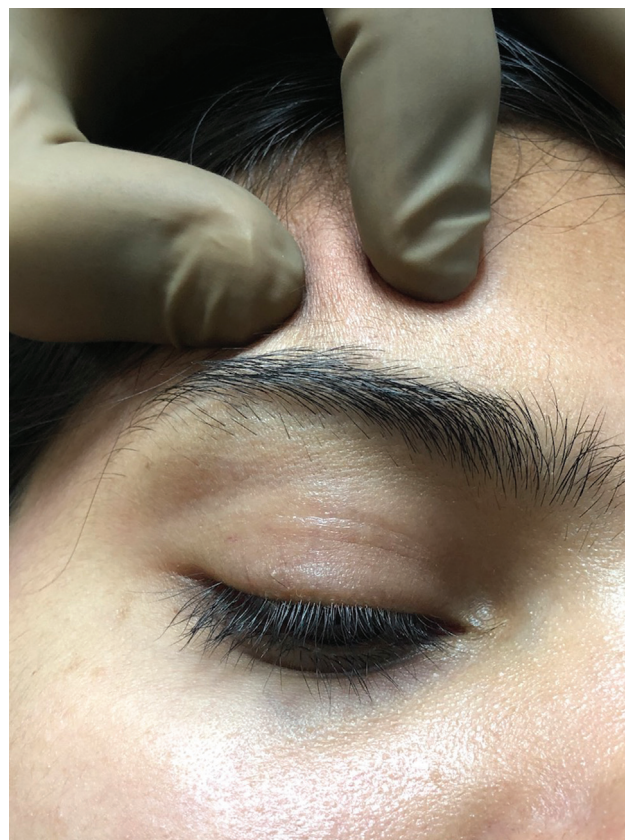

Fig. 1 The picture shows the “gentle pinch” maneuver with the thumb and index finger in the forehead.

in the lower one-third of the forehead. The deep pinch or “pinch and pull” maneuver in the upper two-thirds of the forehead pulls up the skin, subcutaneous fat, and galea layers along with the frontal branch of STA, supratrochlear (ST) artery, and supraorbital (SO) artery, with all of them running on the surface of the galea (►Fig. 3). Loose areolar tissue provides a subgaleal glide plane to the mobile superficial tissue layers of the forehead for movement over the fixed tissue layer, that is, periosteum¹⁴ (►Table 1). By deep pinching/pinching and pulling, the potential space in the relatively avascular, loose areolar tissue layer in the forehead is increased (►Fig. 4). This space can then be utilized for filler injection with needle/cannula in the forehead with minimum risk of vascular complications (►Figs. 5 and 6; ►Video 1 [available in the online version]).

Video 1

Showing injection of filler material (green color) in the relatively avascular, loose areolar tissue layer on the periosteal layer of the forehead when a deep pinch is used to create more space in this layer (cadaver dissection video contributed by author K.M.K.). Online content including video sequences viewable at: <https://www.thieme-connect.com/products/ejournals/html/10.1055/a-1730-8436>.

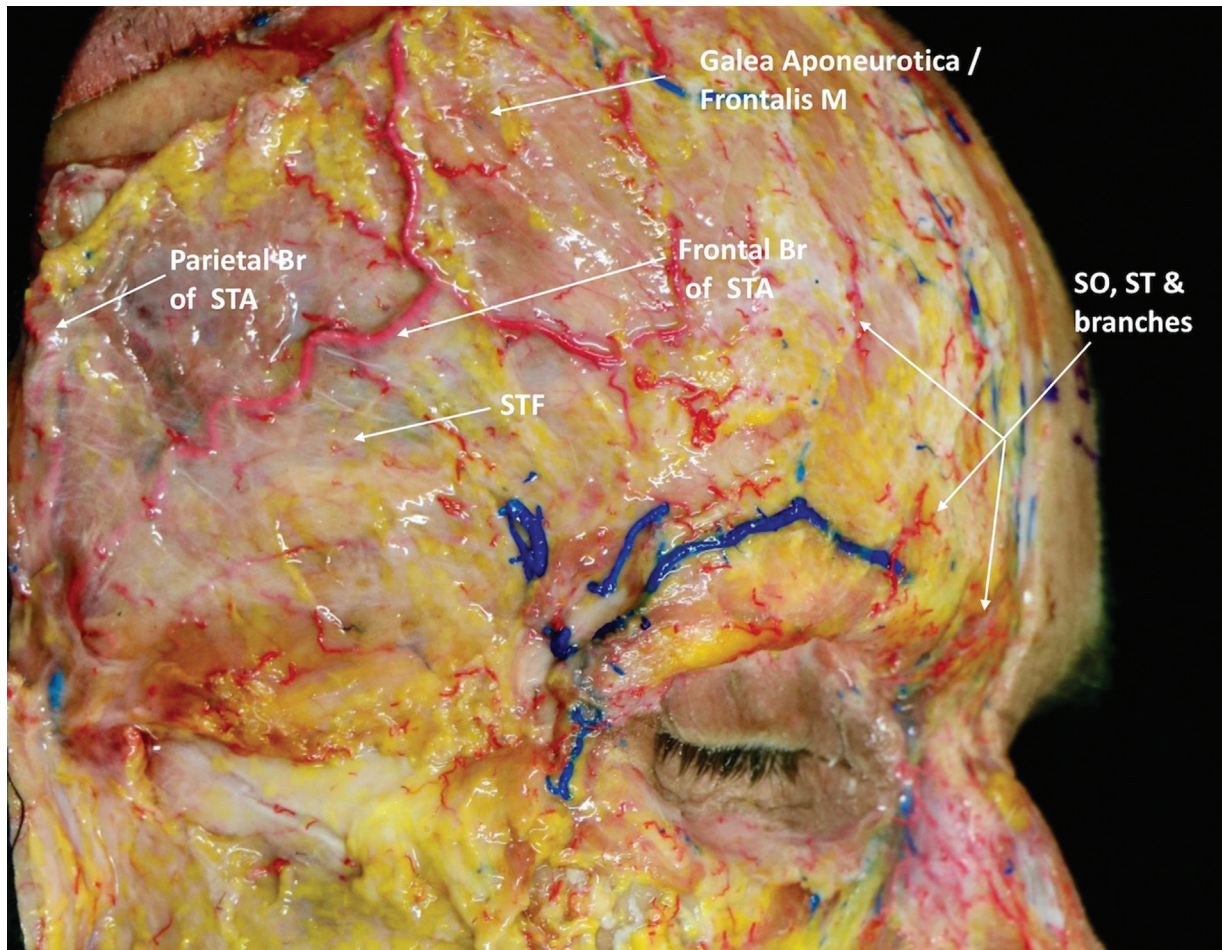


Fig. 2 The cadaver dissection showing the course of the frontal branch of STA on the surface of STF in the temple and galea in the forehead. It also indicates branches of SO and ST in the superficial plane in the upper two-thirds of the forehead (cadaver dissection image contributed by author K.M.K.). SO, supraorbital; ST, supratrochlear; STA, superficial temporal artery; STF, superficial temporal fascia; M, muscle; Br, branch.

Discussion

Filler injections are minimally invasive in comparison to surgical procedures. The key advantages of the filler procedure are shorter procedure time, quick recovery, and theoretically lower possibility of complications. However, while performing the filler injections, one should be cautious not to inject in the blood vessels as significant complications, like skin necrosis^{15,16} and vision loss,¹⁷⁻¹⁹ have been reported with accidental intra-arterial injection. In addition, non-thrombotic pulmonary embolism has also been reported with accidental intravenous injection of fillers.²⁰

Therefore to maximize the value of filler treatment, the aim should be to minimize the possibility of vascular complications by placing the fillers in the correct plane and away from arteries.²¹ It is difficult to learn for injectors as consistently reaching the right injection plane with a needle or cannula is not easy. It requires training for injectors by imparting them the knowledge of arterial and tissue layer anatomy. The knowledge of the precise location and correct depth of major blood vessels, based on facial surface anatomy, is necessary for safe and effective filler injections. During cadaver training or as depicted in anatomy manuals, vital anatomical structures are shown in their natural, undistort-

ed positions.²² However, pinching and pulling with the nondominant hand during filler injection distorts the tissue anatomy.⁵ The impact of pinching on the anatomy of the tissue is now being studied as “pinch anatomy.”^{3,4}

During filler injections, there are two crucial factors to be considered. One is to avoid important arteries, and the other is the filler placement in the right plane.²³ With the knowledge of pinch anatomy, using different pinch methods and the relationship of the critical structures with the tissue layers pulled up in a pinch, clinicians can target specific planes for filler injection while avoiding the important vessels.

During the pinch procedure, consideration for the depth and course of major arteries in that region is essential. During the pinch procedure, it is crucial to learn which layers of the face get separated from deeper layers. During the “pinch and pull” procedure in an area, it is vital to know whether the blood vessels are pulled upward with the tissue layers or not. If the blood vessels are thought to be pulled up with a “pinch and pull” maneuver, injecting the filler in the deeper layer would be much safer. If the blood vessels are not pulled up with “pinch and pull,” injecting the filler in the superficial layers in a pinch would be safer.³

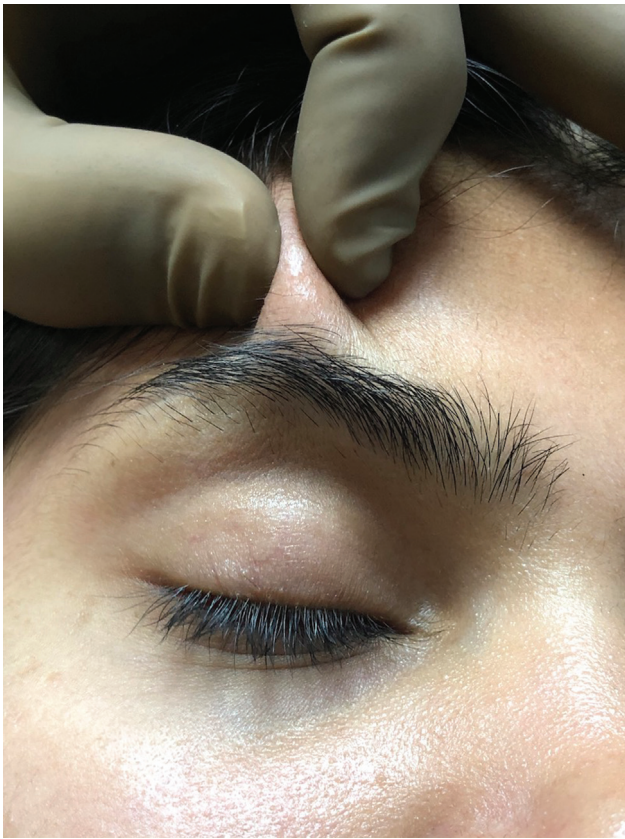

Fig. 3 The picture showing the “deep pinch” or “pinch and pull” maneuver in the forehead, with thumb and index finger.

In a study on temporal fossa, the depth of the skin pinch was tested with a gentle pinch and a deep pinch. Skin from the pinched area was cut in both situations to determine if there was any difference in the movement of tissue layers, based on the strength of the pinch applied. It was found that when the cutting was done on the gentle pinch, only skin and the subcutaneous fat layer were cut with no damage to the superficial temporal fascia (STF) and STA. However, when the pinch was performed deeply with more pressure, the STF was found cut in addition to skin and subcutaneous fat, and the deep temporal fascia (DTF) was exposed. The exposed DTF was not damaged at all.³

Filler injection in the forehead is technically challenging. As filler injection in this area is a blind procedure, it is difficult to assess whether the needle or cannula is in the subcutaneous plane or has reached up to the periosteum. When a pinch of tissue layers is made, the superficial mobile tissue layers separate from the fixed deeper tissue layers before being pulled up. The risk of intra-arterial injection can be reduced by pinching/tenting the skin to provide more space in the avascular glide plane layer.²⁴

The tissue layers behave similarly in the forehead, another anatomical area in the upper face for filler injections besides the temporal fossa. Based on the pinch anatomy, some conclusions can be drawn about the behavior of tissues in the forehead. With a gentle pinch in the forehead, only skin and subcutaneous fat layers are present in a pinch. However, when a deep pinch is applied on the forehead and tissue layers are pulled up (“pinch and pull”), the galea aponeurotica layer with the frontal muscle bellies gets separated from the periosteum. This separation happens at the level of the loose areolar tissue layer between the galea and periosteum. Like the temple, the loose areolar tissue layer acts as a glide plane in the forehead also.^{25,26} Movement of the eyebrow is also facilitated by loose areolar tissue and galea fat pads under the frontalis muscle which forms a glide plane for reversible relative movement of superficial layers over deeper tissue.²⁷

The “pinch and pull” maneuver lifts the superficial mobile tissue layers away from the fixed layer in depth, that is, the periosteum covering the bone. As the blood vessels in the upper two-thirds of the forehead are pulled up with a “pinch and pull” maneuver, injecting the filler in the deeper layer would be much safer. As the blood vessels, that is, SO artery and ST artery, in the lower one-third of forehead and brow region, are not pulled up with “pinch and pull” maneuver, injecting the filler in the deeper layer in the lower third would be dangerous, and superficial filler injection plane is preferred, especially in the brow region.

Fillers in the forehead are indicated for overtly concave appearance.²⁸ The popular method to inject the forehead is with a needle or cannula in the supraperiosteal plane.²⁹ In the forehead, the plane between the galea and periosteum

Table 1 Table showing the summary of changes in pinch anatomy with “gentle pinch” and “deep pinch” in the forehead region

	Gentle pinch	Deep pinch/pinch and pull
Tissue layers involved	It bunches up skin and subcutaneous fat with minimal movement of galeal layer	It separates skin, subcutaneous fat, galea layers from the periosteum
Vascular relation	Frontal branch of STA, branches of SO/ST arteries run in a plane in the superficial part of Galea just deeper to the pinched tissue making it a no-go danger zone in the upper two-thirds of forehead	Relatively avascular loose areolar tissue plane lies deeper to the pinched tissue creating more space in it for cannula or the needle bevel, the vessels being pulled up in the pinched tissue
Injection advice	This plane is ideal for superficial placement of skin rejuvenating fillers. The plane deeper to this pinch is a “No-Go zone” for filler injections in the upper two-thirds of the forehead	The plane deeper to this pinch is ideal, safest plane for filler injection in upper two-thirds of forehead

Abbreviations: SO, supraorbital; ST, supratrochlear; STA, superficial temporal artery.

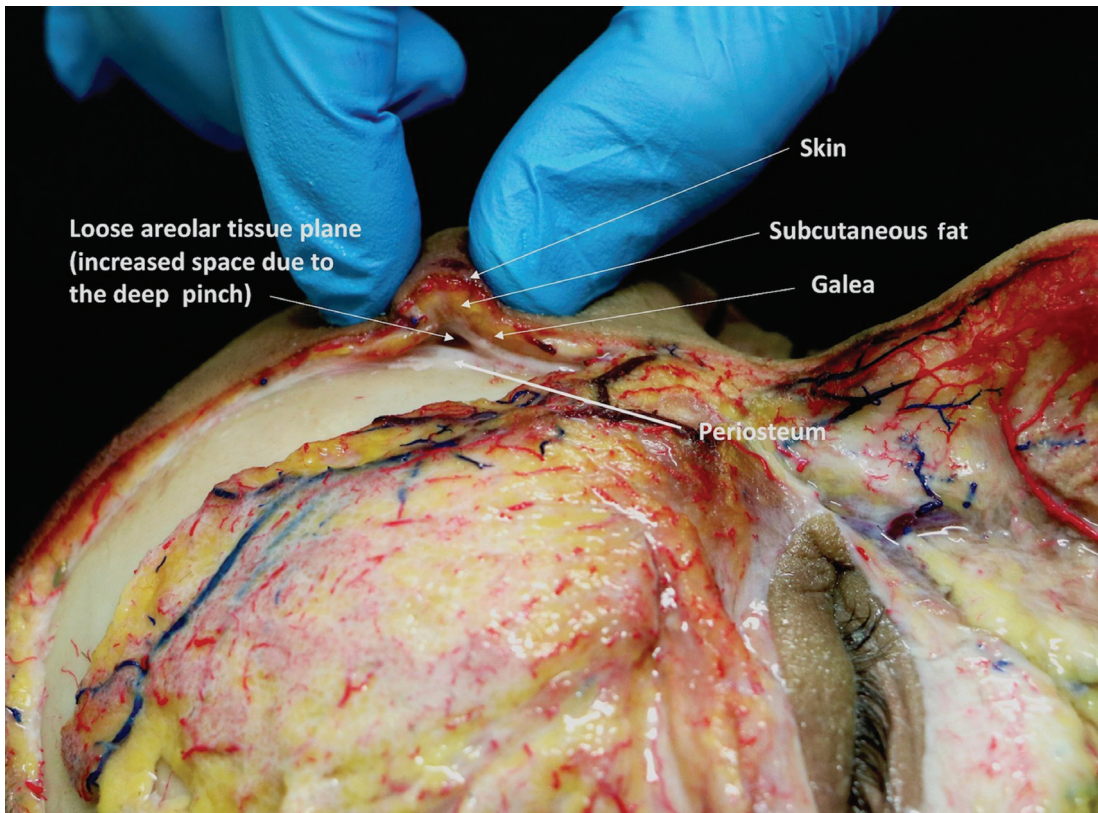


Fig. 4 The cadaver dissection showing “pinch anatomy” of the forehead with the superficial mobile layers gliding over the periosteum to bunch up, creating more space for the bevel of a needle during filler injection in the loose areolar tissue layer (cadaver dissection image contributed by author K.M.K.).

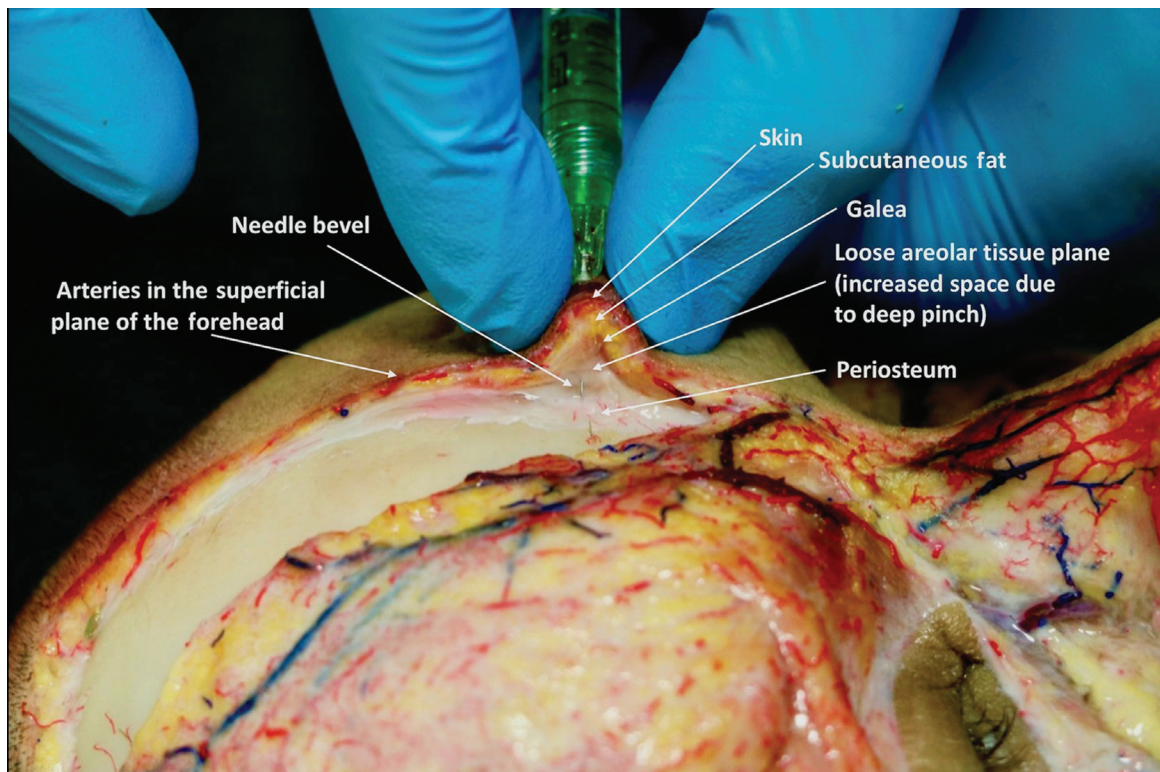


Fig. 5 The cadaver dissection showing “pinch anatomy” of forehead during a deep pinch, creating more space so that complete bevel of the needle is present in the relatively avascular, loose areolar tissue layer during filler injection (cadaver dissection image contributed by author K.M.K.).

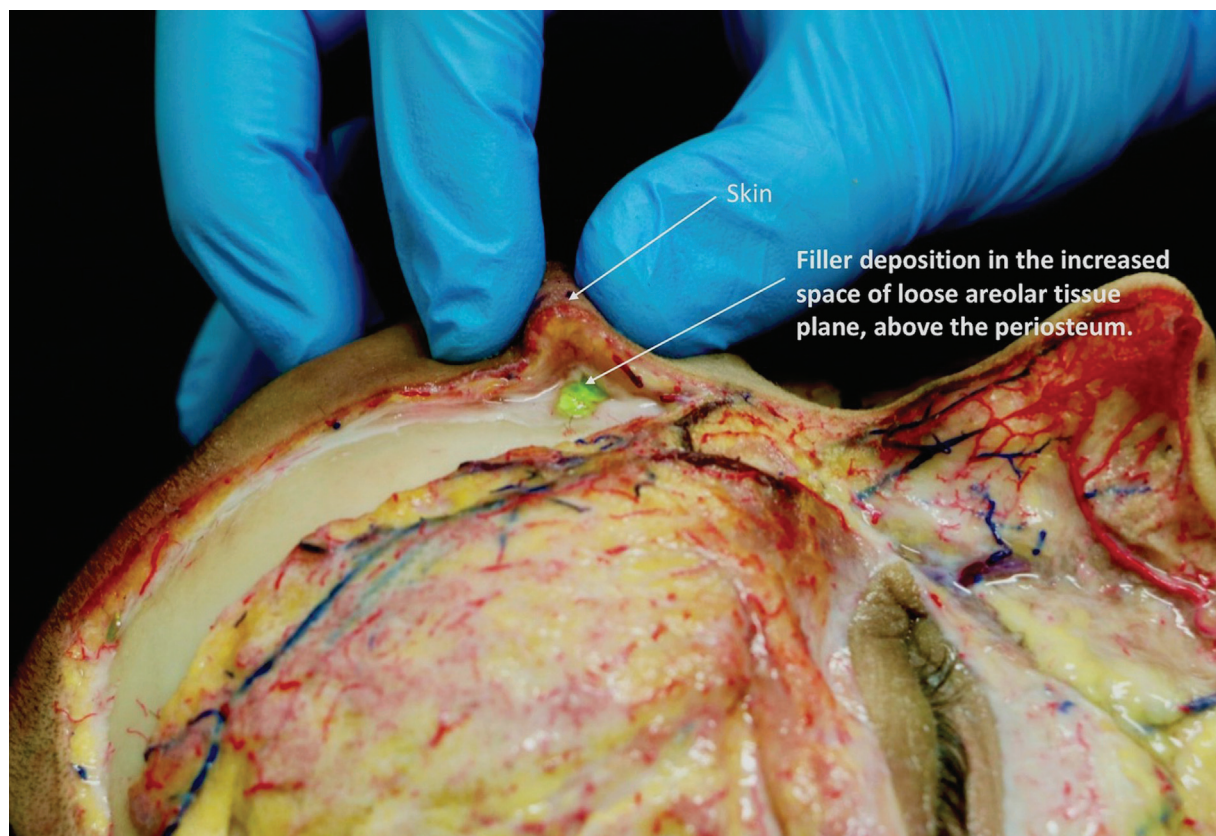


Fig. 6 The cadaver dissection showing the location of filler material (green color) in the relatively avascular, loose areolar tissue layer on the periosteal layer of the forehead when a deep pinch is used to create more space in this layer (cadaver dissection image contributed by author K.M.K.).

provides a relatively avascular plane.³⁰ Injecting fillers in this plane can be a daunting task due to thin tissue layers in the forehead.^{31,32} The concept of “pinch anatomy” can help in enhancing injection skills in the forehead region also. The important vessels in the forehead should be considered before filler injection. The frontal branch of the superficial temporal artery lies superficially on the surface of the galea.³³ The loose areolar tissue plane between the galea and periosteum has no major artery and is best suited for the forehead filler injection.³⁴ The “pinch and pull” maneuver in the forehead lifts the mobile tissue layers, that is, skin, subcutaneous fat, and galea, creating an injection space in the loose areolar tissue plane in the forehead. This simple maneuver with the nondominant hand creates a space in the loose areolar tissue layer of the forehead for safe filler injection. Another advantage of the injection with the “pinch and pull” technique is that the surface irregularities are less visible, and filler spreads easily in this plane after injection. Pinching or tenting the skin provides more space deeper to superficial branches of main arteries by pulling them away from the underlying safe plane.³⁵

During the “pinch and pull” maneuver, the potential space in the loose areolar tissue plane increases. The bevel of the needle is more likely to be entirely in the loose areolar tissue due to an increase in space created by the “pinch and pull” maneuver (—Figs. 5 and 6). The complication caused by the presence of bevel in multiple tissue

layers²⁹ can be mitigated to a large extent by the “pinch and pull,” potentially providing more free space for the entire bevel of the needle to fit.

Conclusion

Using the nondominant hand to make a pinch or a “pinch and pull” maneuver can help reach the correct tissue plane. Knowing this change in the anatomy of tissue layers during the pinched state can help filler injection in the correct tissue plane of the forehead. Thus, “pinch anatomy” can act as an injection guide for filler injection and possibly help avoid an inadvertent injection in the blood vessels. Hence the knowledge of the pinch anatomy can potentially make a filler procedure safer, more precise, and effective in the temple and forehead regions.

Patient Consent

For this study, informed consent of the model used for the pinch anatomy photographs of the forehead has been taken.

Funding

None.

Conflict of Interest

None declared.

References

- 1 Betemps JB, Marchetti F, Lim T, et al. Projection capacity assessment of hyaluronic acid fillers. *Plast Aesthetic Res* 2018;5(06):19
- 2 Kumar N, Rahman E. Global need-assessment for a postgraduate program on non-surgical facial aesthetics. *Aesthet Surg J* 2021;41(04):501–510
- 3 Kim B, Oh S, Jung W. *The Art and Science of Thread Lifting- Based on Pinch Anatomy*. Singapore: Springer Nature Singapore Pte Ltd; 2019
- 4 Hong G, Oh S, Kim B, Lee Y. *The Art and Science of Filler Injection: Based on Clinical Anatomy and the Pinch Technique*. Singapore: Springer Nature Singapore Pte Ltd; 2020
- 5 Oh SM, Kim BC, Jung W. Changes in the layers of the temple during pinch manipulation: implications for thread lifting. *Dermatol Surg* 2019;45(08):1063–1068
- 6 Surek C, Beut J, Stephens R, Lamb J, Jelks G. Volumizing viaducts of the midface: defining the Beut techniques. *Aesthet Surg J* 2015;35(02):121–134
- 7 Kühne U, Imhof M. Treatment of the ageing hand with dermal fillers. *J Cutan Aesthet Surg* 2012;5(03):163–169
- 8 Goldberg DJ, ed. *Dermal fillers*. In: *Aesthetic Dermatology*. vol. 4. New York, NY: Karger; 2018
- 9 Chayen D, Nathan H. Anatomical observations on the subgaleotic fascia of the scalp. *Acta Anat (Basel)* 1974;87(03):427–432
- 10 Sykes JM, Cotofana S, Trevidic P, et al. Upper face: clinical anatomy and regional approaches with injectable fillers. *Plast Reconstr Surg* 2015;136(05, suppl):204S–218S
- 11 Sykes J, Allak A, Palhazi P, Cotofana S. *Anatomy for facial fillers. The Skin Surface and Beyond*. 2018;4:10–26
- 12 Newman J, Costantino P, Moche J. The use of unilateral pericranial flaps for the closure of difficult medial orbital and upper lateral nasal defects. *Skull Base* 2003;13(04):205–209
- 13 Kleintjes WG. Forehead anatomy: arterial variations and venous link of the midline forehead flap. *J Plast Reconstr Aesthet Surg* 2007;60(06):593–606
- 14 Souza C. Reconstruction of large scalp and forehead defects following tumor resection : personal strategy and experience – analysis of 25 cases. *Rev Bras Cir Plást* 2012;27(02):227–237
- 15 Fang M, Rahman E, Kapoor KM. Managing complications of submental artery involvement after hyaluronic acid filler injection in chin region. *Plast Reconstr Surg Glob Open* 2018;6(05):e1789
- 16 Loh KTD, Phoon YS, Phua V, Kapoor KM. Successfully managing impending skin necrosis following hyaluronic acid filler injection, using high-dose pulsed hyaluronidase. *Plast Reconstr Surg Glob Open* 2018;6(02):e1639
- 17 Chatrath V, Banerjee PS, Goodman GJ, Rahman E. Soft-tissue filler-associated blindness: a systematic review of case reports and case series. *Plast Reconstr Surg Glob Open* 2019;7(04):e2173
- 18 Wibowo A, Kapoor KM, Philipp-Dormston WG. Reversal of post-filler vision loss and skin ischaemia with high-dose pulsed hyaluronidase injections. *Aesthetic Plast Surg* 2019;43(05):1337–1344
- 19 Kapoor KM, Kapoor P, Heydenrych I, Bertossi D. Vision loss associated with hyaluronic acid fillers: a systematic review of literature. *Aesthetic Plast Surg* 2020;44(03):929–944
- 20 Kapoor KM, Bertossi D, Li CQ, Saputra DI, Heydenrych I, Yavuzer R. A systematic literature review of the middle temporal vein anatomy: ‘venous danger zone’ in temporal fossa for filler injections. *Aesthetic Plast Surg* 2020;44(05):1803–1810
- 21 Salti G, Rauso R. Facial rejuvenation with fillers: the dual plane technique. *J Cutan Aesthet Surg* 2015;8(03):127–133
- 22 Kumar N, Rahman E. Effectiveness of teaching facial anatomy through cadaver dissection on aesthetic physicians’ knowledge. *Adv Med Educ Pract* 2017;8:475–480
- 23 Heydenrych I, Kapoor KM, De Boule K, et al. A 10-point plan for avoiding hyaluronic acid dermal filler-related complications during facial aesthetic procedures and algorithms for management. *Clin Cosmet Investig Dermatol* 2018;11:603–611
- 24 Bailey SH, Cohen JL, Kenkel JM. Etiology, prevention, and treatment of dermal filler complications. *Aesthet Surg J* 2011;31(01):110–121
- 25 Lee J-S, Hwang S-M, Jung Y-H, et al. Clinical characteristics of the forehead lipoma. *Arch Craniofac Surg* 2014;15(03):117–120
- 26 Salasche SJ, McCollough ML, Angeloni VL, Grabski WJ. Frontalis-associated lipoma of the forehead. *J Am Acad Dermatol* 1989;20(03):462–468
- 27 Stuzin JM, Baker TJ, Gordon HL. The relationship of the superficial and deep facial fascias: relevance to rhytidectomy and aging. *Plast Reconstr Surg* 1992;89(03):441–449, discussion 450–451
- 28 Bertossi D, Lanaro L, Dell’Acqua I, Albanese M, Malchiodi L, Nocini PF. Injectable profiloplasty: forehead, nose, lips, and chin filler treatment. *J Cosmet Dermatol* 2019;18(04):976–984
- 29 Pavicic T, Frank K, Erlbacher K, et al. Precision in dermal filling: a comparison between needle and cannula when using soft tissue fillers. *J Drugs Dermatol* 2017;16(09):866–872
- 30 Potparić Z, Fukuta K, Colen LB, Jackson IT, Carraway JH. Galeo-pericranial flaps in the forehead: a study of blood supply and volumes. *Br J Plast Surg* 1996;49(08):519–528
- 31 Choi Y-J, Lee K-W, Gil Y-C, Hu K-S, Kim H-J. Ultrasonographic analyses of the forehead region for injectable treatments. *Ultrasound Med Biol* 2019;45(10):2641–2648
- 32 Chao YYY. Saline hydrodissection: a novel technique for the injection of calcium hydroxylapatite fillers in the forehead. *Dermatol Surg* 2018;44(01):133–136
- 33 Hotta TA. Understanding the anatomy of the upper face when providing aesthetic injection treatments. *Plast Surg Nurs* 2016;36(03):104–109
- 34 Wanick FBF, Alexandre DC, Issa MCA. Hyaluronic acid filler for forehead, temporal, and periorbicular regions.- In: *Botulinum Toxins, Fillers and Related Substances*. In: Issa MCA, Tamura B, eds.. Switzerland: Cham Springer International Publishing; 2019:241–257
- 35 Brennan C. Avoiding the “danger zones” when injecting dermal fillers and volume enhancers. *Plast Surg Nurs* 2014;34(03):108–111, quiz 112–113