

Novel technique to repair leaked biliary stone extraction balloon

Accessories used for biliary stone extraction include balloon catheters and wire baskets. The stone extraction balloon consists of a catheter with a soft, pliant balloon located at the tip [1]. Although these balloons are meant for single use, in developing countries these balloons are reused after sterilization with ethylene oxide. Mostly these balloons get punctured by the sharp edges of stones and leak from the proximal end, or sometimes they burst due to excessive pressure applied during stone extraction.

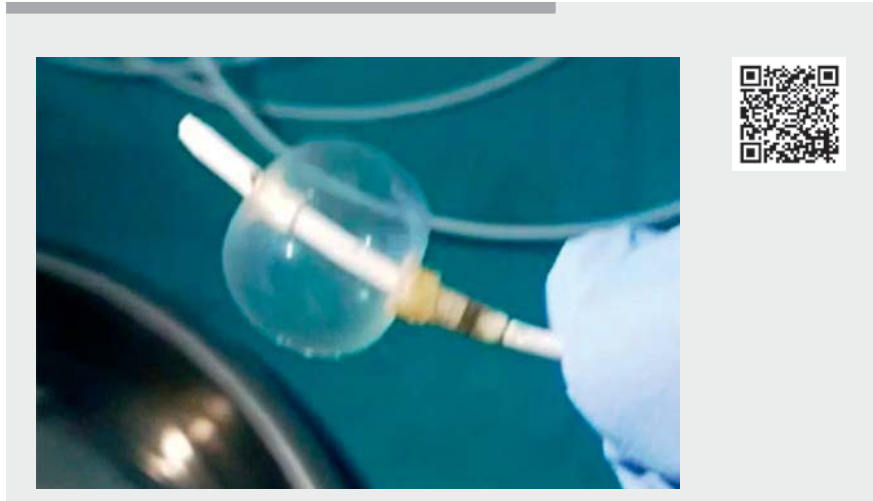
We present a simple method to repair leaked balloons and to reuse them in case of emergency and in centers with limited resources (► **Video 1**).

METHOD: Locate the leakage site by immersing balloon 1 in water and inflating it. During inflation, bubbles will be seen coming from the leakage site (► **Fig. 1**). After locating the point of leakage, dry it with a piece of gauze. Take another damaged balloon (balloon 2) and locate the area with an intact latex sheath (► **Fig. 2**). Cut balloon 2 at one end so as to obtain an intact ring of latex sheath (► **Fig. 3**). Now put the ring over balloon 1. Use forceps to place it exactly over the leaking area. Apply instant adhesive and fix the ring over the balloon 1 (► **Fig. 4**). Let it dry. Check the balloon for any leakage. Sterilize it with ethylene oxide. It can now be used for stone extraction (► **Fig. 5**).

Endoscopy_UCTN_Code_TTT_1AR_2AH

Competing interests

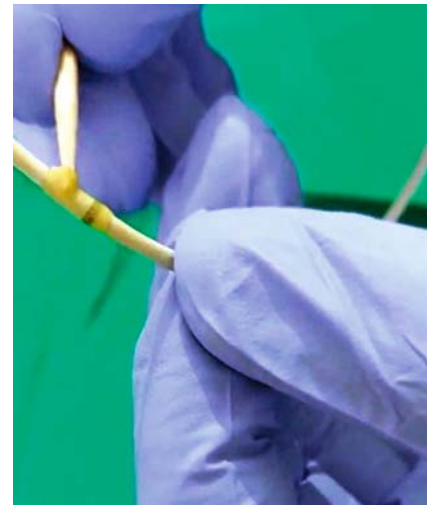
The authors declare that they have no conflict of interest.



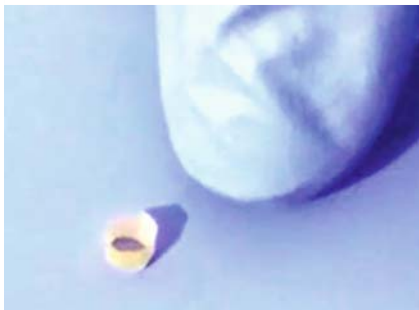► **Video 1** A novel technique to repair leaked biliary stone extraction balloon.



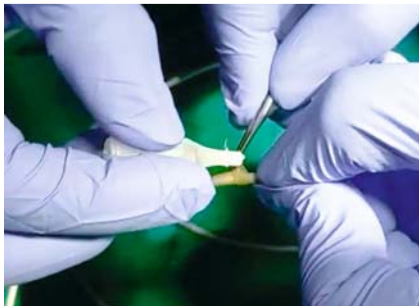► **Fig. 1** Locate the leakage site in balloon 1.



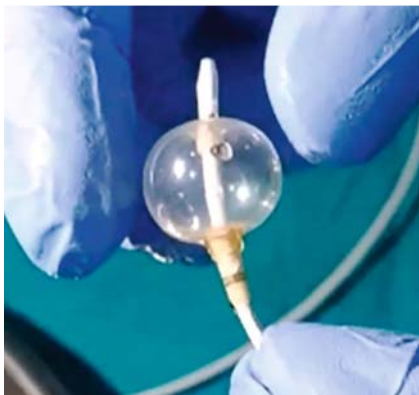► **Fig. 2** Locate the site with intact latex sheath in balloon 2.



► **Fig. 3** Latex ring.




► **Fig. 4** Paste the ring over the leakage site.



► **Fig. 5** Repaired balloon.

The authors

Sachin Dev Munjal , **Yogita Munjal**
Department of Gastroenterology, Gastro Liver
Care and Saksham Hospital, Saharanpur, Uttar
Pradesh, India

Corresponding author

Sachin Dev Munjal, MD
Department of Gastroenterology, Gastro
Liver Care and Saksham Hospital,
Saharanpur, 247001 Uttar Pradesh, India
gastro.liver.help@gmail.com

Reference

- [1] Manes G, Paspatis G, Aabakken L et al. Endoscopic management of common bile duct stones: European Society of Gastrointestinal Endoscopy (ESGE) guideline. *Endoscopy* 2019; 51: 472–491

Bibliography

Endoscopy 2022; 54: E658–E659
DOI 10.1055/a-1732-7356
ISSN 0013-726X
published online 15.2.2022
© 2022. Thieme. All rights reserved.
Georg Thieme Verlag KG, Rüdigerstraße 14,
70469 Stuttgart, Germany

ENDOSCOPY E-VIDEOS
<https://eref.thieme.de/e-videos>



Endoscopy E-Videos is an open access online section, reporting on interesting cases and new techniques in gastroenterological endoscopy. All papers include a high quality video and all contributions are freely accessible online. Processing charges apply (currently EUR 375), discounts and waivers acc. to HINARI are available.

This section has its own submission website at
<https://mc.manuscriptcentral.com/e-videos>