

# Four-Year Efficacy and Safety of iTrack Ab-interno Canaloplasty as a Standalone Procedure and Combined with Cataract Surgery in Open-Angle Glaucoma

## iTrack-Ab-interno-Kanaloplastik als Stand-alone-Eingriff und kombiniert mit Kataraktoperation bei Offenwinkelglaukom: 4-Jahres-Ergebnisse und Sicherheitsprofil

### Authors

Norbert Koerber, Simon Ondrejka

### Affiliation

Augenentrum Köln, Köln, Germany

### Key words

intraocular pressure, ab-interno canaloplasty, MIGS, canaloplasty, minimally invasive glaucoma surgery, open-angle glaucoma

### Schlüsselwörter

Augeninnendruck, Kanaloplastik ab interno, MIGS, Kanaloplastik, Offenwinkelglaukom

received 29.4.2021  
accepted 21.12.2021  
published online 14.4.2022

### Bibliography

Klin Monatsbl Augenheilkd 2023; 240: 1394–1404

DOI 10.1055/a-1737-4149

ISSN 0023-2165

© 2022, Thieme. All rights reserved.

Georg Thieme Verlag KG, Rüdigerstraße 14,  
70469 Stuttgart, Germany

### Correspondence

Prof. Norbert Koerber  
Augenentrum Köln  
Josefstraße 14, 51143 Köln, Germany  
Phone: +49 22 03 10 1970, Fax: +49 22 03 10 1972  
N.Koerber@gmx.de

### ABSTRACT

**Purpose** To evaluate the long-term effectiveness of ab-interno canaloplasty (ABiC), performed with the iTrack microcatheter (Nova Eye Medical, Fremont, CA, USA), in reducing intraocular pressure (IOP) as well as the number of required glaucoma medications in patients with open-angle glaucoma (OAG).

**Methods** In this retrospective single-center consecutive case series, 27 eyes of 21 patients (mean age  $77.3 \pm 5.8$  years) were treated with ABiC performed as a standalone procedure or combined with cataract surgery. Patients with uncontrolled IOP OAG or controlled IOP ( $\leq 18$  mmHg) OAG with intolerance to medications or lack of compliance were included. Patients were followed for up to 4 years following the procedure. The iTrack microcatheter was used to perform a 360-degree circumferential intubation and viscodilation of Schlemm's canal. Primary efficacy endpoints included IOP and the number of glaucoma medications at 12, 24, 36, and 48 months after surgery.

**Results** In all eyes, mean IOP and number of glaucoma medications were significantly reduced from  $19.8 \pm 5.2$  mmHg and  $1.9 \pm 1.00$  at baseline to  $14.6 \pm 3$  mmHg and  $0.9 \pm 0.8$ , respectively, at the 48-month follow-up ( $p < 0.001$ ). IOP was stable from 12 months to 48 months ( $p > 0.005$ ). After 48 months, 39% of the eyes required zero medications compared to 3.7% at baseline, and 72.2% of eyes required only one medication or less. Of all eyes, 77.8% recorded an IOP  $\leq 17$  mmHg. No serious complications were recorded.

**Conclusion** iTrack ABiC performed as a standalone procedure or in combination with cataract surgery significantly reduced IOP and number of medications in patients with OAG up to 4 years after the procedure.

### ZUSAMMENFASSUNG

**Zweck** Ziel war die Ermittlung der Langzeitwirksamkeit der Ab-interno-Kanaloplastik (ABiC) mittels iTrack-Katheter (Nova Eye Medical, Fremont, CA, USA) in Patienten mit primärem Offenwinkelglaukom (POAG) durch die Senkung des Augeninnendrucks (IOP) und der Zahl der benötigten Glaukommedikamente.

**Methoden** In dieser retrospektiven, monozentrischen konsekutiven Fallserie wurden 27 Augen von 21 Patienten (Durchschnittsalter:  $77,3 \pm 5,8$  Jahre) mit ABiC als Stand-alone-Ein-

griff oder in Kombination mit einer Kataraktoperation behandelt. Einbezogen wurden Patienten mit kontrolliertem IOP ( $\leq 18$  mmHg) und unkontrolliertem IOP ( $> 18$  mmHg). Aufgrund von Medikamentenunverträglichkeiten oder mangelnder Compliance wurde bei Patienten mit kontrolliertem IOP die ABiC zur Minimierung der erforderlichen Medikamente durchgeführt und sie wurden anschließend bis zu 4 Jahre lang beobachtet. Der iTrack-Mikrokatheter wurde zur 360°-zirkumferenziellen Intubation und Viskodilatation des Schlemm-Kanals verwendet. Primäre Wirksamkeitsendpunkte der Studie waren der IOP und die Glaukommedikamentenzahl bis 12, 24, 36 und 48 Monate nach dem Eingriff.

**Ergebnisse** Bei allen Augen wurden der mittlere IOP und die Glaukommedikamentenzahl signifikant von  $19,8 \pm 5,2$  mmHg

und  $1,9 \pm 1$  zu Beginn der Studie jeweils auf  $14,6 \pm 3$  mmHg und  $0,9 \pm 0,8$  bei der 48-monatigen Nachuntersuchung reduziert ( $p < 0,001$ ). Der IOP und die Medikamentenzahl waren von 12 bis 48 Monaten stabil ( $p > 0,005$ ). Nach 48 Monaten benötigten 39% der Augen keine Medikamente, verglichen mit 3,7% zu Studienbeginn, und 72,2% der Augen benötigten nur ein Medikament oder weniger. 77,8% der Augen wiesen einen IOP  $\leq 17$  mmHg auf. Es wurden keine ernsthaften Komplikationen verzeichnet.

**Schlussfolgerung** Als Stand-alone-Eingriff oder in Kombination mit einer Kataraktoperation reduzierte die iTrack-ab-interno-Kanaloplastik signifikant den IOP und die Medikamentenzahl bei Patienten mit POAG bis zu 4 Jahre nach dem Eingriff.

## Introduction

Glaucoma is the leading cause of blindness worldwide, with an estimated prevalence of 76 million people in 2020 and is predicted to affect around 112 million people by 2040 [1]. The most common type of glaucoma is open-angle glaucoma (OAG) [1] and its primary treatment involves the reduction of intraocular pressure (IOP), which has been shown to be the most relevant and variable risk factor for progression of glaucomatous optic neuropathy as well as field loss [2]. The traditional treatment algorithm in OAG consists of topical antiglaucoma medications, followed by laser treatment (selective laser trabeculoplasty or SLT) and penetrating filtration surgeries such as trabeculectomy when IOP is no longer controlled with topical therapy [3].

Although a wide variety of effective topical medications are available, poor patient compliance and intolerance are common and can lead to irreversible disease progression [4, 5]. Potential barriers to adherence include difficulty administering eye drops, forgetfulness, intolerance, and cost of the medications [6]. Furthermore, topical medications are associated with a variety of side effects such as ocular surface irritation, blurred vision, pain, bronchoconstriction, and cardiovascular effect [7]. For example, benzalkonium chloride, a preservative common to most topical medications, can cause apoptosis in the endothelial cells and along the trabecular columns [8] as much as the disease itself. This can lead to the fusion of the trabecular meshwork, with the collapse of Schlemm's canal, thereby compromising the function of the natural outflow pathway and limiting the viability of future treatments [9]. For these reasons, patients with mild to moderate glaucoma may benefit from a reduction in the number of medications required to control IOP.

While filtering surgeries are clinically effective for managing glaucoma [10], these procedures are associated with a high rate of complications, including hypotony, failure, and bleb-related infections [11].

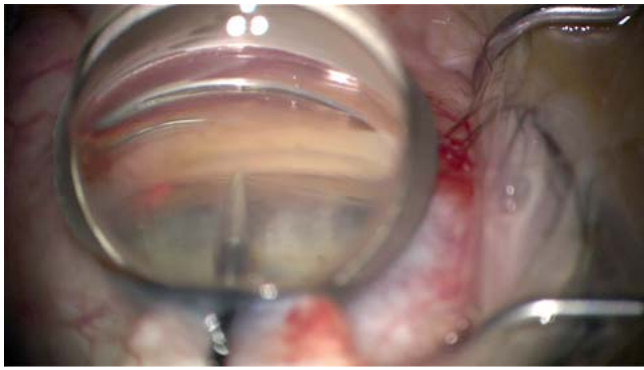
Over the last decade, minimally invasive glaucoma surgery (MIGS) has been developed to fill the treatment gap between topical therapy and invasive glaucoma surgery [3, 12]. In comparison to filtration surgery, MIGS provides several advantages such as minimal disruption to the eye's anatomy and physiology and is

therefore associated with an improved safety profile and rapid postsurgical recovery [13]. These advantages have supported the adoption of MIGS in today's glaucoma practice. Although MIGS was originally designed to be performed in combination with cataract surgery, it has since evolved and some MIGS procedures now offer the possibility to be performed as a standalone surgery.

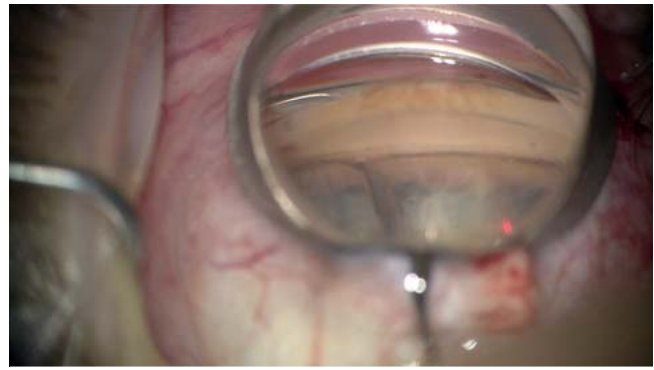
Canaloplasty offers a comprehensive approach by addressing all aspects of potential outflow resistance in the trabecular meshwork, Schlemm's canal, and the collector channel systems [14]. During canaloplasty, a microcatheter is inserted into Schlemm's canal over the entire 360 degrees. The microcatheter is withdrawn whilst injecting an ophthalmic viscoelastic device (OVD) to dilate the full circumference of the canal and a suture is left tensioned in Schlemm's canal.

Ab-interno canaloplasty (ABiC) is a development of the traditional ab-externo canaloplasty that does not require any disruption of the conjunctiva. The procedure has the same proposed mechanism of action as traditional ab-externo canaloplasty by breaking obstructions and adhesions in the canal and restoring the physiological aqueous outflow pathway but does not employ a tensioning suture. During the ab-interno procedure, the iTrack microcatheter is inserted through either a clear corneal or a limbal micro-incision. This has the added advantage of preserving the conjunctiva for future glaucoma treatments, despite a reduced efficacy when compared to the ab-externo technique, which is the reason that the ab-interno is often performed on mild to moderate glaucoma patients. It can be performed as a standalone procedure or in combination with cataract surgery. Previous studies have reported good efficacy in terms of IOP reduction and a reduced need for glaucoma medications whilst reporting low risks of complications up to 12–24 months after surgery [15–17].

The aim of this study was to investigate the efficacy and safety over a 4-year period of ABiC using the iTrack microcatheter (Nova Eye Medical, Fremont, CA, USA) performed as a standalone procedure or in conjunction with cataract surgery. The primary clinical outcomes were a reduction in IOP and glaucoma medications. Additional outcomes were visual field and visual acuity. Safety data was obtained at all time points.



► **Fig. 1** The iTrack microcatheter intubates and viscodilates the entire 360 degrees of Schlemm's canal. The red dot is the illuminated tip of the microcatheter in the trabecular meshwork.



► **Fig. 2** The 24 G needle enters the trabecular meshwork with a 20° bent tip.

## Methods

### Study design

This was a single center, retrospective, consecutive case series analysis of 27 eyes that were treated with an ABiC between the 28th of October 2014 and the 24th of October 2016. All surgeries were undertaken at the Augentrum Köln-Porz, Germany, and were performed by a single surgeon (N.K.). The study was conducted according to the principles stated in the Declaration of Helsinki and all patients provided written informed consent.

### Patient selection

All patients aged 18 years or older with a diagnosis of either uncontrolled or controlled OAG were eligible for inclusion. Controlled IOP was defined as an IOP equal to or less than 18 mmHg. Cases of pseudoexfoliative glaucoma (PEX) due to progression despite treatment were also eligible for inclusion. Eyes with secondary forms of glaucoma such as those with neovascular disease, uveitis, peripheral anterior synechiae, angle closure, narrow-angle glaucoma, or traumatic glaucoma were excluded.

Patients were allocated to undergo ABiC in combination with phacoemulsification if they presented with a cataract.

### Clinical examinations

Preoperative and postoperative assessments included medication use, IOP, gonioscopy, slit lamp, and fundus examinations. IOP was measured using Goldman applanation tonometry and was the average of three measurements at each time point. Data was collected at baseline, and 12, 24, 36, and 48 months after surgery. Best-corrected distance visual acuity (CDVA) and visual field were recorded at baseline and at the last available follow-up. Visual field was measured with a Humphrey machine (Carl Zeiss Meditec, Jena, Germany) using the 24/2 testing strategy. We excluded patients with more than 30% either false positives, false negatives, or fixation losses. Visual field deterioration was defined by loss of the mean deviation (MD).

## Surgical procedure

All eyes underwent ABiC under local anesthesia consisting of a retrobulbar injection of carbocaine and lidocaine. The iTrack 250-micron canaloplasty microcatheter with a fiber optic light and lumen was passed through a clear corneal paracentesis and then through a small longitudinal opening in the trabecular meshwork to circumferentially viscodilate and intubate Schlemm's canal (► **Fig. 1**). The meshwork opening was made with a 24 G needle with a 20° bent tip (► **Fig. 2**). Surgeon-controlled delivery of a high-molecular weight OVD (Healon GV, Johnson & Johnson, New Brunswick, NJ, USA) during withdrawal of the microcatheter allowed for the compressed tissue planes of the trabecular meshwork to separate, and any herniated inner wall tissue to withdraw from the collector channels (see ► **Video 1** and **2**). In combined cases, phacoemulsification and IOL implantation were performed prior to the ABiC procedure. At the end of the procedure, the OVD was removed from the anterior chamber, and the pupil was constricted using Miochol. A subconjunctival dose of gentamicin and dexamethasone was then applied.

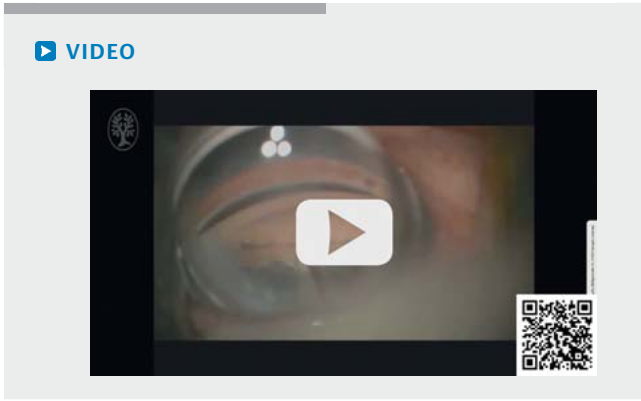
Postoperatively, patients received combined drops of gentamicin and dexamethasone 4 times daily for 1 week, followed by diclofenac drops 4 times daily for 1 month.

## Outcomes

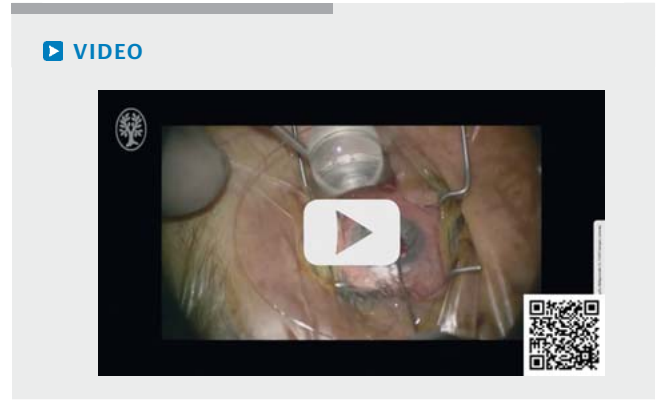
The primary efficacy outcomes were IOP and the number of glaucoma medications. Secondary efficacy outcomes were corrected distance visual acuity and visual field mean deviation. Safety data was obtained by recording intraoperative and postoperative complications.

## Statistics

Descriptive statistics (mean, standard deviation, and range) were used for IOP and number of medications at each visit. Comparative analysis between visits was performed using the repeated-measures ANOVA test followed by a post hoc Tukey test for multiple comparisons and nonparametric Friedman test followed by Wilcoxon signed-rank test for multiple comparisons. A p value of <0.05 was considered statistically significant and p values are indicated where applicable.



► **Video 1** The iTrack microcatheter intubates and viscodilates the entire 360 degrees of Schlemm's canal.



► **Video 2** The red dot is the illuminated tip of the microcatheter in the trabecular meshwork.

► **Table 1** Intraocular pressure (IOP) in mmHg at baseline and all postoperative visits.

All eyes	Baseline	12 M	24 M	36 M	48 M
Mean ± SD	19.85 ± 5.2	14.98 ± 2.6	15.58 ± 3.3	14.71 ± 3.8	14.56 ± 3.0
Min	13.00	10.00	8.00	7.00	10.00
Max	37.00	20.00	26.00	21.00	21.00
N (eyes)	27	26	25	21	18
Standalone	Baseline	12 M	24 M	36 M	48 M
	23.5 ± 9.26	17.67 ± 2.3	17.25 ± 7.37	16.33 ± 4.73	17.67 ± 4.16
Combined with phaco	Baseline	12 M	24 M	36 M	48 M
	19.22 ± 4.20	14.63 ± 2.51	15.27 ± 2.01	14.44 ± 3.73	13.93 ± 2.43

## Results

### Demographics and baseline characteristics

A total of 27 eyes from 21 patients met eligibility criteria and were enrolled in the study. Eleven eyes presented pseudoexfoliation syndrome. Mean age was  $77.3 \pm 5.8$  years, ranging from 66 to 90 years old. There were 11 females and 10 males.

Classification of glaucoma was performed with the Hodapp-Parrish grading system [18] as recommended by the European Glaucoma Society [19] and based on the MD measured using the Humphrey visual field scale. Baseline analysis showed that ten eyes (37.0%) were mild cases ( $< -6$  dB), nine eyes (33.3%) moderate cases (from 6 dB to 12 dB), and four eyes (14.8%) severe cases ( $> -12$  dB). Baseline visual field data was not available for four eyes (14.8%).

The majority of eyes, 23 out of 27 eyes (85%), were treated with ABiC combined with phacoemulsification and 4 eyes (15%) were treated with ABiC as a standalone procedure. Nine patients were lost to follow-up for the 48-month visit as they had returned to their referring ophthalmologist.

### Primary outcomes

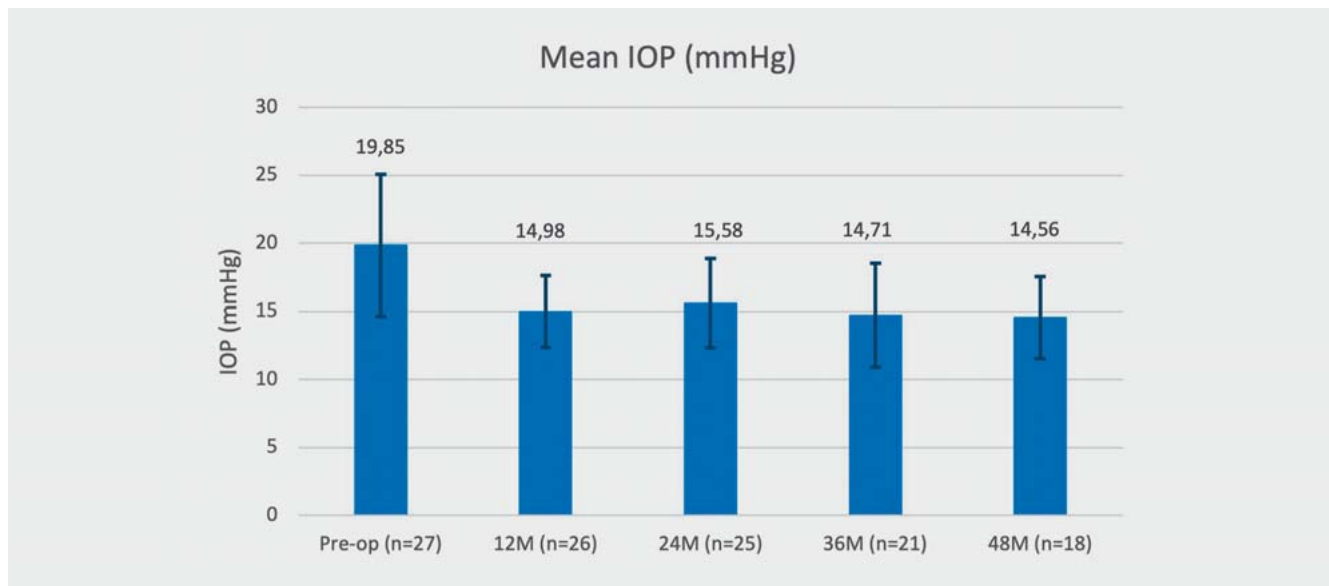
#### Intraocular pressure

Mean IOP at baseline and at each postoperative visit are presented in ► **Table 1** and **Fig. 3**. There was a statistically significant reduction in IOP between baseline ( $19.85 \pm 5.2$  mmHg;  $n = 27$ ) and all postoperative visits ( $p < 0.001$ ). At the 12-month follow-up, mean IOP was  $14.98 \pm 2.6$  mmHg, with no statistically significant difference between all postoperative visits ( $p = 0.35$ ) –  $15.58 \pm 3.3$  mmHg at 24 months,  $14.71 \pm 3.8$  mmHg at 36 months, and  $14.56 \pm 3.0$  at 48 months ( $n = 18$ ).

► **Table 2** shows the percentage of eyes with at least a 25% reduction in IOP and the percentage of eyes with a postoperative IOP of 15 mmHg or 17 mmHg.

#### Glaucoma medications

The mean number of glaucoma medications is presented in ► **Table 3** and **Fig. 4** and decreased from a preoperative average number of  $1.93 \pm 1.00$  ( $n = 27$ ) to  $0.89 \pm 0.83$  at 48 months ( $n = 18$ ). This reduction was determined to be statistically significant at all postoperative visits ( $p < 0.05$ ). The number of medications was stable between 12 and 24 months, with no statistically significant difference in number of medications ( $p \geq 0.135$ ) but then in-



► **Fig. 3** Mean IOP (mmHg) at baseline and postoperative visits. IOP was statistically significantly reduced between baseline and all postoperative visits ( $p < 0.001$ ). There was no statistically significant difference in IOP between all postoperative visits ( $p = 0.35$ ).

► **Table 2** Distribution of IOP success factors.

		At 12 M	At 24 M	At 36 M	At 48 M
% of eyes with:	≥ 25% reduction in IOP	46.2%	40.0%	57.1%	50.0%
	IOP ≤ 17 mmHg	80.8%	80.0%	71.4%	77.8%
	IOP ≤ 15 mmHg	53.8%	48.0%	57.1%	66.7%

► **Table 3** Number of medications at baseline and all postoperative visits.

	Baseline	12 M	24 M	36 M	48 M
Mean ± SD	1.93 ± 1.00	0.30 ± 0.54	0.40 ± 0.64	0.80 ± 0.83	0.89 ± 0.83
Median	1.00	0.00	0.00	1.00	1.00
IQR	2.00	0.50	1.00	1.25	1.75
Min	0	0	0	0	0
Max	4	2	2	2	2
N (eyes)	27	27	25	20	18

IQR: interquartile range

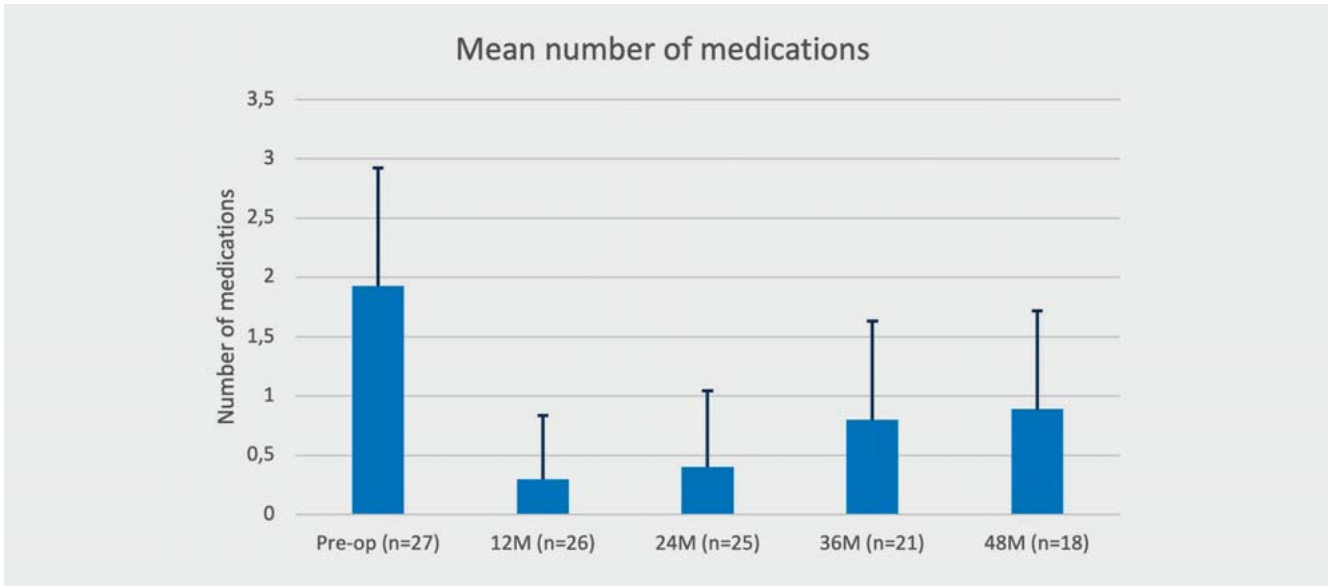
creased between 12 and 36 months ( $p = 0.030$ ) and 48 months ( $p = 0.048$ ).

At 12 months, 26 out of 27 eyes (96.3%) were on 1 medication ( $n = 6$ ) or 0 medications ( $n = 20$ ). The percentage of eyes on 1 medication or less decreased over time: 92% (23 out of 25 eyes) at 24 months, 75% at 36 months (15 out of 20 eyes), and 72.2% at 48 months (13 out of 18 eyes). All eyes were on two medications or less at all postoperative visits (► **Fig. 5**).

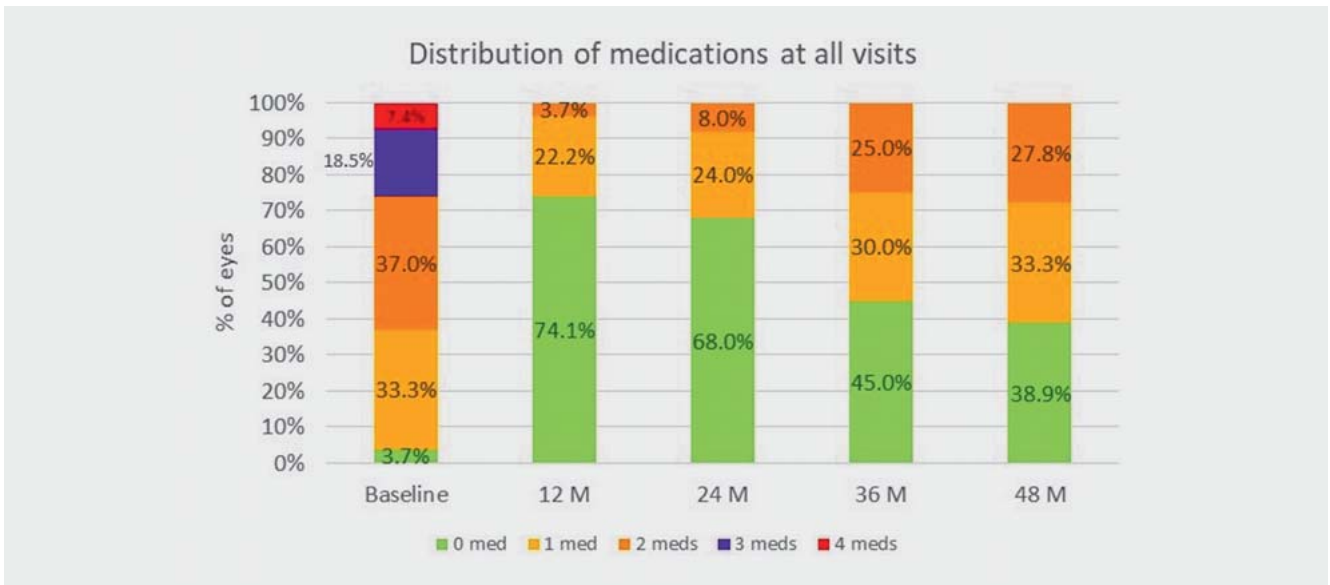
### Standalone vs. combined with cataract surgery

Twenty-three eyes received ABiC combined with cataract surgery and four eyes as a standalone procedure. In both groups, there was a reduction in IOP and medication burden at each time point compared to baseline.

The combined group had a baseline IOP (mmHg) of  $19.22 \pm 4.2$ , which decreased to  $14.63 \pm 2.5$ ,  $15.27 \pm 2$ ,  $14.44 \pm 3.7$ , and  $13.93 \pm 2.4$  at 12, 24, 36, and 48 months, respectively, with a net



► **Fig. 4** Mean number of medications at baseline and postoperative visits. Number of medications was statistically significantly reduced at all postoperative visits compared to baseline ( $p < 0.001$ ). The number of medications was stable between 12 and 48 months ( $p \geq 0.135$ ).



► **Fig. 5** Distribution of medications at all visits.

decrease of 5.28 mmHg. Medication use was reduced from  $1.9 \pm 1$  at baseline to  $0.3 \pm 0.6$ ,  $0.4 \pm 0.7$ ,  $0.9 \pm 0.9$  and  $0.9 \pm 0.8$  at 12, 24, 36, and 48 months, respectively.

For eyes in the standalone group, IOP was reduced from a baseline value of  $23.5 \pm 9$  to  $17.67 \pm 2.3$ ,  $17.25 \pm 7.4$ ,  $16.33 \pm 4.7$  and  $17.67 \pm 4.1$  ( $n = 3$ ) at 12, 24, 36, and 48 months, respectively, with a net decrease of 5.83 mmHg (► **Table 1**). Medication use was reduced from  $2 \pm 0.8$  at baseline to  $0.3 \pm 0.5$ ,  $0.3 \pm 0.7$ ,  $0.3 \pm 0.7$  and  $1 \pm 0.9$  at 12, 24, 36, and 48 months, respectively. One of the 4 eyes in the standalone group presented with pseudoexfolia-

tion syndrome and had a preoperative IOP of 37 mmHg, which reduced to 21 mmHg at 48 months. The other 2 eyes in this groups that reached the 48-month follow-up showed a reduction in IOP of a minimum of 3 mmHg at 48 months.

### Reducing the medication burden in cases of controlled glaucoma

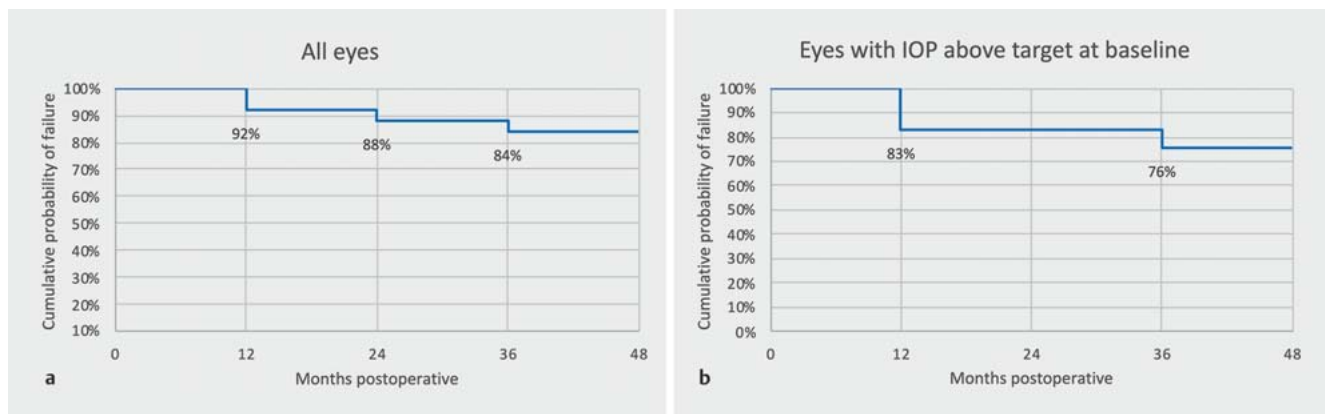
Patients who had a baseline IOP equal to or lower than 18 mmHg recorded a mean number of medications of  $1.77 \pm 0.93$  at baseline. In this group, the number of medications administered in



► **Table 4** Number of medications for group  $\leq 18$  mmHg and  $> 18$  mmHg.

	Number of medications $\leq 18$ mmHg and $> 18$ mmHg					
	Baseline	12 M	24 M	36 M	48 M	
<b>IOP <math>\leq 18</math> mmHg</b>						
Mean $\pm$ SD	1.77 $\pm$ 0.93	0.23 $\pm$ 0.44	0.27 $\pm$ 0.47	0.88 $\pm$ 0.99	0.83 $\pm$ 0.98	$p = 0.85$ between the 2 groups at 48 months
Median	1.00	0.00	0.00	0.50	0.50	
IQR	2.00	0.00	0.50	2.00	1.75	
N (eyes)	13	13	11	8	6	
<b>IOP <math>&gt; 18</math> mmHg</b>						
Mean $\pm$ SD	2.07 $\pm$ 1.07	0.36 $\pm$ 0.63	0.50 $\pm$ 0.76	0.75 $\pm$ 0.75	0.92 $\pm$ 0.79	
Median	1.00	0.00	0.00	1.00	1.00	
IQR	1.75	0.75	1.00	1.00	1.25	
N (eyes)	14	14	14	12	12	

IQR: interquartile range

► **Fig. 6** Kaplan-Meier plot of the cumulative probability of failure for (a) all eyes and for (b) eyes that had a preoperative IOP above target (18 mmHg). Failure was defined as an IOP higher than 18 mmHg on 2 consecutive visits (Lewis, 2011).

the postoperative phase was reduced to  $0.83 \pm 0.98$  after 48 months (► **Table 4**). In addition, at 48 months, 3 of the 6 eyes in this group were on 0 medications (preoperatively they were on 2, 2, and 1 medication, respectively). Eyes that were uncontrolled with medications at baseline (IOP higher than 18 mmHg) also experienced a significant reduction in the number of medications and 4 eyes out of 12 eyes in this group were on 0 medications (33%) at 48 months. In total, 7 eyes out of 18 (39%) were on 0 medications at 48 months.

All 9 eyes but 1 that were lost between the 12- and 48-month visits were on 0 medications at 12 or 24 months.

### Controlled intraocular pressure pre- and postoperatively

About half of the eyes ( $n = 13$ ) were defined as successfully controlled with medications at baseline, with an IOP equal to or less

than 18 mmHg. In these eyes, ABIC was performed to reduce patient reliance on medications due to intolerance to medications.

Out of the 27 eyes of the total cohort, 4 eyes had an IOP higher than 18 mmHg for 2 consecutive follow-up visits: 1 eye was below 18 mmHg at baseline, then IOP increased at 24–36 months but decreased to 14 mmHg at 48 months; the remaining 3 eyes were above 18 mmHg and had an IOP above target for 2 consecutive follow-up visits. However, the IOP of 1 of those 3 eyes started at 37 mmHg at baseline and fell to 21 mmHg at 48 months (PEX).

► **Fig. 6** describes the cumulative probability of failure defined as an IOP higher than the target of 18 mmHg on consecutive visits as defined in Lewis et al. [20].

### Visual Acuity

There was a statistically significant improvement in CDVA between baseline and the last postoperative visit ( $p < 0.001$ ). The mean logMAR CDVA was  $0.36 \pm 0.37$  (20/45 Snellen) at baseline

► **Table 5** Results at 12 months for different MIGS studies in the literature.

Publication	IOP baseline (in mmHg)	IOP 12 months (in mmHg)	Number of medications baseline	Number of medications 12 months
Our study (n = 27) (ABiC)	19.8 ± 5.2	15.0 ± 2.6	1.92 ± 1.00	0.30 ± 0.54
Gallardo et al. [16] (n = 75) (ABiC)	20.4 ± 4.7	13.3 ± 1.9	2.8 ± 0.9	1.1 ± 1.1
Kazerounian et al. [17] (n = 25) (ABiC)	20.24 ± 5.92	12.55 ± 3.33	1.92 ± 1.04	0.05 ± 0.23*
Pahlitzsch et al. [25] (n = 130) (Trabectome)	19.2 ± 4.0	11.8 ± 3.1	2.3 ± 0.8	2.3 ± 1.4
Fea [26] (n = 12) (iStent)	17.9 ± 2.6	14.8 ± 1.2	2.0 ± 0.9	0.4 ± 0.7
Hengerer et al. [27] (n = 81) (iStent)	22.6 ± 6.2	14.3 ± 1.7	2.5 ± 1.1	0.8 ± 0.9
Pfeiffer et al. [24] (n = 50)** (Hydrus)	18.9 ± 3.3	16.1 ± 3	2.0 ± 1.0	0.5 ± 1.1

\*At 24 months. \*\* MIGS with cataract surgery results only.

and  $0.15 \pm 0.31$  (between 20/25 and 20/32 Snellen) postoperatively, representing an average gain of 2 lines of visual acuity.

### Visual Field

The mean deviation recorded from the Humphrey visual field was not statistically significantly different between baseline and the last postoperative visit ( $p = 0.634$ ), indicating that there was no deterioration of the visual field. Mean baseline was  $-7.86 \pm 6.90$  dB and mean postoperative was  $-6.95 \pm 5.72$  dB.

All eyes except one showed no change or improvement. One eye demonstrated a deterioration of the visual field. In this patient, IOP was lowered from 20 mmHg to 13 mmHg at 12 months, but then increased to 15 and 17 mmHg at subsequent follow-ups, whilst gaining 3 lines of visual acuity at the last follow-up.

### Safety Outcomes

No secondary surgical interventions were required in order to control IOP in any of the eyes. No significant complications were noted, except for a single case of limited descemetolysis near the limbus. This was likely caused by a slower withdrawal of the catheter with a subsequent local over-delivery of the OVD in the canal that resulted in a detachment of the Descemet membrane. This resolved spontaneously after 6 weeks, with no sequelae and a stable IOP. No other adverse events were reported.

### Discussion

In this retrospective case series study, ABiC performed as a stand-alone procedure or in conjunction with cataract surgery was found to be a safe and effective option for maintaining a sustained IOP reduction in patients with OAG up to 4 years, from  $19.8 \pm 5.2$  (n = 27) mmHg at baseline to  $14.6 \pm 3.0$  mmHg (n = 18) at the 48-month follow-up.

It was also effective in reducing glaucoma medication dependence, with approximately 39% of eyes medication free and 72% of the eyes on 1 medication or less at 4 years. Overall, no eye was on more than two medications 48 months after the procedure. About half of the eyes (n = 13) were defined as successfully controlled with medications at baseline, with an IOP equal to or less

than 18 mmHg. In these eyes, ABiC was performed to reduce patient reliance on medications due to intolerance of the medications. At 48 months, 50% of the eyes in this group were medication free and the 2 eyes that were missed between the 36–48-month follow-up were medication free at 36 months.

All patients who were lost to follow-up returned to their referring ophthalmologist because they showed no complications, and the overall outcome was satisfying; all but one patient was medication free at their last (12, 24, or 36 month) follow-up. Our conclusion is that ABiC appears effective in patients with controlled glaucoma who wish to reduce the reliance on medications due to intolerance or noncompliance.

The cohort also achieved an average gain of two lines of CDVA. Whilst we assume that this improvement is largely due to cataract removal, none of eyes lost any line of visual acuity, proving that ABiC does not jeopardize visual acuity.

Our clinical outcomes are in accordance with those reported in other studies. A consecutive case series by Gallardo et al. demonstrated comparable clinical efficacy and safety of the same ABiC device (iTrack) over a 12-month period [16]. Another case series by Gallardo, which included a 24-month follow-up, also showed similar results: at 24 months (n = 60), the mean IOP and baseline medications were reduced from  $20 \pm 4.9$  mmHg and  $2.77 \pm 0.91$  to  $13.5 \pm 2.6$  mmHg and  $1.7 \pm 1.29$ , respectively. Twenty-five percent of eyes were medication free and 47% of patients were on one or fewer medications at 24 months compared to only 10% at baseline [21].

In another study, Kazerounian et al. observed a similar substantial and sustained lowering of IOP, which was comparable with our cohort [17] (► **Table 5**).

We therefore conclude that the significant reduction in IOP at 12 months that we observed in our study is comparable with other 12-month studies. This IOP reduction was maintained in our study at 48 months with no significant change from the 12-month follow-up ( $p = 0.35$ ), indicating that the IOP outcomes were stable over time. We also observed a significant reduction of medications at 12–24–36–48 months, which was in line with two of the three studies mentioned, although after 24 months, the analysis showed an increase in the number of medications be-



tween 12 and 36 months and a borderline ( $p = 0.048$ ) increase between 12 and 48 months.

In our study, we were able to demonstrate that the efficacy of ABiC and the reduction in IOP was maintained up to 4 years after the procedure. This is an encouraging result and, to the authors' knowledge, the longest follow-up available to date for the ABiC procedure performed with the iTrack microcatheter.

Other licensed MIGS that specifically target the conventional outflow pathway include the Trabectome (NeoMedix Corporation, Tustin, CA, USA), the iStent (Glaukos, Burlington, MA, USA) and the Hydrus Microstent (Ivantis, Inc., Irvine, CA, USA) [22–24]. Pahlitzsch et al. showed a mean IOP reduction for Trabectome [25] that was comparable with our current series. Fea [26] and Hengerer et al. [27] found similar results using the iStent. The study by Pfeiffer et al. [3, 24] also yielded comparable results implanting the Hydrus in conjunction with cataract surgery (see ► **Table 5**). In contrast, these procedures are focal in their approach, whereas ABiC addresses all aspects of the conventional outflow system without leaving an implant in place.

It is of particular importance to understand the effect of cataract surgery on IOP. A recent study by Samuelson et al. [28] estimated cataract surgery alone was able to lower IOP 5.4 mmHg at 24 months but other longer-term (3–5 years) studies conducted in relevant patient populations, such as mild and moderate OAG patients, suggest a more modest long-term IOP reduction of 1–2 mmHg [29, 30], including a dedicated study by Shingleton et al. who reported an IOP decrease of  $1.8 \pm 3.5$  mmHg at 5 years [31] and Kozera et al. who found an IOP decrease of 0.90 mmHg and 0.43 mmHg at 24 months; groups were divided according to the initial IOP (after the washout period) into IOP < 26 mmHg and IOP  $\geq$  26 mmHg [32].

The patient cohort in this study demonstrated a net IOP decrease of 5.3 mmHg at 48 months for all eyes, a decrease of 5.28 mmHg for eyes with cataract surgery, and a decrease of 5.83 mmHg for standalone eyes. In addition, all eyes in the standalone group were able to reduce IOP of at least 3 mmHg at 48 months. This suggests an additional IOP benefit of ABiC above that expected for phacoemulsification alone, especially when we consider that approximately half of the eyes ( $n = 13$ ) were defined as successfully controlled with medications at baseline. For these patients, the primary treatment goal was to reduce medication dependence whilst maintaining IOP within the target range. Gallardo [21] as well as previous studies of patients undergoing ABiC have demonstrated similar IOP reduction in eyes treated with either a standalone ABiC procedure or combined procedure, which recommends that ABiC offers utility beyond the reduction of IOP [16, 33, 34]. Nevertheless, in order to assess the IOP lowering effect of ABiC outside of cataract surgery, a study with a sufficient number of patients would be required.

In this current series, no severe complications occurred either intraoperatively or postoperatively, although the study was underpowered to identify low-risk complications. In one patient, a limited descemetolysis near the limbus was observed, likely due to an over-delivery of viscoelastic during a slower withdrawal of the catheter through Schlemm's canal. A potential complication that was not observed in our case series, but which occurs in approximately 5% of the cases [35], is where the microcatheter can divert

into a collector channel. This complication can be managed by making a paracentesis 180° away and catheterizing in the opposite direction in order to achieve a successful 360° viscodilation. In our experience, we found that, because the bulbous tip of the microcatheter is atraumatic, there were no instances of choroidal damage. The illuminated LED tip allows the surgeon to track the microcatheter as it passes through the full length of Schlemm's canal and prevents misdirection into the collector channels or suprachoroidal space. Furthermore, temporary misdirection of the microcatheter may be resolved by applying pressure to the affected area or again, by making a paracentesis 180° away from the site of the misdirection and catheterizing in the opposite direction.

The limitations and potential biases of this case series include the lack of randomization, a small sample size, its retrospective nature, and the inclusion in the same group of eyes treated with combined cataract surgery as well as eyes treated with a standalone procedure.

Further analysis in a larger number of eyes will be needed to confirm the findings of this study. However, our findings indicate that the efficacy of ABiC in lowering IOP and reducing medication dependency was comparable to previous 12-month ABiC studies, and IOP reduction was sustained up to 4 years following surgery.

Despite its efficacy and safety profile, these results do not suggest that ABiC should supplant ab-externo canaloplasty or traditional glaucoma surgery. Traditional ab-externo canaloplasty has a rich history, particularly in Germany, with more advanced glaucoma cases, and some studies have suggested that its efficacy is comparable with trabeculectomy [36].

Rather, we recommend the deployment of ABiC earlier in the treatment paradigm of mild to moderate glaucoma patients in order to delay more invasive treatments.

Further studies that employ a larger case series are required to assess its efficacy and to investigate patient-center outcomes. A prospective, multicenter, randomized, single-masked clinical trial to evaluate the effective outcomes of ABiC, with iTrack performed as a standalone procedure, is currently under way in the United States [37].

## Conclusion

This 48-month data showed that ABiC performed in combination with phacoemulsification or as a standalone procedure results in a significant reduction in IOP compared to the preoperative baseline along with a significant decrease in mean glaucoma medications. Our results showed that performing ABiC with the iTrack is safe and effective in patients with OAG up to 4 years. Further studies with prospective multicenter trials with a larger patient cohort are needed to evaluate the outcomes of ABiC as a standalone procedure and combined with cataract surgery.

## Conflict of Interest

The authors have no financial or proprietary interest in any material or method mentioned. Prof. N. Körber is the Principal Investigator for the Catalyst clinical study which uses the product mentioned in this manuscript (iTrack, Nova Eye Medical).

## References

- [1] Tham YC, Li X, Wong TY et al. Global prevalence of glaucoma and projections of glaucoma burden through 2040: a systematic review and meta-analysis. *Ophthalmology* 2014; 121: 2081–2090. doi:10.1016/j.ophtha.2014.05.013
- [2] Leske MC, Heijl A, Hyman L et al. Early Manifest Glaucoma Trial: design and baseline data. *Ophthalmology* 1999; 106: 2144–2153. doi:10.1016/S0161-6420(99)90497-9
- [3] Lavia C, Dallorto L, Maule M et al. Minimally-invasive glaucoma surgeries (MIGS) for open angle glaucoma: A systematic review and meta-analysis. *PLoS ONE* 2017; 12: e0183142. doi:10.1371/journal.pone.0183142
- [4] Olthoff CMG, Schouten JS, van de Borne BW et al. Noncompliance with ocular hypotensive treatment in patients with glaucoma or ocular hypertension: an evidence-based review. *Ophthalmology* 2005; 112: 953–961.e7. doi:10.1016/j.ophtha.2004.12.035
- [5] Rossi GCM, Pasinetti GM, Scudeller L et al. Do adherence rates and glaucomatous visual field progression correlate? *Eur J Ophthalmol* 2011; 21: 410–414. doi:10.5301/EJO.2010.6112
- [6] Newman-Casey PA, Robin AL, Blachley T et al. The Most Common Barriers to Glaucoma Medication Adherence: A Cross-Sectional Survey. *Ophthalmology* 2015; 122: 1308–1316. doi:10.1016/j.ophtha.2015.03.026
- [7] Beckers HJ, Schouten JS, Webers CA et al. Side effects of commonly used glaucoma medications: comparison of tolerability, chance of discontinuation, and patient satisfaction. *Graefes Arch Clin Exp Ophthalmol* 2008; 246: 1485–1490. doi:10.1007/s00417-008-0875-7
- [8] Ammar DA, Kahook MY. Effects of benzalkonium chloride- or polyquad-preserved fixed combination glaucoma medications on human trabecular meshwork cells. *Mol Vis* 2011; 17: 1806–1813
- [9] Last JA, Pan T, Ding Y et al. Elastic modulus determination of normal and glaucomatous human trabecular meshwork. *Invest Ophthalmol Vis Sci* 2011; 52: 2147–2152. doi:10.1167/iovs.10-6342
- [10] Razeghinejad MR, Spaeth GL. A history of the surgical management of glaucoma. *Optom Vis Sci* 2011; 88: E39–E47. doi:10.1097/OPX.0b013e3181fe2226
- [11] Borisuth N, Phillips B, Krupin T. The risk profile of glaucoma filtration surgery. *Curr Opin Ophthalmol* 1999; 10: 112–116. doi:10.1097/00055735-199904000-00006
- [12] Francis BA, Singh K, Lin SC et al. Novel glaucoma procedures: a report by the American Academy of Ophthalmology. *Ophthalmology* 2011; 118: 1466–1480. doi:10.1016/j.ophtha.2011.03.028
- [13] Saheb H, Ahmed IIK. Micro-invasive glaucoma surgery: current perspectives and future directions. *Curr Opin Ophthalmol* 2012; 23: 96–104. doi:10.1097/ICU.0b013e3182834ff1e7
- [14] Khaimi MA. Canaloplasty: A Minimally Invasive and Maximally Effective Glaucoma Treatment. *J Ophthalmol* 2015; 2015: 485065. doi:10.1155/2015/485065
- [15] Gallardo MJ, Supnet RA, Ahmed IIK. Circumferential viscodilation of Schlemm's canal for open-angle glaucoma: ab-interno vs. ab-externo canaloplasty with tensioning suture. *Clin Ophthalmol* 2018; 12: 2493–2498. doi:10.2147/OPHTH.S178962
- [16] Gallardo MJ, Supnet RA, Ahmed IIK. Viscodilation of Schlemm's canal for the reduction of IOP via an ab-interno approach. *Clin Ophthalmol* 2018; 12: 2149–2155. doi:10.2147/OPHTH.S177597
- [17] Kazerounian S, Zimbelmann M, Lörtscher M et al. Canaloplasty ab interno (AbiC) – 2-Year-Results of a Novel Minimally Invasive Glaucoma Surgery (MIGS) Technique. *Klin Monbl Augenheilkd* 2021; 238: 1113–1119. doi:10.1055/a-1250-8431
- [18] Hodapp E, Parrish RKI, Anderson DR. Clinical decisions in glaucoma. St. Louis: The CVMosby Co.; 1993
- [19] [Anonymous]. European glaucoma society terminology and guidelines for glaucoma, 4th edition – Chapter 2: Classification and terminology Supported by the EGS Foundation: Part 1: Foreword; Introduction; Glossary; Chapter 2 classification and terminology. *Br J Ophthalmol* 2017; 101: 73–127. doi:10.1136/bjophthalmol-2016-EGSguideline.002
- [20] Lewis RA, von Wolff K, Tetz M et al. Canaloplasty: Three-year results of circumferential viscodilation and tensioning of Schlemm canal using a microcatheter to treat open-angle glaucoma. *J Cataract Refract Surg* 2011; 37: 682–690. doi:10.1016/j.jcrs.2010.10.055
- [21] Gallardo MJ. 24-Month Efficacy of Viscodilation of Schlemm's Canal and the Distal Outflow System with Itrack Ab-Interno Canaloplasty for the Treatment of Primary Open-Angle Glaucoma. *Clin Ophthalmol* 2021; 15: 1591–1599. doi:10.2147/OPHTH.S272506
- [22] Godfrey DG, Fellman RL, Neelakantan A. Canal surgery in adult glaucoma. *Curr Opin Ophthalmol* 2009; 20: 116–121. doi:10.1097/ICU.0b013e3182831eef65
- [23] Craven ER, Katz LJ, Wells JM et al. Cataract surgery with trabecular microbypass stent implantation in patients with mild-to-moderate open-angle glaucoma and cataract: two-year follow-up. *J Cataract Refract Surg* 2012; 38: 1339–1345. doi:10.1016/j.jcrs.2012.03.025
- [24] Pfeiffer N, Garcia-Feijoo J, Martinez-de-la-Casa JM et al. A Randomized Trial of a Schlemm's Canal Microstent with Phacoemulsification for Reducing Intraocular Pressure in Open-Angle Glaucoma. *Ophthalmology* 2015; 122: 1283–1293. doi:10.1016/j.ophtha.2015.03.031
- [25] Pahlitzsch M, Gonnermann J, Maier AKB et al. [Trabeculectomy ab Interno in primary open angle glaucoma and exfoliative glaucoma]. *Klin Monbl Augenheilkd* 2015; 232: 1198–1207. doi:10.1055/s-0041-105941
- [26] Fea AM. Phacoemulsification versus phacoemulsification with microbypass stent implantation in primary open-angle glaucoma. Randomized double-masked clinical trial. *J Cataract Refract Surg* 2010; 36: 407–412. doi:10.1016/j.jcrs.2009.10.031
- [27] Hengerer FH, Auffarth GU, Riffel C et al. Prospective, Non-randomized, 36-Month Study of Second-Generation Trabecular Micro-Bypass Stents with Phacoemulsification in Eyes with Various Types of Glaucoma. *Ophthalmol Ther* 2018; 7: 405–415. doi:10.1007/s40123-018-0152-8
- [28] Samuelson TW, Sarkisian SRJ, Lubeck DM et al. Prospective, Randomized, Controlled Pivotal Trial of an Ab Interno Implanted Trabecular Micro-Bypass in Primary Open-Angle Glaucoma and Cataract: Two-Year Results. *Ophthalmology* 2019; 126: 811–821. doi:10.1016/j.ophtha.2019.03.006
- [29] Majstruk L, Leray B, Bouillot A et al. Long term effect of phacoemulsification on intraocular pressure in patients with medically controlled primary open-angle glaucoma. *BMC Ophthalmol* 2019; 19: 149. doi:10.1186/S12886-019-1157-3
- [30] Mathalone N, Hyams M, Neiman S et al. Long-term intraocular pressure control after clear corneal phacoemulsification in glaucoma patients. *J Cataract Refract Surg* 2005; 31: 479–483. doi:10.1016/j.jcrs.2004.06.046
- [31] Shingleton BJ, Pasternack JJ, Hung JW et al. Three and five year changes in intraocular pressures after clear corneal phacoemulsification in open angle glaucoma patients, glaucoma suspects, and normal patients. *J Glaucoma* 2006; 15: 494–498. doi:10.1097/01.ijg.0000212294.31411.92
- [32] Kozera M, Konopińska J, Mariak Z et al. Effectiveness of iStent trabecular micro-bypass system combined with phacoemulsification vs. phacoemulsification alone in patients with glaucoma and cataract depending on the initial intraocular pressure. *Ophthalmic Res* 2020; 64: 327–336. doi:10.1159/000511456
- [33] Davids AM, Pahlitzsch M, Boeker A et al. Ab interno canaloplasty (AbiC)–12-month results of a new minimally invasive glaucoma surgery (MIGS). *Graefes Arch Clin Exp Ophthalmol* 2019; 257: 1947–1953. doi:10.1007/s00417-019-04366-3

- [34] Ondrejka S, Koerber N. 360° ab-Interno Schlemm's canal viscodilation in primary open-angle glaucoma. *Clin Ophthalmol* 2019; 13: 1235–1246. doi:10.2147/OPTH.S203917
- [35] Koerber N. Ab interno canaloplasty for the treatment of glaucoma: a case series study. *Spektrum Augenheilkd* 2018; 32: 223–227. doi:10.1007/s00717-018-0416-7
- [36] Brüggemann A, Despouy JT, Wegent A et al. Intraindividual comparison of Canaloplasty versus trabeculectomy with mitomycin C in a single-surgeon series. *J Glaucoma* 2013; 22: 577–583. doi:10.1097/IJG.0b013e318255bb30
- [37] [Anonymous]. Multicenter Ab-interno Glaucoma Study Investigating Canaloplasty (MAGIC). *ClinicalTrials.gov*. Identifier: NCT04769453. 2021. Accessed March 1, 2021 at: <https://clinicaltrials.gov/ct2/show/NCT04769453>