


# The Effect of Locally Delivered Apocynin on Fat Graft Survival in an Experimental Rat Animal Model

Doğan Çakan, MD<sup>1</sup>  Sinem Eroğlu, MD<sup>2</sup> Ekrem Ramazan Keskin, MD<sup>3</sup>

<sup>1</sup>Department of Otorhinolaryngology, Istanbul University-Cerrahpaşa Cerrahpaşa Medical Faculty, Istanbul University, Istanbul, Turkey

<sup>2</sup>Department of Aesthetic, Plastic and Reconstructive Surgery Haydarpaşa Numune Training and Research Hospital, Istanbul, Turkey

<sup>3</sup>Department of Aesthetic, Plastic and Reconstructive Surgery Istanbul Rio Clinic, Istanbul, Turkey

Address for correspondence Doğan Çakan, MD, Cerrahpaşa Tıp Fakültesi Fatih, Istanbul, Turkey (e-mail: drdgnckn@gmail.com).

Facial Plast Surg 2022;38:419–427.

## Abstract

We aimed to investigate the efficacy of locally delivered apocynin on fat graft survival in an experimental autologous fat grafting (AFG) model created in rats. Twenty-one Wistar albino male rats were included in this study. The 0.647 g mean weight grafts were harvested from the inguinal region and transferred to the nape of every rat. The subjects were randomly separated into three groups. Saline, dimethyl sulfoxide (DMSO), and apocynin, a dose of 20 mg/kg, solutions were applied once a day for 2 weeks. After 3 months, the rats were sacrificed. The evaluation of physical measurements (weight and volume) and survival rates of the grafts for volume and weight, the viable cell count (VC) with the 3-(4,5-dimethylthiazol-2-yl)-2,5-diphenyltetrazolium bromide (MTT) assay, and histopathological parameters were done. All biophysical parameters were found to be significantly higher in the apocynin group compared with other groups ( $p < 0.05$ ). In the MTT test, the saline group was normalized to 100%. According to this, DMSO and apocynin groups' means were 106 and 163%, respectively. The VC was significantly higher in the apocynin group than the other groups ( $p < 0.05$ ). The VC was significantly higher in the DMSO group than in the saline group ( $p < 0.05$ ). No significant difference was found in other comparisons performed according to biophysical and histopathological parameters ( $p > 0.05$ ). The locally delivered apocynin decreases fat graft volume loss in an experimental AFG model. Consequently, apocynin can be used as an effective substance to increase graft survival. The level of evidence was not available.

## Keywords

- ▶ Animals
- ▶ Apocynin
- ▶ Adipose tissue
- ▶ Graft survival
- ▶ Rats

Fat grafting is a technique where the harvested adipose tissue is embedded into various compartments underneath the skin. The term autologous fat grafting (AFG) refers to the procedure where the source of fat is the same person on whom it is to be used.<sup>1</sup>

Clinical applications of AFG include reconstructive and aesthetic procedures; the treatment of congenital or acquired malformations, such as tissue augmentation, contouring, and rejuvenating procedures; and repair of soft

tissue defects, treatment of burn injuries, radiation damages, contractures, and scars.<sup>2–4</sup> Apart from plastic and aesthetic surgeries, it has many other uses such as paranasal sinus obliteration, tympanic membrane perforation repair, laryngoplasty and pharyngoplasty, mastoidectomy cavity obliteration, cleft palate repair, and anal sphincteroplasty.<sup>5</sup>

AFG has many attributes that should be in a consummate filling substance such as biocompatibility, accessibility, low immunogenicity, and non-toxicity.<sup>6</sup> AFG is easy to perform, a

Issue Theme Functional Facial Plastic Surgery; Guest Editors: Clinton D. Humphrey, MD, FACS, and J. David Kriet, MD, FACS

© 2022. Thieme. All rights reserved. Thieme Medical Publishers, Inc., 333 Seventh Avenue, 18th Floor, New York, NY 10001, USA

DOI <https://doi.org/10.1055/a-1738-1194>  
ISSN 0736-6825.

procedure that leads to low morbidity in the donor site and is cost-effective. However, the high resorption rate (RR) is the disadvantage of AFG that can cause repetitive applications and undesired outcomes.<sup>7,8</sup>

Post-procedure RRs have been reported between 20 and 80% in different studies.<sup>9,10</sup> The fat graft survival is affected by the donor and recipient site of the graft and the processes applied during the grafting procedure.<sup>11–14</sup> To reduce the RRs, an environment with well-established vascularity and less inflammation and apoptosis should be provided.<sup>14,15</sup>

The nicotinamide adenine dinucleotide phosphate oxidases (NOXs), multi-unit enzymes in many cells, are a substantial origin of the reactive oxygen radicals (ROs).<sup>16</sup> ROs cause cell damage and apoptosis by damaging DNA, RNA, and structural elements of the cell.<sup>17</sup>

*Picrorhiza kurroa* is a domestic herb grown in the Himalayas, and its extracts are used as a complementary and alternative medicine.<sup>18</sup> Apocynin (acetovanillone, 4'-hydroxy-3'-methoxyacetophenone) is a substance obtained from *Picrorhiza kurroa*.<sup>19</sup> Apocynin acts as a powerful and selective NOX inhibitor.<sup>20</sup> It prevents the translocation of cytosolic subunits of NOX to the cell membrane and inhibits its activation.<sup>16</sup> It is a substance with anti-oxidant, anti-inflammatory, and anti-apoptotic properties that have been experimented within the treatment of vascular, inflammatory, and degenerative diseases.<sup>20–22</sup>

Keskin and Çakan showed that the systemic administration of apocynin decreases graft volume loss in the rat model of autologous tissue transfer.<sup>23</sup> The aim of this study was to examine the efficacy of local apocynin delivery on the main physical and histopathological characteristics of rat AFGs.

## Materials and Methods

The study was conducted in the Animal Application and Research Center with the approval of Acibadem University Local Ethics Committee (decision no: 12.08/51).

### Animals

The minimum sample size was estimated based on a study by Keskin and Çakan.<sup>23</sup> The minimum sample size for each group, with 99% confidence interval and 5% tolerable error assumptions, was seven. In our study, 21 healthy male Wistar albino rats (9–10 weeks old) each weighing 200 to 350 g were used. The animals were held in standardized husbandry conditions with a 12:12 hours light–dark light cycle and at  $22 \pm 2^\circ\text{C}$  temperature. The animals were housed in groups of three per cage and fed ad libitum with water and standard pelleted food.

### Chemical Agents

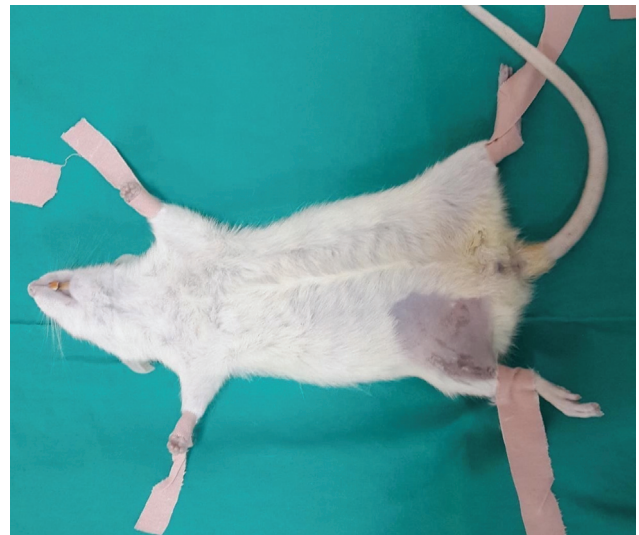Apocynin (Acetovanillone,  $\geq 98\%$ ) (Sigma Aldrich, MO), thiazolyl blue tetrazolium bromide (3-(4,5-dimethylthiazol-2-yl)-2,5-diphenyltetrazolium bromide [MTT]) (Sigma Aldrich), 0.9% NaCl (Saline) (Adeka, Turkey), and dimethyl sulfoxide (DMSO) (Sigma Aldrich) were the main elements in this study. MTT was stored at  $4^\circ\text{C}$ , and apocynin, saline, and DMSO at room temperature. Apocynin dose, 20 mg/kg, was calculated based on the study of Keskin and Çakan.<sup>23</sup>

## Experimental Design

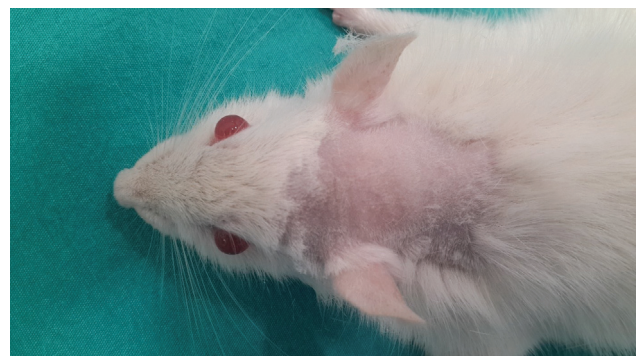
The animals ( $n = 21$ ) were randomly separated into three experimental groups: control (group 1), DMSO (group 2), and apocynin (group 3). Each group consisted of seven animal subjects.

### Grafting Surgery

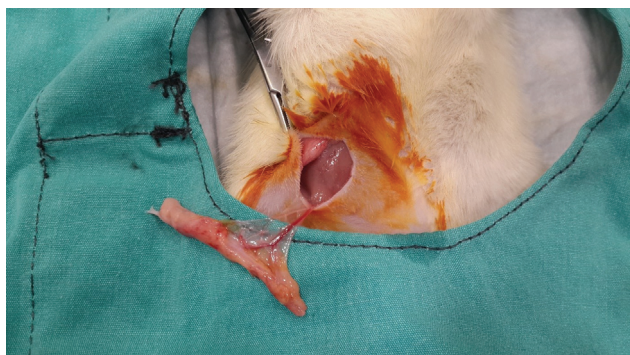
All subjects in the groups were anesthetized with intramuscular ketamine hydrochloride (Ketalar, Pfizer, NY) at a dose of 45 mg/kg and xylazine hydrochloride (Basilazin, Bavet, Germany) at a dose of 5 mg/kg. Ten minutes after the induction of anesthesia, the rats were placed propitiously, and the inguinal area was cleaned with povidone-iodine (Betadine 10%, Mundipharma, Germany) and shaved to harvest the graft aseptically (►Fig. 1). Thereupon, the nape regions of rats were shaved (►Fig. 2). To attain the inguinal fat tissue, a 2 to 3 cm skin incision was made in the right groin parallel to the inguinal ligament and the inguinal adipofacial pad was found and dissected from the circumambient tissues (►Fig. 3). Epigastric inferior artery and vein attached to the fat pad were cauterized for hemostasis and fat pad was harvested (►Fig. 4). Adipose tissues taken as grafts weighted between 0.4 and 0.8 g. The surgical region was sutured with a 4/0 suture (Perma



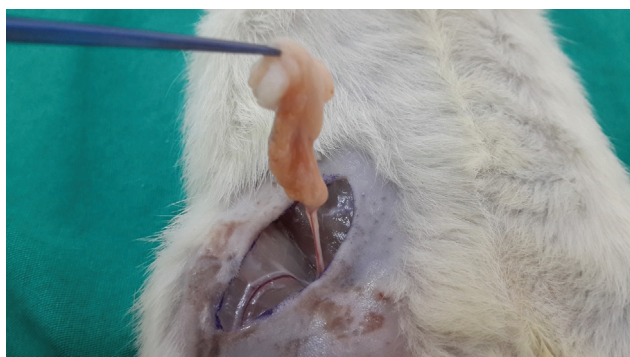**Fig. 1** Preparation of the subject for the surgical adipose tissue harvest and transfer procedure.



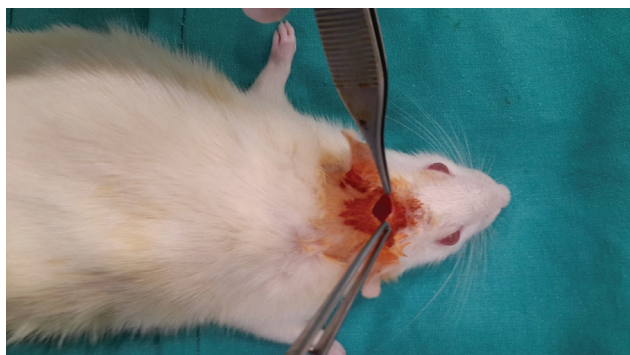
**Fig. 2** The subject's shaven two inter-ear and nape area.



**Fig. 3** Microdissection to reach the inguinal adipose tissue.



**Fig. 4** The preparation of the fat graft.

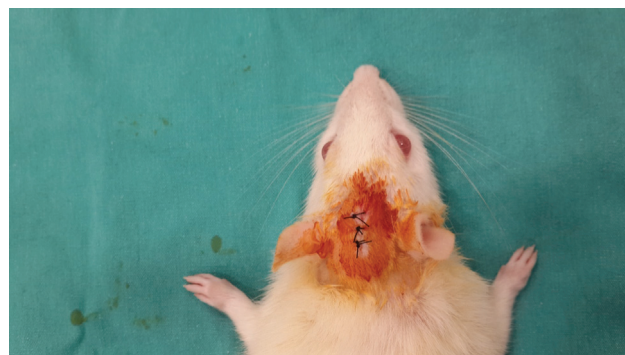


**Fig. 5** The subcutaneous pocket prepared for the autologous fat graft.

Hand, Ethicon Inc., NJ). The fat graft was positioned into the subcutaneous pocket prepared on the nape of the animal (► **Fig. 5**). The nape incision was sutured with 5/0 suture (Perma Hand®, Ethicon Inc.) (► **Fig. 6**). The incisions were dressed with OpSite® spray (Smith & Nephew, UK).

#### Treatment Procedure in the Groups

- Group 1 (saline, control): Subsequent to the surgical process, 0.3 mL saline was injected into the graft pocket once daily.
- Group 2 (DMSO): In our study, apocynin was dissolved in DMSO. We established group 2 to investigate the effect of DMSO. Subsequent to the surgical process, a 0.3 mL mixture including 0.015 mL DMSO was injected into the graft pocket once daily.



**Fig. 6** The sutured incision in the nape.

- Group 3 (apocynin): After the surgical process, a 0.3 mL mixture including 20 mg/kg apocynin and 0.015 mL DMSO was injected into the graft pocket once daily.

Saline was applied to expand the mixture volumes, and the solutions were injected by the same person at the same time for 14 days. Ninety days afterward the surgery, the animals were sacrificed with 100 mg/kg intraperitoneal pentobarbital injection.

#### The Biophysical Evaluations

All measurements were made, immediately after the fat graft was excised, blindly. The surgical procedures at the beginning of the experiment and the surgical procedures at the end of the experiment were performed by different surgeons. The surgeon who performed the excision and measurements of the grafts did not know which group the subjects belonged to. Likewise, pathological examinations were performed by an experienced pathologist who was blinded about which group the specimens belonged to.

The AFG weights were calculated after the initial procurement and after the tissue harvesting at the end of an experiment using a precision scale (AUW220D, Shimadzu Corp., Japan).

AFG survival rate for the weight (SRW) was calculated by the following formula:

$$\text{SRW} = \frac{\text{the excised AFG weight at the end of the study (POSTOP-AGF-W)}}{\text{AFG weight before tissue transfer (PREOP-AGF-W)}}$$

After weight assessments, each graft was put in 3 mL of saline in a receptacle, and its volume was calculated based on the quantity of overflow. The same procedure was repeated at the end of the study.

The AFG survival rate for volume (SRV) was calculated by the following formula:

$$\text{SRV} = \frac{\text{postoperative AFG volume at the end of the study (POSTOP-AGF-VOL)}}{\text{preoperative AFG volume (PREOP-AGF-VOL)}}$$

MTT is a water-soluble agent that is accumulated within the living cells with an active metabolism and reduced to the

water-insoluble chromogenic purple dye formazan by the enzymatic mitochondrial reaction. Since the amount of formazan produced by reduction of MTT is directly proportional to the number of living, not to dead cells during MTT exposure, the MTT colorimetric assay is commonly used to quantify cell viability and cell proliferation. The cytotoxic or proliferative effect of any medicinal substance can be defined by this method.<sup>24,25</sup> The potential efficacy of the agents in this study on the survival of the graft cells was analyzed with the MTT kit (Catalog No. 11465007001, Sigma Aldrich) according to the manufacturer's instruction manual. The MTT test for all subjects was performed on the same day with the same multi-well plate.

#### MTT Assay

The impact of the apocynin and control compounds (saline or solvent DMSO-alone) on the survival of the AFG-derived cells was analyzed by the MTT assay following the manufacturer's instructions. Briefly, a 100 mg aliquot was divided from each graft for the MTT test. After mechanically mashing with a pipette, these pieces were digested with trypsin (0.5 mg/mL) and collagenase P (2 mg/mL) solution (Collagenase P, Sigma Aldrich) at 37°C for 45 minutes, and 10 µL of MTT labeling reagent was added to the 100 µL cell culture medium (Medium RPMI 1640 containing 10% FCS, Sigma Aldrich) (containing AFG cells in 96-well flat-bottom plates (5 × 10<sup>3</sup> cells/well). A negative control (blank) of 10 µL of the MTT stock solution was added to 100 µL of medium alone. Thereafter, the plates were placed into the humidified incubator (37°C and 5–6.5% CO<sub>2</sub>) and left for 60 minutes. All but 25 µL of the medium was removed from the wells, and 50 µL of DMSO was added to each well and mixed thoroughly with a pipette. The suspension was further incubated at 37°C and 5 to 6.5% CO<sub>2</sub> conditions for 20 minutes. The reducing agent dithiothreitol was used as the positive control. The signals were quantified at 570 nm absorbance in a microplate reader (µ-Quant, BioTek Instruments, VT). Four wells were used for each subject. The cell viability (%) was calculated using the following formula: (optical density (OD) treated sample (apocynin or DMSO) [–blank]) / (OD control well (phosphate-buffered saline) [–blank]) × 100

#### Histopathological Assessment

At the end of the study, the sizes of the excised grafts were determined macroscopically. Afterward, the grafts were fixed with 10% neutral formaldehyde. Five micrometer-thick sections were obtained from the paraffin-embedded blocks, which were prepared from the fixed tissue. The sample sections were stained with hematoxylin and eosin and examined by the Brightfield Light Microscopy (Primo Star ILED, Carl Zeiss Meditec AG, Germany) at high magnification. The histopathological examinations were blindly performed by an expert pathologist. The inflammation, vascularization, lipogranuloma formation, cyst formation, and fibrosis were evaluated by separating them into four categories (0: none, 1: mild, 2: moderate, and 3: intensive). The vascularity was defined according to the number of vascular structures.

#### Statistical Analysis

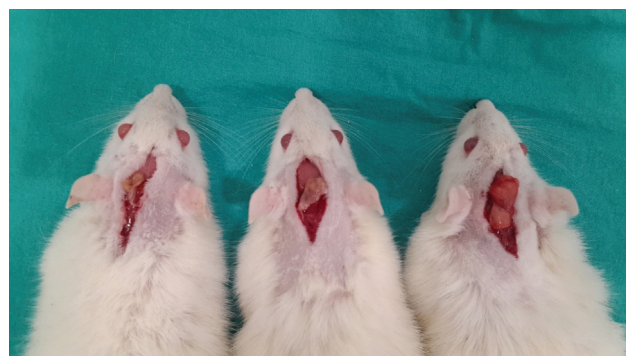
The minimum sample size was calculated by using the G\*Power software version 3.1.<sup>26</sup> All statistical evaluations were performed with the SPSS 20 (IBM® Corp., NY). The Kruskal–Wallis test was used to compare outcomes among the three groups. The Mann–Whitney U test (for independent samples) and Wilcoxon Signed Ranks Test (for related samples) were used in paired comparisons. The statistical significance level was set to  $p < 0.05$ .

#### Results

All subjects survived until the end of the experiment. No complications such as infection, necrosis, or fluid collection were observed in any of the rats. The rat weights and ages were statistically similar in three groups at the beginning of the experiment (248 ± 25, 256.8 ± 18.2, and 241.9 ± 23 g [the Kruskal–Wallis test,  $p > 0.05$ ]). Excellent recovery post-surgery was manifested by gained animal weight at the end of the study with the mean values of 269.7 ± 31, 279.5 ± 18.5, and 262.1 ± 25.5 g, for groups 1, 2, and 3, respectively. However, there was no statistically significant difference between the groups (the Kruskal–Wallis test,  $p > 0.05$ ).

The excised grafts were investigated macroscopically. Small-sized and less vascular grafts were determined in the control group. Bigger and more vascular grafts were determined in group 2. The biggest and most vascular grafts were determined in group 3 (► Fig. 7).

► Table 1 lists the physical measurements of all AFGs before and after the adipose tissue transfer surgery. The preoperative AFG weights (PREOP-AFG-W) and volumes (PREOP-AFG-VOL) were similar ( $p > 0.05$ ). However, in all groups, the mean postoperative AFG weights (POSTOP-AFG-W) and volumes (POSTOP-AFG-VOL) were found to be significantly lower than their respective preoperative mean values ( $p_{\text{weight}} = 0.018$  for all three groups;  $p_{\text{volumes}} = 0.017, 0.017, 0.014$ ). According to the paired comparisons between the separate groups, the POSTOP-AFG-W in group 3 was found to be significantly higher (mean ± standard deviation (SD)<sub>POSTOP-AFG-W</sub> = 0.19 ± 0.07, 0.2 ± 0.04, 0.34 ± 0.05 g) compared with the other groups ( $p < 0.05$ ). Similarly, the POSTOP-AFG-VOL of the apocynin-treated AFGs in group 3 was found to be significantly higher (Mean ± SD<sub>POSTOP-AFG-VOL</sub> = 0.13 ± 0.05, 0.19 ± 0.04, 0.36 ± 0.05 cc) than those in group 1 ( $p = 0.001$ ) or



**Fig. 7** Macroscopic views of the grafts at the end of the experiment. Groups 1 and 3 (from left to right).

**Table 1** Evaluation of survival based on the changes in physical weight (SRW) or volume (SRV) characteristics of preoperative (PREOP) and postoperative (POSTOP) saline (group 1), DMSO (group 2), and apocynin (group 3) treated autologous rat fat grafts

Groups	Physical parameter	Subject number														Mean ±SD	
		1		2		3		4		5		6		7			
		Preop	Postop	Preop	Postop	Preop	Postop	Preop	Postop	Preop	Postop	Preop	Postop	Preop	Postop	Preop	Postop
Group 1 (n = 7)	Weight (g)	0.73	0.13	0.57	0.14	0.64	0.1	0.8	0.3	0.7	0.18	0.8	0.23	0.7	0.24	0.70 ± 0.08	0.19 ± 0.07
	SRW percentage	0.18		0.25		0.16		0.37		0.26		0.29		0.34		26% ± 8	
	Volume (cc)	0.8	0.1	0.7	0.1	0.5	0.1	0.8	0.2	0.6	0.2	0.7	0.1	0.6	0.2	0.67 ± 0.11	0.13 ± 0.05
	SRV percentage	0.13		0.14		0.2		0.25		0.33		0.14		0.17		19% ± 7	
Group 2 (n = 7)	Weight (g)	0.81	0.23	0.57	0.2	0.45	0.17	0.62	0.21	0.7	0.14	0.59	0.15	0.7	0.2	0.63 ± 0.11	0.2 ± 0.04
	SRW percentage	0.28		0.35		0.6		0.34		0.2		0.25		0.29		33% ± 13	
	Volume (cc)	0.8	0.2	0.6	0.2	0.4	0.2	0.7	0.2	0.6	0.2	0.7	0.1	0.7	0.2	0.69 ± 0.07	0.19 ± 0.04
	SRV percentage	0.29		0.25		0.33		0.29		0.33		0.14		0.29		27% ± 6	
Group 3 (n = 7)	Weight (g)	0.5	0.29	0.58	0.33	0.47	0.29	0.68	0.42	0.58	0.37	0.8	0.32	0.61	0.35	0.60 ± 0.11	0.34 ± 0.05
	SRW percentage	0.58		0.57		0.62		0.62		0.64		0.4		0.57		57% ± 8	
	Volume (cc)	0.5	0.3	0.6	0.3	0.5	0.3	0.7	0.4	0.6	0.4	0.8	0.3	0.6	0.4	0.61 ± 0.1	0.36 ± 0.05
	SRV percentage	0.6		0.67		0.6		0.57		0.67		0.37		0.67		60% ± 10	

Abbreviations: DMSO, dimethyl sulfoxide; SD, standard deviation.

group 2 ( $p = 0.001$ ) There were no statistically significant differences in the POSTOP-AFG-W or POSTOP-AFG-VOL between groups 1 and 2 ( $p > 0.05$ ) (see ►Table 2).

SRW (26, 33, and 57%) of the apocynin-treated AFGs was found to be higher compared with group 1 ( $p = 0.002$ ) or group 2 ( $p = 0.009$ ), while there were no significant SRW and SRV differences observed between the DMSO- and saline-alone treated AFGs ( $p > 0.05$ ) (see ►Table 3). A statistically significant difference was found in the SRV between all the groups ( $p = 0.001$ ). In paired comparisons between the groups, the SRV (19, 27, and 60%) of group 3 was found to be significantly higher compared with group 1 ( $p = 0.002$ ) and group 2 ( $p = 0.002$ ) (see ►Table 3).

Mitochondrial activity, indicator of live cells, was estimated by the colorimetric MTT assay. The survival of saline-treated (group 1) AFG-derived cells was used as control and for normalization purposes was set to 100%. The statistical mean and SD of cell viability for group 2 and group 3 were  $106 \pm 2.38$  and  $163 \pm 2.08\%$ , respectively. There was a statistically significant difference in cell survival between the groups ( $p < 0.05$ ). The MTT-generated absorbance signals in group 3 were markedly higher compared with group 1 ( $p = 0.001$ ) and group 2 ( $p = 0.002$ ). Surprisingly, DMSO treatment alone also caused a significant pro-survival effect when compared with the saline treatment conditions of AFGs ( $p = 0.001$ ) (see ►Table 3).

According to the microscopic evaluation data of excised AFGs, the lowest degree of vascularity was detected in the saline-treated AFGs (group 1) and the most vascular specimens were seen in the apocynin-treated AFGs (group 3) (►Fig. 7). There were no statistically significant differences found in the histopathological parameters such as lipogranuloma formation, the presence of cyst(s), fibrosis, or inflammation between the groups ( $p > 0.05$ ) (►Table 4, ►Fig. 8–9).

## Discussion

AFG is a multi-purpose procedure that is performed millions of times each year by various medical disciplines worldwide for aesthetic and reconstructive aims. Only the number of AFG applied to the face by plastic surgeons was 598,823 in 2019 worldwide, and it increases every year.<sup>27</sup> Although AFG is an ideal filling procedure with many features, the main disadvantage of this method is its RR that can lead to unpredictable long-term results.<sup>7,8</sup> There are numerous experimental substances that have been reported to reduce RR in various steps of AFG, such as vitamin E, platelet-rich plasma, growth factors, curcumin, estradiol, acetylcysteine, insulin,  $\beta$  blockers, and deferoxamine.<sup>28–33</sup> In the present study, we showed that local application of apocynin decreases the RR of AFG and improves the graft survival. The SRW (26, 33, and 57%) and the SRV (19, 27, and 60%) of fat grafts were found to be higher in apocynin-treated group compared with other groups.

Several cellular and molecular mechanisms underlying graft resorption after AFG have been reported so far. Currently, there are three basic (graft survival, host cell

**Table 2** Evaluation of weight and volume parameters of preoperative and postoperative saline (group 1, control), DMSO (group 2), and apocynin (group 3) treated autologous fat graft

Physical parameter	Measurement time	Group 1 (n = 7)	Group 2 (n = 7)	Group 3 (n = 7)	p Value (between groups)
Weight (g)	Preoperative	0.70 ± 0.08	0.63 ± 0.11	0.60 ± 0.11	0.192
	Postoperative	0.19 ± 0.07	0.2 ± 0.04	0.34 ± 0.05	<b>0.002<sup>b</sup></b>
p-Value (within group)		<b>0.018<sup>a</sup></b>	<b>0.018<sup>a</sup></b>	<b>0.018<sup>a</sup></b>	
Volume (cc)	Preoperative	0.67 ± 0.11	0.69 ± 0.07	0.61 ± 0.1	0.34
	Postoperative	0.13 ± 0.05	0.19 ± 0.04	0.36 ± 0.05	<b>0.002<sup>b</sup></b>
p-Value (within group)		<b>0.017<sup>a</sup></b>	<b>0.017<sup>a</sup></b>	<b>0.014<sup>a</sup></b>	

Abbreviations: DMSO, dimethyl sulfoxide

<sup>a</sup>Wilcoxon Signed Ranks Test  $p < 0.05$ <sup>b</sup>Kruskal–Wallis Test  $p < 0.05$ **Table 3** Estimated exact between group statistical significance p-values of physical parameters of 2-week saline (group 1, control), DMSO (group 2), and apocynin (group 3) treated autologous fat grafts evaluated 90 days after the grafting surgery

p	Compared groups	SRW	SRV	MTT	POSTOP-W	POSTOP-VOL
	1–2–3	<b>0.003<sup>a</sup></b>	<b>0.001<sup>a</sup></b>	<b>0.0001<sup>a</sup></b>	<b>0.002<sup>a</sup></b>	<b>0.002<sup>a</sup></b>
	1–2	0.4	0.07	<b>0.001<sup>b</sup></b>	0.654	0.07
	1–3	<b>0.002<sup>b</sup></b>	<b>0.002<sup>a</sup></b>	<b>0.001<sup>b</sup></b>	<b>0.004<sup>b</sup></b>	<b>0.001<sup>b</sup></b>
	2–3	<b>0.009<sup>b</sup></b>	<b>0.002<sup>a</sup></b>	<b>0.002<sup>b</sup></b>	<b>0.002<sup>b</sup></b>	<b>0.001<sup>b</sup></b>

Abbreviations: MTT; 3-(4,5-dimethylthiazol-2-yl)-2,5-diphenyltetrazolium bromide; POSTOP-VOL; postoperative volume; POSTOP-W; postoperative weight; SRV; survival rates for volume; SRW, survival rates for weight.

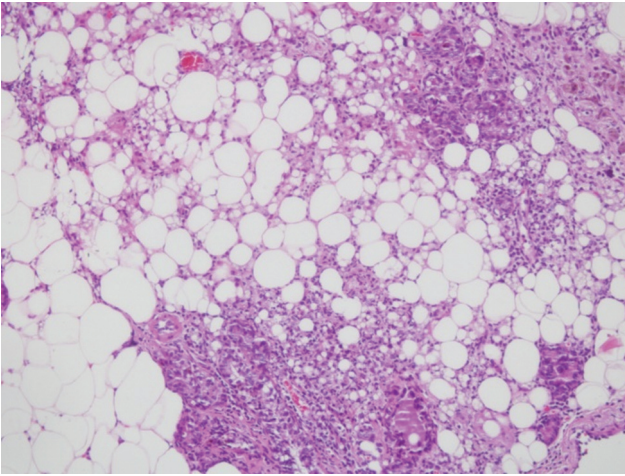
<sup>a</sup>Kruskal–Wallis Test  $p < 0.05$ <sup>b</sup>Mann–Whitney U Test  $p < 0.05$ **Table 4** Histopathological parameters of 2-week saline (group 1, control), DMSO (group 2), and apocynin (group 3) treated autologous fat grafts evaluated 90 days after the grafting surgery

Histopathological parameters	Density	Group 1 (saline) (n = 7)	Group 2 (DMSO) (n = 7)	Group 3 (apocynin) (n = 7)	p <sup>a</sup>
		n	n	n	
Lipogranuloma	None	6	5	4	0.45
	Mild	1	2	2	
	Moderate	0	0	1	
Cyst	None	5	4	7	0.17
	Mild	2	3	0	
Fibrosis	None	5	5	7	0.17
	Mild	2	1	0	
	Moderate	0	1	0	
Inflammation	None	5	4	5	0.72
	Mild	2	2	2	
	Moderate	0	1	0	

<sup>a</sup>Kruskal–Wallis test

replacement, and graft replacement) theories explaining how fat grafts remain alive after the grafting procedure.<sup>34–36</sup> In Peer's "graft survival theory," the count of the surviving adipocytes is the main factor determining the graft permanence.<sup>35</sup>

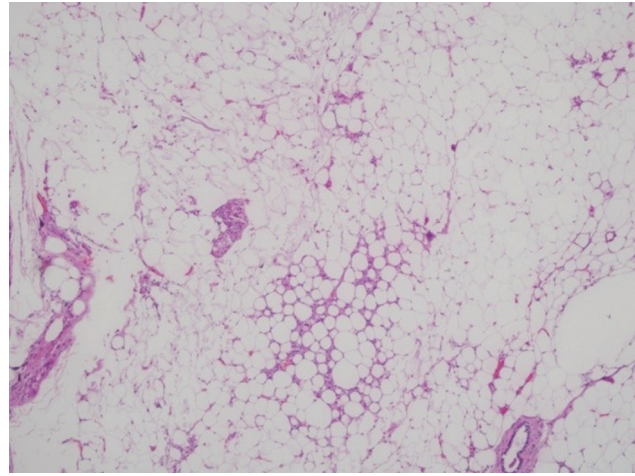
Mechanical trauma that increases the production of inflammatory cytokines and ROSs during grafting is inevitable and causes the modulation in adipocyte gene expression.<sup>37</sup> Coleman showed that 50% of the adipocytes undergo necrosis due to oxidation when exposed to air during the



**Fig. 8** Cellular infiltration, fibrosis, and micro-cyst formation observed in the saline-treated (control) group (H&E, x10). H&E, hematoxylin and eosin.

preparation of the fat graft.<sup>38</sup> The adipocytes are also exposed to ischemia and inflammation in the recipient area.<sup>31</sup> These factors, to which adipocytes are exposed, damage the cell membrane and, thus, cause cell death by apoptosis and necrosis.<sup>31</sup> Accordingly, a recipient site with increasing vascularity and subsiding oxidative stress and inflammation reactions would positively affect fat grafting outcomes by reducing cell death by apoptosis as in a conventional wound healing setting.<sup>39–41</sup> Therefore, it has been speculated that anti-oxidant and anti-apoptotic molecules play a critical role in either induction or maintenance of pro-healing microenvironment capable of reducing the resorption of the graft. In a search of clinically effective substances with minimal side effects, the compounds such as acetylcysteine, DMSO, coenzyme Q10, niacin B3, and curcumin have been used to prevent fat graft resorption with varying outcomes.<sup>30–33</sup> Therefore, there is a requirement for a better substance that can be easily adjusted for clinical use.

The anti-inflammatory, anti-oxidant, and anti-apoptotic effects of apocynin have been demonstrated in several studies.<sup>42–45</sup> To investigate the pharmacological effects of apocynin on animal models, the intraperitoneal administration method has been used most frequently.<sup>45</sup> After the promising results of systemically used apocynin, we designed this study to determine the effect of local application of apocynin on the AFG to facilitate possible clinical use and reduce possible side effects.<sup>23</sup> Only male animals were included in this experiment to avoid hormonal effects, mainly estrogen, which could affect adipose metabolism.<sup>46</sup> Like in our prior experiment,<sup>23</sup> the inguinal fat pad, the largest adipose tissue in rats,<sup>47</sup> was used as the potential autograft. There are various methods for creating AFGs.<sup>12</sup> The fat graft transfer without any procedure, which is one of these methods, is not preferred today because it causes more necrosis than other techniques such as liposuction or slicing the graft into small pieces.<sup>48</sup> In addition, there is no donor area with a sufficient amount of adipose tissue that can be harvested by a vacuum technique in rats and it is problematic to calculate the RR of the graft transplanted



**Fig. 9** Normal viable adipose tissue with minimal lipogranuloma observed in the apocynin-treated group (H&E, x10). H&E, hematoxylin and eosin.

with a vacuum.<sup>23</sup> For these reasons, the technique that results in the highest RR of AFGs was used to determine the potential pro-survival effects of apocynin in this study, and the graft was transplanted in one piece without any procedure, unlike in the current clinical practice. Previous studies show that fat cells can tolerate hypoxia for approximately 24 hours due to their low metabolic activities.<sup>49</sup> However, many studies have suggested that the graft material should be transferred to the recipient site no later than 1 hour after harvest, since adipocytes may lose their viability due to ischemia.<sup>50,51</sup> Mecott et al showed that there was no difference in the number of living fat cells between the adipose tissue transferred right after harvesting and the adipose tissue transferred after a 30 minutes decantation period.<sup>52</sup> In our study, in accordance with this information, we completed all our measurements within 5 minutes after harvesting and transferred the adipose tissue to the recipient area.

Although the adipocytes constitute just 20% or less of total cells in lipoaspirate material, the number of these cells is the main factor that determines the final volume of the graft.<sup>48</sup> Due to the delicate structure and high metabolic rate of adipocytes, almost 20% of these cells undergo apoptosis at the early stages of fat tissue grafting.<sup>31,53</sup> The absorption of the fat grafts was investigated by Eto et al who described the three-zone graft survival theory. In this theory, the avascular graft is divided into three zones: an outer “the survival zone,” an intermediate “the regenerative zone,” and a central “the necrotic zone”.<sup>48</sup> Eto et al. reported that the most mature adipocytes that reside in the intermediate regenerative and central necrotic zones are the most sensitive to ischemia among all cellular components of lipoaspirate and undergo apoptosis and release inflammatory factors in the first 24 hours post-surgery. However adipose tissue-derived stem cells, which are relatively resistant to ischemia, could remain alive for 3 more days in the regenerative graft zone, and the survival rate of these cells eventually determines the final graft volume.<sup>48</sup> Previous studies reported that the proportion of newly formed adipocytes in the regenerative

graft zone achieve base levels 3 months after grafting and that the “acute” regenerative and lipogenic phase is completed at the end of the third-month post-surgery.<sup>54</sup> Afterward, an acute “chronic” stabilizing process begins and fat tissue volume does not reduce.<sup>54</sup> Therefore, in this study, we began apocynin injections immediately after the grafting, applied daily for 14 days, similar to previous studies, and ended the study on the 90th day of the experiment.<sup>23,55,56</sup> Since apocynin was dissolved in DMSO, a separate group was established to examine the effects that may be caused by DMSO treatment alone.

In this experimental study, the apocynin group was found to be statistically superior to other groups in terms of the macroscopic dimension, macro/microscopic vascularity, SRW percentage and SRV percentage, and the count of living cells with MTT assay ( $p < 0.05$ ). There was no significant difference according to pathology. The reason for this may be that we prepared a single histopathological section from the graft center, which was accepted as the last site to be reached by angiogenesis. However, previous studies showed that no regeneration occurs in the center of the graft and the central necrotic space is either absorbed or occupied by new fibrous tissue.<sup>57</sup> To define a significant difference in histopathological parameters across the entire AGF, a multi-slice evaluation of each specimen is required.

This experimental study, which showed the positive effects of apocynin in fat grafting, has some limitations. The first limitation is that we transferred the fat graft as a single piece, unlike the clinical practice. The second limitation is that we administered apocynin for 14 days, which may not be possible in clinical practice.

In conclusion, in this experimental study, we showed that local application of apocynin decreases the fat graft volume and weight loss in an AFG model created in rats. Apocynin can be used locally as an absorption-reducing substance in the AFG procedure. Repetition of similar experiments on a larger number of same and different species of animals, using the same and/or different doses with single dose or shorter administration times and similar evaluation methods, is needed to further confirm a positive role of apocynin in supporting fat graft survival.

#### Ethical Statement

The study was conducted in Acibadem University Experimental Animal Application and Research Center with the approval of Acibadem University Local Ethics Committee (decision no: 12.08/51). All institutional and national guidelines for the care and use of laboratory animals were followed.

#### Contributions

Each of the authors has contributed to reading and approved this manuscript. The experiment was done by ERK and SC. The article was written by DC. This manuscript is original and it or any part of it has not been previously published, and it is not under consideration for publication elsewhere.

#### Funding

None.

#### Conflict of Interest

None declared.

#### Acknowledgment

The authors thank the staff of Cerrahpaşa Medical Faculty, Department of Pathology.

#### References

- Bohluli B, Bagheri SC, Consky EK. Fat grafting as an adjunct to facial rejuvenation procedures. *Atlas Oral Maxillofac Surg Clin North Am* 2018;26(01):51–57
- Strong AL, Cederna PS, Rubin JP, Coleman SR, Levi B. The current state of fat grafting: a review of harvesting, processing, and injection techniques. *Plast Reconstr Surg* 2015;136(04):897–912
- Abu-Ghname A, Perdanasari AT, Reece EM. Principles and applications of fat grafting in plastic surgery. *Semin Plast Surg* 2019;33(03):147–154
- Hoppela E, Grönroos TJ, Saarikko AM, et al. Fat grafting can induce browning of white adipose tissue. *Plast Reconstr Surg Glob Open* 2018;6(06):e1804
- Sezgin B, Özmen S. Fat grafting to the face with adjunctive microneedling: a simple technique with high patient satisfaction. *Turk J Med Sci* 2018;48(03):592–601
- Guisantes E, Fontdevila J, Rodríguez G. Autologous fat grafting for correction of unaesthetic scars. *Ann Plast Surg* 2012;69(05):550–554
- Minn KW, Min KH, Chang H, Kim S, Heo EJ. Effects of fat preparation methods on the viabilities of autologous fat grafts. *Aesthetic Plast Surg* 2010;34(05):626–631
- MacRae JW, Tholpady SS, Ogle RC, Morgan RF. Ex vivo fat graft preservation: effects and implications of cryopreservation. *Ann Plast Surg* 2004;52(03):281–282, discussion 283
- Park B, Kong JS, Kang S, Kim YW. The effect of epidermal growth factor on autogenous fat graft. *Aesthetic Plast Surg* 2011;35(05):738–744
- Por YC, Yeow VK, Louri N, Lim TK, Kee I, Song IC. Platelet-rich plasma has no effect on increasing free fat graft survival in the nude mouse. *J Plast Reconstr Aesthet Surg* 2009;62(08):1030–1034
- Fraga MF, Helene A Jr, Nakamura F, Lellis RF, Kikuchi W, Esteban D. Comparative study of the integration and viability of autologous and nonautologous autologous fat tissue grafts—experimental model in rabbits. *J Plast Reconstr Aesthet Surg* 2008;61(09):1044–1048
- Pu LL, Coleman SR, Cui X, Ferguson RE Jr, Vasconez HC. Cryopreservation of autologous fat grafts harvested with the Coleman technique. *Ann Plast Surg* 2010;64(03):333–337
- Grewal N, Yacomotti L, Melkonyan V, Massey M, Bradley JP, Zuk PA. Freezing adipose tissue grafts may damage their ability to integrate into the host. *Connect Tissue Res* 2009;50(01):14–28
- Kim SK, Yang JY, Kim CW, Baek SH, Kim U, Hwang E. The effect of hyaluronidase on the fat graft. *J Craniofac Surg* 2020;31(03):618–621
- Cin B, Ciloglu NS, Omar S, Terzi NK. Effect of rosmarinic acid and alcohol on fat graft survival in rat model. *Aesthetic Plast Surg* 2020;44(01):177–185
- Laddha AP, Kulkarni YA. NADPH oxidase: a membrane-bound enzyme and its inhibitors in diabetic complications. *Eur J Pharmacol* 2020;881:173206
- Cui H, Kong Y, Zhang H. Oxidative stress, mitochondrial dysfunction, and aging. *J Signal Transduct* 2012;2012:646354
- Stefanska J, Pawliczak R. Apocynin: molecular aptitudes. *Mediators Inflamm* 2008;2008:106507



- 19 Heumüller S, Wind S, Barbosa-Sicard E, et al. Apocynin is not an inhibitor of vascular NADPH oxidases but an antioxidant. *Hypertension* 2008;51(02):211–217
- 20 Riganti C, Costamagna C, Bosia A, Ghigo D. The NADPH oxidase inhibitor apocynin (acetovanillone) induces oxidative stress. *Toxicol Appl Pharmacol* 2006;212(03):179–187
- 21 Vejrazka M, Míček R, Stípek S. Apocynin inhibits NADPH oxidase in phagocytes but stimulates ROS production in non-phagocytic cells. *Biochim Biophys Acta* 2005;1722(02):143–147
- 22 Du ZD, Yu S, Qi Y, et al. NADPH oxidase inhibitor apocynin decreases mitochondrial dysfunction and apoptosis in the ventral cochlear nucleus of D-galactose-induced aging model in rats. *Neurochem Int* 2019;124:31–40
- 23 Keskin ER, Çakan D. The effect of apocynin on fat graft survival. *Aesthetic Plast Surg* 2021;45(04):1843–1852
- 24 Alley MC, Scudiero DA, Monks A, et al. Feasibility of drug screening with panels of human tumor cell lines using a microculture tetrazolium assay. *Cancer Res* 1988;48(03):589–601
- 25 Carmichael J, DeGraff WG, Gazdar AF, Minna JD, Mitchell JB. Evaluation of a tetrazolium-based semiautomated colorimetric assay: assessment of chemosensitivity testing. *Cancer Res* 1987;47(04):936–942
- 26 Faul F, Erdfelder E, Lang A-G, Buchner A. G\*Power 3: a flexible statistical power analysis program for the social, behavioral, and biomedical sciences. *Behav Res Methods* 2007;39(02):175–191
- 27 International Society of Aesthetic Plastic Surgery. Global Survey Results (2019). . Accessed April 29, 2021 <https://www.isaps.org/wp-content/uploads/2020/12/Global-Survey-2019.pdf>
- 28 Yuksel E, Weinfeld AB, Cleek R, et al. Increased free fat-graft survival with the long-term, local delivery of insulin, insulin-like growth factor-I, and basic fibroblast growth factor by PLGA/PEG microspheres. *Plast Reconstr Surg* 2000;105(05):1712–1720
- 29 Ayhan M, Senen D, Adanali G, Görgü M, Erdoğan B, Albayrak B. Use of beta blockers for increasing survival of free fat grafts. *Aesthetic Plast Surg* 2001;25(05):338–342
- 30 Temiz G, Sirinoglu H, Yesiloglu N, Filinte D, Kaçmaz C. Effects of deferoxamine on fat graft survival. *Facial Plast Surg* 2016;32(04):438–443
- 31 Medina MA III, Nguyen JT, Kirkham JC, et al. Polymer therapy: a novel treatment to improve fat graft viability. *Plast Reconstr Surg* 2011;127(06):2270–2282
- 32 Gillis J, Gebremeskel S, Phipps KD, et al. Effect of n-acetylcysteine on adipose-derived stem cell and autologous fat graft survival in a mouse model. *Plast Reconstr Surg* 2015;136(02):179e–188e
- 33 Medina MA, Lee JH, Kirkham JC, McCormack MC, Randolph MA, Austen WG. Fat grafting, ischemia reperfusion, apoptosis, antioxidants. *J Surg Res* 2011;165(02):323–328
- 34 Shih L, Davis MJ, Winocour SJ. The science of fat grafting. *Semin Plast Surg* 2020;34(01):5–10
- 35 Peer LA. Loss of weight and volume in human fat grafts with postulation of a “Cell Survival Theory”. *Plast Reconstr Surg* 1950;5:217–230
- 36 Oranges CM, Striebel J, Tremp M, et al. The preparation of the recipient site in fat grafting: a comprehensive review of the preclinical evidence. *Plast Reconstr Surg* 2019;143(04):1099–1107
- 37 Espiritu DJ, Mazzone T. Oxidative stress regulates adipocyte apolipoprotein e and suppresses its expression in obesity. *Diabetes* 2008;57(11):2992–2998
- 38 Coleman SR. Facial recontouring with lipostructure. *Clin Plast Surg* 1997;24(02):347–367
- 39 Maumus M, Sengenès C, Decaunes P, et al. Evidence of in situ proliferation of adult adipose tissue-derived progenitor cells: influence of fat mass microenvironment and growth. *J Clin Endocrinol Metab* 2008;93(10):4098–4106
- 40 Çakan D, Aydın S, Demir G, Başak K. The effect of curcumin on healing in an animal nasal septal perforation model. *Laryngoscope* 2019;129(10):E349–E354
- 41 Ghosh A, Kanthasamy A, Joseph J, et al. Anti-inflammatory and neuroprotective effects of an orally active apocynin derivative in pre-clinical models of Parkinson's disease. *J Neuroinflammation* 2012;9:241
- 42 Kinkade K, Streeter J, Miller FJ. Inhibition of NADPH oxidase by apocynin attenuates progression of atherosclerosis. *Int J Mol Sci* 2013;14(08):17017–17028
- 43 Joshi S, Saylor BT, Wang W, Peck AB, Khan SR. Apocynin-treatment reverses hyperoxaluria induced changes in NADPH oxidase system expression in rat kidneys: a transcriptional study. *PLoS One* 2012;7(10):e47738
- 44 Pan L, Qian S. Apocynin promotes neural function recovery and suppresses neuronal apoptosis by inhibiting Tlr4/NF-κB signaling pathway in a rat model of cerebral infarction. *Int J Immunopathol Pharmacol* 2018;32:2058738418817700
- 45 Savla SR, Laddha AP, Kulkarni YA. Pharmacology of apocynin: a natural acetophenone. *Drug Metab Rev* 2021;53(04):542–562
- 46 Varghese J, Griffin M, Mosahebi A, Butler P. Systematic review of patient factors affecting adipose stem cell viability and function: implications for regenerative therapy. *Stem Cell Res Ther* 2017;8(01):45
- 47 Nasir S, Aydın MA, Karahan N, Altuntaş S. Fat tissue as a new vascular carrier for prefabrication in reconstructive surgery: experimental study in rats. *J Plast Reconstr Aesthet Surg* 2008;61(07):799–806
- 48 Eto H, Kato H, Suga H, et al. The fate of adipocytes after non-vascularized fat grafting: evidence of early death and replacement of adipocytes. *Plast Reconstr Surg* 2012;129(05):1081–1092
- 49 Suga H, Eto H, Aoi N, et al. Adipose tissue remodeling under ischemia: death of adipocytes and activation of stem/progenitor cells. *Plast Reconstr Surg* 2010;126(06):1911–1923
- 50 Mecott GA, Gonzalez IZ, Montes de Oca R, et al. Effect of decantation time on viability and apoptosis in adipocytes after liposuction. *Aesthetic Plast Surg* 2019;43(01):228–232
- 51 Coban YK, Ciralik H. The effects of increased ischemic times on adipose tissue: a histopathologic study using the epigastric flap model in rats. *Aesthetic Plast Surg* 2007;31(05):570–573
- 52 Mecott GA, Cueto-Ramos RG, González-Martínez A, et al. Determination of the ratio of the decantation time and the separation of components in lipoaspirate. *Ann Plast Surg* 2020;85(05):e7–e11
- 53 Wang WZ, Fang XH, Williams SJ, et al. Analysis for apoptosis and necrosis on adipocytes, stromal vascular fraction, and adipose-derived stem cells in human lipoaspirates after liposuction. *Plast Reconstr Surg* 2013;131(01):77e–85e
- 54 Mashiko T, Yoshimura K. How does fat survive and remodel after grafting? *Clin Plast Surg* 2015;42(02):181–190
- 55 Hu L, Zhang Y, Lim PS, et al. Apocynin but not L-arginine prevents and reverses dexamethasone-induced hypertension in the rat. *Am J Hypertens* 2006;19(04):413–418
- 56 Tan YC, Abdul Sattar M, Ahmeda AF, et al. Apocynin and catalase prevent hypertension and kidney injury in cyclosporine A-induced nephrotoxicity in rats. *PLoS One* 2020;15(04):e0231472
- 57 Liao HT, Marra KG, Rubin JP. Application of platelet-rich plasma and platelet-rich fibrin in fat grafting: basic science and literature review. *Tissue Eng Part B Rev* 2014;20(04):267–276