

Effect of Teriparatide on Subsequent Fracture and Bone Mineral Density in 47 Women with Pregnancy- and Lactation-associated Osteoporosis and Vertebral Fractures

Auswirkung von Teriparatid auf nachfolgende Frakturen und Knochendichte bei 47 Frauen mit schwangerschaftsassoziierter Osteoporose und Wirbelfrakturen



Authors

Peyman Hadji^{1,2}, Niki Mouzakiti³, Ioannis Kyvernitis⁴

Affiliations

- 1 Frankfurt Centre for Bone Health, Frankfurt, Germany
- 2 Philipps-University of Marburg, Marburg, Germany
- 3 Dpt. of Obstetrics and Gynaecology, Centre for Ultrasound and Prenatal Medicine, Buergerhospital and Clementine Children's Hospital Frankfurt a. M., Dr. Senckenberg Foundation and Johann-Wolfgang-Goethe University of Frankfurt, Frankfurt, Germany
- 4 Dpt. Of Obstetrics and Prenatal Medicine, Asklepios Clinic Barmbek, University of Semmelweis, Hamburg, Germany

Key words

fracture osteoporosis, teriparatide, pregnancy, lactation

Schlüsselwörter

osteoporotische Frakturen, Teriparatid, Schwangerschaft, Stillzeit

received 4. 11. 2021

accepted after revision 1. 4. 2022

Bibliography

Geburtsh Frauenheilk 2022; 82: 619–626

DOI 10.1055/a-1816-6700

ISSN 0016-5751

© 2022. The Author(s).

This is an open access article published by Thieme under the terms of the Creative Commons Attribution-NonDerivative-NonCommercial-License, permitting copying and reproduction so long as the original work is given appropriate credit. Contents may not be used for commercial purposes, or adapted, remixed, transformed or built upon. (<https://creativecommons.org/licenses/by-nc-nd/4.0/>)

Georg Thieme Verlag KG, Rüdigerstraße 14,
70469 Stuttgart, Germany

Correspondence

Prof. Dr. Ioannis Kyvernitis

Dpt. of Obstetrics and Gynaecology, Asklepios Clinic Barmbek
Ruebenkamp 220, 22307 Hamburg, Germany

i.kyvernitis@asklepios.com

ABSTRACT

Introduction Pregnancy- and lactation-associated osteoporosis (PLO) with predominantly vertebral fractures is a rare but severe disease which can occur in the last trimester of pregnancy or postpartum. The aim of the present study was to assess the impact of teriparatide on subsequent fractures and bone mineral density (BMD) in patients with PLO.

Materials and Methods A total of 47 patients with PLO and postpartum spinal fractures (mean: 4 fractures) undergoing treatment with teriparatide were investigated. The data collection period was set between 2006 and 2018. All patients received a subcutaneous injection of 20 µg teriparatide once a day for 24 months as well as individually adapted vitamin D supplementation. After 24 months of treatment, all women received no further treatment and either had regular menstrual cycles or took oral contraceptives. Fractures were confirmed by X-ray or MRI. Changes in BMD from baseline were examined using serial DXA measurements.

Results After 24 months of teriparatide treatment, we could demonstrate an increase in BMD at the lumbar spine, femoral neck and total hip of +30.1%, +11.7% and +12.2% respectively ($p < 0.001$ for all). At 12 months after cessation of treatment, BMD remained stable compared to the 24-month measurements at the lumbar spine, femoral neck and total hip which showed non-significant changes of +1.4%, +2.6% and +4.1% respectively. Out of the 47 patients with PLO with a mean of 4 existing fractures, 4 patients (7.8%) sustained a subsequent fracture, two after 3–5 months of treatment and two at > 6 months of treatment.

Conclusion 24 months of treatment with teriparatide in women with PLO and multiple vertebral fractures significantly increased BMD, predominantly BMD of the spine. As patients were premenopausal, there was no significant decrease in BMD in the following 12 months after cessation of treatment.

ZUSAMMENFASSUNG

Einleitung Schwangerschaftsassozierte Osteoporose (PLO) mit Wirbelfrakturen ist eine seltene, aber ernste Erkrankung, die im letzten Trimenon oder nach der Geburt auftreten kann. Ziel dieser Studie war es, die Auswirkung von Teriparatid auf nachfolgend auftretende Frakturen sowie die Knochendichte (BMD) bei Patientinnen mit PLO zu evaluieren.

Material und Methoden Untersucht wurden insgesamt 47 Patientinnen mit PLO und postpartalen Wirbelfrakturen (Durchschnitt: 4 Frakturen), die mit Teriparatid behandelt wurden. Die Daten wurden zwischen 2006 und 2018 gesammelt. Alle Patientinnen erhielten einmal täglich eine subkutane Injektion von 20 µg Teriparatid über einen Zeitraum von 24 Monaten sowie eine individuell angepasste Supplementierung mit Vitamin D. Nach 24 Monaten Behandlung wurde die Behandlung ausgesetzt. Alle Frauen hatten entweder regelmäßige Menstruationszyklen oder nahmen orale Kontrazeptiva. Das Vorhandensein von Frakturen wurde entweder durch Röntgenuntersuchungen oder MRT bestätigt. Änderungen der Knochendichte-Ausgangswerte wurden mit DXA-Messungen festgestellt.

Ergebnisse Nach 24 Monaten Teriparatid-Behandlung wurde eine Zunahme der Knochendichte im Lendenwirbelbereich, am Schenkelhals und über die gesamte Hüfte in Höhe von +30,1%, +11,7% bzw. +12,2% festgestellt ($p < 0,001$ für alle Werte). Zwölf Monate nach Einstellung der Behandlung war die Knochendichte stabil verglichen mit den Messungen an der Lendenwirbelsäule, an Schenkelhals und der gesamten Hüfte nach 24 Monaten; es wurden nichtsignifikante Änderungen in Höhe von +1,4%, +2,6% bzw. +4,1% gemessen. Von den insgesamt 47 Patientinnen mit PLO und durchschnittlich 4 Frakturen erlitten 4 Patientinnen (7,8%) nach Beginn der Behandlung 1 Fraktur, davon 2 nach 3–5 Monaten Behandlung und 2 nach mehr als 6 Monaten Behandlung.

Schlussfolgerung Eine Behandlung mit Teriparatid über 24 Monate bei Frauen mit PLO und mehreren Wirbelfrakturen führt zu einer signifikanten Zunahme der Knochendichte, vor allem im Bereich der Wirbelsäule. Da alle Patientinnen noch prämenopausal waren, gab es keine signifikante Abnahme der Knochendichte 12 Monate nach Einstellung der Behandlung.

Introduction

Osteoporosis occurs predominantly in postmenopausal women, and osteoporosis-related spine and hip fractures are associated with increased morbidity and mortality rates [1]. Pregnancy- and lactation-associated osteoporosis (PLO) is a rare, but in most cases severe, type of premenopausal osteoporosis and was first described as a clinical syndrome in 1955 by Nordin et al. Today, the incidence is estimated to be 0.4 per 100 000 women [2,3]. According to the World Health Organisation (WHO), osteoporosis is defined as a T-score of -2.5 or less at the hip or spine in postmenopausal women and men [4]. For premenopausal women, the International Society for Clinical Densitometry (ISCD) suggested using the z-score to identify patients at high risk of fracture [5]. A medical intervention should be considered in patients with a z-score of ≤ 2 or accompanied by the fragility fractures during or after pregnancy. Most agents available to treat osteoporosis are either contraindicated or of unknown efficacy in premenopausal women, and the possible impact on the foetus is also unknown.

PLO is a rare condition which occurs predominantly in the first pregnancy (70%), occurring in the last trimester of pregnancy or immediately postpartum [6]. Pregnancy and lactation are both high maintenance periods with regard to skeletal health. Although the mechanisms of bone mineral density alteration during those periods are unknown [3], it is well documented that increased calcium requirements during foetal and neonatal development should be met by synergistically increasing intestinal calcium absorption [7]. During both pregnancy and the period of lactation, parathyroid hormone levels (PTH) increase, leading to osteoclast activation which leads to elevated serum calcium levels and a subsequent loss in bone mineral density [8]. In addition to the role of the parathyroid hormone in physiological pregnancy, it should be noted that parathyroid hormone-related peptide (PTHrP) also

plays a pivotal role in calcium homeostasis during pregnancy, which is quite distinct from its pathophysiological mechanism of action in the setting of tumour-induced humoral hypercalcaemia. In contrast, serum PTH decreases during pregnancy to a low normal range during the first trimester and may increase back to mid-normal ranges by the end of gestation [7]. It is unknown why most women preserve bone homeostasis while in others, pregnancy or lactation leads to fragility fractures; genetic skeletal predisposition undoubtedly contributes to this catabolic process [9,10]. The rarity of this disease is a key issue when diagnosing PLO. PLO should be suspected in all pregnant or breastfeeding women complaining of severe, persistent and treatment-resistant back and/or lower back pain. The indistinct clinical symptoms present in pregnancy often considered to be benign antenatal discomfort, the high incidence of musculoskeletal complaints, and the hesitation to perform diagnostic imaging during pregnancy often severely delay the detection of PLO. Therefore, PLO remains underreported and undertreated [11,12]. If undetected and untreated, PLO can lead to an accumulation of vertebral compression fractures and subsequent fractures [13]. In addition to PLO with vertebral compression fractures, women may also be affected by transient osteoporosis of the hip, a multifactorial disease of unclear aetiology [14].

Physical activity, calcium intake, and vitamin D supplementation in combination with medical intervention play a key role in the treatment of osteoporosis [15]. Kovacs et al. addressed this and examined non-pharmacological as well as pharmacological approaches [9]. The non-pharmacological approach includes cessation of lactation as well as calcium and vitamin D supplementation. During lactation, an average of 300–400 mg of calcium is transferred daily from mother to child, which may lead to a maternal skeletal calcium loss of up to 5–10%. Remarkably, in most cases, this amount is fully regained at 6–12 months after cessa-

tion of lactation; therefore, the weaning process constitutes a major part of treatment [16]. Teriparatide (recombinant human parathyroid hormone, PTH) is a bone-forming agent, predominantly used in cases with severe osteoporosis [15]. Teriparatide enhances the anabolic osteoblast process, inhibits osteoblast apoptosis, and is hypothesised to even accelerate fracture healing [17]. Failure to this mechanisms causes severe back pain and facilitates vertebral prolapse following osteoporotic vertebral fracture, which may lead to neurological deficits [18].

We conducted the present analysis to investigate the effect of teriparatide on subsequent fracture risk and changes in lumbar spine, femoral neck, and total hip bone mineral density (BMD) in patients with PLO and at least one vertebral fracture.

Patients and Methods

We included a total of 47 patients with PLO who had suffered spine fractures postpartum and had been referred to the German reference centre for PLO between 2004 and 2018. This was a retrospective study using data collected between 2006 and 2018.

Methodology

All patients completed a standardised questionnaire including detailed history of disease and medication use known to effect bone health. Baseline characteristics were extracted from the data including age, height, weight, BMI, and age at menarche. We also obtained more detailed information, such as mode of delivery, timing of PLO in the context of the number of pregnancies, the use of oral contraceptives and history of assisted reproductive medicine prior to diagnosis with PLO. All BMD measurements and changes from baseline were obtained from the German PLO reference centre using serial dual-energy X-ray absorptiometry (DXA) performed with the same device (Prodigy; GE/Lunar). We have previously reported on the precision error and least significant change (LSC) of BMD measurements using this device [19, 20]. All fractures were confirmed by X-ray or MRI. Fractured vertebrae were excluded from BMD measurements in accordance with our standard operating procedures. All participants ceased breastfeeding once vertebral fractures were diagnosed. No previous history of antiresorptive treatment had been recorded, only a few patients had been administered glucocorticoids prior to PLO (10.6%). None of the patients had a previous history of osteoporotic fracture prior to pregnancy. None of the included women had a history of medication intake or disease that could interfere with bone metabolism and lead to secondary osteoporosis.

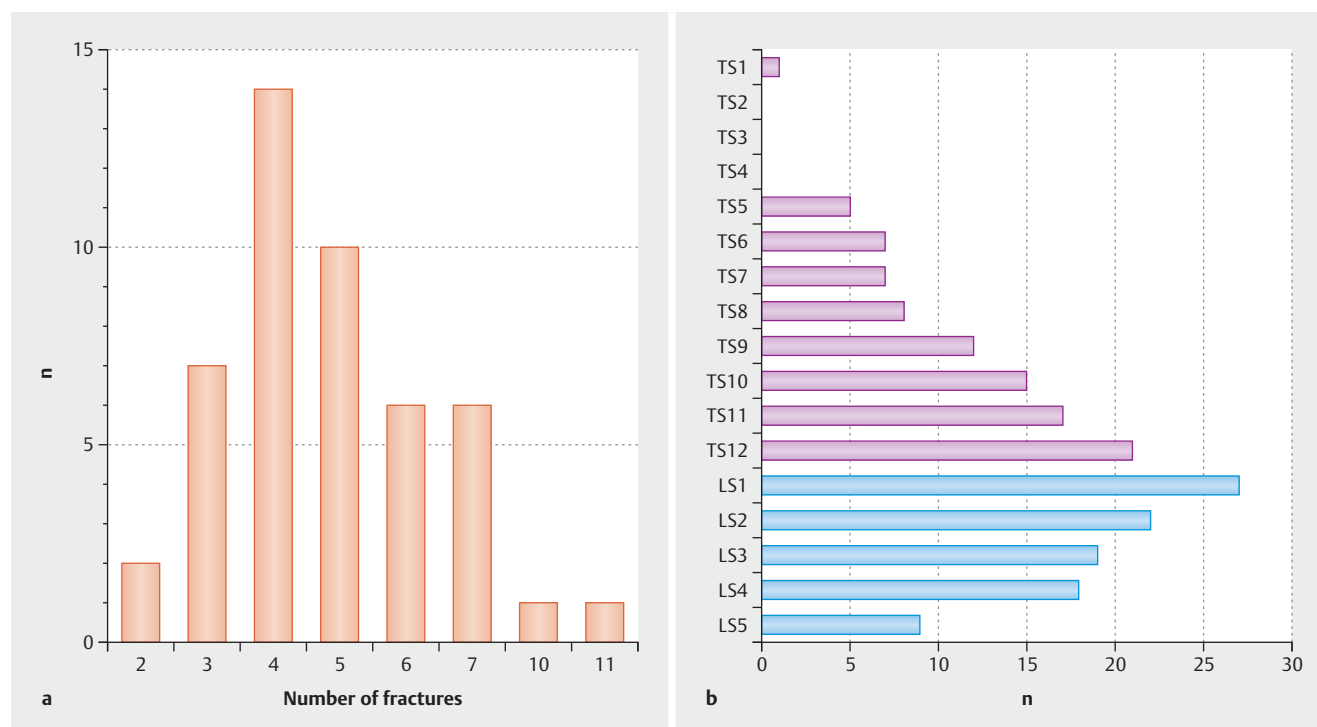
The treatment regimen consisted of subcutaneous injection with 20 µg teriparatide once daily for a total of 24 months. All patients were instructed on teriparatide administration, given dietary advice on improving bone health and ensuring an optimal calcium intake, and were supplemented with vitamin D if necessary. The patient's adherence to treatment was confirmed and documented at the 12- and 24-month visits. Teriparatide treatment was initiated immediately after the first visit to the German PLO reference centre. Informed consent was obtained from all patients; data analysis was permitted by the ethics committee of the University of Marburg and was conducted in accordance with German law and the Declaration of Helsinki.

► **Table 1** Baseline characteristics.

	N	Mean %	SD
Age (years)	47	34.2	4.8
Height (cm)	47	166.3	5.6
Weight (kg)	47	62.6	10.1
Body mass index (kg/m ²)	47	22.6	3.4
Age at menarche (years)	47	13.1	1.3

► **Table 2** Additional baseline characteristics.

		N	%
Mode of delivery for PLO pregnancy	Normal delivery	31	66.0
	Vaginal operative delivery	1	2.1
	Primary caesarean section	10	21.3
	Secondary caesarean section	5	10.6
Pregnancy when PLO was diagnosed	1st	39	83.0
	2nd	6	12.8
	3rd	1	2.1
	1st and 2nd	1	2.1
Use of oral contraceptives prior to PLO	No	5	10.6
	Yes	42	89.4
Use of assisted reproductive medicine prior to PLO	No	46	97.9
	Yes	1	2.1
Immobilisation during pregnancy	No	37	78.7
	Yes	10	21.3
Heparin during pregnancy	No	40	85.1
	Yes	7	14.9
Cycle irregularities prior to PLO (%)	No	31	66.0
	Yes	16	34.0
Secondary amenorrhoea (> 6 months) prior to PLO (%)	No	39	83.0
	Yes	8	17.0
Use of glucocorticoids prior to PLO	No	42	89.4
	Yes	5	10.6
Smoking prior to PLO (%)	No	42	89.4
	Yes	5	10.6
History of lactose intolerance (%)	No	40	85.1
	Yes	7	14.9
Family history of osteoporosis	no	33	70.2
	Yes	14	29.8



► **Fig. 1 a** Number of fractures at baseline in women with PLO (N = 47). Most patients suffered from 4 fractures and the number of fractures ranged between 3 and 7. **b** Location of spine fractures in women with PLO at baseline. The fractures were distributed between the lumbar and thoracic spine, with 72.3% of all fractures observed at the lumbar and 68.1% in the thoracic spine.

Statistical analysis

Statistical analysis was performed using IBM SPSS software, version 24.0. Statistical significance was achieved at a power of 0.8 and an α of 0.05. Spearman's correlation coefficient was used to obtain comparative results. Wilcoxon and Mann-Whitney U test were used to evaluate group differences, and baseline characteristics were analysed for normal distribution using χ^2 test and Fisher's exact test.

Results

Baseline characteristics

Our study included 47 patients with PLO and vertebral fractures. All women received 20 μ g teriparatide daily over a period of 24 months shortly after being diagnosed with PLO.

Demographic characteristics showed that the mean age of our population was 34.2 years with a mean weight of 62.6 kg, height of 166.3 cm and BMI of 22.6 (► **Table 1**). ► **Table 2** includes additional baseline characteristics such as the use of oral contraceptives, previous history of assisted reproductive medicine, immobilisation during pregnancy, etc. The mode of delivery was predominantly spontaneous vaginal delivery (66% of the study population). In 83% of cases, PLO occurred during the first pregnancy.

Follow-up data

Next, we investigated the number and distribution of fractures per patient with PLO. The mean number of vertebral fractures

was 4 and the distribution of fractures is displayed in ► **Fig. 1 a**. We also investigated the location of fractures. Fractures were evenly distributed between the lumbar and thoracic spine, with 72.3% of all fractures observed at the lumbar and 68.1% in the thoracic spine (predominantly LS1, followed by LS2 and TS12; ► **Fig. 1 b**). All patients presented with fractures after a severe episode of back pain without having suffered a traumatic accident. Most women presented with four vertebral fractures, followed by five; very few patients had ten or more fragility fractures (► **Fig. 1 b**); no distal radius or hip fractures were observed.

Time-dependent changes in BMD, T-scores and z-scores in women with PLO, and teriparatide treatment are shown in ► **Table 3**. Median changes in lumbar spine, femoral neck, and total hip BMD using T-scores and z-scores were examined. (► **Fig. 2 a–c**). We evaluated time-dependent changes in BMD at the lumbar spine, femoral neck and total hip at baseline, after 12 and 24 months of teriparatide treatment and after a further 12 months of follow-up (36 months after the start of treatment). We found a significant, linear increase in BMD at all visits.

The BMD increase from baseline in the lumbar spine at 12, 24 and 36 months was +21.1%, +31.4% and +30.3%, respectively ($p < 0.001$). At the femoral neck, we found a significant increase of +9.3%, +12.2% and +16.3%, respectively ($p < 0.001$), and at the total hip, we found a significant increase of +7.7%, +11.7% and +13.3% for the same period ($p < 0.05$, ► **Fig. 3 a–c**). BMD gradually increased from baseline to 36 months in all groups (+16.3%, +13.3% and +31.5%), with BMD values recorded at 24 months of treatment.

► **Table 3** Time-dependent changes in BMD, T-scores and z-scores in women with PLO receiving teriparatide treatment.

Time (months)		0	12	24	36
Femoral neck (g/cm ²)	N	37	21	26	16
	Mean	0.73	0.79	0.83	0.83
	SD	0.09	0.11	0.10	0.12
Femoral neck T-score	N	36	21	27	16
	Mean	-2.01	-1.59	-1.17	-1.26
	SD	0.73	0.92	0.75	0.93
Femoral neck z-score	N	34	20	24	16
	Mean	-1.84	-1.42	-0.97	-1.05
	SD	0.80	1.02	0.80	0.97
Total hip (g/cm ²)	N	36	20	25	14
	Mean	0.76	0.81	0.85	0.82
	SD	0.10	0.08	0.10	0.07
Total hip T-score	N	38	19	26	14
	Mean	-1.98	-1.58	-1.22	-1.46
	SD	0.82	0.66	0.85	0.57
Total hip z-score	N	33	19	25	14
	Mean	-1.80	-1.45	-1.08	-1.30
	SD	0.87	0.78	0.80	0.65
Lumbar spine (g/cm ²)	N	40	23	27	15
	Mean	0.800	0.941	1.022	0.954
	SD	0.128	0.108	0.112	0.091
Lumbar spine T-score	N	40	23	29	17
	Mean	-3.02	-1.83	-1.40	-1.76
	SD	0.95	0.90	1.08	0.73
Lumbar spine z-score	N	38	22	26	17
	Mean	-2.96	-1.67	-1.31	-1.60
	SD	1.03	1.00	1.14	0.84

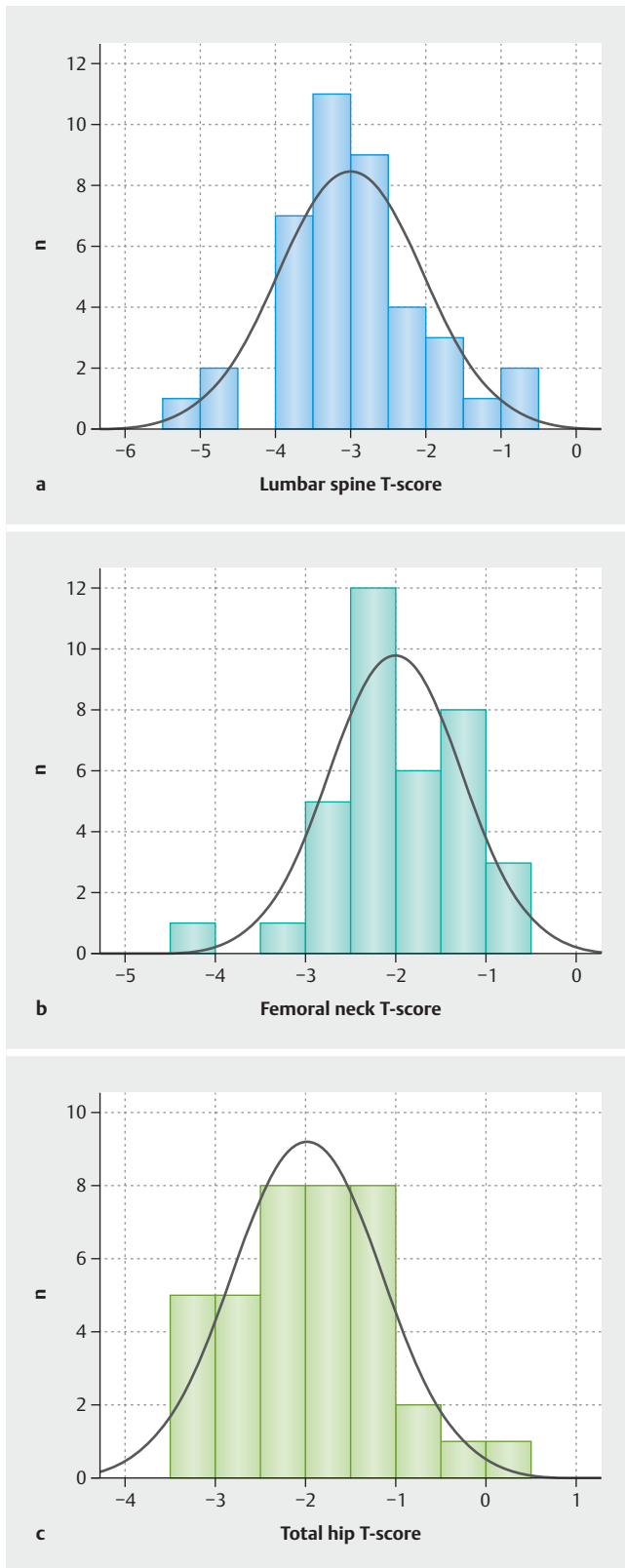
Four out of the 47 patients (7.8%) suffered a subsequent fracture in the area of the lumbar spine whilst receiving teriparatide treatment. Two of these patients suffered a repeat fracture within three to five months of diagnosis and two after six months. All subsequent fractures were identified by X-ray.

Discussion

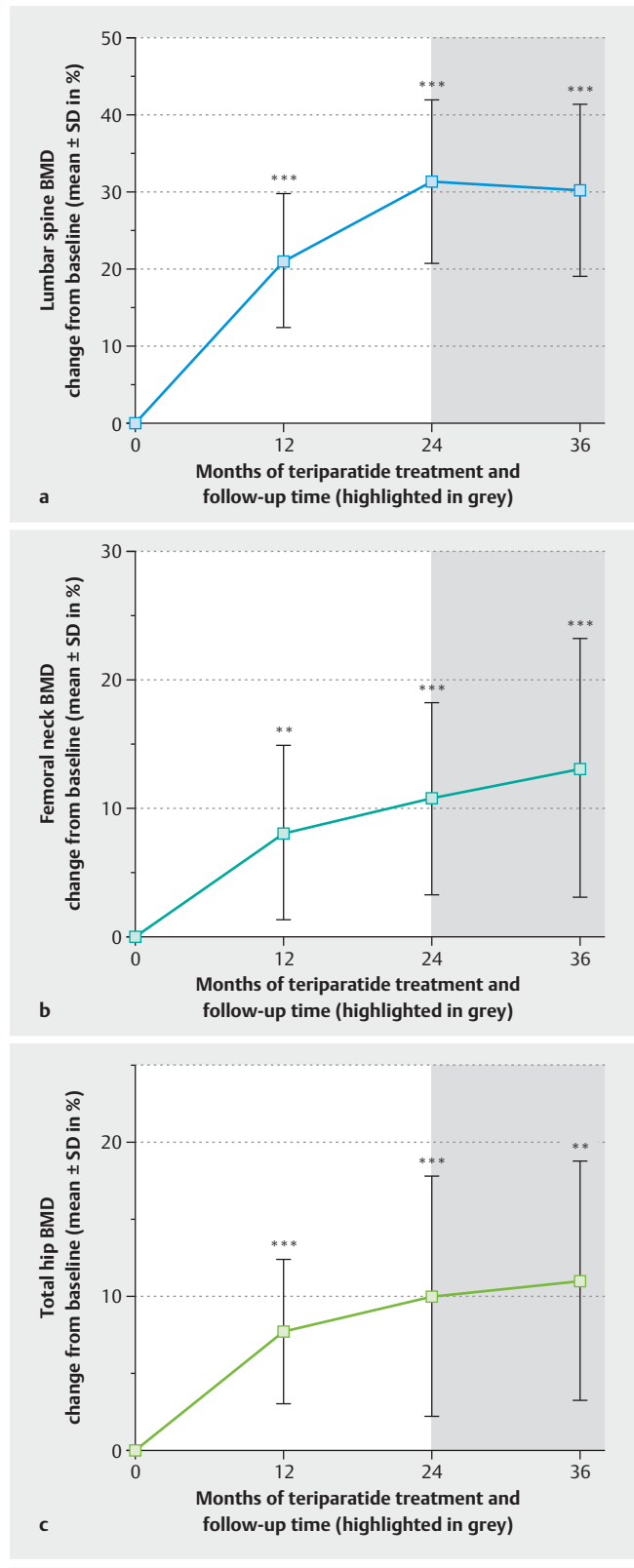
We demonstrated a linear increase of lumbar spine, femoral neck, and total hip BMD after 24 months of treatment with teriparatide. After 24 months of teriparatide treatment, the increase seems to be most pronounced in lumbar spine BMD, with only rare cases of further subsequent fractures occurring in women with PLO and existing vertebral fractures. Long-term follow-up data [21] including subsequent fracture risk from our German reference centre (n = 107 over 6 years) showed that almost one quarter of patients with PLO sustained a subsequent fracture. This fracture risk correlated with the number of fractures at diagnosis. These findings were recently confirmed in a review by Qian et al. [22] and were congruent with other 338 cases from 65 included papers.

Pregnancy- and lactation-associated osteoporosis is an infrequent but severe condition that is often misdiagnosed. Its aetiology is only partly understood but risk factors such as poor nutrition, insufficient calcium and vitamin D levels, high BMI, physical inactivity, smoking, first degree relative with a history of PLO, and corticosteroid intake have been identified [23]. Hadji et al. [24] identified pregnancy-associated diseases which require immobilisation as the highest impact risk for PLO in a large study with 102 PLO patients and 102 controls. Recently, Butscheidt et al. [25, 26] reported on three monogenic mutations in *LRP5*, *COL1A1* and *COL1A2* which may play a role in the aetiopathogenesis of PLO. As such, pregnancy was found to be a skeletal risk factor promoting the initial onset of previously unrecognised monogenic bone disorders.

Today, there is no generally accepted treatment guideline for patients with PLO, and treatment protocols are controversially discussed. There is an undoubted consensus that treatment should aim to prevent further fractures by increasing BMD, especially at the most vulnerable fracture site.



► **Fig. 2** a Distribution of lumbar spine T-scores in women with PLO at baseline. b Distribution of femoral neck T-scores in women with PLO at baseline. c Distribution of total hip T-scores in women with PLO at baseline.



► **Fig. 3** a Increase of lumbar spine BMD in relation to duration of teriparatide treatment. 24 months of treatment with teriparatide significantly increased BMD, predominantly at the spine. As all patients were premenopausal, there was no significant decrease of BMD in the 12 months after cessation of treatment. b Increase of femoral neck BMD in relation to duration of teriparatide treatment. c Increase of total hip BMD in relation to duration of teriparatide treatment.

The pharmacological approach includes various antiresorptive agents such as bisphosphonates and denosumab as well as bone anabolic treatments such as teriparatide [27]. In the past, the use of bisphosphonates as a pharmacological treatment option for PLO has been the subject of a few studies. Unfortunately, as bisphosphonates persist for a long time in bone, are able to cross the placental barrier, and may accumulate in the foetal skeleton, their use is controversially discussed [23]. In contrast to bisphosphonates, teriparatide has a low half-life of only a few hours; it does not accumulate inside the bone matrix and thus poses no threat to subsequent pregnancies if administration is discontinued early enough [12, 28]. The data of Cohen et al. [29] showing low bone remodelling rates at the tissue level in women with PLO provides the pathophysiological rationale for the use of teriparatide in the setting of PLO. In a recent report, Hellmeyer et al. emphasised the positive effects of teriparatide over 18 months [30]. Soon afterwards, Lampropoulou-Adamidou et al. were also able to demonstrate the positive effects of teriparatide treatment without any serious adverse foetal effects [28, 31]. Choe et al. supported this hypothesis and examined the effect of teriparatide over 18 months of continuous administration [32]. Finally, Winarno et al. examined the use of teriparatide after unsuccessful therapy with bisphosphonates in a complex case of pregnancy-related osteoporosis [33].

Altogether only six case reports of teriparatide treatment have been published, all showing a substantial increase in BMD [34]. Previously, O'Sullivan et al. reported that the increase in BMD is greater at the lumbar spine than at the femoral neck and total hip which is in agreement with our own findings [23]. Similarly, Hong et al. [35] concluded that lumbar spine BMD increased irrespective of baseline values after treatment with teriparatide. Importantly, the increase in BMD was sustained for a period of 12 months after discontinuation of teriparatide without any further medical treatment in patients using oral contraceptives or with a regular menstrual cycle. It is important to emphasise that after stopping lactation, patients with PLO regain normal endogenous oestrogen levels, thereby normalising bone turnover and perhaps also BMD. This approach may have an important clinical impact on the course of PLO and should be included in the follow-up strategy [36].

Our study has several limitations that should be addressed. The retrospective nature of our single treatment arm study could indicate confounders, although we included all patients who received teriparatide in the given timeframe for whom BMD measurements at baseline and after 12, 24 months and 36 months were available. The demographic heterogeneity within the treatment group is a potential source of selection bias, but this is a problem for all studies of rare diseases. A placebo-controlled randomised study would certainly best address the research question, but because of the rarity of PLO, it is highly unlikely that such a RCT will ever be performed. It is also unlikely that a patient with PLO and 4 or more vertebral fractures would agree to receive placebo over the course of 24 months. We were unable to distinguish between the increase in BMD due to the cessation of lactation and the resumption of regular menstrual cycles and the increase due to teriparatide treatment, as all studied patients stopped lactation and started teriparatide treatment.

We did not collect serum levels to measure levels of reproductive hormones and vitamin D, PTH or markers of bone turnover, which would have been interesting to compare with the increase in BMD. Finally, we also did not examine sequential treatment with teriparatide and bisphosphonates or denosumab, which would also deliver interesting results. Due to the infrequency of PLO, we wanted to focus on a single treatment regimen and avoid decreasing the number of patients per group.

To our knowledge, this is the largest study to include a substantial number of cases for the purpose of investigating and demonstrating the positive effects of teriparatide on subsequent fracture risk and bone mineral density in women with pregnancy- and lactation-associated osteoporosis (PLO) with vertebral fractures.

Conclusion

In conclusion, with regard to early diagnosis, it is crucial that physicians are cautious when pregnant or lactating women report treatment-resistant back pain. Early diagnosis is of the utmost importance. Even in pregnancy, MRI is an optional possible diagnostic tool to identify fractures which may influence the delivery mode as well as to propose primary weaning. If treatment is indicated in patients with PLO and several vertebral fractures, our results indicate that teriparatide treatment is effective at substantially increasing BMD and perhaps reducing the subsequent risk of fracture.

Conflict of Interest

The authors declare that they have no conflict of interest.

References

- [1] Johnell O, Kanis JA. An estimate of the worldwide prevalence and disability associated with osteoporotic fractures. *Osteoporos Int* 2006; 17: 1726–1733
- [2] Nordin BE, Roper A. Post-pregnancy osteoporosis; a syndrome? *Lancet* 1955; 268: 431–434
- [3] Winter EM, Ireland A, Butterfield NC et al. Pregnancy and lactation, a challenge for the skeleton. *Endocr Connect* 2020; 9: R143–R157
- [4] Kanis JA. Diagnosis of osteoporosis and assessment of fracture risk. *Lancet* 2002; 359: 1929–1936
- [5] Lewiecki EM, Kendler DL, Kiebzak GM et al. Special report on the official positions of the International Society for Clinical Densitometry. *Osteoporos Int* 2004; 15: 779–784
- [6] Loukadaki O, Tournis S, Gazi S. Clinical Case: Pregnancy lactation osteoporosis. *Mediterr J Rheumatol* 2017; 28: 161–163
- [7] Kovacs CS. Maternal Mineral and Bone Metabolism During Pregnancy, Lactation, and Post-Weaning Recovery. *Physiol Rev* 2016; 96: 449–547
- [8] Ma YL, Cain RL, Halladay DL et al. Catabolic effects of continuous human PTH (1–38) in vivo is associated with sustained stimulation of RANKL and inhibition of osteoprotegerin and gene-associated bone formation. *Endocrinology* 2001; 142: 4047–4054
- [9] Kovacs CS, Ralston SH. Presentation and management of osteoporosis presenting in association with pregnancy or lactation. *Osteoporos Int* 2015; 26: 2223–2241
- [10] Miyamoto T, Miyakoshi K, Sato Y et al. Changes in bone metabolic profile associated with pregnancy or lactation. *Sci Rep* 2019; 9: 6787

- [11] Wright EV, Naqvi AZ, Syed S et al. Transient osteoporosis of the hip in pregnancy: the orthopaedic management of bilateral neck of femur fractures in the third trimester. *BMJ Case Rep* 2021; 14: e238659
- [12] Cerit ET, Cerit M. A case of pregnancy and lactation associated osteoporosis in the third pregnancy; robust response to teriparatide despite delayed administration. *Bone Rep* 2020; 13: 100706
- [13] Di Gregorio S, Danilowicz K, Rubin Z et al. Osteoporosis with vertebral fractures associated with pregnancy and lactation. *Nutrition* 2000; 16: 1052–1055
- [14] Hadji P, Boekhoff J, Hahn M et al. Pregnancy-associated transient osteoporosis of the hip: results of a case-control study. *Arch Osteoporos* 2017; 12: 11
- [15] Iwata A, Kanayama M, Oha F et al. Effect of teriparatide (rh-PTH 1–34) versus bisphosphonate on the healing of osteoporotic vertebral compression fracture: A retrospective comparative study. *BMC Musculoskelet Disord* 2017; 18: 148
- [16] Kovacs CS. Osteoporosis presenting in pregnancy, puerperium, and lactation. *Curr Opin Endocrinol Diabetes Obes* 2014; 21: 468–475. doi:10.1097/MED.000000000000102
- [17] Aspenberg P, Genant HK, Johansson T et al. Teriparatide for acceleration of fracture repair in humans: a prospective, randomized, double-blind study of 102 postmenopausal women with distal radial fractures. *J Bone Miner Res* 2010; 25: 404–414
- [18] Hoshino M, Nakamura H, Terai H et al. Factors affecting neurological deficits and intractable back pain in patients with insufficient bone union following osteoporotic vertebral fracture. *Eur Spine J* 2009; 18: 1279–1286
- [19] Kalder M, Hans D, Kyvernitakis I et al. Effects of Exemestane and Tamoxifen treatment on bone texture analysis assessed by TBS in comparison with bone mineral density assessed by DXA in women with breast cancer. *J Clin Densitom* 2014; 17: 66–71
- [20] Hadji P, Imani P, Wuster C et al. Comparison of dual-energy X-ray absorptiometry with six quantitative ultrasonometry devices in women with hip fractures. *Climacteric* 2015; 18: 411–418
- [21] Kyvernitakis I, Reuter TC, Hellmeyer L et al. Subsequent fracture risk of women with pregnancy and lactation-associated osteoporosis after a median of 6 years of follow-up. *Osteoporos Int* 2018; 29: 135–142
- [22] Qian Y, Wang L, Yu L et al. Pregnancy- and lactation-associated osteoporosis with vertebral fractures: a systematic review. *BMC Musculoskelet Disord* 2021; 22: 926
- [23] O’Sullivan SM, Grey AB, Singh R et al. Bisphosphonates in pregnancy and lactation-associated osteoporosis. *Osteoporos Int* 2006; 17: 1008–1012
- [24] Hadji P, Boekhoff J, Hahn M et al. Pregnancy-associated osteoporosis: a case-control study. *Osteoporos Int* 2017; 28: 1393–1399
- [25] Butscheidt S, Tsourdi E, Rolvien T et al. Relevant genetic variants are common in women with pregnancy and lactation-associated osteoporosis (PLO) and predispose to more severe clinical manifestations. *Bone* 2021; 147: 115911
- [26] Butscheidt S, Delsmann A, Rolvien T et al. Mutational analysis uncovers monogenic bone disorders in women with pregnancy-associated osteoporosis: three novel mutations in LRP5, COL1A1, and COL1A2. *Osteoporos Int* 2018; 29: 1643–1651
- [27] Laroche M, Talibart M, Cormier C et al. Pregnancy-related fractures: a retrospective study of a French cohort of 52 patients and review of the literature. *Osteoporos Int* 2017; 28: 3135–3142
- [28] Lampropoulou-Adamidou K, Trovas G, Stathopoulos IP et al. Case report: Teriparatide treatment in a case of severe pregnancy- and lactation-associated osteoporosis. *Hormones (Athens)* 2012; 11: 495–500
- [29] Cohen A, Kamanda-Kosseh M, Dempster DW et al. Women With Pregnancy and Lactation-Associated Osteoporosis (PLO) Have Low Bone Remodeling Rates at the Tissue Level. *J Bone Miner Res* 2019; 34: 1552–1561
- [30] Hellmeyer L, Boekhoff J, Hadji P. Treatment with teriparatide in a patient with pregnancy-associated osteoporosis. *Gynecol Endocrinol* 2010; 26: 725–728
- [31] Lampropoulou-Adamidou K, Trovas G, Triantafyllopoulos IK et al. Teriparatide Treatment in Patients with Pregnancy- and Lactation-Associated Osteoporosis. *Calcif Tissue Int* 2021; 109: 554–562
- [32] Choe EY, Song JE, Park KH et al. Effect of teriparatide on pregnancy and lactation-associated osteoporosis with multiple vertebral fractures. *J Bone Miner Metab* 2012; 30: 596–601
- [33] Winarno AS, Kyvernitakis I, Hadji P. Successful treatment of 1–34 parathyroid hormone (PTH) after failure of bisphosphonate therapy in a complex case of pregnancy associated osteoporosis and multiple fractures. *Z Geburtshilfe Neonatol* 2014; 218: 171–173
- [34] Polat SB, Evranos B, Aydin C et al. Effective treatment of severe pregnancy and lactation-related osteoporosis with teriparatide: case report and review of the literature. *Gynecol Endocrinol* 2015; 31: 522–525
- [35] Hong N, Kim JE, Lee SJ et al. Changes in bone mineral density and bone turnover markers during treatment with teriparatide in pregnancy- and lactation-associated osteoporosis. *Clin Endocrinol (Oxf)* 2018; 88: 652–658
- [36] Lee S, Hong N, Kim KJ et al. Bone Density After Teriparatide Discontinuation With or Without Antiresorptive Therapy in Pregnancy- and Lactation-Associated Osteoporosis. *Calcif Tissue Int* 2021; 109: 544–553