

Professional Standards in Medical Ultrasound – EFSUMB Position Paper (Short Version)

General Aspects

Professionelle Standards im medizinischen Ultraschall – EFSUMB-Positionspapier

Allgemeine Aspekte

Authors

Matthias Wüstner¹, Maija Radzina^{2,3}, Fabrizio Calliada⁴, Vito Cantisani⁵, Roald Flesland Havre^{6,7}, Klaus-Vitold Jenderka⁸, Adnan Kabaalioglu⁹, Milan Kocian^{10,11}, Christian Kollmann¹², Julian Künzel¹³, Adrian Lim¹⁴, Giovanni Maconi¹⁵, Vladimir Mitkov¹⁶, Alina Popescu¹⁷, Adrian Saftoiu¹⁸, Paul S. Sidhu¹⁹, Christian Jensen²⁰

Affiliations

- 1 Central Interdisciplinary Sonography, Krankenhaus der Barmherzigen Brüder, Trier, Germany
- 2 Radiology Research laboratory, Riga Stradins University, Riga, Latvia
- 3 Diagnostic Radiology Institute, Paul Stradins Clinical University Hospital, Riga, Latvia
- 4 Department of Radiology, Policlinico San Matteo, Pavia, Italy
- 5 Department of Radiology, “Sapienza” University of Rome, ROME, Italy
- 6 Department of Medicine, Haukeland University Hospital, Bergen, Norway
- 7 National Centre for Ultrasound in Gastroenterology, Haukeland University Hospital, Bergen, Norway
- 8 FB INW, Hochschule Merseburg, Germany
- 9 Radiology Department, Koç University Hospital, Istanbul, Turkey
- 10 Anästhesie und Intensiv, Asklepios Klinik Burglengenfeld, Germany
- 11 Visual Medicine s. r. o., Olomouc, Czech Republic
- 12 Center for Medical Physics & Biomedical Engineering, Medical University Vienna, Austria
- 13 Otorhinolaryngology, University of Regensburg, Germany
- 14 Imaging, Imperial College, London, United Kingdom of Great Britain and Northern Ireland
- 15 Gastroenterology Unit, Department of Biomedical and Clinical Sciences, “L. Sacco” University Hospital, “L. Sacco” University Hospital, Milan, Italy
- 16 Diagnostic Ultrasound Division, Russian Medical Academy of Continuous Professional Education, Moscow, Russian Federation
- 17 Gastroenterology, University of Medicine and Pharmacy Timisoara, Romania
- 18 Res Ctr Gastroenterol Hepatol, University of Medicine and Pharmacy of Craiova, Romania
- 19 Radiology, King’s College London, United Kingdom of Great Britain and Northern Ireland

20 Klinik für Innere Medizin, Krankenhaus Märkisch Oderland Strausberg/Wriezen, Germany

Key words

ultrasound, education, training, quality Assurance, imaging

received 28.07.2021

accepted 09.05.2022

published online 18.07.2022

Bibliography

Ultraschall in Med 2022; 43: 456–463

DOI 10.1055/a-1854-2936

ISSN 0172-4614

© 2022, Thieme. All rights reserved.

Georg Thieme Verlag KG, Rüdigerstraße 14, 70469 Stuttgart, Germany

Correspondence

Dr. Matthias Wüstner

Central Interdisciplinary Sonography, Krankenhaus der Barmherzigen Brüder, Trier, Krankenhaus der Barmherzigen Brüder, Nordallee 1, 54292 Trier, Germany

Tel.: +49/6 51/2 08 18 80

m.wuestner@mail.de

ABSTRACT

This first position paper of the European Federation of Societies for Ultrasound in Medicine and Biology (EFSUMB) on professional standards presents a common position across the different medical professions within EFSUMB regarding optimal standards for the performing and reporting of ultrasound examinations by any professional ultrasound operator. It describes general aspects of professionalism that ensure procedure quality, effectiveness, efficiency, and sustainability in virtually all application fields of medical ultrasound. Recommendations are given related to safety and indication of ultrasound examinations, requirements for examination rooms, structured examination, systematic reporting of results, and

management, communication and archiving of ultrasound data. The print version of this article is a short version. The long version is published online.

ZUSAMMENFASSUNG

Dieses erste Positionspapier der European Federation of Societies for Ultrasound in Medicine and Biology (EFSUMB) zu professionellen Standards beschreibt eine gemeinsame Position der verschiedenen medizinischen Berufe innerhalb der EFSUMB zu optimalen Standards, wie Ultraschall-Untersuchungen von jedem professionellen Untersucher durch-

geführt und befundet werden sollten. Beschrieben werden allgemeine Aspekte der Professionalität, die die Qualität, Effektivität, Effizienz und Nachhaltigkeit in praktisch allen Anwendungsbereichen des medizinischen Ultraschalls gewährleisten. Empfehlungen werden gegeben zur Sicherheit und Indikationsstellung von Ultraschall-Untersuchungen, zu Anforderungen an Untersuchungsräume, zur strukturierten Untersuchung und systematischen Befundung sowie zur Verarbeitung, Kommunikation und Archivierung von Ultraschall-daten. Die gedruckte Version dieses Artikels ist eine kurze Version. Die lange Version wird online veröffentlicht.

1. Introduction

In 2006, the Education and Practical Standards Committee (EPSC) of the European Federation of Societies in Medicine and Biology (EFSUMB) developed a set of minimum training requirements [1] recommending structured theoretical and practical training for gynecological, obstetric, gastroenterological, nephro-urological, breast, and vascular ultrasound (US). Three levels of training and expertise were proposed, and a curriculum for each of the three levels of training was developed for the many different fields of US application. The paper also acknowledged that a systematic recording of findings of any US examination in the patient records was mandatory.

In this paper (short version; the long version is published online), the EFSUMB describes a concept of professionalism, which aims to make medical US a reliable professional service based on common and uniform quality standards with respect to regular service structures and management when US examinations are performed. This includes a relevant clinical indication, followed by a thorough and structured US examination with reliable and comprehensible storage of images/cine-loops and a clear systematic report.

The presented standards may appear demanding and not all US professionals currently in practice may achieve them. Nevertheless, the EFSUMB is committed to the approach of developing optimal rather than minimal professional standards with respect to exemplary patient care.

Professional medical US practitioners in Europe, including physicians and non-physicians who specialize in US, must all have completed comprehensive curricular training and received formal approval by the different national regulatory authorities to comply with legal regulations.

This EFSUMB position paper presents a common position across the different medical professions within the EFSUMB regarding the optimal standards for the performing and reporting of US examinations by any professional US operator regardless of where and “who performs your scan” [2] and other variable conditions in the respective national health care systems.

2. Legal Aspects and Indication for Medical Ultrasound

All medical facilities providing US services, i. e., hospitals, doctor's offices, outpatient clinics, and other health service institutions, under whose legal responsibility medical ultrasonography is carried out, are legally and ethically responsible for the proper training of personnel to safely use equipment of appropriate quality with an understanding of the limitations of medical ultrasound [1].

US devices are subject to a medical device regulation [3] and national implementation is undertaken under the Medical Product laws of the individual countries, e. g. [4, 5]. A special institution (notified body) within Europe certifies if the device is in compliance with these directives before the product is sold. After a positive evaluation the CE-mark is given with a 4-digit number to identify this notified body [6]. Additional information about the possible acoustic output of this device is also integrated into this CE-mark evaluation.

The user can see two indices related to the active output: the mechanical (MI) and thermal index (TI) that have to be displayed on the monitor. Depending on the individual settings, these indices are changed online and should not exceed the maximum values specified as “Good Practice” for the specific medical application. The ALARA principle (as low as reasonably achievable) is always the best choice in unclear situations according to a benefit/risk-analysis for all applications.

In any situation, US practitioners should follow the safety recommendations given by national and international societies and their special committees [7, 8].

Regular long-term certified maintenance of US equipment and transducers is mandatory to ensure optimal function of the different US techniques. Maintenance should be performed within the optimal standards described by equipment manufacturers.

Position Statement 1: Medical facilities are responsible for safety, legal aspects of ultrasound services, and the regular maintenance of medical ultrasound equipment (agree/disagree/abstain: 17/0/0).

As with any medical imaging procedure, an US examination should only be performed for a reasonable medical indication. Although the risk is very low, the potentially harmful physical effects of US energy on examined body tissues [9] must be taken into account when establishing the indication. The purpose, procedure, limits, and complications of the US examination, parti-

cularly for invasive US-guided procedures, for which informed written or verbal consent is required, should be explained to the patient. “Preventive” whole-body US examinations of asymptomatic persons are not recommended. They have no medical indication and are controversial as part of a general health check, owing to incidental findings which may be of uncertain clinical relevance and false-positive findings with potentially negative psychological, medical, and economic effects [10, 11].

Position Statement 2: Every ultrasound examination requires an appropriate medical indication and justification (17/0/0).

3. Organization of Medical Ultrasound Service

In medical facilities dedicated to training doctors or other health-care professionals who perform ultrasound scans, such as university clinics, teaching hospitals, and other medical training centers, departments, sections, or similar work units providing medical US services should have a responsibility hierarchy. They should be managed and headed by a responsible US practitioner with the highest level of expertise. The organization of the US service must allow for continuous training, supervision, and quality assurance of novices and practitioners with less experience. The most suitable and beneficial manner in which this teaching and expertise development can occur is the “mentoring” system, where two practitioners, one senior and one junior, take turns performing scanning in the same room in order to ensure supervision, teaching, continuous learning, and professional development to keep the diagnostic professional standard of the staff stable over a long period.

Previous patient examination findings and clinical information should be available to the examiners before starting any new patient examination. This applies to images and written reports for diagnostic imaging – not only previous US exams but also other relevant imaging (CT, MRI, X-ray, endoscopy, laboratory findings, etc.) – and the patients’ clinical records. In a digitalized workflow this requires access to a Picture Archiving and Communication System (PACS) and hospital information system in the US room.

Activities that can be delegated to (non-scanning) US assistants include all organizational work regarding patient appointment scheduling, patient transport organization, patient reception, in-department management of patients, examination preparation, environmental maintenance and material supply organization, patient support to the examination couch, and routine documentation.

Position Statement 3: Medical ultrasound services with a training mandate should facilitate continuous training and mentoring, ideally delivered in teams of two practitioners (16/1/0).

4. Medical Ultrasound Scanning Room

The spatial design of US rooms and departments should take into account the spectrum and workload with respect to performed examinations and interventions. An efficient workflow, adequate lighting conditions, compliance with hygienic working conditions, and patient safety must be ensured through appropriate room design. Each examination room should provide sufficient space for US equipment, stretcher and/or patient bed, examiner, docu-

mentation station, disinfectant facilities, and must also allow for emergency patient care. Intervention rooms require additional space for assistance, intervention equipment, preparation and processing of biological material, resuscitation equipment, and patient transfer (see ► Fig. 1). A working surface for sterile material, patient monitoring, oxygen supply and infusion, as well as dimmable room lighting and a movable spotlight are preconditions for US-guided interventions.

The space required for basic US examinations can be calculated by combining the modular functional parts that are needed. For example, 25 m² can provide one changing room for the patient and a desk for one practitioner in an US room in a hospital. Or 17 m² are enough for rooms for ambulatory patients only [12, 13]. These are absolute minimal requirements. Below these limits, the lack of space results in avoidable additional work steps with every patient, which have to be considered during the entire period of use of the room.

The optimal size of an efficient US room, including two changing rooms, space for a team of two US practitioners, plus one organizational/documentation assistant, to enable complex interventions, may add up to e.g. 45 m², excluding staff changing and restrooms. (For more details see the long version, published online).

Position Statement 4: Specifically designed medical ultrasound rooms of appropriate size are recommended for an optimally safe and efficient workflow (17/0/0).

5. Medical Ultrasound Hygiene

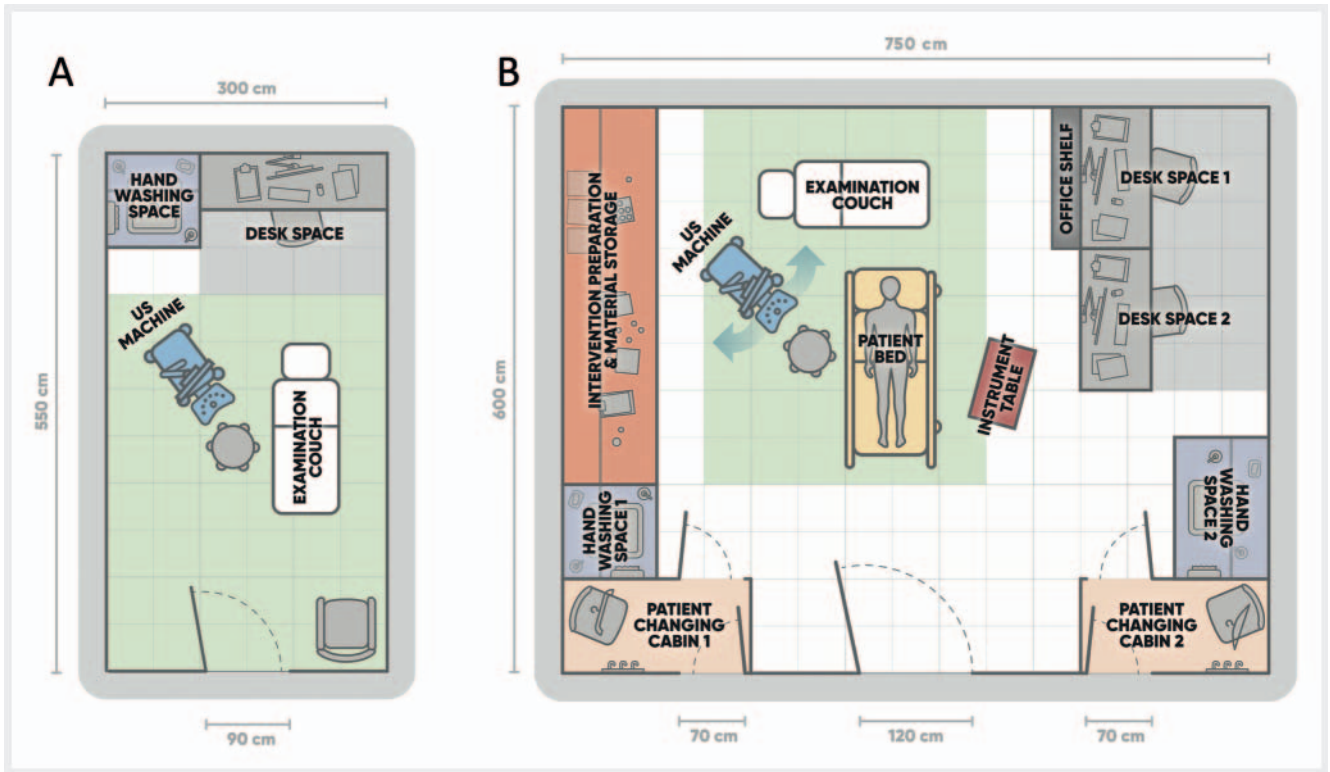
Adequate preparation and cleaning of the transducer, US unit, and the examination couch are required to avoid potential infection transmission [14–19]. Adherence to published protocols for the cleaning and reprocessing of medical US equipment varies considerably among US practitioners worldwide and is disadvantageous to good practice [20].

Guidelines for transducer and scan hygiene predominantly refer to the use of non-sterile gel as a coupling agent [14–19]. The standard use of spray or liquid disinfectants, which are used to disinfect the transducers before and after use, as coupling agents instead of gel can simplify and shorten the examination. Care should be taken to ensure that only disinfectants compatible with the transducer materials, as documented in the manufacturers’ guidelines, are used. Disinfectant sprays and liquids specifically designed for disinfecting mucous membranes (e.g., octenidine) may be superior to alcohol-based disinfectant coupling agents because they form a lubricating layer on the skin for the transducer instead of evaporating rapidly.

Position Statement 5: Hygiene plans and standards for cleaning and disinfecting ultrasound equipment should be implemented for every ultrasound service with monitoring of compliance (17/0/0).

6. Structured Medical Ultrasound Examination

US examinations should follow a predefined standardized scheme in which all relevant organs and/or structures are imaged completely and systematically on two planes and in different patient



► **Fig. 1** Suggestions for the design of ultrasound examination rooms: **A** Minimal Ultrasound room for ambulatory patients only, approximately 17.5 m². **B** Ultrasound room in a hospital enabling education in a two practitioner setting plus assistant person, as well as complex interventions e. g. percutaneous catheter drainages etc., approximately 45 m². The light green rectangle marks the minimal space for medical ultrasound at all: 12 m² = examination couch + 1 meter in every direction, required according to [13]. Both room concepts have minimal size in relation to the functions covered. Existing architecture may not allow for such optimal use of space, and no space is considered for more functions, e. g. anesthesia.

positions, if appropriate. In addition to normal organs and structures relevant to the indication, all pathological findings should be examined with US when encountered. Complementary US techniques such as Doppler US, elastography, and contrast-enhanced ultrasound (CEUS) should be applied selectively, when necessary, to answer the clinical question or to characterize pathological findings according to accepted practice guidelines [21–24].

Algorithms with predefined transducer positions have been published for almost all US applications, in particular for abdominal US [25–29], thoracic US [30, 31], joint US [32], thyroid US [33, 34], echocardiography [35], vascular US [36–39], and US-guided interventions [40, 41]. If standard examination algorithms have not been published for a particular US application, the US practitioner should follow an institutional or at least an individual standardized examination scheme to ensure that it is retrospectively clear what was examined and how.

Position Statement 6: A structured medical ultrasound examination based on standard algorithms is recommended (17/0/0).

7. Acquisition of Medical Ultrasound Images and Cine-Loops

In institutions with a digitized workflow, the complete image bundle of any US examination should be stored digitally, primarily as a DICOM dataset in the system, that ideally covers the patient’s entire

US examination. The raw data should be available for dedicated software analysis if further processing of the dataset is required (e. g., CEUS or volumetric post-processing). All single images, representative cine-loops, and/or 3 D volume datasets selected by the examiner to demonstrate his diagnostic conclusions should be sent to the PACS unit.

The still images dataset must include:

- all organs to be assessed on at least two, ideally perpendicular, planes, both showing the maximal extension of the organ including measurements in 3 dimensions for volume calculation, if applicable,
- all pathologic findings on at least two, ideally perpendicular, planes, both showing the maximal extension of the lesion/pathologic change including measurements in possibly 3 dimensions. In case of multiplicity of pathologic lesions, image storage may be limited to a selection, showing the range of variety, including one or more typical “reference lesions” with size/volume measured for follow-up purposes.

Video sequences should be used

for complete volume acquisition (sweep through a complete organ/region) for anatomical representation of an organ/anatomical structure/pathology: The organ/lesion view should be taken in only one steady sweep from outside of one margin to the outside of the other margin, in a recognizable direction.

And for documentation of physiologic or pathologic dynamic phenomena (e. g., heart action, fetal movements, bowel wall movements, blood flow, contrast enhancement, lung sliding). The respective organ/structure should be taken with a transducer held still in an adapted plane. The cine-loop should contain a representative time period [39].

3D volume datasets

may replace cine-loops of steady sweeps through organs or pathologic findings obtained for complete volume acquisition.

Labeling

Still images and cine-loops should be labeled with appropriate pictograms/terminology/abbreviations. Topographic pictograms are better and more rapidly understood than written transducer position labels, with the advantage of being independent of language differences.

Non-image information which must be provided with any still image or cine-loop includes:

Patient identification data, institution/examiner identification data, date and time of the examination image or cine-loop.

Additional data to specify technical details of the exam:

US system/model, US transducer, frequency, mechanical and thermal index, and other technical pre- and post-processing settings used, focus position(s), if applicable.

Position statement 7: Ultrasound images and cine-loops from all standard ultrasound views and any abnormal finding should be stored and reported (16/0/1).

8. Medical Ultrasound Reporting

The main purpose of the written US report is to communicate findings, conclusions, and the relevance to the clinical enquiry to the referring clinician. In medical facilities, where patient records are kept electronically, US findings should be recorded, reported, and archived electronically, too.

Beside patient identification data, each report should contain relevant information about when, where, and by whom the examination was performed, for what indication, and which equipment was used. Subsequently normal and pathological findings must be documented in a systematic approach. Limitations of the examination quality and confidence level should be indicated.

What to communicate to the patient during, or shortly after the examination, depends on the circumstances of the examination.

For the communication of medical US results to the referrer and the patient file, a **structured report** using standardized reporting templates is recommended. Structured reporting using digital “report templates” standardizes and simplifies reports by sometimes exchanging the sentences with short phrases and giving the examiner a chance to select different options quickly [42–47]. Structured documentation is a promising approach to standardizing findings, improving the overall reporting quality of various diagnostic modalities, and facilitating interdisciplinary communication [48–53]. Referring physicians and US practitioners generally prefer structured reports over free-text findings [54–56].

Inexperienced examiners can benefit from the use of structured documentation, as relevant content and the naming of

anatomical structures are indicated and the recommended terminology is offered during the preparation of the report, thus serving as a checklist for the examiner [47, 55, 56].

The US imaging spectrum is so large that recommendation of a single common “report form” that covers all fields, is not possible. However, there are a number of mandatory rules to follow (► **Table 1**):

The text volume of an US report may range from summary notes in the patient’s file, e. g. focused thoracic US: “No pleural effusion found on right side”, to very extensive versions with recording of all cine-loops to be archived together with a detailed report, with all nine categories, e. g., in second-trimester obstetric US screening, the summary may be three to five pages long.

Position Statement 8: Structured ultrasound reporting and the use of templates and text modules is recommended (17/0/0).

Communication of Medical US Findings

Selected relevant image material should be demonstrated, explained, and discussed with the responsible clinician(s) as with all other imaging modalities. This may happen via an inter-personal exchange between the examiner and referring clinician or in multi-disciplinary clinico-radiological meetings. To influence immediate clinical management, in cases of high clinical urgency, a verbal report highlighting the salient findings should be given directly to the responsible clinician prior to issuing a formal report or even better by clinician presence and involvement during the examination of the patient.

The complete digitally stored medical US image material and the report should be available for all clinicians involved in patient care. Depending on national regulations, the patient and other medical personnel may also have access to the images and the associated report of the US examination.

Position Statement 9: The digitally stored and reported medical ultrasound data should be available for all involved parties in the patient’s care and should be communicated in a timely manner (17/0/0).

9. Medical Ultrasound Data Management and Archiving

DICOM (Digital Imaging and Communication in Medicine) has been established as a non-proprietary standard for the storage, communication, and management of medical imaging information and related data [57, 58]. It is implemented in all modern medical US systems and, therefore, should be used for digital documentation and archiving of medical US imaging. PACS (Picture Archiving and Communication System) is the software solution that enables storage and reproduction of any kind of medical DICOM imaging material and digital reports, which should be used to archive and manage medical imaging data. Thus, US images and cine-loops are available on an equal par with image files from other imaging modalities, allowing demonstration in multidisciplinary meetings, direct comparison with findings from cross-sectional imaging, follow-up imaging, the application of image-fusion techniques, and the partial replace-

► **Table 1** Mandatory content of ultrasound examination reports.

1.	<i>Institutional identification (name of hospital/practice/referring physician and investigator identification)</i>
2.	<i>Patient identification (family name, first name, sex, birth date. Patient's address may, in hospitals, be replaced by internal file number to relate patient data to medical history and address data stored in central system: e. g. HIS)</i>
3.	<i>Date and time of US examination</i>
4.	<i>Relevant anamnestic and clinical information stating the indication for the examination</i>
5.	<i>Diagnostic question(s) to be solved by the US examination</i>
6.	<i>Scanning conditions and, if so, limitations of the examination, e. g., regions/organs not seen</i>
7.	<i>Descriptions of US appearance of organs and pathologies</i> <i>The report should describe image characteristics in grayscale or Doppler US using standardized terminology, but not clinical diagnoses. It is advised to use text modules for normal findings and frequent pathologies. The description should use these categories for organs or structures: Position – Size – Shape – Contours – Echogenicity – Echo Texture – Tubular Structures (vessels, ducts) – phase-specific enhancement pattern with US contrast agent, relative stiffness with US elastography.</i>
8.	<i>Summary or interpretation including (suspected) diagnoses</i> <i>Three parts are advised:</i> a) <i>Answering the clinical question(s) raised</i> b) <i>Listing other pathologic findings possibly in the order of their clinical relevance (e. g., potential malignancies prior to simple cysts)</i> c) <i>Closing remark about the remainder of the examined areas, excluding other abnormalities in relation to possible limitations, e. g., due to unfavorable examination conditions</i> <i>A cautious interpretation of images is advised to avoid potentially false conclusions. Diagnostic statements should not predetermine the absolute diagnosis, e. g., "patient has metastases", but instead keep the relation to the method used: e. g., "typical sonographic appearance of metastases".</i>
9.	<i>Diagnostic and/or therapeutic consequences, possibly including suggestions for further diagnostic workup or follow-up</i> <i>Imperative instructions for further patient management within the examination report derived from US findings may cause medicolegal problems if a recommended action is not implemented by the clinically responsible physician. Therefore, considerations regarding further medical management should be formulated as suggestions rather than recommendations (e. g., not "surgery is necessary" but instead "surgery is worth considering".</i>

ment of imaging involving exposure to radiation. However, PACS use and implementation may be variable among countries for a number of different reasons [59].

Position Statement 10: Digital image archiving of ultrasound examinations is mandatory. In institutions use of the standard PACS is recommended (17/0/0).

10. Quality Considerations

Patients and referring physicians should expect to receive the best achievable quality of medical US. As providers of medical US, the objective is to achieve a diagnostic reliability level comparable to the level published in guidelines and other high-quality review publications. Quality assurance reviews and maintenance of US equipment should meet the accepted original manufacturer standards.

In comparison to other imaging modalities, US is more operator-dependent. This is often perceived as a failure to examine the relevant area with the transducer or as being the result of the region being obscured, e. g., by gas or bone. US examinations can be as informative as other imaging modalities or even better and may even have the advantage of superior spatial resolution, real-time live presentation, and the ability to readily repeat the examination. It is vital that the target organ/region is stored as an image or video file, because without this, there can be no re-evaluation by a second expert. Every US practitioner must strive to achieve a level of imaging reliability similar to other imaging modalities. An attempt should be made with US to obtain images of all aspects of the target region/organ, to ensure that the examination is reliable

with respect to identifying or dismissing abnormalities. Where a full examination is not possible, a thorough description of the regions/organs/aspects that were not clearly imaged or where there was limited diagnostic quality should be stated and the report should be written in a way that makes the limitations of the examination clear. This applies in particular to part c) of the conclusion (table 1, 8.): the value of a summarizing statement regarding the other examined organs and regions without pathologies not mentioned in parts a) and b) of the conclusion. For example, "The remainder of the ultrasound examination demonstrated no findings of clinical significance" must be put into perspective by an indication of any patient-specific or methodological limitations of the examination of these organs and regions.

US diagnoses in parts a) and b) of the report's conclusion should be formulated as precisely and definitively as possible, but in a patient-specific manner, with relevant differential diagnoses taken into account. To minimize loss of examiner reputation, even the most typical sonographic appearance should only be referred to as such: e. g., "typical sonographic aspect like liver metastases", not just "liver metastases".

In order to be able to obtain pooled statistical data for quality assurance of a medical institution and its qualified US practitioners (sensitivity, specificity, positive/negative predictive value, and overall accuracy of US diagnoses), it is necessary to classify the final diagnosis correctly according to the International Classification of Diseases (ICD). Currently, there are a number of medical diagnostic procedures with mandatory national quality databases, e. g., endoscopic US, and US departments can benchmark against these national standards. It is recommended to perform quality

assurance as a regular activity in order to confirm the practice quality and be compared to other institutions.

Position Statement 11: Regular critical review of medical ultrasound reports is recommended (16/0/1).

11. Conclusion and Future Perspectives

The practice of medical US still varies considerably in the areas of procedure, image storing, and reporting. Most practices will have some areas where they could improve. In this manuscript we have described the areas that the EFSUMB considers to be an optimum standard for all US practitioners to attain. Practitioners should also be aware of existing guidelines and position papers, to continually assess and improve their US practice.

The ability to store and share US images and videos in a standardized digital database, co-joined with a report from the operator, is crucial to improve the applicability and clinical yield of this modality, in terms of economic value, quality, and educational value. Adhering to these standards makes US examination a more reliable, reproducible, and standardized imaging modality in line with other cross-sectional imaging methods.

With large datasets becoming available, US may benefit in the near future from deep learning artificial intelligence solutions that could help to improve implementation of unified standards and quality, thereby helping US practitioners to scan and report readily, precisely, and accurately [60].

With a standardized approach, there are also better opportunities for appropriate reimbursement and the timing of equipment update or renewal.

Conflict of Interest

The authors disclose reimbursement of travel expenses by EFSUMB or national scientific societies, resulting from their involvement in EFSUMB ExB or related committee activities. Further disclosures: Matthias Wuestner: Lecture fees in Ultrasound courses and congresses from Ultrasound academy of DEGUM, Campus ACADEMY, SonoABCD – UEC & Partners Medical Education GmbH, Landesärztekammer Niedersachsen, Falk Foundation, Support to perform ultrasound courses from Philips and Mindray. Vito Cantisani: Lecturer fee as speaker for Bracco, Samsung, Canon. Klaus Jenderka: shares of GAMPT mbH (Company for Applied Medical Physics and Technique). Julian Kuenzel: fees for participation in expert meetings from BMS and for performing DEGUM certified ultrasound courses by SonoForKlinik. Support to perform ultrasound courses by GE Healthcare, travelling support by Merz. Adrian Lim: Fees for lectures and articles from Canon Medical Systems, Siemens Medical Systems and Bracco. Research Grants and Support – Philips Medical Systems and Canon Medical Systems. Vladimir Mitkov: Lecture fees in Ultrasound courses, webinars and congresses from Canon Medical Systems (Japan), GE Healthcare (USA), Mindray (China), Philips. Adrian Saftoiu: Lecture fees in Ultrasound / EUS courses and congresses from Bracco Suisse and Pentax Medical Singapore. 100% shares held in EchoEndoPlus company, involved in Romania in healthcare. Christian Jenssen: fees for lectures and/or participation in expert meetings from FALK Foundation, Hitachi Medical Ultrasound, GE Healthcare, Bracco and Ultrasound Academy of DEGUM. Support to perform ultrasound courses by Canon, Hitachi, GE Healthcare and Bracco.

References

- [1] Education and Professional Standards Committee, European Federation of Societies for Ultrasound in Medicine and Biology. Minimum training recommendations for the practice of medical ultrasound. *Ultraschall in Med* 2006; 27 (1): 79–105
- [2] Edwards HM, Sidhu PS. Who's doing your scan? A European perspective on ultrasound services. *Ultraschall in Med* 2017; 38 (5): 479–482
- [3] Regulation (EU) 2017/745 of the European Parliament and of the Council of 5 April 2017 on medical devices, amending Directive 2001/83/EC, Regulation (EC) No 178/2002 and Regulation (EC) No 1223/2009 and repealing Council Directives 90/385/EEC and 93/42/EEC (Consolidated version): EUR-Lex – 32017R0745 – EN – EUR-Lex (europa.eu) (accessed April 17, 2021).
- [4] Gesetz über Medizinprodukte (Medizinproduktegesetz – MPG, BGBl. I p. 1133) 7.8.2002, adopted 18.7.2017; Germany. <https://www.gesetze-im-internet.de/mpg/MPG.pdf> (accessed April 17, 2021)
- [5] Bundesgesetz betreffend Medizinprodukte (Medizinproduktegesetz – MPG, Fassung v. 12.9.2018, BGBl. No. 657/1996), Austria. RIS – Medizinproduktegesetz – Bundesrecht konsolidiert, Fassung vom 22.05.2021 (bka.gv.at) (accessed April 17, 2021).
- [6] European Commission, Single Market and Standards, Notified Bodies, Brussels. https://ec.europa.eu/growth/singlemarket/goods/building-blocks/notified-bodies_en
- [7] Kollmann C, Jenderka KV, Moran C et al. EFSUMB clinical safety statement for diagnostic ultrasound – (2019 revision). *Ultraschall in Med* 2020; 41 (4): 387–389
- [8] EFSUMB – ECMUS Safety Statements. <https://www.efsumb.org/safety-statements> (accessed April 17, 2021)
- [9] Schiavone C, Grassi R, Bertolotto M et al. The sonographic medical act. *J Ultrasound* 2020; 23 (4): 445–447
- [10] Livingston CJ, Freeman RJ, Mohammad A et al. Choosing Wisely in preventive medicine: The American College of Preventive Medicine's top 5 list of recommendations. *Am J Prev Med* 2016; 51 (1): 141–149
- [11] Dietrich CF, Westerway S, Nolsoe C et al. Commentary on the World Federation for Ultrasound in Medicine and Biology project “incidental findings”. *Ultrasound Med Biol* 2020; 46 (7): 1815–1820
- [12] Hayward C. Sizing Imaging and Procedure Rooms, January 2, 2021. <https://blog.spacemed.com/sizing-imaging-and-procedure-rooms/> (accessed March 26, 2022)
- [13] Facility Guidelines Institute with assistance from the U.S. Department of Health and Human Services. 2.2–3.4.5 Ultrasound, in: 2010 Guidelines for Design and Construction of Health Care Facilities. <https://www.aapm.org/meetings/amos2/pdf/49-14367-84348-888.pdf> (accessed March 26, 2022)
- [14] EFSUMB. Best Practice recommendation for cleaning and disinfection of ultrasound transducers whilst maintaining transducer integrity. 2019. Available at (accessed April 17, 2021): https://www.efsumb.org/wp-content/uploads/2020/12/2019-probe_cleaning_recommendation.pdf
- [15] Nyhsen CM, Humphreys H, Koerner RJ et al. Infection prevention and control in ultrasound – best practice recommendations from the European Society of Radiology Ultrasound Working Group. *Insights Imaging* 2017; 8 (6): 523–535
- [16] American Institute of Ultrasound in Medicine. Guidelines for Cleaning and Preparing External- and Internal-Use Ultrasound Transducers and Equipment Between Patients as well as Safe Handling and Use of Ultrasound Coupling Gel. <https://www.aium.org/officialStatements/57> (accessed April 17, 2021)
- [17] Müller T, Martiny H, Merz E et al. DEGUM recommendations on infection prevention in ultrasound and endoscopic ultrasound. *Ultraschall in Med* 2018; 39 (3): 284–303

- [18] Basseal M, Westerway SC, Juraja M et al. Guidelines for reprocessing ultrasound transducers. *Australas J Ultrasound Med* 2017; 20: 30–40
- [19] American College of Emergency Physicians. Guideline for Ultrasound Transducer Cleaning and Disinfection. *Ann Emerg Med* 2018; 72: e45–e47
- [20] Westerway SC, Basseal JM, Abramovicz JS. Medical ultrasound disinfection and hygiene practices: WFUMB global survey results. *Ultrasound Med Biol* 2019; 45: 344–352
- [21] Dietrich CF, Bamber J, Berzigotti A et al. EFSUMB Guidelines and Recommendations on the Clinical Use of Liver Ultrasound Elastography, Update 2017 (Long Version). *Ultraschall in Med* 2017; 38 (4): e16–e47
- [22] Săftoiu A, Gilja OH, Sidhu PS et al. The EFSUMB Guidelines and Recommendations for the Clinical Practice of Elastography in Non-Hepatic Applications: Update 2018. *Ultraschall in Med* 2019; 40 (4): 425–453
- [23] Sidhu PS, Cantisani V, Dietrich CF et al. The EFSUMB Guidelines and Recommendations for the Clinical Practice of Contrast-Enhanced Ultrasound (CEUS) in Non-Hepatic Applications: Update 2017 (Long Version). *Ultraschall in Med* 2018; 39 (2): e2–e44
- [24] Dietrich CF, Nolsøe CP, Barr RG et al. Guidelines and Good Clinical Practice Recommendations for Contrast Enhanced Ultrasound (CEUS) in the Liver – Update 2020 – WFUMB in Cooperation with EFSUMB, AFSUMB, AIUM, and FLAUS. *Ultraschall in Med* 2020; 41 (5): 562–585
- [25] Atkinson NSS, Bryant RV, Dong Y et al. How to perform gastrointestinal ultrasound: Anatomy and normal findings. *World J Gastroenterol* 2017; 23 (38): 6931–6941
- [26] American Institute of Ultrasound in Medicine. AIUM practice guideline for the performance of an ultrasound examination of the abdomen and/or retroperitoneum. *J Ultrasound Med* 2012; 31 (8): 1301–1312
- [27] Walas MK, Skoczylas K, Gierbliński I. Standards of the Polish Ultrasound Society – update. The liver, gallbladder and bile ducts examinations. *J Ultrason* 2012; 12 (51): 428–445
- [28] Ćwik G. Standards of the Polish Ultrasound Society – update. Pancreas examination. *J Ultrason* 2013; 13 (53): 167–177
- [29] Tyloch JF, Woźniak MM, Wieczorek AP. Standards of the Polish Ultrasound Society – update. The kidney, ureters and urinary bladder. *J Ultrason* 2013; 13 (54): 293–307
- [30] Laursen CB, Clive A, Halifax R et al. European Respiratory Society Statement on Thoracic Ultrasound. *Eur Respir J* 2020: 2001519
- [31] Gargani L, Volpicelli G. How I do it: lung ultrasound. *Cardiovasc Ultrasound* 2014; 12: 25
- [32] Möller I, Janta I, Backhaus M et al. The 2017 EULAR standardised procedures for ultrasound imaging in rheumatology. *Ann Rheum Dis* 2017; 76 (12): 1974–1979
- [33] Kwak JY, Han KH, Yoon JH et al. Thyroid imaging reporting and data system for US features of nodules: a step in establishing better stratification of cancer risk. *Radiology* 2011; 260 (3): 892–899
- [34] Trzebińska A, Dobruch-Sobczak K, Jakubowski W et al. Standards of the Polish Ultrasound Society – update. Ultrasound examination of thyroid gland and ultrasound-guided thyroid biopsy. *J Ultrason* 2014; 14 (56): 49–60
- [35] Mitchell C, Rahko PS, Blauwet LA et al. Guidelines for Performing a Comprehensive Transthoracic Echocardiographic Examination in Adults: Recommendations from the American Society of Echocardiography. *J Am Soc Echocardiogr* 2019; 32 (1): 1–64
- [36] Santos SND, Alcantara ML, Freire CMV et al. Vascular Ultrasound Statement from the Department of Cardiovascular Imaging of the Brazilian Society of Cardiology – 2019. *Arq Bras Cardiol* 2019; 112 (6): 809–849
- [37] Małek G, Nowicki A. Standards of the Polish Ultrasound Society – update. Sonography of the lower extremity veins. *J Ultrason* 2014; 14 (58): 287–296
- [38] Małek G, Elwertowski M, Nowicki A. Standards of the Polish Ultrasound Society – update. Ultrasound examination of the aorta and arteries of the lower extremities. *J Ultrason* 2014; 14 (57): 192–202
- [39] Elwertowski M, Małek G. Standards of the Polish Ultrasound Society – update. Examination of the extracranial carotid and vertebral arteries. *J Ultrason* 2014; 14 (57): 179–191
- [40] Millington SJ, Colvin MO, Shiloh AL et al. How I Do It: Ultrasound-Guided Internal Jugular and Femoral Central Venous Catheter Insertion. *Chest* 2020; 158 (6): 2425–2430
- [41] Troianos CA, Hartman GS, Glas KE et al. Guidelines for performing ultrasound guided vascular cannulation: recommendations of the American Society of Echocardiography and the Society of Cardiovascular Anesthesiologists. *J Am Soc Echocardiogr* 2011; 24 (12): 1291–1318
- [42] Armas RR. Qualities of a good radiology report. *Am J Roentgenol* 1998; 170 (4): 1110
- [43] Brady AP. Radiology reporting – from Hemingway to HAL? *Insights Imaging* 2018; 9 (2): 237–246
- [44] Weiss DL, Langlotz CP. Structured Reporting: Patient Care Enhancement or Productivity Nightmare? *Radiology* 2008; 249 (3): 739–747
- [45] European Society of Radiology. ESR paper on structured reporting in radiology. *Insights Imaging* 2018; 9 (1): 1–7
- [46] Kuhn K, Zemmler T, Reichert M et al. Structured data collection and knowledge-based user guidance for abdominal ultrasound reporting. *Proc Annu Symp Comput Appl Med Care* 1993: 311–315
- [47] O'Connor SD, Kulkarni NM, Griffin MO Jr et al. Structured reporting in ultrasound. *Ultrasound Q* 2020; 36 (1): 1–5
- [48] An JY, Unsorfer KML, Weinreb JC. BI-RADS, C-RADS, CAD-RADS, LI-RADS, Lung-RADS, NI-RADS, O-RADS, PI-RADS, TI-RADS: Reporting and Data Systems. *Radiographics* 2019; 39 (5): 1435–1436
- [49] Ernst BP, Hodeib M, Strieth S et al. Structured reporting of head and neck ultrasound examinations. *BMC Med Imaging* 2015; 19: 25
- [50] Russ G, Bonnema SJ, Erdogan MF et al. European Thyroid Association Guidelines for Ultrasound Malignancy Risk Stratification of Thyroid Nodules in Adults: The EU-TIRADS. *Eur Thyroid J* 2017; 6 (5): 225–237
- [51] Chernyak V, Fowler KJ, Kamaya A et al. Liver Imaging Reporting and Data System (LI-RADS) Version 2018: Imaging of Hepatocellular Carcinoma in At-Risk Patients. *Radiology* 2018; 289 (3): 816–830
- [52] Kono Y, Lyschik A, Cosgrove D et al. Contrast Enhanced Ultrasound (CEUS) Liver Imaging Reporting and Data System (LI-RADS®): the official version by the American College of Radiology (ACR). *Ultraschall in Med* 2017; 38 (1): 85–86
- [53] Geyer T, Rübenthaler J, Marschner C et al. Structured Reporting Using CEUS LI-RADS for the Diagnosis of Hepatocellular Carcinoma (HCC)- Impact and Advantages on Report Integrity, Quality and Interdisciplinary Communication. *Cancers (Basel)* 2021; 13 (3): 534
- [54] Schwartz LH, Panicek DM, Berk AR et al. Improving communication of diagnostic radiology findings through structured reporting. *Radiology* 2011; 260 (1): 174–181
- [55] Ernst BP, Katzer F, Kunzel J et al. Impact of structured reporting on developing head and neck ultrasound skills. *BMC Med Educ* 2019; 19: 102
- [56] Ernst BP, Strieth S, Katzer F et al. The use of structured reporting of head and neck ultrasound ensures time-efficiency and report quality during residency. *Eur Arch Otorhinolaryngol* 2020; 277: 269–276
- [57] Bidgood WD Jr, Horii SC, Prior FW et al. Understanding and using DICOM, the data interchange standard for biomedical imaging. *J Am Med Inform Assoc* 1997; 4 (3): 199–212
- [58] Graham RN, Perriss RW, Scarsbrook AF. DICOM demystified: a review of digital file formats and their use in radiological practice. *Clin Radiol* 2005; 60 (11): 1133–1140
- [59] Foord K. Year 2000: status of picture archiving and digital imaging in European hospitals. *Eur Radiol* 2001; 11 (3): 513–524
- [60] Cantisani V, Grani G, Tovoli F et al. Artificial Intelligence: What is it and how can it expand the ultrasound potential in the future? *Ultraschall in Med* 2020; 41 (4): 356–360