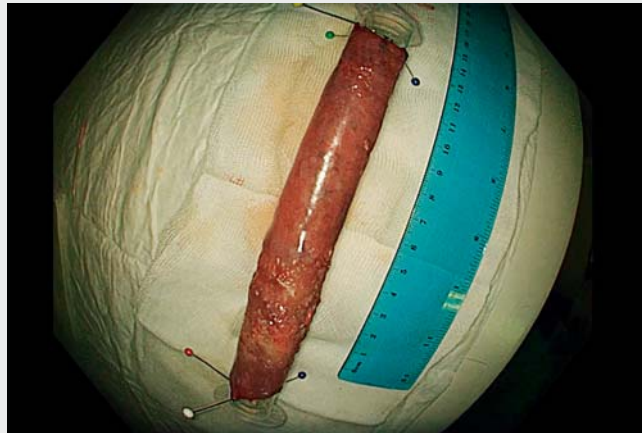

Tunneling and clip-with-line techniques for successful long circumferential esophageal endoscopic submucosal dissection



A 67-year-old man with multiple comorbidities was referred to our institution owing to a recent diagnosis of a superficial esophageal squamous cell carcinoma. Endoscopic evaluation using white-light, narrow-band imaging and lugol chromoendoscopy revealed a circumferential 6-cm, Paris 0-IIa, type V3 intrapillary capillary loop classification lesion, from 37 to 43 cm from the incisors. Multiple minor Paris 0-IIb + 0-IIc lesions were also observed proximally, up to 30 cm from the incisors. Following multidisciplinary evaluation, circumferential endoscopic submucosal dissection (ESD) was scheduled (▶ **Video 1**). Proximal and distal circumferential incisions were made using a 1.5-mm DualKnife (Olympus, Tokyo, Japan). Next, two contralateral submucosal tunnels were accomplished, leaving two longitudinal lateral bridges. Then, the additional use of the clip-with-line technique allowed constant traction of the specimen, enabling dissection of the remaining lateral bridges. A full circumferential specimen 15 cm in length was retrieved. Lastly, triamcinolone acetonide was injected into the residual submucosal layer. The patient was discharged under oral prednisolone. Histological examination revealed an R0 resection of a 57-mm, well-differentiated squamous cell carcinoma, with lymphovascular invasion and submucosal invasion >200 µm, along with additional R0, m3 squamous cell carcinoma and high-grade dysplastic lesions corresponding to the proximal lesions. On endoscopic follow-up, a mild stricture easily traversable with a standard endoscope was noted. Radiotherapy was proposed on multidisciplinary review. Esophageal ESD is a complex procedure. The thinness of the muscle wall and the narrow esophageal diameter make scope manipulation difficult and increases the risk of perforation.



▶ **Video 1** Tunneling and clip-with-line techniques for successful long circumferential esophageal endoscopic submucosal dissection.



We demonstrated that combining tunneling and clip-with-line techniques enables successful circumferential esophageal endoscopic submucosal dissection.

Endoscopy_UCTN_Code_TTT_1AO_2AG

Competing interests

The authors declare that they have no conflict of interest.

The authors

Daniela Falcão, Joana Alves-Silva , **Sara Archer, Isabel Pedroto, Ricardo Marcos-Pinto, Ricardo Küttner-Magalhães** 
Gastroenterology Department, Centro Hospitalar Universitário do Porto, Porto, Portugal

Corresponding author

Daniela Falcão, MD
Gastroenterology Department, Centro Hospitalar Universitário do Porto, Porto, Portugal, Praça D. Filipa de Lencastre, nº 189, 2060-189, Porto, Portugal
daniela Teixeirafalcao@gmail.com

Bibliography

Endoscopy 2022; 54: E981
DOI 10.1055/a-1884-9380
ISSN 0013-726X
published online 4.8.2022
© 2022. The Author(s).

This is an open access article published by Thieme under the terms of the Creative Commons Attribution-NonDerivative-NonCommercial License, permitting copying and reproduction so long as the original work is given appropriate credit. Contents may not be used for commercial purposes, or adapted, remixed, transformed or built upon. (<https://creativecommons.org/licenses/by-nc-nd/4.0/>)

Georg Thieme Verlag KG, Rüdigerstraße 14, 70469 Stuttgart, Germany

