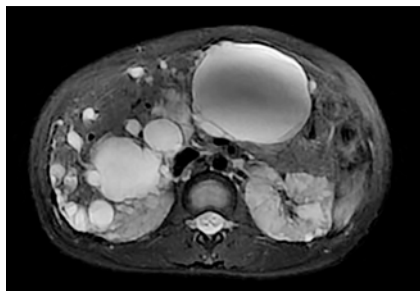
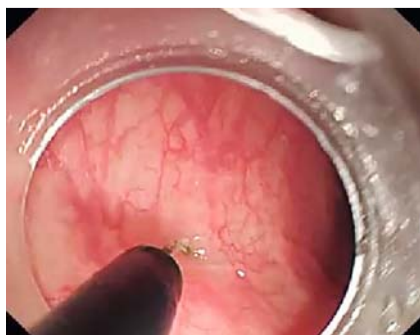

Trans sigmoid colon NOTES sclerotherapy for polycystic liver disease

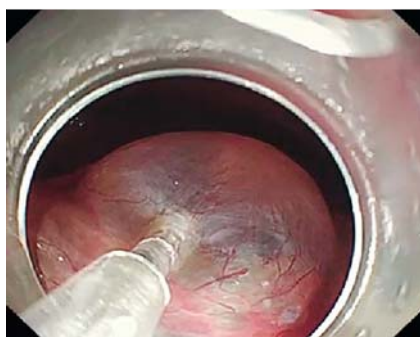OPEN ACCESS



► **Fig. 1** Before sclerotherapy T2-weighted magnetic resonance imaging (MRI) showed cysts with irregular high signal from sac fluid and cyst edges with a maximum vesicle volume of $9.0 \times 7.1 \times 8.3$ cm.



► **Fig. 2** Natural orifice transluminal endoscopic surgery (NOTES) sclerotherapy technique: an incision was made using a hook-knife in the anterior wall of the sigmoid colon 18 cm from the anus.



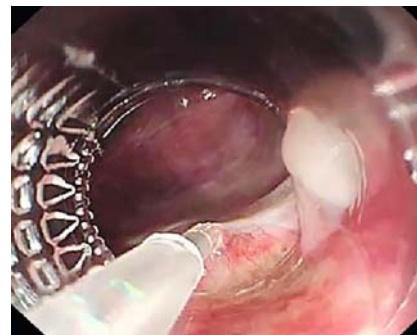
► **Fig. 3** The colonoscope entered the abdominal cavity and reached the surface of the liver, and an endoscopic needle was used to drain the sac fluid.

Laparoscopic cystic fluid aspiration is one of the common treatments for polycystic liver disease (PLD) [1]. However, laparoscopes have limited flexibility, and parts of the abdominal cavity are difficult to reach [2]. To avoid the problem of laparoscope inflexibility, we use the more flexible endoscope to perform sclerotherapy for polycystic liver disease by means of natural orifice transluminal endoscopic surgery (NOTES).

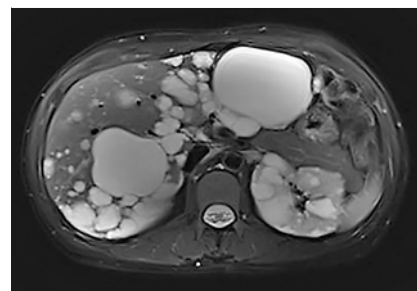
This is the first study to use NOTES sclerotherapy for polycystic liver disease.

A 34-year-old woman presented with progressive epigastric distension, and was diagnosed with polycystic liver disease (► **Fig. 1**). After informed consent was given, a NOTES procedure was performed (► **Video 1**), with the patient under general anesthesia. The intestine was prepared in a routine fashion and sterilized, and a balloon-tube was placed in the descending colon to block the digestive juices. Using a hook-knife, an incision was made in the anterior wall of the sigmoid colon 18 cm from the anus (► **Fig. 2**). The endoscope was introduced into the abdominal cavity via the incision and reached the surface of the liver, where the liver cysts were visible. An endoscopic needle was used to drain sac fluid (► **Fig. 3**) and a certain amount of foam sclerosing agent (lauromacrogol) was then injected (► **Fig. 4**). Ultimately, nearly 500 mL of sac fluid was extracted. Adhesions were released at the same time. After rinsing with normal saline, the incision was finally closed using clips. The procedure was performed successfully without any adverse events.

The patient recovered well. Follow-up MRI after 3 months showed a 2-cm³ reduction in volume of the largest cyst (► **Fig. 5**). The MRI signal values were significantly different compared with pre-NOTES. The patient's liver function remains normal.



► **Fig. 4** Foam sclerosing agent was injected into the sac cavity after the extraction of the sac fluid.



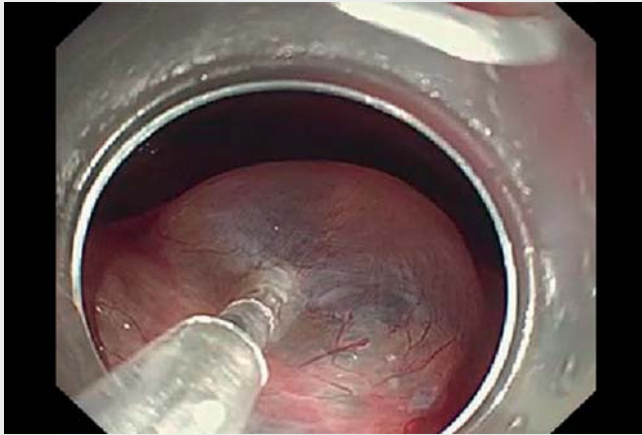
► **Fig. 5** Post-sclerotherapy, follow-up T2-weighted MRI showed cysts with regular high signal inside and cyst edges, with a maximum vesicle volume of $7.3 \times 5.7 \times 7.6$ cm.

NOTES sclerotherapy for polycystic liver disease is a novel technique and appears to safely preserve normal liver tissue. Further clinical studies with larger samples and long-term follow-up are needed to evaluate the effectiveness and safety of NOTES sclerotherapy for polycystic liver disease [3,4].

Endoscopy_UCTN_Code_TTT_1AT_2AZ

Funding

Sichuan Medical Association Medical Youth Innovation Fund
Q18046



Video 1 Sclerotherapy for polycystic liver disease in a 34-year-old woman by means of trans sigmoid colon natural orifice transluminal endoscopic surgery (NOTES).

Bibliography

Endoscopy 2022; 54: E984–E985

DOI 10.1055/a-1887-5737

ISSN 0013-726X

published online 4.8.2022

© 2022. The Author(s).

This is an open access article published by Thieme under the terms of the Creative Commons Attribution-NonDerivative-NonCommercial License, permitting copying and reproduction so long as the original work is given appropriate credit. Contents may not be used for commercial purposes, or adapted, remixed, transformed or built upon. (<https://creativecommons.org/licenses/by-nc-nd/4.0/>)

Georg Thieme Verlag KG, Rüdigerstraße 14, 70469 Stuttgart, Germany



ENDOSCOPY E-VIDEOS

<https://eref.thieme.de/e-videos>




Endoscopy E-Videos is an open access online section, reporting on interesting cases and new techniques in gastroenterological endoscopy. All papers include a high quality video and all contributions are freely accessible online. Processing charges apply (currently EUR 375), discounts and waivers acc. to HINARI are available.

This section has its own submission website at <https://mc.manuscriptcentral.com/e-videos>

Competing interests

The authors declare that they have no conflict of interest.

The authors

Tianyu Liu^{1,2}, Suyu He¹, Linlin Chen¹ , Kai Jiang¹, Xiaomei Ding², Xiquan Wang¹, Ying Bi¹

1 Fourth Department, Digestive Disease Center, Suining Central Hospital, Sichuan, China

2 Department of Digestive Endoscopy Center, Suining Central Hospital, Sichuan, China

Corresponding author

Linlin Chen, MD

Fourth Department, Digestive Disease Center, Suining Central Hospital, 127 Desheng West Road, Sichuan, China
Fax: 011-86825-2292270
chenlinlinmedical@outlook.com

References

- [1] Gevers T, Drenth J. Diagnosis and management of polycystic liver disease. *Nat Rev Gastroenterol Hepatol* 2013; 10: 101–108
- [2] Ullah S, Ali FS, Liu BR. Advancing flexible endoscopy to natural orifice transluminal endoscopic surgery. *Curr Opin Gastroenterol* 2021; 37: 470–477
- [3] Wijnands TF, Ronot M, Gevers TJ et al. Predictors of treatment response following aspiration sclerotherapy of hepatic cysts: an international pooled analysis of individual patient data. *Eur Radiol* 2017; 27: 741–748
- [4] Wijnands TF, Görtjes AP, Gevers TJ et al. Efficacy and safety of aspiration sclerotherapy of simple hepatic cysts: a systematic review. *Am J Roentgenol* 2017; 208: 201–207