

Novel J-tip guidewire for reintervention after stent-by-stent placement in patients with malignant hilar biliary obstruction




Authors

Tadahisa Inoue¹  Mayu Ibusuki¹, Rena Kitano, Kazumasa Sakamoto¹, Satoshi Kimoto¹, Yuji Kobayashi¹, Yoshio Sumida¹, Yukiomi Nakade¹, Kiyooki Ito¹, Masashi Yoneda¹

Institution

1 Department of Gastroenterology, Aichi Medical University, Aichi

submitted 18.3.2022

accepted after revision 12.7.2022

published online 13.7.2022

Bibliography

Endosc Int Open 2022; 10: E1291–E1296

DOI 10.1055/a-1899-4124

ISSN 2364-3722

© 2022. The Author(s).


This is an open access article published by Thieme under the terms of the Creative Commons Attribution-NonDerivative-NonCommercial License, permitting copying

and reproduction so long as the original work is given appropriate credit. Contents may not be used for commercial purposes, or adapted, remixed, transformed or built upon. (<https://creativecommons.org/licenses/by-nc-nd/4.0/>)

Georg Thieme Verlag KG, Rüdigerstraße 14,
70469 Stuttgart, Germany

Corresponding author

Tadahisa Inoue, MD, PhD, FJGES, Department of Gastroenterology, Aichi Medical University, 1-1 Yazakokarimata, Nagakute, Aichi 480-1195, Japan
Fax: +81 561 63 3208
tinoue-tag@umin.ac.jp

 Supplementary material is available under <https://doi.org/10.1055/a-1899-4124>

Reintervention (RI) after bilateral metal stent placement for malignant hilar biliary obstruction is a highly technically challenging procedure. This study aimed to examine the use of a novel J-tip guidewire (GW) for RI after stent-by-stent (SBS) placement. The study outcomes included technical success, procedure time, and procedure-related adverse events (AEs) associated with RI after SBS placement. These parameters were compared between 20 patients who underwent RI using the J-tip GW (J-GW group) and a control cohort of 20 patients who underwent RI using a conventional GW (C-GW group). The technical success rate for GW placement without any advanced technique was significantly higher in the J-GW group than in the C-GW group. The median procedure time was significantly shorter in the J-GW group. No significant differences in the procedure-related AE rate were observed between the groups. The novel J-tip GW yielded higher technical success rates with appropriate GW placement and shorter procedure time for RI after SBS placement, simplifying and streamlining the RI procedure.

Introduction

Bilateral self-expandable metal stent (SEMS) placement is considered the first-line approach in patients with unresectable malignant hilar biliary obstruction (MHBO) because bilateral drainage confers a higher clinical success rate and stent patency of greater durability compared to unilateral drainage in these patients [1]. Bilateral SEMS placement can be performed using the stent-in-stent (SIS) or stent-by-stent (SBS) technique [2]. Although the superiority of one method over the other remains to be determined [3], the recent development of ultrathin delivery systems ($\leq 6F$), which enable the simultaneous insertion of two SEMSs, has simplified the SBS method, enabling wider implementation [4].

However, endoscopists must currently consider the stenting strategy in anticipation of reintervention (RI) because of the incidence of recurrent biliary obstruction (RBO) in approximately half of patients even after bilateral SEMS placement [2]. RI for RBO after bilateral SEMS placement is highly challenging from the technical perspective [5, 6], and simplification of the RI procedure is a major research theme in this field. Appropriate selective cannulation of the lumen(s) of previously inserted SEMS without passing the stent mesh is the most onerous step during RI after SBS placement. We developed a novel J-tip

guidewire (GW), which is specialized for RI, to overcome this issue. This study aimed to examine the feasibility and utility of this J-tip GW for RI after SBS placement in patients with MHBO.

Methods

Patients

This retrospective single-center exploratory pilot study investigated 20 consecutive patients with MHBO aged ≥ 20 years, who underwent RI using the J-tip GW after SBS placement (including secondary or more RI procedures) between 2019 and 2021. The exclusion criteria for patient selection were as follows: with duodenal papilla that could not be reached, without pathological confirmation of malignancy, with missing information regarding the details of the procedure and outcomes, and refusal to participate. The outcomes were compared with those of a historical control group consisting of an equal number of consecutive patients who underwent RI using the conventional GW before 2019 when the J-tip GW was introduced at the institution. An uncovered laser-cut SEMS with an ultra-thin delivery system (ZeoStent V; Zeon Medical, Tokyo, Japan, or Bilerush selective; Piolax Medical Devices) was used for all SBS procedures, and all SEMS were placed above the duodenal papilla. The diameter of the SEMS was 8 mm in all cases, and the length ranged from 40 to 100 mm based on the length of the stricture.


The institutional review board of Aichi Medical University Hospital approved this study, which was conducted in accordance with the principles of the Declaration of Helsinki. All patients provided written informed consent for the RI procedures, and an opt-out method was applied for their consent to having any information published.

J-tip GW

A standard 0.025-inch GW (M-Through; Asahi Intecc, Aichi, Japan, EndoSelector; Boston Scientific, Marlborough, Massachusetts, United States, or VisiGlide 2; Olympus Medical Systems, Tokyo, Japan) was utilized for fabricating the J-tip GW. These GWs, which possessed adequate shaft stiffness and length (4500 mm) for use under endoscopic guidance, were originally fabricated for endoscopic retrograde cholangiopancreatography. The tip of the GW was manipulated by hand to form a loop. The loop diameter was adjusted to approximately 5 to 8 mm. Subsequently, an angle of approximately 10° was made at the base of the loop (► **Fig. 1** and **Supplementary Fig. 1**). The rationale underlying this J-shaped GW is that the loop makes it difficult to pass through the mesh and enables easy selective cannulation of the lumen of the SEMS (► **Fig. 2** and ► **Video 1**).

Technique

The JF260V, TJF260V or TJFQ290V duodenoscope (Olympus Medical Systems) was employed for RI. Selection of the lumen of the SEMS was attempted using the GW after biliary cannulation with a standard catheter (MTW Endoskopie Manufaktur, Wesel, Germany) (► **Fig. 3** and ► **Video 2**). The catheter was subsequently advanced over the GW when the latter reached the intrahepatic bile duct through the SEMS. If the catheter could not be advanced due to interference with the SEMS, can-



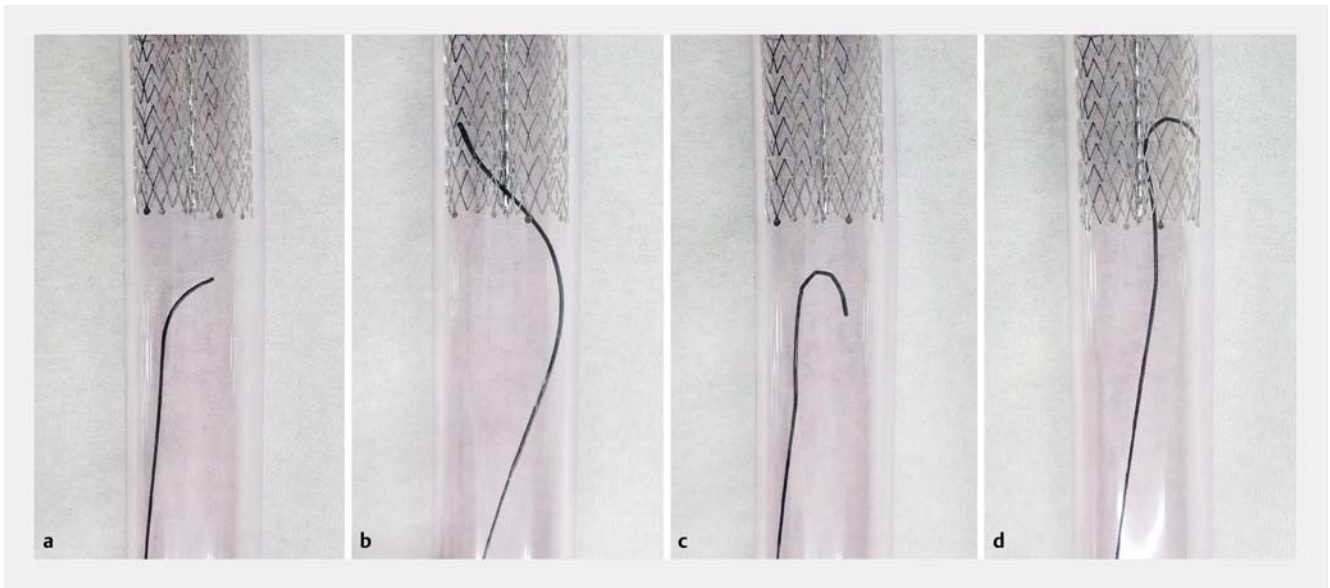
► **Fig. 1** **a** Standard angle-tip guidewire (M-Through; Asahi Intecc, Aichi, Japan). **b** Novel J- tip guidewire was fabricated manually by manipulating a standard one. The loop diameter was adjusted to approximately 5 to 8 mm, and an angle of approximately 10° was made at the base of the loop.

ulation of the lumen was attempted again based on the assumption that the stent mesh was passed. Selective cannulation of the lumen of the SEMS on the contralateral side was attempted in the same manner. Subsequently, the planned treatment procedure, including stent placement and cleaning with a balloon catheter, was performed. The unprocessed conventional angle-type GW (M-Through, EndoSelector, or VisiGlide 2) was used in the control group.

The advanced technique was attempted using the Swing Tip (Olympus Medical Systems) cannula-guided approach and cholangioscopy-guided approach [7] in both groups, if selection of the appropriate SEMS lumen failed, the latter of which was achieved using the SpyGlass DS system (Boston Scientific). An experienced endoscopist skilled in MHBO stenting conducted or directly supervised all procedures.

Outcomes and definitions

The study outcomes included the technical and therapeutic successes, procedure time, and procedure-related adverse events (AEs) associated with RI after SBS placement. The outcomes were compared between the treatment cohort that underwent RI using the J-tip GW (J-GW group) and the control co-



► **Fig. 2** Bench test for the stent-by-stent placement model. **a, b** Conventional guidewires tend to cross the stent mesh. **c, d** The J-tip guidewire bounces off even if it interferes with the stent wires, making inadvertent mesh crossing difficult, and can easily be guided into a wider stent lumen, instead of the narrower stent mesh).

► **VIDEO**

► **Video 1** Comparison of selective cannulation of the stent lumen using the conventional guidewire with the novel J-tip guidewire with the bench test on a stent-by-stent placement model.

hort that underwent RI using the conventional GW (C-GW group).

Technical success was defined as successful completion and attainment of proper access to the left and right intrahepatic ducts through each SEMS, including selective cannulation of the appropriate inner lumen of the SEMS and catheter advancement, without the need for any advanced technique. Therapeutic success was defined as successful completion of the intended treatment, e.g. accomplishment of stent placement after GW insertion. The procedure time for GW placement was defined as the duration from the start of cannulation to successful placement of two GWs. The total procedure time was defined as the duration from the start of cannulation to successful completion of intended treatment.

Statistical analysis

Fisher's exact test was used to evaluate the differences between the categorical variables, and the Mann-Whitney U test was used to compare the continuous variables. All statistical analyses were conducted using EZR version 1.54 (Saitama Medical Centre, Jichi Medical University, Saitama, Japan). $P < 0.05$ was considered significant.

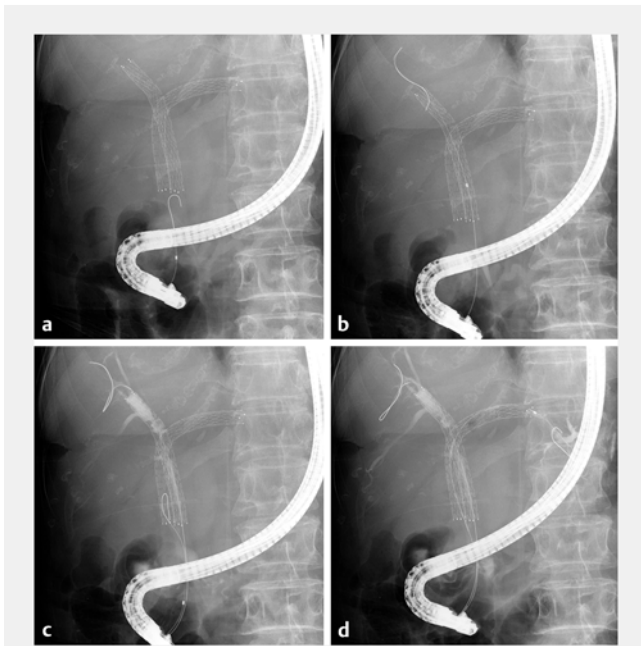
Results

Patient characteristics

► **Table 1** presents characteristics of the study population. The alignment rate of the distal ends of the initial SEMS, which was defined as a gap ≤ 3 mm between the two stents, was 100% (20/20) and 95% (19/20) in the J-GW and C-GW groups, respectively, and the difference was not significant ($P = 1.000$). The median diameter of the common bile duct below the SEMSs did not differ significantly between the two groups (8.2 mm versus 8.0 mm for the J-GW and C-GW groups, respectively; $P = 0.431$).

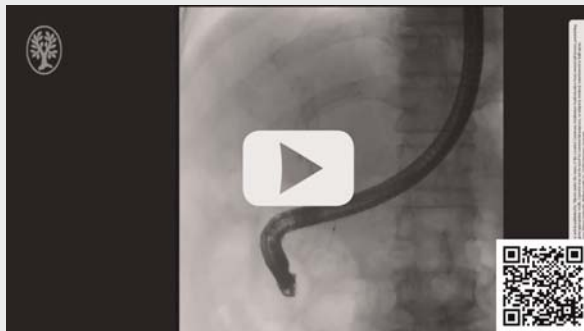Outcomes

► **Table 2** presents the outcomes of RI after SBS placement. The technical success rate for GW placement without any advanced technique was significantly higher in the J-GW group at 90% (18/20) than in the C-GW group at 55% (11/20) ($P = 0.031$). The median procedure time from the initiation of biliary cannulation to the successful placement of two GWs was significantly shorter in the J-GW group than that in the C-GW group (10.0 min versus 22.5 min, $P < 0.001$). Moreover, the total procedure time was also shorter in the J-GW Group (22.5 min versus 35.0 min, $P = 0.016$). Therapeutic success was achieved in 100% (18/18) of the patients in the J-GW group, and 91% (10/



► **Fig. 3** a, b The J-tip guidewire is easily inserted into the stent lumen without passing the stent mesh. c, d The same maneuver is achieved on the contralateral side by selecting the lumen properly in the same way.

▶ VIDEO



► **Video 2** Reintervention using a novel J-tip guidewire after stent-by-stent placement in a patient with malignant hilar biliary obstruction.

11) in the C-GW group among the patients with successful GW placement, although the difference was not significant ($P=0.379$).

GW placement was technically unsuccessful in two patients in the J-GW group because of failure to select one SEMS in one patient and failure to select both SEMSs in the other. Technical success was achieved using the Swing Tip cannula-guided technique in the first patient and the cholangioscopy-guided approach in the second patient. Technical success was achieved in four of the nine patients with technical failure in the C-GW group using the Swing Tip cannula-guided technique, while the cholangioscopy-guided approach was successful in the

two other patients. However, treatment failure persisted in the remaining three patients, who eventually underwent only unilateral stent placement.

The rate of procedure-related AEs was 5% (1/20) and 5% (1/20) in the J-GW and C-GW groups, respectively, without significant differences ($P=1.000$). One case of cholangitis occurred in both groups, which improved with conservative management. GW-related AEs, such as GW rupture or stacking during the procedure, were not observed in either group.

Discussion

This study demonstrated that the novel J-tip GW yielded a higher technical success rate with appropriate GW insertion and shorter procedure time for RI after SBS placement. The AE rate with the J-tip GW was comparable to that with the conventional GW.

RI after bilateral SEMS placement is beset by technical challenges; the success rate of RI was 76.3% to 85.7% [5, 8, 9] after SIS and 79.1% [10] after SBS, according to recent studies. Although the ability to simultaneously deploy two stent delivery systems has simplified the SBS technique, the difficulty of RI remains unmitigated; appropriate selective cannulation of the stent lumen with device advancement, without passing the stent mesh, is the most challenging part of the procedure [10]. Because the frequency of RBO with initial bilateral SEMS placement is sufficiently high to include almost half of the treated population, RI is an important consideration while planning the first stenting. Moreover, the low success rate of RI can cast doubt on the choice to implement bilateral SEMS placement.

If appropriate selective cannulation of the SEMS lumen fails with the standard approach during RI after SBS, the approach employing the Swing Tip cannula, which has a manually controllable tip, can be useful. However, it is not valid in all cases because this cannula can only move in two directions. Although cholangioscopy can overcome this issue because the scope can be moved in four directions, its use may be difficult in the setting of a narrow bile duct due to the large diameter of the cholangioscope. Further, a cholangioscopy-guided procedure may be more expensive with a prolonged procedure duration. Hence, simple, convenient, and reliable techniques and devices are needed to simplify the RI procedure [7].

The novel J-tip GW may meet the above-mentioned prerequisites. The looped tip of the GW bounces off even if it interferes with the stent wires, lowering the possibility of inadvertent mesh crossing. We predicted that the looped configuration would enable the GW to be easily guided into the wider SEMS lumen rather than the narrower stent mesh. Moreover, another frequent problem is that the GW appears outside the SEMS, especially in the common bile duct, where the stents are parallel, even after successful selection of the distal stent ends; the novel GW is expected to be useful in this respect as well. This feature may also be useful even for RI after SIS. However, GWs with appropriately wide J-tips are not currently available for endoscopic use. The loops need to be fabricated by hand, which requires skillful craftsmanship, so achieving con-

► **Table 1** Baseline patient characteristics.

	J-tip GW group	Conventional GW group	P value
Number of patients, n	20	20	
Sex, (male/female), n	8/12	8/12	1.000
Median age (range), years	81 (72–86)	80 (66–83)	0.209
Performance status, n (%)			1.000
▪ 0–1	13 (65)	13 (65)	
▪ ≥2	7 (35)	7 (35)	
Etiology, n (%)			0.696
▪ Cholangiocarcinoma	15 (75)	14 (70)	
▪ Gallbladder carcinoma	3 (15)	2 (10)	
▪ Pancreatic carcinoma	0	2 (10)	
▪ Others	2 (10)	2 (10)	
Metastasis, n (%)	10 (50)	15 (75)	0.191
Receiving chemotherapy, n (%)	13 (65)	17 (85)	0.273
Cholangitis, n (%)	13 (65)	10 (50)	0.523
Bismuth classification, n (%)			0.844
▪ II	4 (20)	5 (25)	
▪ III	7 (35)	5 (25)	
▪ IV	9 (45)	10 (50)	
Median length of the stricture ¹ (range), mm	18.0 (12.0–35.0)	17.5 (11.0–28.0)	0.411
Median diameter of the CBD ¹ (range), mm	8.2 (5.6–11.0)	8.0 (4.0–10.5)	0.431
Diameter of the initial SEMS, n (%)			1.000
▪ 8 mm	20 (100)	20 (100)	
Type of initial SEMS, n (%)			1.000
▪ Laser-cut	20 (100)	20 (100)	
Alignment of the initial SEMS's distal ends, n (%)	20 (100)	19 (95)	1.000

GW, guidewire; CBD, common bile duct; SEMS, self-expandable metal stent.
¹ Before initial stent-by-stent placement.

stant reproducibility of the shape and size of the loop can be difficult. It is expected that GWs with an appropriate preformed loop or GWs with easier handling characteristics will become commercially available.

This study had some limitations that should be considered. First, it had a single-center retrospective design and small sample size. Hence, selection bias could not be eliminated owing to the study design. Second, all procedures were performed by a single experienced endoscopist, and the J-tip GW was fabricated manually by manipulating any of three types of standard GW, so the results may not be directly applicable to other institutions. Last, we could not eliminate the possible effect of the learning curve of the endoscopist on the results; conventional GWs were used during an earlier period than the novel GW. Although this novel GW has the potential to be useful for RI after

SBS placement, its effectiveness should be confirmed by further clinical studies.

Conclusions

In conclusion, this is the first study to report the use of the novel J-tip GW for RI after SBS, with promising results. As RI is a very difficult procedure that is performed in clinically complex situations, we hope that use of the modified GW will simplify RI.

► **Table 2** Outcomes of reintervention after stent-by-stent placement.

	J-tip GW group	Conventional GW group	P value
Technical success of GW placement without advanced techniques, n (%)	18/20 (90)	11/20 (55)	0.031
▪ Failure to select one SEMS	1	7	
▪ Failure to select two SEMS	1	2	
Therapeutic success without advanced technique, n (%)	18/18 (100)	10/11 (91)	0.379
Median procedure time of GW placement (range), min	10.0 (5–19)	22.5 (13–80)	<0.001
Median total procedure time (range), min	22.5 (12–67)	35.0 (16–91)	0.016
Procedure-related adverse events, n (%)	1/20 (5)	1/20 (5)	1.000
▪ Cholangitis	1	1	

GW, guidewire; SEMS, self-expandable metal stent.

Competing interests

Dr. Inoue received honoraria from Boston Scientific Japan, Ltd., outside the submitted work.

References

- [1] Lee TH, Kim TH, Moon JH et al. Bilateral versus unilateral placement of metal stents for inoperable high-grade malignant hilar biliary strictures: a multicenter, prospective, randomized study (with video). *Gastrointest Endosc* 2017; 86: 817–827
- [2] Naitoh I, Inoue T, Hayashi K. Which is better for unresectable malignant hilar biliary obstruction: side-by-side versus stent-in-stent? *Gastrointest Interv* 2018; 7: 78–84
- [3] Lee TH, Moon JH, Choi JH et al. Prospective comparison of endoscopic bilateral stent-in-stent versus stent-by-stent deployment for inoperable advanced malignant hilar biliary stricture. *Gastrointest Endosc* 2019; 90: 222–230
- [4] Inoue T, Ibusuki M, Kitano R et al. Combined side-by-side and stent-in-stent method for triple metal stenting in patients with malignant hilar biliary obstruction. *Dig Endosc* 2019; 31: 698–705
- [5] Tomoda T, Kato H, Kawamoto H et al. Usefulness of a newly designed plastic stent for endoscopic re-intervention in patients with malignant hilar biliary obstruction. *Endoscopy* 2017; 49: 1087–1091
- [6] Inoue T, Naitoh I, Okumura F et al. Reintervention for stent occlusion after bilateral self-expandable metallic stent placement for malignant hilar biliary obstruction. *Dig Endosc* 2016; 28: 731–737
- [7] Inoue T, Kitano R, Yoneda M. Troubleshooting of reinterventions after stent-by-stent placement for malignant hilar biliary obstruction (with videos). *Hepatobiliary Pancreat Dis Int* 2021: S1499-3872(21) 00128-4 doi:10.1016/j.hbpd.2021.07.005
- [8] Okuno M, Mukai T, Iwashita T et al. Evaluation of endoscopic reintervention for self-expandable metallic stent obstruction after stent-in-stent placement for malignant hilar biliary obstruction. *J Hepatobiliary Pancreat Sci* 2019; 26: 211–218
- [9] Son JH, Lee HS, Lee SH et al. Revision of bilateral self-expandable metallic stents placed using the stent-in-stent technique for malignant hilar biliary obstruction. *Hepatobiliary Pancreat Dis Int* 2018; 17: 437–442
- [10] Inoue T, Naitoh I, Suzuki Y et al. Multi-center study of endoscopic revision after side-by-side metal stent placement for malignant hilar biliary obstruction. *Dig Endosc* 2021; 33: 807–814