

# Subepithelial tumors: How does endoscopic full-thickness resection & submucosal tunneling with endoscopic resection compare with laparoscopic endoscopic cooperative surgery?




## Authors

Michel Kahaleh<sup>1</sup>, Vicky Bhagat<sup>1</sup>, Peter Dellatore<sup>1</sup>, Amy Tyberg<sup>1</sup>, Avik Sarkar<sup>1</sup>, Haroon M. Shahid<sup>1</sup>, Iman Andalib<sup>1</sup>, Resheed Alkhiari<sup>1</sup>, Monica Gaidhane<sup>1</sup>, Prashant Kedia<sup>2</sup>, Jose Nieto<sup>3</sup>, Nikhil A. Kumta<sup>4</sup>, Rebekah E. Dixon<sup>4</sup>, Habeeb Salameh<sup>4</sup>, Georgios Mavrogenis<sup>5</sup>, Stefanos Bassioulkas<sup>6</sup>, Seiichiro Abe<sup>7</sup>, Vitor N. Arentes<sup>8</sup>, Flavio H. Morita<sup>9</sup>, Paulo Sakai<sup>9</sup>, Eduardo G. de Moura<sup>9</sup>

## Institutions

- 1 Gastroenterology, Robert Wood Johnson University, New Brunswick, New Jersey, United States
- 2 Gastroenterology, Methodist Hospital, Dallas, Texas, United States
- 3 Borland-Groover Clinic, Jacksonville, Florida, United States
- 4 Gastroenterology, Mount Sinai Hospital, New York, New York, United States
- 5 Gastroenterology, Mytilene Hospital, Mytilene, Greece
- 6 Gastroenterology, Latpikin, Athens, Greece
- 7 Endoscopy Division, National Cancer Center Hospital, Tokyo, Japan
- 8 Federal University of Minas Gerais, Belo Horizonte, MG, Brazil
- 9 Gastroenterology, University of Sao Paulo Medical School, Sao Paulo, Brazil

submitted 3.3.2021

accepted after revision 10.8.2022

published online 11.8.2022

## Bibliography

Endosc Int Open 2022; 10: E1491–E1496

DOI 10.1055/a-1922-7890

ISSN 2364-3722

© 2022. The Author(s).

This is an open access article published by Thieme under the terms of the Creative Commons Attribution-NonDerivative-NonCommercial License, permitting copying and reproduction so long as the original work is given appropriate credit. Contents may not be used for commercial purposes, or adapted, remixed, transformed or built upon. (<https://creativecommons.org/licenses/by-nc-nd/4.0/>)

Georg Thieme Verlag KG, Rüdigerstraße 14,  
70469 Stuttgart, Germany

## Corresponding author

Michel Kahaleh, MD, Professor of Medicine, Clinical Director of Gastroenterology, Robert Wood Johnson University Hospital, 51 French Street, MEB 479 New Brunswick, New Brunswick, NJ 08901, United States

Fax: +1-732-235-7307

mkahaleh@gmail.com

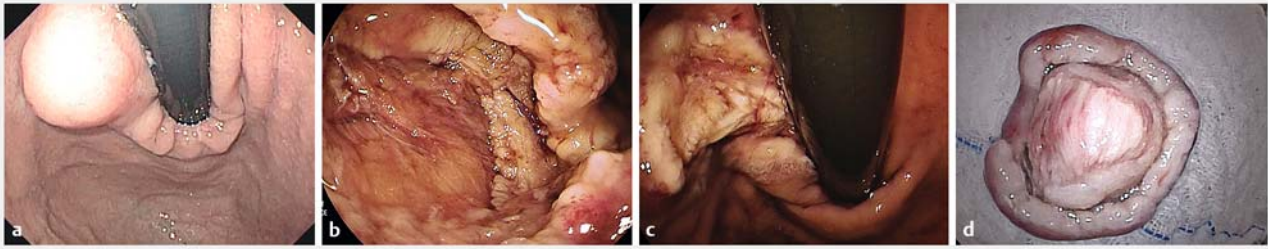
## ABSTRACT

**Background and study aims** Endoscopic techniques are rapidly emerging for resection of subepithelial tumors (SETs). Submucosal tunneling for endoscopic resection (STER), endoscopic full-thickness resection (EFTR) and laparoscopic endoscopic cooperative surgery (LECS) are current alternatives to open surgery. In this study, we aimed to compare the three endoscopic techniques.

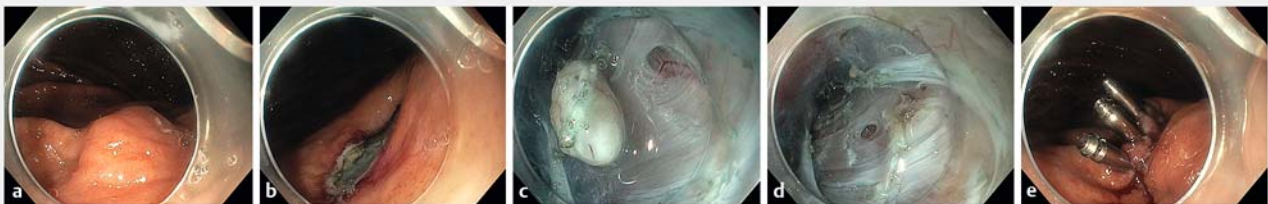**Patients and methods** Consecutive patients who underwent resection of a submucosal esophageal or gastric lesion at several tertiary care centers were included in a dedicated registry over 3 years. Demographics, size and location of resected lesion, histology of specimen, length of procedure, adverse events (AEs), duration of hospital stay, and follow-up data were collected.

**Results** Ninety-six patients were included (47.7% male, mean age 62): STER n = 34, EFTR n = 34, LECS n = 280. The lesions included leiomyoma, gastrointestinal stromal tumors (GISTs) and other. The mean lesion size was 28 mm (STD 16, range 20–72 mm). The majority of lesions in the EFTR and laparoscopic-assisted resection group were GISTs. There was no significant difference in clear resection margins, post-procedure complication rates, recurrence rate and total follow-up duration between the groups. However, the LECS group had a procedure time at least 30 minutes longer than STER or EFTR ( $P < 0.01$ ). Total hospital stay for the laparoscopic-assisted resection group was also longer when compared to STER (1.5) and EFTR (1.8) ( $P < 0.01$ ).

**Conclusions** STER, EFTR, and laparoscopic-assisted resection are efficacious approaches for resection of SETs with similar R0 resection rates, complication rates, and AE rates. Laparoscopic assisted resection appears more time-consuming and is associated with a longer hospital stay.



► **Fig. 1** Laparoscopic-assisted endoscopic resection. **a** Subepithelial lesion next to the cardia. **b** Full-thickness endoscopic resection including muscularis propria and exposing serosa layer. **c** Endoscopic view of laparoscopic gastric suture to close the defect. **d** Specimen resected en bloc. Histology revealed a gastrointestinal stromal tumor (GIST) from the muscularis propria without mitosis with free margins. Immunohistochemistry revealed positivity for CD117 and CD34.



► **Fig. 2** Submucosal tunneling for endoscopic resection. **a** Subepithelial lesion in the stomach before STER. **b** Opening of the tunnel with horizontal incision. **c** Isolation of the lesion within the tunnel created. **d** Removal of the lesion leaving an empty tunnel. **e** Closure of the opening with clips.

## Introduction

The number of gastrointestinal subepithelial tumors (SETs) identified is increasing with the use of endoscopic ultrasonography (EUS) [1]. SETs are tumors that originate from beneath the mucosal layer [2]. Upper gastrointestinal SETs <2 cm can often be followed with periodic surveillance with endoscopy and EUS. However, some of these tumors have the potential to become malignant and may require resection. The malignant potential of SETs has been reported to be around 13% in EUS series [3]. Certain factors on EUS have been associated with increased risk of malignancy including large tumor size, heterogeneous echo pattern or cystic spaces on EUS, along with ulceration [4–6]. Those originating from the muscularis propria (MP) layer or those of large diameter have a higher potential to become malignant requiring resection [7].

Techniques that are available for lesion removal include surgery or endoscopic resection. Submucosal esophageal and gastric lesions can be removed endoscopically using different advanced endoscopic techniques. Submucosal tunneling for endoscopic resection (STER) is an effective endoscopic way of resecting tumors [8–11] that involves tunneling within the submucosa surrounding the lesion in order to complete the en bloc resection. Endoscopic full-thickness resection (EFTR) is also a safe and effective way to resect SETs [12, 17–19]. This technique involves removal of the lesion by creating a full-thickness defect that is closed after en bloc removal. An alternative technique involves laparoscopic endoscopic cooperative surgery (LECS) where the lesion is partially resected using endoscopic

submucosal dissection (ESD) technique and then fully removed and/or closed with laparoscopic surgery [20]. In this study, we aim to compare the endoscopic techniques of STER and EFTR with LECS.

## Patients and methods

### Patients

Consecutive patients who underwent resection of a submucosal esophageal or gastric lesion (► **Fig. 1** and ► **Fig. 2**) from nine tertiary care centers and 12 endoscopists were included in a dedicated registry over three years. The performing endoscopists were specifically trained in ESD with at least 50 ESDs performed prior to conducting EFTR or STER procedures. All of the surgically assisted LECS were performed using the classical LECS method.

Demographics, size of resected lesion, location of lesion, histology of specimen, length of procedure, adverse events (AEs), duration of hospital stay, and follow-up data were collected. We used the size and location of the lesion to determine which technique would be best suited for the patient.

### Statistics

One-way analysis of variance (ANOVA), and *t*-test analyses were conducted for comparing continuous variables between the groups, while Chi Square and Fisher's exact tests were used for categorical variables. Two-sided *P* < 0.05 was considered statistically significant. All descriptive and statistical analyses were

► **Table 1** Comparison of clinical characteristics.

	STER	EFTR	LECS	P value
n	34	34	28	
Age (mean)	59.3 yrs (13.3 SD)	61.6 yr (16.3 SD) median 65	59 yr (SD 11) median 61.5	.821537
Gender Male	19 (56%)	14 (41%)	12 (43%)	
Procedure time (mins)	96.2 (SD 52)	87.6 (SD 40.7)	128.7 (SD 48.6)	.000078

STER, submucosal tunnel endoscopic resection; EFTR, endoscopic full-thickness resection; ESD endoscopic submucosal dissection; SD, standard deviation.

conducted using MedCalc V18.9 (MedCalc Software, Ostend, Belgium).

## Results

### Clinical characteristics

A total of 96 patients were included in the study (47.7% male, mean age 62): STER n=34, EFTR n=34, LECS n=28. The histology of the lesions pre-resection included leiomyoma (n=25), GIST (n=41), ectopic pancreas (8), lipoma (8), schwannoma (4), carcinoid tumors (5), and granular cell tumors (5). Most of the lesions in the EFTR and LECS were GISTs. In the STER group, there were more lesions categorized as “other (ectopic pancreas, lipoma, schwannoma, carcinoid tumor and granular cell tumors)” in comparison to leiomyoma and GIST (► **Table 1**).

There was no statistically significant difference between the resection sizes of STER (23.2 mm, SD 18.2 mm), EFTR (35.7 mm, SD 15.8 mm), and LECS (33.4 mm, SD 16.7 mm).

### Procedure time and hospital stay

The mean procedure time was 96.2 minutes (range, 43–153), 87.6 minutes (45.3–127.2), and 128.7 minutes (92.8–185) for the STER, EFTR, and LECS groups, respectively. Within the STER group, the endoscopic method of closure included 21 patients getting clips, six patients getting over-the-scope clips (OTSCs) and 16 patients getting endosuturing.

Within the EFTR group, the endoscopic method of closure included six patients getting clips, five patients getting OTSCs and 28 patients getting endosuturing.

The mean length of hospital stay was 1.5, 1.8, and 2.3 days for the STER, EFTR, and LECS groups, respectively. The LECS group procedure time and hospital stay were significantly longer than for both STER and EFTR ( $P<0.01$ ). LECS cases were at least 30 minutes longer than STER or EFTR ( $P<0.01$ ). Total hospital stay for the LECS group was also longer than compared to STER (1.5) or EFTR (1.8) ( $P<0.01$ ).

### Histopathology assessment

In the STER group, final histopathology showed nine leiomyomas (26.5%), seven GISTs (20.5%), and 18 “other” tumors (53%). In the EFTR group, there were six leiomyomas (17.5%), 20 GISTs (59%) and eight “other” tumors (23.5%). In the LECS group, there were 10 leiomyomas (35.7%), 14 GISTs (50%), and four “other” tumors (14.3%) (► **Table 2** and ► **Table 3**). The

► **Table 2** Location of tumor lesions.

	STER	EFTR	LECS
Upper esophagus	1	0	0
Mid esophagus	3	1	0
Lower esophagus	8	3	1
Gastroesophageal junction	2	3	2
Fundus	2	13	13
Body	10	7	9
Antrum	8	7	3
Total	34	34	28

STER, submucosal tunnel endoscopic resection; EFTR, endoscopic full-thickness resection; ESD, endoscopic submucosal dissection.

► **Table 3** Histopathology of lesions.

	STER N=34	EFTR N=34	LECS N=28
Leiomyoma	9	6	10
GIST	7	20	14
Schwannoma	1	0	3
Other benign tumor	11	2	0
Other	6	6	1
Size on resection	23.2 mm (SD 18.2 mm)	35.7 mm (SD 15.8 mm)	33.4 mm (SD 16.7)

STER, submucosal tunnel endoscopic resection; EFTR, endoscopic full-thickness resection; ESD, endoscopic submucosal dissection; GIST gastrointestinal stromal tumor; SD, standard deviation.

pathological findings showed clear margins in 32 (94%) STER group, 33 (97%) in the EFTR group, and 28 (100%) in the LECS group. The difference was not statistically significant, ( $P=0.83$ ). These lesions were diagnosed histologically before resection with EUS fine needle aspiration.

► **Table 4** Operative complications according to procedure.

Complication	Clavien-Dindo classification	STER	EFTR	LECS
n		34	34	28
Pneumoperitoneum	2b	1	1	2
Perforation	2b	0	1	2
Gastrointestinal intraluminal hemorrhage	2b	0	0	2
Intra-abdominal hemorrhage	2b	0	0	3

STER, submucosal tunnel endoscopic resection; EFTR, endoscopic full-thickness resection; ESD, endoscopic submucosal dissection.

► **Table 5** Post-procedure results.

	STER	EFTR	LECS	P value
n	34	34	28	
Complications	1 (3%)	3 (9%)	9 (32%)	.02968
Clear margins on resection	32 (94%)	33 (97%)	28 (100%)	0.829158
Post-procedure hospital stay (days)	1.5 (SD 0.78)	1.8 (SD 1)	2.3 (SD 0.71)	<.00001
Recurrence	1	0	0	
Total follow-up duration (months)	13 months (SD 10.7)	13 months (SD 8.8)	12.5 months (SD 6.7)	.06155

STER, submucosal tunnel endoscopic resection; EFTR, endoscopic full-thickness resection; ESD endoscopic submucosal dissection; SD, standard deviation.

## Complications

There was no significant difference between groups in the incidence of complications (► **Table 4**). There was one complication (3%), consisting of a pneumoperitoneum requiring decompression, in the STER group. In the EFTR group, there was one case (3%) of pneumoperitoneum requiring decompression and two cases of perforation (6%). One was an esophageal tear treated with clip placement. The other case of perforation was a delayed perforation seen after recovery of the patient. In comparison, there were two cases (7%) of gastrointestinal intraluminal hemorrhage, two cases (7%) of perforation and three cases (10.7%) of intra-abdominal hemorrhage seen in the LECS group. Intra-abdominal hemorrhage was the result of delayed bleeding in the two cases in the LECS group. The two gastrointestinal intraluminal hemorrhage only required transfusion and resolved spontaneously. Two of three patients with intra-abdominal hemorrhages required observation only. The third one was temporized with clipping and then went to surgery.

## Follow-up after treatment

Patients were followed up with repeat endoscopy at 3, 6, and 12 months post-procedure. If any abnormality was seen, further imaging was obtained. The mean follow-up time was 13, 13, and 12.5 months in the STER, EFTR, and LECS groups, respectively (9.8–10.1). There was one recurrence (3%) in the STER group. This was seen 3 years post-resection in a patient with leiomyoma. The patient presented with dysphagia and un-

derwent endoscopy with repeat resection. No recurrence was noted in the EFTR and lap-assisted ESD group (► **Table 5**).

## Discussion

To our knowledge, our study is the first to report results comparing STER and EFTR of submucosal gastric and esophageal lesions with laparoscopic-assisted resection. EFTR and STER is indicated for SETs that are <5 cm in diameter, arising from the muscularis propria. If they are greater than 5 cm, the combined surgical approach such as LECS is recommended. STER is utilized in areas of the GI tract where tunneling is possible. Use of EFTR is limited for esophageal SETs. For esophageal lesions, STER is preferable. EFTR is used for gastric, duodenal lesions and colonic lesions [21]. STER is used in locations where a tunnel can be made and be reached in a straight line, which includes from the mid esophagus to the gastric cardia [22].

Endoscopic resection has many advantages over surgical resection such as utilizing the natural cavity of the patient thereby leaving no scars on the abdomen, reducing inflammatory factors associated with surgical trauma, and lower incidences of infection [23]. Endoscopic resection also allows for limited alteration of anatomy of the upper gastrointestinal tract compared to surgical resection of the gastric cavity, which completely changes the anatomy of the structure and may lead to other comorbidities. And lastly, endoscopic resection has less bleeding and higher manipulation ability than laparoscopic resection. However, endoscopic resection is generally not feasible for large tumors, which often require surgical resection. A

study by Wang et al. [23] retrospectively compared endoscopic and laparoscopic resection on non-intracavitary gastric stromal tumors in 66 patients. The study demonstrated that the median operation times and hospitalization fees of the endoscopic group were significantly lower than the laparoscopic group. This study showed that hospital stay for the two groups was similar [23].

More than 20 studies using STER have been published with outcome data on 700 plus patients showing a pooled therapeutic success of >77% with an en bloc resection rate of >85% and no recurrences [24]. In >20 studies where STER had been used, there was a decreased rate of serious complications and there was no STER-associated mortality reported. [1] Wang et al [25] conducted a retrospective study of 39 patients with esophageal leiomyoma in which 21 of the patients received ESD and 18 of the patients received STER. The study demonstrated that the efficacy and complications of the ESD and STER were comparable, but STER was associated with decreased operating time, shorter duration of hospital stay, and faster rate of healing of the incision when compared with ESD. A large study consisting of 290 patients with SETs who underwent STER had an overall incidence rate of complications at 23.4% (68/290) [26]. Xu et al. [8] reported a 13.3% perforation rate (2 of 15) in their study for resection of esophageal SETs with STER. This study demonstrated a mean procedure time of 78.7 minutes (range 25–130 minutes) and showed that all the lesions were successfully resected with lateral and vertical free margins [8]. A study by Ye et al. [27] in which resection was done for esophageal SETs showed a perforation rate of 20% (3 of 15). The average follow-up period was of 3.5 months after treatment with STER (range 1–9 months) and there was no residual tumor tissue or tumor recurrence noted in the study [27]. Our study had a perforation rate of 3.3% (1 of 30). It may differ from the Xu et al. [8] study since all large defects in the EFTR group were closed with endoscopic suturing in the patients treated endoscopically, decreasing the chance of delayed perforation. The mean procedure time for our study was 104 min ( $P < 0.01$ ) which is in the range for the Xu et al. [27] study. Our study was similar and showed that the clear margins were obtained on 94% of the tumors (32/34). Our study had a longer follow-up period consisting of an average of 13 months in STER group and there was one case (3%) of recurrence of tumor noted.

EFTR has been less studied than STER in the literature and may be less preferable than STER because mucosal integrity is left intact during STER but not EFTR [8, 27, 28]. The key to the EFTR procedure is the ability to close the wall defect after resection to prevent complications requiring surgery [12]. A study carried out by Tan et al. [29] was able to demonstrate from 52 procedures that both EFTR and STER are comparable in terms of procedure time, safety, and effectiveness when defect closure is complete [29]. A study of 26 patients with gastric SETs that originated from the MP treated with EFTR showed a complete resection rate of 100% with a mean operative time of 105 minutes (range, 60–145). [12] There were no AEs such as bleeding, peritonitis or abscess seen after treatment. There were no residual or recurrences found during the follow-up period (mean, 8 months; range, 6–24 months) [12].

Our study was able to show 33 of 34 (97%) negative histologic margins on endoscopic resection, which is similar to other studies using EFTR. No recurrence was seen on follow-up of at least 13 months. Closure of the resection site was performed with an endoscopic suturing system in the United States and with hemostatic clips and an endoloop technique in Asia and Latin America.

Our study demonstrated a similar rate of AEs, shorter procedure time, and shorter hospital stay when comparing endoscopic resection to LECS with no significant difference in recurrence during follow-up.

A limitation of this study is that experienced endoscopists performed the procedures. Given that the SETs discussed in this study arise from the MP layer, ESD experts who are able to manage possible complications should perform it. Another limitation is related to the selection of technique offered in each case; indeed, lesions treated with LECS might have been more complex based on location or depth in the stomach while LECS in the esophagus is not feasible.

## Conclusions

In conclusion, we consider the treatment of SET with STER and EFTR to be safe and effective with similar rates of AEs, shorter procedure time and shorter hospital stay compared with LECS. STER and EFTR are minimally invasive and effective treatments for selected patients with SET. These endoscopic approaches may prevent the need for surgical resection without compromising curability.

## Competing interests

Avik Sarkar has done consulting work for US Endoscopy and Obalon Therapeutics. Haroon Shahid has done consulting work for US Endoscopy. Amy Tyberg has done consulting work for NinePoint Medical, EndoGastric Solutions, and Obalon Therapeutics. Michel Kahaleh has done consulting work for Boston Scientific, Interscope Med, and Abbvie. He has received research grants from Boston Scientific, Emcision, Conmed, Pinnacle, Cook, Gore, Merit, and Olympus. Monica Gaidhane has done consulting for 3D Matrix

## Clinical trial

ClinicalTrials.gov  
NCT05041608

**TRIAL REGISTRATION:** Retrospective trial NCT05041608 at ClinicalTrials.gov (<http://www.clinicaltrials.gov/>)

## References

- [1] Yuyong TanJH, Deliang Liu. Current status of submucosal tunneling endoscopic resection for gastrointestinal submucosal tumors originating from the muscularis propria layer (Review). *Oncology Letters* 2017; 14: 5085–5090

- [2] Faulx AL, Kothari S, Acosta RD et al. The role of endoscopy in subepithelial lesions of the GI tract. *Gastrointest Endosc* 2017; 85: 1117–1132
- [3] Polkowski M. Endoscopic ultrasound and endoscopic ultrasound-guided fine-needle biopsy for the diagnosis of malignant submucosal tumors. *Endoscopy* 2005; 37: 635–645
- [4] Chak A, Canto MI, Rosch T et al. Endosonographic differentiation of benign and malignant stromal cell tumors. *Gastrointest Endosc* 1997; 45: 468–473
- [5] Palazzo L, Landi B, Cellier C et al. Endosonographic features predictive of benign and malignant gastrointestinal stromal cell tumours. *Gut* 2000; 46: 88–92
- [6] Kawamoto K, Yamada Y, Utsunomiya T et al. Gastrointestinal submucosal tumors: evaluation with endoscopic US. *Radiology* 1997; 205: 733–740
- [7] Toshiro N, Naoki K, Shinjiro Y et al. Submucosal tumors: Comprehensive guide for the diagnosis and therapy of gastrointestinal submucosal tumors. *Digestive Endoscopy* 2013; 25: 479–489
- [8] Xu MD, Cai MY, Zhou PH et al. Submucosal tunneling endoscopic resection: a new technique for treating upper GI submucosal tumors originating from the muscularis propria layer (with videos). *Gastrointest Endosc* 2012; 75: 195–199
- [9] Lu J, Zheng M, Jiao T et al. Transcardiac tunneling technique for endoscopic submucosal dissection of gastric fundus tumors arising from the muscularis propria. *Endoscopy* 2014; 46: 888–892
- [10] Li QL, Chen WF, Zhang C et al. Clinical impact of submucosal tunneling endoscopic resection for the treatment of gastric submucosal tumors originating from the muscularis propria layer (with video). *Surg Endosc* 2015; 29: 3640–3646
- [11] Wang H, Tan Y, Zhou Y et al. Submucosal tunneling endoscopic resection for upper gastrointestinal submucosal tumors originating from the muscularis propria layer. *Eur J Gastroenterol Hepatol* 2015; 27: 776–780
- [12] Zhou PH, Yao LQ, Qin XY et al. Endoscopic full-thickness resection without laparoscopic assistance for gastric submucosal tumors originated from the muscularis propria. *Surg Endosc* 2011; 25: 2926–2931
- [13] Tan Y, Tang X, Guo T et al. Comparison between submucosal tunneling endoscopic resection and endoscopic full-thickness resection for gastric stromal tumors originating from the muscularis propria layer. *Surg Endosc* 2017; 31: 3376–3382
- [14] Zhou DJ, Dai ZB, Wells MM et al. Submucosal tunneling and endoscopic resection of submucosal tumors at the esophagogastric junction. *World J Gastroenterol* 2015; 21: 578–583
- [15] Huang LY, Cui J, Lin SJ et al. Endoscopic full-thickness resection for gastric submucosal tumors arising from the muscularis propria layer. *World J Gastroenterol* 2014; 20: 13981–13986
- [16] Guo J, Liu Z, Sun S et al. Endoscopic full-thickness resection with defect closure using an over-the-scope clip for gastric subepithelial tumors originating from the muscularis propria. *Surg Endosc* 2015; 29: 3356–3362
- [17] Chiu PWY, Phee SJ, Wang Z et al. Feasibility of full-thickness gastric resection using master and slave transluminal endoscopic robot and closure by overstitch: a preclinical study. *Surgical Endoscopy* 2014; 28: 319–324
- [18] Shi Q, Chen T, Zhong YS et al. Complete closure of large gastric defects after endoscopic full-thickness resection, using endoloop and metallic clip interrupted suture. *Endoscopy* 2013; 45: 329–334
- [19] Schlag C, Wilhelm D, von Delius S et al. EndoResect study: endoscopic full-thickness resection of gastric subepithelial tumors. *Endoscopy* 2013; 45: 4–11
- [20] Hiki N, Nunobe S. Laparoscopic endoscopic cooperative surgery (LECS) for the gastrointestinal tract: Updated indications. *Ann Gastroenterol Surg* 2019; 3: 239–246
- [21] Cai MY, Carreras-Presas Martin F, Zhou PH. Endoscopic full-thickness resection for gastrointestinal submucosal tumors. *Dig Endosc* 2018; 30: 17–24
- [22] Zhang X, Modayil R, Criscitelli T et al. Endoscopic resection for subepithelial lesions-pure endoscopic full-thickness resection and submucosal tunneling endoscopic resection. *Transl Gastroenterol Hepatol* 2019; 4: 39
- [23] Wang L, Ren W, Fan CQ et al. Full-thickness endoscopic resection of nonintracavitary gastric stromal tumors: a novel approach. *Surg Endosc* 2011; 25: 641–647
- [24] Inoue H, Ikeda H, Hosoya T et al. Submucosal endoscopic tumor resection for subepithelial tumors in the esophagus and cardia. *Endoscopy* 2012; 44: 225–230
- [25] Wang L, Ren W, Zhang Z et al. Retrospective study of endoscopic submucosal tunnel dissection (ESTD) for surgical resection of esophageal leiomyoma. *Surg Endosc* 2013; 27: 4259–4266
- [26] Chen T, Zhang C, Yao LQ et al. Management of the complications of submucosal tunneling endoscopic resection for upper gastrointestinal submucosal tumors. *Endoscopy* 2016; 48: 149–155
- [27] Ye LP, Zhang Y, Mao XL et al. Submucosal tunnelling endoscopic resection for the treatment of esophageal submucosal tumours originating from the muscularis propria layer: an analysis of 15 cases. *Dig Liver Dis* 2013; 45: 119–123
- [28] Tang X, Ren Y, Huang S et al. Endoscopic submucosal tunnel dissection for upper gastrointestinal submucosal tumors originating from the muscularis propria layer: a single-center study. *Gut Liver* 2017; 11: 620–627
- [29] Tan Y, Lv L, Duan T et al. Comparison between submucosal tunneling endoscopic resection and video-assisted thoracoscopic surgery for large esophageal leiomyoma originating from the muscularis propria layer. *Surg Endosc* 2016; 30: 3121–3127