

# Main Principles of Vitrectomy Using Intraocular Tamponades – A Basic Course in Surgery

## Grundlagen der Vitrektomie unter Verwendung intraokularer Tamponaden – ein chirurgischer Basiskurs



### Authors

Carsten Framme<sup>1</sup>, Helmut G. Sachs<sup>2</sup>, Joachim Wachtlin<sup>3</sup>, Nikolaos E. Bechrakis<sup>4</sup>, Hans Hoerauf<sup>5</sup>, Veit-Peter Gabel<sup>6</sup>

### Affiliations

- 1 Augenklinik, Medizinische Hochschule Hannover, Deutschland
- 2 Augenklinik, Carl-Thiem-Klinikum Cottbus gGmbH, Deutschland
- 3 Augenheilkunde, Sankt Gertrauden-Krankenhaus, Berlin, Deutschland
- 4 Klinik für Augenheilkunde, Universitätsklinikum Essen, Deutschland
- 5 Augenheilkunde, Universitätsmedizin Göttingen, Deutschland
- 6 Augenheilkunde, Universität Regensburg, Emeritus, München, Deutschland

### Key words

vitrectomy, silicone oil, perfluorocarbons, sulfur hexafluoride, intraocular tamponades, retinal retachment

### Schlüsselwörter

Vitrektomie, Silikonöl, Perfluorocarbone, Schwefelhexafluorid, intraokulare Tamponaden, Netzhautablösung

received 28.4.2022

accepted 30.7.2022

### Bibliography

Klin Monatsbl Augenheilkd 2022; 239: 1337–1353

DOI 10.1055/a-1929-9413

ISSN 0023-2165


© 2022. The Author(s).

This is an open access article published by Thieme under the terms of the Creative Commons Attribution-NonDerivative-NonCommercial-License, permitting copying and reproduction so long as the original work is given appropriate credit. Contents may not be used for commercial purposes, or adapted, remixed, transformed or built upon. (<https://creativecommons.org/licenses/by-nc-nd/4.0/>)

Georg Thieme Verlag KG, Rüdigerstraße 14,  
70469 Stuttgart, Germany

### Correspondence

Prof. Carsten Framme, MD, FEBO, MHM, MBA  
Augenklinik, Medizinische Hochschule Hannover  
Carl-Neuberg-Str. 1, 30625 Hannover, Deutschland  
Phone: + 49 (0) 51 15 32 30 60, Fax: + 49 (0) 51 15 32 16 10 53  
Framme.Carsten@mh-hannover.de

 Supplementary material is available under  
<https://doi.org/10.1055/a-1929-9413>

### ABSTRACT

This article is intended to clearly present the basic principles for the use of intraocular tamponades in vitreous/retinal surgery in the event of retinal detachment and other pathologies using additional video footage. It examines the various gases, silicone oils and perfluorocarbon liquids with their indications, administration and in particular intraoperative handling including pitfalls and complications. Characteristic animations show the principles of use in surgery in a comprehensible way. The two lead authors dedicate this article to their teacher Prof. Dr. V.-P. Gabel, who in the early 1990s successfully established the first vitrectomy courses for ophthalmologists at Regensburg University Eye Clinic each year. Many colleagues who still work in retinal surgery today first started learning about this segment on these courses. The other coauthors participated under his supervision in annual vitrectomy wet labs run by the German Academy of Ophthalmology.

### ZUSAMMENFASSUNG

In diesem Artikel sollen die Grundlagen zur Verwendung intraokularer Tamponaden in der Glaskörper-/Netzhautchirurgie bei Ablatio retinae und anderen Pathologien anhand zusätzlichen Videomaterials anschaulich dargestellt werden. Behandelt werden die verschiedenen Gase, Silikonöle und flüssigen Perfluorocarbone mit ihren Indikationen, ihrer Anwendung und insbesondere der intraoperativen Handhabung mit Fallstricken und Komplikationen. Charakteristische Animationen

zeigen dabei nachvollziehbar die Prinzipien in der chirurgischen Handhabung. Seitens der beiden Erstautoren ist dieser Artikel ihrem Lehrer Herrn Prof. Dr. V.-P. Gabel gewidmet, der in den frühen 90er-Jahren die ersten Vitrektomiekurse für Augenärzte an der Universitäts-Augenklinik Regensburg erfolgreich im jährlichen Rhythmus etabliert hat und in denen viele

heute noch netzhautchirurgisch tätige Kolleginnen und Kollegen ihre ersten Schritte in diesem Segment erlernt haben. Die weiteren Co-Autoren partizipierten unter seiner Leitung an jährlichen Vitrektomie-Wetlabs im Rahmen der Augenärztlichen Akademie Deutschlands.

## Introduction

It would be inconceivable to carry out modern retinal surgery using the pars plana vitrectomy (PPV) technique without adequate agents and tamponades designed for intraocular applications. In the context of classic scleral buckling surgery for retinal detachments using filling or cerclage, with and without subretinal transscleral drainage, an intraocular tamponade is not necessarily required in order to successfully reattach the retina. Successful treatment results can be achieved solely through reattachment of the foramen to its base using the buckling technique and corresponding cryocoagulation for scarring, enabling fluid absorption via the retinal pigment epithelium (RPE). If external drainage is used for the subretinal fluid, the hypotonia that then occurs in the eye bulb can, depending on the extent of the drainage, be compensated by means of a transscleral air or gas injection. In the surgical approach without subretinal drainage, the increase in volume that is required beforehand on account of the buckling can be achieved by paracentesis of the anterior chamber and, if necessary, multiple iterations of fluid removal. Depending on the consistency of the potentially viscous subretinal fluid and the pumping ability of the RPE, complete reattachment of the retina with this surgical method can sometimes take days or even weeks. Nevertheless, if the retina is successfully reattached, it is highly probable that no retinal holes will have been missed, which means the result remains stable. On the other hand, with external drainage, there is the advantage that reattachment is usually very quick. However, during the early postoperative phase, it is not possible to be sure whether a foramen may have been overlooked that could result in a recurrence of the detachment. Faude et al. provide an excellent overview of buckling surgery in a review from 2002 [1], as do Hoerauf et al. in 2008 [2]; both of these publications are still of current relevance.

Buckling surgery has fallen from favor in recent years, especially given the increasing prevalence of sutureless 23 G, 25 G, and 27 G vitrectomy techniques [3,4]. Since it is paramount that the eye lens—which becomes cloudy within one year of vitreous surgery in approximately 30% of cases—is preserved as much as possible, scleral buckling surgery is currently mainly performed on younger patients. In these younger patients the vitreous body, which is usually still very compact, adheres strongly to the retina, and “complete” separation of the vitreous body can only be partially performed, or else entails a significantly increased risk of retinal lesions. Thus, further possible indications for scleral buckling surgery include inferior retinal detachments with foramen/foramina in the lower circumference in younger patients. However, surgeons these days have much more experience with primary vitrectomy, which is more common and quicker to perform, and

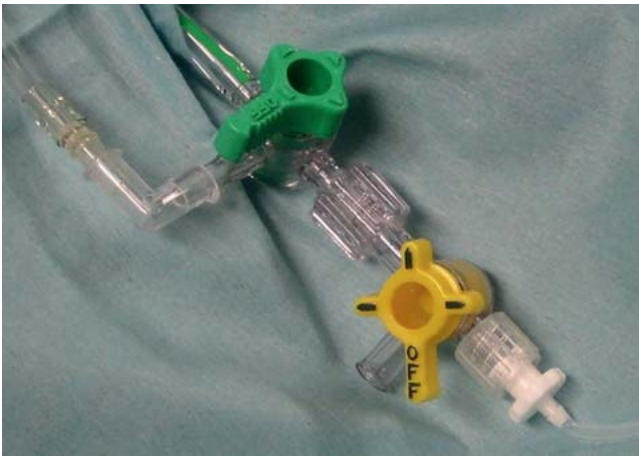allows easier visualization of foramina; hence, the skills needed for scleral buckling surgery are increasingly being lost. Another advantage of vitrectomy is that even highly complex vitreoretinal pathologies can be successfully treated with the initial surgery. Still, scleral buckling techniques should remain available for the reasons mentioned above, and training and education for this surgery should continue.

These days, pseudophakic retinal detachment, which is more commonly caused by smaller, preoral foramina rather than equatorially located horseshoe-shaped foramina, and which has therefore been operated on for a long time using a combination of vitrectomy and cerclage, can also be treated with vitrectomy alone (with 20 G PPV or with 23–25 G PPV using a trocar system), achieving the same or better results for permanent reattachment [5]. For successful treatment, depending on the severity of the initial condition, intraoperative substances such as air, gas, perfluorocarbon liquid (PFCL), and, if necessary, silicone oil are required. With regard to the gases and perfluorocarbons, Faude et al. have also published older but very detailed reviews on the chemistry, effects, and corresponding fields of clinical application [6–8]. The purpose of this overview is to give a detailed description of the surgical procedure, especially when using intraocular tamponades, intended as a basic course in surgery.

## Surgical Setup

The supply lines of modern vitrectomy machines may vary more or less depending on their design. Generally speaking, the infusion port, which in a traditional 20 G vitrectomy, after opening the conjunctiva and after sclerostomy, is inserted through the sclera and into the vitreous cavity using a suitable piercing instrument, usually 3.5–4 mm inferotemporal to the limbus, and is then fixed with a suture, delivers fluid (e.g., Balanced Salt Solution [BSS]) from the machine to the eye such that the intraocular pressure can be individually adjusted by the machine. In a phakic situation, a shorter 4 mm infusion port is preferred so as not to compromise the lens. In a pseudophakic or aphakic situation, the longer 6 mm infusion port can be used. Especially when it comes to complex retinal detachments with, for example, proliferative vitreoretinopathy (PVR), primary choroidal swelling, or choroidal hemorrhages, and a probable need for oil filling, the 20 G vitrectomy is often preferred, as it may allow for better subretinal surgery using curved instruments, and it can make oil filling easier. However, in principle, oil insertion and subretinal surgery are also possible with PPV using a trocar system.

The port is always placed in the eye with the infusion turned off, and before the infusion is turned on, it is necessary to check that there is a secure intravitreal fit in order to definitively rule



► **Fig. 1** Possible setup for supply of BSS, air, and gas for pars plana vitrectomy.

out possible infusion into the choroid (this is most easily done by looking at the eye at an angle from the side on which the microscope is located; the infusion is turned on by gently pressing the infusion port into the eye and allowing it to slide back slightly after opening). A longer infusion port is more secure for optimal intravitreal placement, but also carries with it the risk of damaging the lens if there is tilting or if the eye is phakic. It is therefore useful to secure the tube with a SteriStrip. The same principle applies to vitrectomy using a trocar system. Parallel to the water supply, you can switch to the air supply on the machine (or alternatively via the tube system). In addition, a (further) 3-way valve allows gas to be injected by means of a syringe (► **Fig. 1**). After the infusion has begun, two further sclerostomies are carried out in nasal and superotemporal positions, e.g., at the point midway between the 1 and 2 o'clock positions and midway between the 10 and 11 o'clock positions (as far apart as possible so that the thumbs do not touch). Bougienage of the openings with a tapered probe makes it easier to insert the instruments during a 20 G vitrectomy. In addition, care should be taken to ensure that the conjunctiva and tenon are removed cleanly in order to avoid possible epithelial invasion and to ensure that wound conditions are adequate for re-adaptation at the end of the operation (mainly by cross-stitching with a braided Vicryl suture or a monofilament PDS7.0 suture). Wound insufficiencies can also occur in vitrectomy using a trocar system; in which case, (transconjunctival) suturing is also required.

As a general rule, when performing surgical techniques using trocar systems, air or gas should be left in the eye at the end of the operation, at least in the anterior space, in order to achieve improved wound tightness. Mild postoperative hypotonia is usually not a problem and will resolve by itself. But it can, of course, increase the risk of vitreous hemorrhage or choroidal amotion, as well as bleeding from the sclerostomy entrance points.

### Intraocular behavior of air and gas/air mixtures

	Expansion pure	nonexpansive mixture	Half-life days	duration of stay 1 ml pure
Air	1x		1-1.5	5-7d
SF <sub>6</sub>	2-2.5x	20%	2,5	10 d
C <sub>2</sub> F <sub>6</sub>	3,3x	16%	3,5	30 d
C <sub>3</sub> F <sub>8</sub>	4x	12%	5	55 d

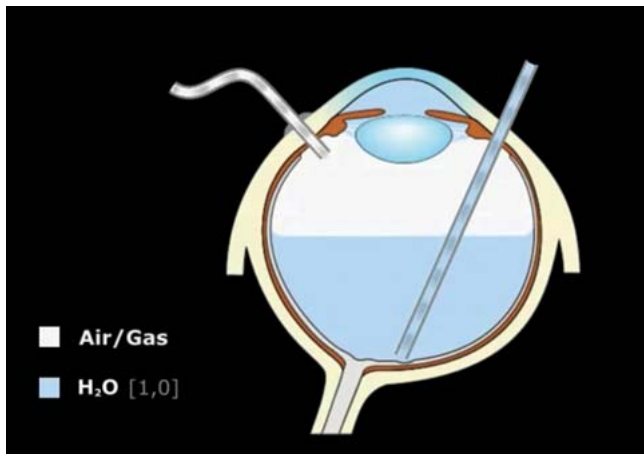
► **Fig. 2** Characteristics of the retention time of air and gases in the eye (adapted from [6, 9]).

## Water–Air Exchange

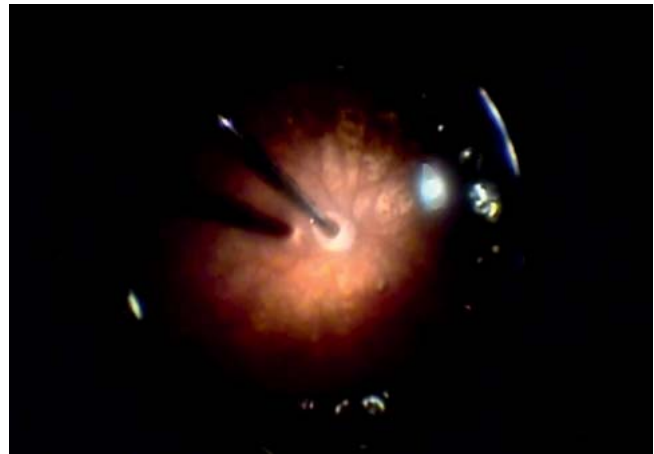
Air has a half-life of about 1–1.5 days and generally stays in the eye for about 5–7 days after complete filling (► **Fig. 2**; adapted from [6, 9]). It is important for patients to be informed about the prohibition on flying or taking trips to higher altitude regions until the air or gas tamponade has been completely reabsorbed, since the air or gas expansion in the eye can cause an increase in pressure, potentially leading to circulatory disorders in the central artery, with the associated risk of blindness. It is not possible to definitively specify a safe altitude. Experiences vary, from having pressure problems starting at a few hundred meters up to no problems at all at over 2,000 meters; this presumably also depends individually on the amount of gas in the eye. Patients are also advised against diving if they have had gas filling, because the increased external pressure of the water with possible tissue compression can be problematic. When using gases, it is important, from an intraoperative perspective, to know the non-expansive mixing ratios of gas and air (► **Fig. 2**).

► **Fig. 3** shows the simple complete water–air exchange. With an attached retina this can easily be achieved via the machine-adjusted air supply if the so-called flute needle is inserted through the sclerostomy incision to the posterior pole, through which the intraocular water is then flushed out by the air pressure (► **Fig. 3/Video 1 [Supplementary material A]** and ► **Fig. 4/Video 2 [Supplementary material B]**). Similarly, there is also the option of actively suctioning the aqueous phase with the cutter or vitrector. In the animations it should be noted that, contrary to the less-than-optimal representation of the flute needle over the fovea, the flute needle should for the most part be held over the deepest point of the eye, namely the optic disk.

An air–water exchange of this kind with three to four repeats is generally recommended, for example, when removing silicone oil (see below), in order to be able to remove as many residual oil bubbles as possible, some of which are emulsified and which usually gather at the interface at which the opening of the flute needle should be held when filling air. If you switch back to



► **Fig. 3** Simple water–air exchange with attached retina. The machine injects air into the eye via the infusion tube (air/gas). The water ( $\text{H}_2\text{O}$ ) is flushed out of the eye with the flute needle (see ► **Video 1** [Supplementary material A]).



► **Fig. 4** Simple intraoperative water–air exchange. The flute needle is moved further and further, following the water level, until it reaches the optic disk (see ► **Video 2** [Supplementary material B]).

“water” after completing the air filling, this can lead to short-term hypotonia of the bulb, which can be regulated by adjusting the flute needle. In order to reduce the risk of postoperative bleeding, air can be left in the eye at the end of the operation to prevent hypotonia. However, this is not absolutely necessary in the case of an attached retina with no other pathology, as long as the sclerostomy incisions are sutured. Once the procedure has been completed, the infusion port is removed and the suture that is usually put in place beforehand is pulled shut and tied. In vitrectomy with a trocar system, the trocars are simply pulled out. Since they have built-in valves, they do not represent an open system on the eye, which is why some of authors still prefer 20 G vitrectomy for the surgical treatment of endophthalmitis, as it allows a wide-lumen flow through which pathogens may be better flushed out. However, this can also be achieved by means of active suction with a trocar system by or removing the valves from the trocars. Note that if the eye is filled with air, the peripheral retina is depicted over a larger area (“you have a more peripheral view”), although this detracts from the visibility of the retinal structures themselves. After a posterior capsulotomy has been newly performed during vitrectomy, fogging up on the back of an intraocular lens can be problematic as it impedes clear visibility of the posterior pole. Surgeons can inject BSS or a viscoelastic fluid into the back of the lens to improve visibility.

## Use of Gases

### Indications

Gases are used to treat rhegmatogenous and tractive retinal detachments up to PVR stage A/B [10], for simpler tractive detachments as part of proliferative retinopathies in vascular retinal diseases, and in macular surgery, whereby postoperative head positioning can result in mechanical pressure on the retina (► **Fig. 5**). According to the literature, the probability of being able to close a macular hole, for example, is about 90% or higher [11]. Especially

### Indications for intraocular gas application

- Primary ppV in rhegm. retinal detachment
- Primary ppV for PVR stages A / B
- Proliferative retinopathy with retinal holes, without strong hemorrhage
- Macular surgery
  - Macular hole formation, Macular pucker
  - Central retinal detachment in myopia, optic pit
  - If applicable: Vitreomacular traction
- Subretinal macular hemorrhage (r-tPA)

► **Fig. 5** List of possible indications for intraoperative gas filling.

in cases of subretinal macular bleeding, which occurs more frequently in neovascular age-related macular degeneration (AMD), the additional subretinal injection of a “recombinant tissue plasminogen activator (r-tPA)” with or without “VEGF inhibitor” is an option during vitrectomy for the liquefaction of clots and subsequent gas filling; placing the patient’s head in a downward position is also an option for mechanical expulsion of the blood into the periphery [12]. Epiretinal gliosis or vitreomacular traction syndrome do not usually require a gas endotamponade.

### Procedure for gas filling

Different techniques are used for gas filling. Gas can be injected into the air-filled eye bulb in an antegrade manner via the infusion port (3-way valve) with at least one sclerostomy hole open at the top, which is then tied off with a suture (20 G) shortly before the gas syringe is emptied. When the infusion port is pulled, especially in the case of 20 G surgery in which the suture is ideally

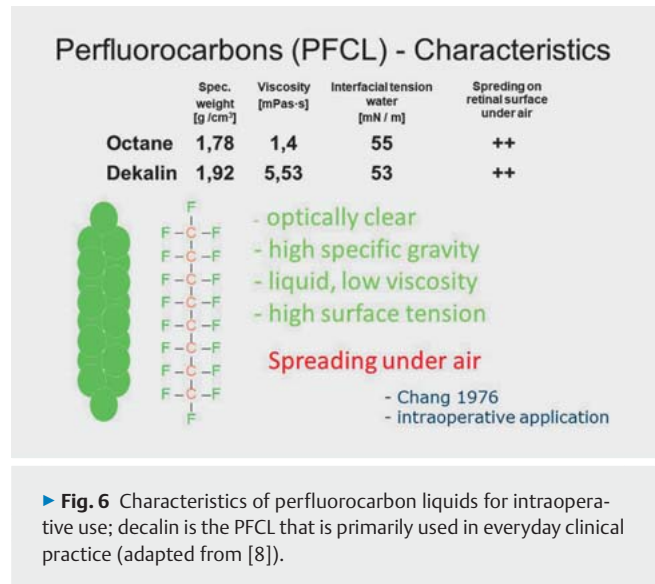
tightened immediately, the eye can usually be closed well with the appropriate gas filling and correct intraocular pressure. However, if loss of pressure is detected in this case, the appropriate intraocular pressure can be restored by means of transscleral reinjection with a 30 G cannula. For this reason, the syringe should always have a residual amount of gas left in it, which can be used for this maneuver. The approach for vitrectomy with a trocar system entails first pulling the two upper trocars and checking the sclerostomies for leaks (in an air-filled eye, there will be air bubbles when water is dripped onto the surface). If the results are inadequate, transconjunctival resuturing must be performed. After this, the air pressure on the machine is set very low and the gas is injected in a retrograde manner via the pars plana using a 30 G cannula. If you are working with a machine which does not allow injection to be performed against the air pressure on the machine, it is advisable to simultaneously use a second empty 30 G cannula through which the excess pressure can be released when the gas is slowly injected. In another technique, a 20-mL syringe with the gas mixture is connected to the 25 G port (Luer Lock), and pressure equalization (release) is then assured with a cannula via one of the upper 25 G ports. Alternatively, the gas mixture can also be injected via the 3-way valve on the infusion tubing. It is possible to select different syringe sizes while retaining the correct air-gas concentrations. What is important here is that the eye is flushed out several times with the gas mixture, so that the desired gas concentration is present inside the eye.

### Selecting the gas

For non-complex detachments with a “hole on top” situation, sulfur hexafluoride ( $\text{SF}_6$ ) is generally used; in a 20% gas-air mixture this is not expansive, and remains in the eye for around 10–14 days with a half-life of approximately 2.5 days (► Fig. 2). In case of retinal detachments with inferior holes, hexafluoroethane ( $\text{C}_2\text{F}_6$ ) 16% can be used since it has a significantly longer half-life and remains in the eye for about 4 weeks following vitrectomy. In retinal detachment surgery, for logical reasons, all foramina—after they have been adequately treated with an endolaser and/or cryoretinopexy—must remain pressed against their base via the gas tamponade for a few days until the scarring induced by the pexy is thick enough that the adhesions can no longer be loosened, and thus no more water can get from the vitreous cavity through the foramen into the subretinal space. This longer-acting gas can better guarantee this outcome, especially in the lower area. Octafluoropropane ( $\text{C}_3\text{F}_8$ ) has an even longer half-life and is a suitable alternative to  $\text{C}_2\text{F}_6$  in certain situations. The use of octafluoropropane in the context of retinal detachment surgery (e.g., in PVR) must be weighed up against the possibly safer option of silicone oil filling.

### Use of Perfluorocarbon Liquid (PFCL)

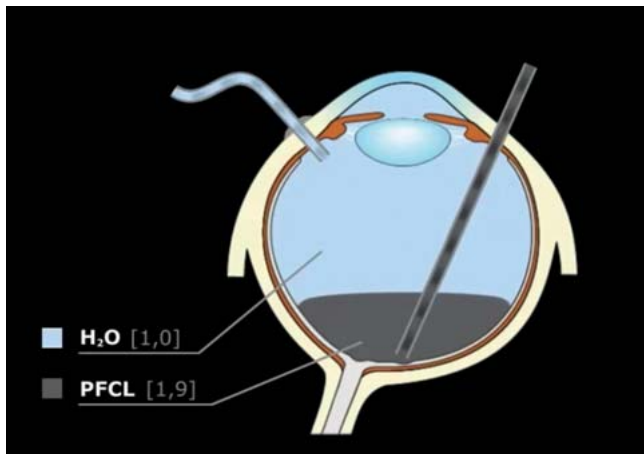
Perfluorocarbon liquid (PFCL) is used intraoperatively as a support to reattach the retina; it is not a long-term tamponade and is primarily used in complex cases. PFCL is often not necessary in cases of simple rhegmatogenous retinal detachment. Vitrectomy requires safe posterior vitreous detachment (PVD) followed by paring back the vitreous body as far into the periphery as possible us-



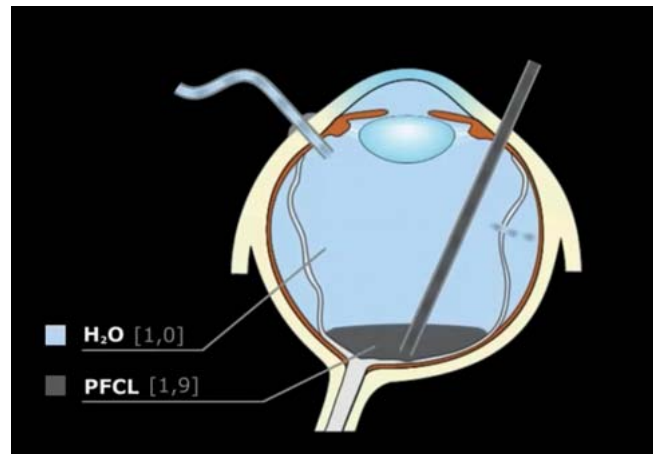
ing a cutter (caution must be exercised in phakic situations or cases of possible lens touch). After hole detection (possibly using peripheral indentation!) and, where appropriate, marking the foramina at the central edge using endodiathermy (better visibility with air!), subretinal drainage (if the position or size of the foramina is adverse, an iatrogenic drainage foramen may also be created using endodiathermy) and successive air filling enable the retina to be reattached mainly free of creases. If there is any remaining subretinal shifting fluid, this is unproblematic as long as there is no crease directly in the fovea area. With gas filling, the fluid will disappear the following day. However, postoperative positioning is especially important with regard to avoiding central retinal folds. Adequate coagulation of the marked foramina can be carried out intraoperatively on the air-filled bulb by means of cryocoagulation or endolaser coagulation, and finally, as outlined above, air can be exchanged for gas. A complex case of PVD can be remedied more easily by demarcating the posterior vitreous membrane through intravitreal injection of triamcinolone.

In complex detachment situations, it would be unimaginable to perform vitreoretinal surgery without PFCL as an intraoperative aid (“3rd hand”); the use of PFCL has sustainably improved surgical results [13]. However, there is a risk that the PFCL will not be completely removed by the end of the surgery and may also get into the subretinal area. The latter is not uncommon when the fovea is affected; it can then be confused with postoperative macular edema, which can lead to misinterpretation and even IVOM therapy [14]. If the bulb is filled with PFCL, manipulating the edges of the foramina with the flute needle should be avoided intraoperatively, as this increases the risk of the PFCL getting into the subretinal area. Likewise, surgeons should prevent the formation of PFCL bubbles at the hole edges which is caused by excessive irrigation flow [8].

Perfluorocarbons were first described and used in an intraocular application by Chang in 1976 [15, 16]. They are colorless and have a higher specific weight than water, which makes them ideal for smoothing out and reattaching the retina as described above (► Fig. 6).



► **Fig. 7** Injection of PFCL into the vitrectomized vitreous cavity with the retina attached. The injection needle is guided through the sclerostomy incision to the posterior pole, PFCL is subsequently injected, avoiding the formation of bubbles where possible (the tip of the needle must remain inside the PFCL bubble) (see ► **Video 3** [Supplementary material C]).



► **Fig. 8** Insertion of PFCL into the vitrectomized vitreous cavity with the retina detached. PFCL is inserted just above the posterior pole and displaces subretinal fluid in the anterior direction via the foramen, which has been adequately dissected in advance (see ► **Video 4** [Supplementary material D]).

## Intraoperative management

Regarding the intraoperative management of PFCL, the following illustrations demonstrate the most important basic rules. In case of an attached retina and a vitrectomized vitreous cavity, the injection needle with PFCL is brought via the upper sclerostomy to the posterior pole and then injected slowly. For this purpose, a double-barreled needle can be used which has a second lumen attached a little higher; this serves to assist in pushing out the displaced water. Luer lock syringes are safe to use, as the double-barreled cannula does not dislodge if the pressure is increased. It is important to keep the tip of the needle inside the PFCL bubble during the injection process, in order to prevent bubble formation and the associated difficult visualization, potentially leading to incomplete removal (► **Fig. 7/Video 3** [Supplementary material C]). In order to protect the macula during surgical extraction, it can be useful to inject PFCL with the retina attached, for example, with lenses that have been luxated into the vitreous body.

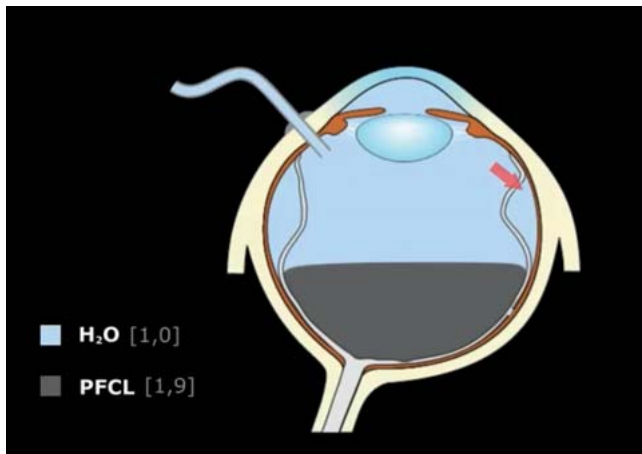
In the case of a detached retina, the foramen edges must be adequately dissected. By injecting PFCL at the posterior pole, the subretinal fluid is displaced in the anterior direction and enters the vitreous cavity via the foramen. This maneuver is often sufficient to reattach the retina, in which case the adjacent foramina can now be easily treated, e.g., with cryocoagulation (► **Fig. 8/Video 4** [Supplementary material D]). Due to the high surface tension, the PFCL droplets usually run across the foramina without difficulty and do not penetrate into the subretinal area.

However, caution must be exercised in cases of very central foramina—whether pre-existing or iatrogenic, for example, when proliferation membranes are removed. In this case, it is possible for PFCL to get into the subretinal area. As filling with PFCL progresses, the lack of relief from vitreal traction at the edge of the hole can result in tearing at the edge of the hole, resulting in a severe retinal tear through which large amounts of PFCL can get into the subretinal area. Irrespective of which endotamponade is later

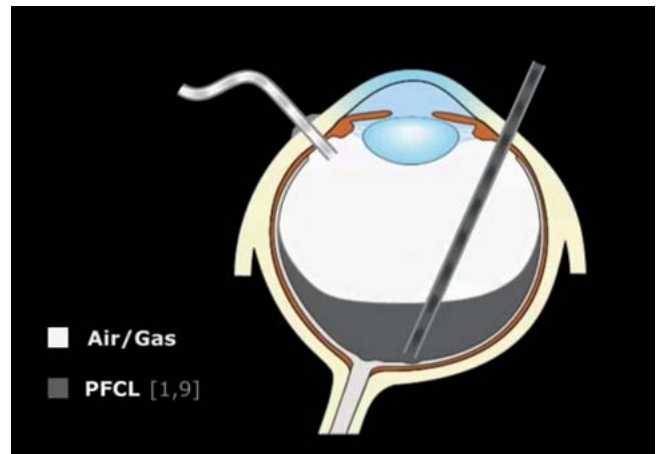
selected as a replacement, the objective is to ensure that the retina is free of traction. If this cannot be achieved due to intraretinal shortening or non-alleviated epiretinal or subretinal traction in PVR, a retinectomy must be performed to provide relief before more PFCL is injected, and before coagulation and safe replacement can be carried out. In any case, the subretinal PFCL must be removed.

## Shifting fluid

In primary rhegmatogenous detachment, depending on the extent of PFCL filling and on the position of the foramen or foramina, so-called “shifting fluid” is generally formed from the subretinal fluid as it moves in an anterior direction. This fluid is, as it were, “trapped” in this subretinal area, because the foramina are covered with the applied PFCL from a certain point onwards, and subretinal fluid can therefore no longer escape. This sometimes results in a persistent, anterior “detachment roll” which can only be removed, for example, by suctioning the subretinal fluid via the retinal defects; this must be performed before coagulation of the retinal foramina can be carried out. Generally, as described above, a small amount of shifting fluid can be left without any problems. While the fluid will flow back to the center during the “PFCL–air” exchange that is usually carried out, it will be completely reabsorbed the following day through the gas tamponade (see above). However, larger amounts should be avoided (possible formation of central retinal fold!); in the case of more centrally located foramina, it may be appropriate to cut another iatrogenic drainage foramen in a more anterior position after partial PFCL filling in order to then remove as much of the remaining subretinal fluid as possible during continued PFCL filling (or air filling) (► **Fig. 9/Video 5** [Supplementary material E]).



► **Fig. 9** Insertion of PFCL into the vitrectomized vitreous cavity with detached retina and a central foramen. After retinal reattachment in the posterior area and accumulation of a large amount of shifting fluid in the anterior area, subretinal fluid can then be successively drained via a peripheral iatrogenic drainage foramen using a flute needle (this can also be done without a flute needle if more PFCL is injected) (see ► **Video 5** [Supplementary material E]).



► **Fig. 10** Air insertion via the infusion port in a PFCL-filled eye. The PFCL can be safely removed from the vitreous cavity by inserting the flute needle as far as the posterior pole (if need be, also using a cutter and active suction in the case of vitrectomy with a trocar system) (see ► **Video 6** [Supplementary material F]).

## Removal of PFCL

After the foramina have been adequately treated with laser and/or cryopexy using PFCL, and the associated reattachment of the retina has been achieved, the PFCL must be removed again. In many cases, surgeons aim for endotamponade with gas at the end of the operation. To attain this objective, PFCL must be exchanged for air in the first step. ► **Fig. 10** illustrates the management of this procedure, in which the flute needle is placed and routed to the posterior pole, and the PFCL is evacuated through the needle by means of the air pressure from the machine (► **Fig. 10/Video 6** [Supplementary material F]). In the case of vitrectomy with a trocar system, in order to expedite the procedure, a cutter with active suction is often used with instruments of smaller diameter; the flute needle is then only used at the posterior pole for precise suctioning of PFCL residues. The challenge with this maneuver is to avoid another retinal detachment, which certainly can eventuate if, for example, there is an excessive amount of water phase between the PFCL phase and the air inserted during the exchange via the infusion port (similar to the water–air exchange described above). As soon as the excess water phase shifts in a posterior direction over the foramen area due to suctioning of the PFCL with the flute needle, detachment can occur; in which case, PFCL filling has to be performed again, and the exchange maneuver has to be repeated.

As already shown in ► **Fig. 6**, PFCL under air can spread over a wide area of the retinal surface, making complete removal complicated. In order to prevent PFCL residues from remaining in the eye, the posterior pole can and should be filled with a small amount of water, e.g., briefly via the infusion port or via a sclerostomy. Of course, the water level must not be higher than the most central foramen. The PFCL can now collect again in the water phase, and the PFCL and water can then be suctioned together (► **Fig. 11/Video 7** [Supplementary material G]). In contrast to

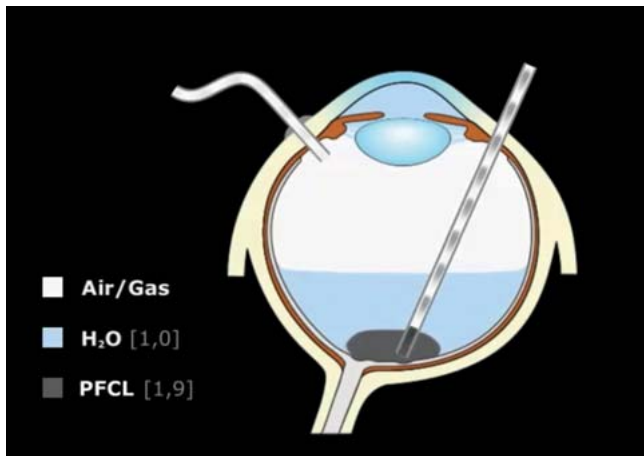
what is depicted in the illustration, PFCL residues are best “maneuvered” in such a way that they are not suctioned from the fovea, but rather from above the optic disk. After this, the desired gas exchange is performed as described above; in this process, longer-acting gas is preferred for inferior foramina.

## Serious complications with air and PFCL

In complex (but traction-free) situations, it is sometimes possible to reattach the retina with air filling (or direct oil insertion; see below) but without PFCL, and to treat the foramina using laser or cryo under air or after silicone oil filling (see below). When treating severe intraocular bleeding, for example, filling the area with air early on can enable visualization of the retinal structures. However, when carrying out a maneuver of this nature with air, surgeons must be cautious when it comes to open eye injuries involving large areas of the choroid, as there have been reported cases of air embolisms with a fatal outcome [17, 18]. We can only speculate as to whether the risk of this complication may be increased through the increased use of vitrectomy with a trocar system as opposed to 20 G vitrectomy with open sclerostomies, which possibly have lower intraocular air pressure.

It must also be mentioned here that, under increased intraocular pressure, larger amounts of PFCL can get into the systemic blood circulation through exposed inner openings of the vorticoses veins, e.g., in trauma surgery or oncological chorioidectomies (endoresection) [19]. Since decalin has lower vapor pressure, this is probably less of a problem than it is with octane, which has a significantly higher vapor pressure and can, due to warming up in the systemic circulation, lead to significant evaporation with air embolism, with fatal consequences [20]. In principle, this problem can be prevented through cauterization and by severing the affected vorticoses veins [21].

Furthermore, there have been reports in recent years of toxic reactions to perfluorocarbons [22], which were all due to contamination during the manufacturing process [23]. Care must there-



► **Fig. 11** Residual PFCL spread over a wide area of the retina surface under air can be removed by injecting water onto the posterior pole (in the center of the foramina!) via an infusion port or sclerotomy; the PFCL can then collect here as a cohesive liquid bubble. This mixed liquid can then be removed more easily with the consecutive supply of air (see ► **Video 7** [Supplementary material G]).

fore be taken to ensure that the liquids are as pure as possible. As a guide for this purpose, a parameter called the H value has been defined; this can be requested from the manufacturer and is a measure of the purity of the substance [24]. Regular, highly purified perfluorocarbons used intraoperatively are not toxic.

## Use of Silicone Oil and Silicone Oil Mixtures in the Surgical Treatment of Retinal Detachment

### General information on silicone oil tamponades

Silicone oil (polydimethylsiloxane) was first used in an intraocular application in the early 1960s—well before regular vitrectomy was possible [25]. In their pioneering work from 1971, Scott and Zivojnović succeeded in combining the application of silicone oil with vitrectomy, making it possible, in particular, to treat severe eye injuries and/or retinal detachments [26,27]. Szurman and Bartz-Schmidt have published a highly detailed article on classic silicone oils in vitreoretinal surgery [28]. ► **Fig. 12** shows the characteristics of the silicone oils, also compared to PFCLs (► **Fig. 12**); [29,30].

The characteristics of the partially fluorinated PFCLs are interesting as they have a lower density than the classic PFCLs and are used as components of silicone oil mixtures in order to make the silicone oil heavier (silicone oil has an actual specific weight of  $0.97 \text{ g/cm}^3$ ); this makes it possible, in particular, to better treat inferior PVR detachments [31].

When using a silicone oil tamponade, the problem is that even with the complete tamponade that is usually desired, a crescent of water always remains in the lower area, in which promoter substances for PVR formation accumulate [32]. This is the reason why PVR redetachment commonly develops downwards, and this, in addition to pronounced peeling of epiretinal membranes, often

### Characteristics of PFCL, Silicone Oil and Mixtures

	Spec. weight [g/cm <sup>3</sup> ]	Viscosity [mPas·s]	Interfacial tension water [mN/m]	Spreading on retinal surface under air
<b>Perfluorocarbons</b>				
Octane	1,78	1,4	55	++
Dekalin	1,92	5,53	53	++
<b>Part. fluor. PFCL (FALK)</b>				
F <sub>6</sub> H <sub>8</sub>	1,35	2,5	49	+
<b>Polydimethylsiloxane (Sili)</b>	<b>0,97</b>	<b>1000</b> <b>5000</b>	<b>45</b>	<b>-</b>
<b>Heavy Silicone Oil (Sili-FALK mixtures)</b>				
Densiron (30% Alkan)	1,06	1400		-
Oxane Hd (10% Alkan)	1,03	3300	41	-

► **Fig. 12** Characteristics of silicone oil and so-called “heavy silicone oil” as a mixture of oils with partially fluorinated perfluorocarbons (adapted from [8, 29, 30]).

has to be treated in follow-up operations by means of inferior retinectomy. The hope was, therefore, that this problem could be solved using the so-called heavy silicone oils. The heyday of heavy silicone oil use was around 2002 and subsequent years. However, our own evaluations of a larger clinical cohort of PVR detachment patients who underwent treatment at the Eye Clinic of the University Hospital of Regensburg did not show an improved reattachment rate compared to study results for “conventional” surgery, which mostly consisted of vitrectomy, cerclage, retinectomy, and regular oil filling [33]. The multicentric, prospective HSO study also did not find an advantage with heavy oils compared to the use of conventional oils [34]; similarly, a US meta-analysis did not recognize any advantage, resulting in heavy oils not being approved in the USA [35]. Moreover, heavy oils are also said to be associated with a higher potential for intraocular inflammation [36].

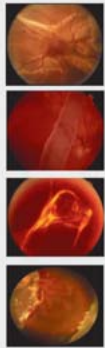
As a consequence, only regular light silicone oils are generally used today. A high viscosity of 5,000 mPas is preferred, as this has a lower tendency to emulsify, which—depending on the duration of the tamponade—can ultimately lead to secondary glaucoma [37]. In vitrectomy with a trocar system, however, low-viscosity silicone oils are used, because they are presumably easier to inject through the smaller-volume instruments. But even 5,000 mPas silicone oil can be injected relatively easily through 25 G trocars using a machine with lower pump pressures, although a sclerotomy hole must be made in order to remove it.

### Indications for silicone oil filling

► **Fig. 13** shows a detailed list of some of the areas of application in which silicone oil is used. According to this, all PVR-C stages and retinectomies are treated with silicone oil filling, as are traction detachments, especially when the traction cannot be adequately relieved. A classic indication for silicone oil is giant retinal tear (retinal tear extending over at least three clock positions), since the use of gas significantly increases the risk of detachment and PVR. It should be mentioned here that there is also an increased risk of detachment in the other eye; consequently, prophylactic la-



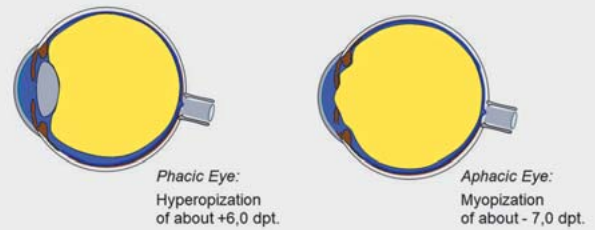
## Application of Silicone Oil



- PVR – retinal detachment stage C
- Giant tear retinal detachment
- Tractional retinal detachment
- Retinectomies

► **Fig. 13** Indications for the use of silicone oils in retinal detachment surgery.

## Silicone Oil Tamponade



Silicone Oil is held in the posterior segment by an intact iris-lens-diaphragm

With phacodonesis / zonulolysis: risk of prolapse

► **Fig. 14** Change in refraction due to silicone oil filling in phakic and aphakic eyes.

ser cerclage may be considered during the treatment course [38]. Silicone oil can also be used in the following areas of application: for trauma surgery, in complicated hole configurations, when rapid restoration of vision is required in patients who only have one eye remaining and are unable to position themselves, in repeated surgery in the case of macular holes that are not closed ( $C_2F_6$  or  $C_3F_8$  can also be used here), in the treatment of subretinal mass bleeding (for example, in case of neovascular AMD), and in the treatment of bulbar hypotonia of various etiologies.

### Effects of a silicone oil tamponade in the eye/ Ando iridectomy in aphakic cases

A silicone oil tamponade has significant effects on the eye, and both the surgeon and physician providing follow-up care should be aware of this. Generally, the silicone oil is kept in the posterior segment by means of an intact iris-lens diaphragm (► **Fig. 14**). In a phakic situation, the patient should be informed that this leads to hyperopic magnification of about 5–6 dpt. If the iris-lens diaphragm is not intact, due for example to zonulolysis after trauma or after complicated cataract surgery (sulcus implantation, scleral-fixated intraocular lens [IOL], or iris clip lens), silicone oil can pass into the anterior chamber and can lead to corneal decompensation if it is in contact with the corneal endothelium for a prolonged period. This should be avoided where possible. If it does occur, the silicone oil must be removed quickly, at least from the anterior chamber. However, if the intraocular pressure is not too high, it is possible to wait for a short while (a matter of weeks)–even if the anterior chamber is completely full–until the retina has stabilized to such an extent that surgeons can attempt the complete removal of the silicone oil. If it is not possible to avoid using a silicone oil tamponade for a longer period of time, the intraocular lens including the capsular sac (aphakia) must be removed, and an inferior Ando iridectomy must be performed at the 6 o'clock position [39]. This must be done in order to prevent a silicone oil prolapse in an aphakic situation, which carries with it a risk of a pupillary block (► **Fig. 15**). The purpose of the inferior Ando iridectomy at the 6 o'clock position is to get the intraocular

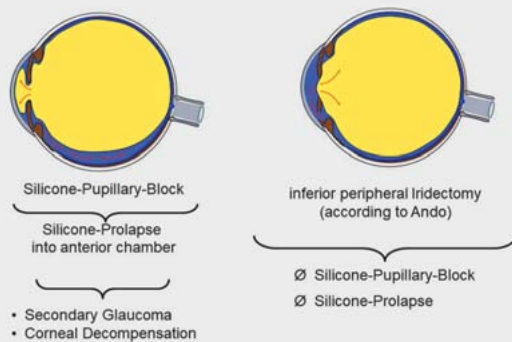
fluid, whose transpupillary route is blocked by the silicone oil, into the anterior chamber via this “bypass”, and thus to keep the oil behind the pupillary plane. Some surgeons perform two additional peripheral iridectomies, in nasal and temporal positions, with the aim of maintaining the flow of intraocular fluid even in a lateral recumbent position. However, if bulbar hypotonia occurs as a result of ciliary body dysfunction, even an open Ando iridectomy cannot keep the silicone oil behind the pupillary plane. This leads to very difficult and complex situations in which the silicone oil is only left as a prophylaxis against phthisis, with keratopathy often accepted as a trade-off. An oil-filled aphakic eye can generally result in a significant myopization of up to about –7 dpt (► **Fig. 14**).

Regarding the postoperative changes in refraction after silicone oil filling, which are sometimes considerable, the complications of anisometropia and aniseikonia must be taken into account and the patient must be informed accordingly, especially if the patient's vision is still good. If necessary, a contact lens can be used to compensate while the oil tamponade remains in the eye, or else the oil must be removed early; this can be done after about six weeks, since all the necessary scarring on the retina should be assured at this point. In straightforward cases, the silicone oil can be removed at a later stage.

### Loss of visual acuity due to silicone oil

An important point to note when using silicone oil tamponades is the small but still nevertheless real risk of irreversible loss of visual acuity, the causes of which are still unclear [40]. This risk should not be ignored, especially in cases of a primary “macula-on-situation” and if the patient has relatively good initial visual acuity. If the retinal conditions are stable, the silicone oil should be removed promptly. However, if the patient's vision is still good with the silicone oil in place, removal of the silicone oil can lead to a corresponding loss of visual acuity. This is why the indication for silicone oil should be considered carefully in all cases, but especially in patients with a potentially high level of visual acuity. The patient should be informed of this.

## Silicon Oil Tamponade in the aphakic Eye



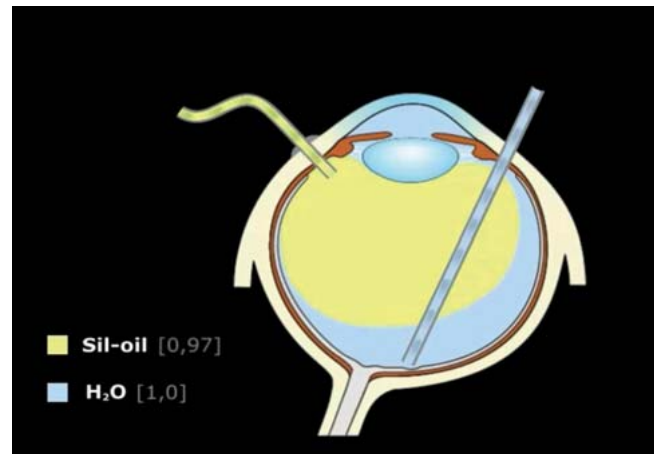
► **Fig. 15** Problems with silicone oil filling in an aphakic eye, and the need for Ando iridectomy at the 6 o'clock position.

## Surgical procedure for silicone oil filling

The following supplementary materials illustrate the use of silicone oil in vitrectomy. The infusion port is used for the simple oil filling of the water-filled eye. The oil syringe is connected to the 3-way valve (► **Fig. 1**), which is then switched from water infusion to oil instillation. State-of-the-art machines used today can pump the oil into the eye at variable speeds. Of course—as explained above with the previous techniques—the flute needle must be placed inside the water phase in order to be able to suction the remaining water directly at the posterior pole towards the end of the oil filling procedure, thereby ensuring that the oil filling is as complete as possible (► **Fig. 16/Video 8 [Supplementary material H]**). A water–oil exchange of this nature would be conceivable, for example, in the treatment of hypotonia syndrome, in the context of severe proliferative retinopathy with attached retina, for treatment with a choroidal patch, or in cases of severe eye bulb trauma. In situations of detachment, the retina must first be placed under PFCL or air for logical reasons, as described above. The simpler procedure as shown in ► **Fig. 16** is only rarely required in everyday clinical practice, but it illustrates the basic principle of oil injection.

As in ► **Fig. 16**, a direct oil–PFCL exchange can also be performed by infusing silicone oil into the PFCL-filled bulb via the infusion port and leaving the flute needle in place in the PFCL phase until complete exchange has occurred (► **Fig. 17/Video 9 [Supplementary material I]**). In the vitrectomy procedures carried out thus far, we have regularly discussed how large the water phase between silicone oil and PFCL could or should be—as shown in this figure and animation. Generally speaking, it is possible for PFCL to mix with oil at the interface. This should be prevented. On the other hand, as already described above, detachment can occur during exchange if the water phase is too large and this water then flows beneath the retina into the area of the foramina that has not yet healed.

It makes sense to keep the water phase as small as possible so that the oil can be inserted via the infusion port in the context of 20 G vitrectomy, which is often performed in such situations. The

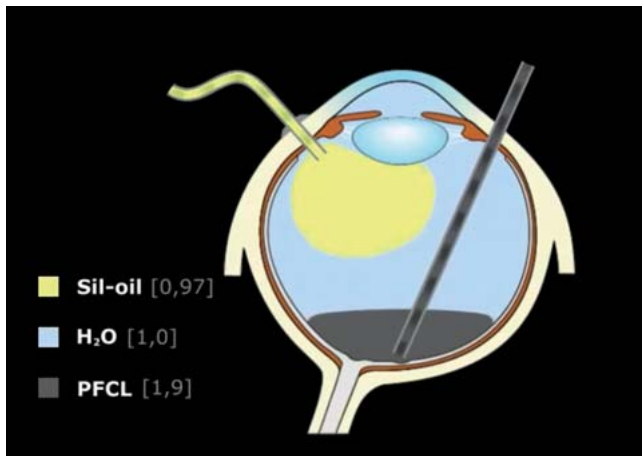


► **Fig. 16** Silicone oil is pushed into the vitreous cavity by the machine via the infusion port. The oil weighs less than water, so it moves from the top to the bottom, and pushes water to the outside via the flute needle positioned at the posterior pole (see ► **Video 8 [Supplementary material H]**).

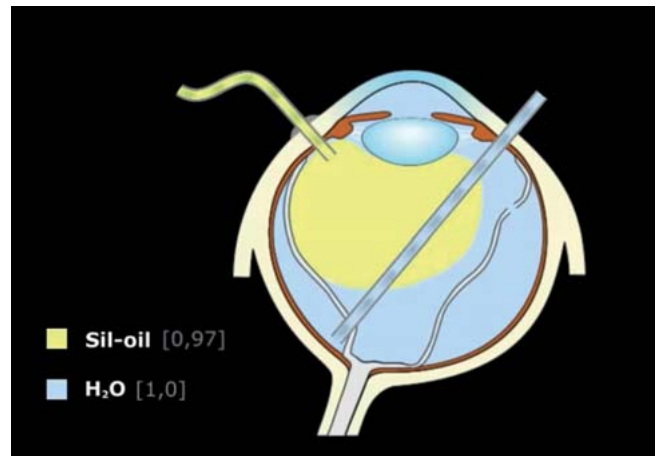
oil displaces the water that is above the PFCL in the anterior area via the sclerostomy opening. The surgeon has the choice of either leaving a sclerostomy hole open (the light guide is placed in the other hole!) or positioning the flute needle in the water phase in the meantime. As soon as the water has been completely displaced, intraocular pressure will increase, which will be recognizable through the central artery beginning to pulse. At this moment at the latest, the flute needle must be immersed in the PFCL phase and the exchange can now take place with further injection of silicone oil, if the pressure conditions are normal. Towards the end, the PFCL level can usually be seen relatively easily under the oil, so that—in the ideal case—residual PFCL can be carefully “suctioned” above the optic disk. Of course, “suction” is not strictly speaking the correct term here, since the PFCL is displaced passively due to the oil pressure. Since the tubes that carry the silicone oil are elastic, it is imperative to inject carefully towards the end of the procedure, as the oil continues to “drip out” and the central retina can accidentally be suctioned into the opening of the flute needle—an incredibly tricky situation that must be avoided at all costs. It may be necessary to insert the flute needle several times so as to remove all the PFCL residue. However, in between the flute needle insertions the needle should be actively rinsed, as the opening can become clogged with the oil, which would prevent any further exchange from taking place.

These days, an indirect exchange of PFCL for silicone oil via the intermediate step of air filling (see above) is carried out more commonly, as it is much easier. However, in more complex cases, there is a higher risk of slippage of subretinal fluid, which should be avoided.

The advantage of an indirect exchange is that the silicone oil can be inserted into the completely air-filled bulb relatively easily, ideally with an attached retina, via the working sclerostomy hole “from the bottom upwards”. As a rule, this is done depending on the degree of oil filling during the injection with successive reduction of the intraocular air pressure by the machine. During the fill-



► **Fig. 17** As in ► **Fig. 16**, a direct oil–PFCL exchange can be performed by infusing silicone oil via the infusion port and leaving the flute needle in place in the PFCL phase until complete exchange has occurred (see ► **Video 9 [Supplementary material I]**). As discussed in the text, contrary to what is shown in the illustration, the water phase should be kept as small as possible.



► **Fig. 18** Direct insertion of oil via the infusion port in the case of a detached retina and drainage of subretinal fluid using a flute needle via the central foramina (rather unfavorable but possible situation in challenging PVR detachments or complex trauma cases; see ► **Video 10 [Supplementary material J]**).

ing process, the air is displaced upwards via the sclerostomy hole, and the residual air bubble can be easily removed towards the end of the operation via the second sclerostomy hole using the flute needle. Since the infusion port is only delivering air during this process, you will be able to see the oil entering the infusion port towards the end (the air pressure on the machine should then be “zero” and/or the 3-way valve for air supply should be closed), which reliably indicates that the posterior segment of the eye is completely filled with oil.

### Intraoperative problems with silicone oil filling

Since the introduction of PFCL, the direct exchange of water for silicone oil has become rare. As already indicated above, however, there may be situations in which intraocular reattachment of the retina using PFCL or air cannot be achieved, e.g., in the case of very central and large foramina and traction detachments, or in complex trauma situations. In such cases, after the traction has been relieved as much as possible, it is possible to carry out direct oil filling via the infusion port and direct drainage of subretinal fluid through the central foramina using a flute needle (► **Fig. 18/Video 10 [Supplementary material J]**). Even though this procedure is not ideal and involves a high risk of PVR re-detachment, in some cases it can stabilize an initially complex situation to the extent that surgeons have the time to carefully plan a revision operation.

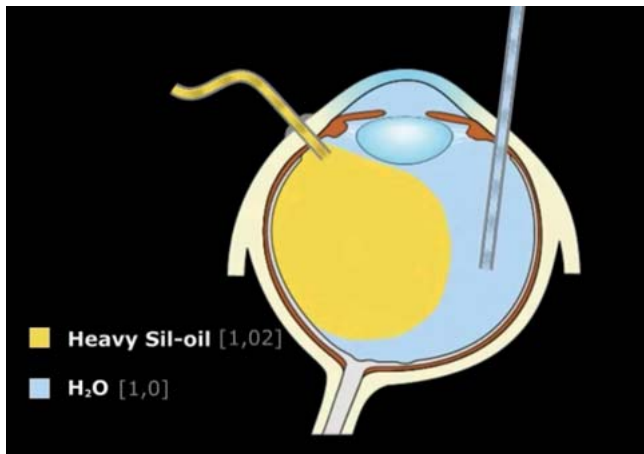
In cases of direct PFCL–silicone oil exchange, it also becomes more difficult if the retina, which was previously attached under PFCL, becomes detached again during oil filling. In that case, if necessary, an iatrogenic retinotomy at a suitable point, with subsequent subretinal drainage under silicone oil, can help to remove residual subretinal fluid. In even more complex cases, it may be necessary to completely remove the oil again and, for example, repeat the procedure with a more extensive retinectomy. A new

infusion port is required in such cases, since the first port will be clogged with oil, usually preventing further water infusion.

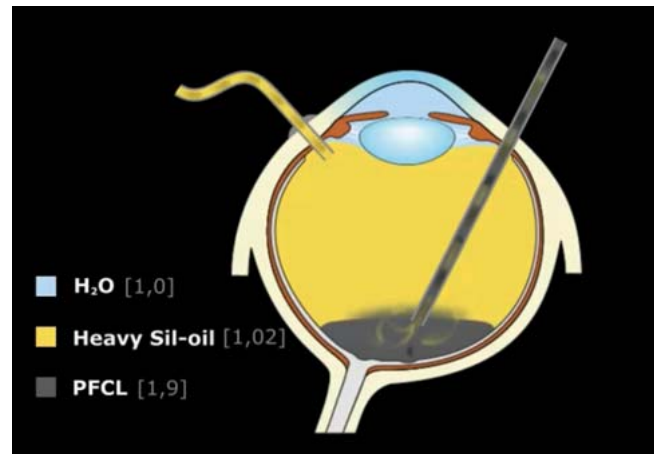
As already mentioned above, if oil filling is required in an aphakic situation, this can lead to an intraoperative block of the iridocorneal angle due to the oil pressure. Therefore, before filling the eye with oil, the anterior chamber can be “positioned” using a viscoelastic fluid in order to keep the iridocorneal angle anatomically open, and thus avoid a pupillary block in the supine position caused by the silicone oil pressing from behind. Alternatively, the entire eye, including the anterior chamber, can be filled with oil (the iridocorneal angle must then be coated with oil) if the eye is left with very low intraocular pressure at the end of the operation (Schiotz tonometry may help here). Due to the low pressure (caution: risk of secondary bleeding!), volume has practically been created in advance, so that the anterior chamber can refill itself with water after the operation and when the patient is lying on their stomach, and the oil can flow from the anterior chamber into the posterior segment—in the case of normotension. Another option would be to constrict the pupil using intracameral acetylcholine before inserting oil, while leaving water or air in the anterior chamber. The prerequisite for these measures is an open Ando iridectomy; it must be ensured that the iridectomy is definitely passable and that there are no longer any capsule components in the lower area. Postoperatively, patients should be placed in a prone position, with subsequent pressure monitoring carried out on the ward. If the pressure increases when intracameral viscoelastic fluid is used, this can be drained relatively easily postoperatively to relieve pressure via paracentesis with the slit lamp.

### Removal of silicone oil

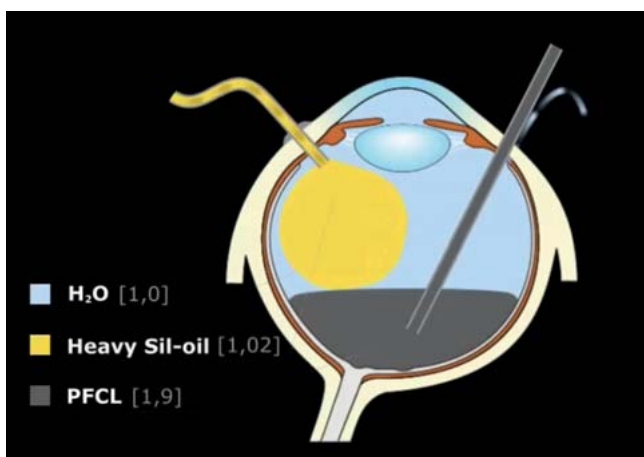
Silicone oil that has been inserted into the eye should generally be removed again if the retinal situation is stable—unless the prognosis for visual acuity is poor or the retinal findings are correspondingly poor, making removal impossible. In cases of persistent bul-



► **Fig. 19** Insertion of heavy silicone oil into water: in the middle of the filling process the oil tends to displace the lower part of the water, so that the flute needle has to “suction” the residual water in the anterior segment of the eye towards the end of the procedure (see ► **Video 11** [Supplementary material K]).



► **Fig. 21** Insertion of heavy silicone oil on PFCL. After water displacement, due to the similar properties of PFCL and the partially fluorinated oils, these oils can mix at the interface, resulting in a higher risk of corresponding residues of both mixed agents (see ► **Video 12** [Supplementary material L]).



► **Fig. 20** Insertion of heavy silicone oil on PFCL. After displacement of the water (which can also be done without a flute needle), PFCL is finally displaced via the flute needle (see ► **Video 12** [Supplementary material L]).

bar hypotonia or phtisis, the silicone oil should be left as a permanent tamponade. Leaving the silicone oil in place can also be useful in the case of redetachment after multiple operations. Some rare cases of inferior peripheral detachment can also remain permanently stable under silicone oil, so that no further operations are required. However, as already mentioned, if silicone oil remains in the eye for a long period of time, e.g., for years, this can result in oil emulsification of varying degrees and secondary glaucoma.

Surgical oil removal is traditionally performed by means of 3-port vitrectomy in which, after the sclerostomy hole has been created at the top, the oil is then suctioned, either by the machine or with active manual suction, ideally with a large-volume Vigo

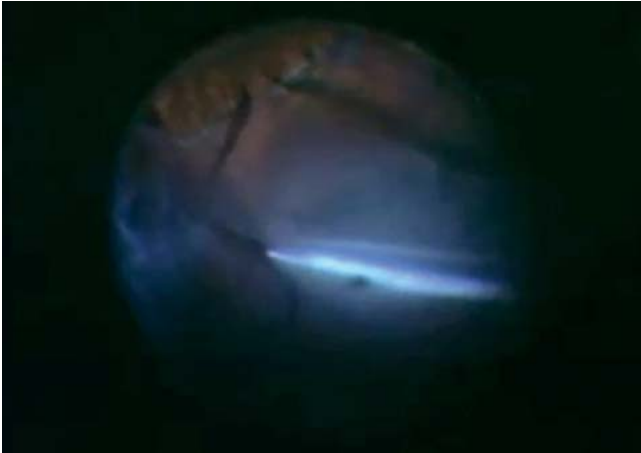cannula, for example. Depending on the infusion pressure, “turbulence” can occur in the vitreous cavity during this maneuver, which means that the oil bubbles, displaced to a deeper position by the water inflow, are slow to move upwards. Additionally, the infusion port immersed in the silicone oil can be blocked at the beginning of the operation, so that the machine has to significantly increase the intraocular pressure for a short time in order to clear the opening. After successful oil removal, a vitrectomy should always be performed again so as to remove any peripheral vitreous residues (which are more often present in the anterior position if a cataract is removed at the same time during the oil removal). The surgeon should also check whether the retina is securely attached, and finally—as mentioned above—the remaining oil bubbles should safely be removed by exchanging water and air about three times. We warn against skipping the vitrectomy step and merely “draining” the oil, as this will not allow for potentially relevant problems to be identified.

### Heavy silicone oil

Based on the author’s own experiences and the study results presented (see above), the authors of this manuscript no longer see a need to use heavy silicone oil. However, since it is still available, it is probably also still used, and removal of heavy silicone oil will at least still need to be carried out; accordingly, we give a brief outline of the procedure with heavy silicone oil.

In principle, insertion of heavy silicone oil works in a similar way to what has already been shown in ► **Fig. 16**. However, since the liquid is heavier than water, the oil mass moves downwards much faster in water; this means that the flute needle has to be pulled upwards throughout the entire filling process, since the residual volume of water is primarily in the upper area towards the end of the procedure (► **Fig. 19/Video 11** [Supplementary material K]).

► **Fig. 20** and **21** show the procedure for inserting heavy silicone oil on PFCL. Here, too, as already discussed for ► **Fig. 17**, the water above the PFCL phase must first be displaced during



► **Fig. 22** Removal of heavy oil from the posterior pole. The oil residues can stick to the surface of the retina as “sticky oil”, which in some cases can hardly be removed. The flute needle must be long enough to work close to the posterior pole (see ► **Video 13** [Supplementary material M]).

the exchange; this can be done with or without an inserted flute needle (► **Fig. 20/Video 12** [Supplementary material L]). However, as soon as the water has been displaced, the PFCL is displaced further via the flute cannula; because of the similar properties of the two substances (high proportion of partially fluorinated PFCL in heavy silicone oil; ► **Fig. 12**), this brings a risk of them mixing together due to the turbulence in the area of the suction cannula, resulting in the corresponding residues remaining in the eye with changed properties (► **Fig. 21/Video 12** [Supplementary material L]).

The result is that heavy silicone oil is more difficult to remove than regular silicone oil for two reasons: firstly, it requires a long suction cannula, ideally reaching the posterior pole, with the attendant risk of applying strong suction close to the retina; secondly, the unfortunate situation sometimes arises of “sticky oil” on the retinal surface; this makes it very difficult to remove the oil in its entirety, without iatrogenic damage close to the retinal surface (► **Fig. 22/Video 13** [Supplementary material M]). If this does occur, Kirchoff recommends inserting PFCL at the posterior pole, which should make the distance easier due to the mix of substances [31].

## Conclusion

The aim of this manuscript was to convey basic knowledge in the field of vitrectomy-based retinal detachment surgery, as well as other pathologies, with a special focus on the handling of the intraocular tamponades that are available. This work in no way claims to be complete; neither does it claim to correctly present the special advice of all surgeons. Learning how to perform a vitrectomy, especially for retinal detachment, is less standardized than, for example, learning about traditional cataract surgery; also, the surgical procedure is less predictable and can vary considerably. The individual approach and individual preferences of different surgeons vary according to which “school” of retinal

and vitreous surgery they learned from. The basics presented here correspond to the specifications of our esteemed teacher, Prof. Dr. V.-P. Gabel, Munich and Regensburg (for HGS and CF), who has worked in the field of vitrectomy since the beginning of the 1970s, and who created the animations, inserted as supplementary online material, displaying the still valid principles of vitrectomy. Animations have been inserted as supplementary online material. The co-authors of the “erweiterte Essener Vitrektomie-Schule”, as students of Michael H. Foerster (JW, NEB) and Horst Laqua (HH), have also been involved in the models and in discussions over the past decades with V.-P. Gabel. This manuscript is dedicated to him.

## Supplementary Material

The correspondingly marked figures are mainly provided with video animations, which are intended to illustrate the described operative procedure once again, thus allowing the best possible learning effect to be achieved.

## Acknowledgements

The authors warmly thank Dr. I. Volkmann, Hanover, for the final preparation of the supplementary video material for this article.

## Conflict of Interest

The authors declare that they have no conflict of interest.

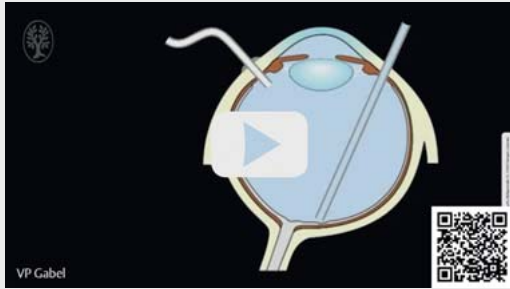
## References

- [1] Faude F, Meier P, Wiedmann P. Eindellende Operationen bei rhegmatogener Amotio retinae. *Ophthalmologie* 2002; 90: 308–323
- [2] Hoerauf H, Heimann H, Hansen L et al. Skleraeindellende Ablatiochirurgie und pneumatische Retinopexie. Techniken, Indikationen und Ergebnisse. *Ophthalmologie* 2008; 105: 7–18
- [3] Radeck V, Helbig H, Barth T et al. Ablatiochirurgie: Trends über 15 Jahre. *Ophthalmologie* 2022; 119 (Suppl. 1): S64–S70. doi:10.1007/s00347-021-01430-4
- [4] Nishitsuka K, Kawasaki R, Yamakiri K et al.; Japan Retinal Detachment Registry Group. Preoperative factors to select vitrectomy or scleral buckling for retinal detachment in microincision vitrectomy era. *Graefes Arch Clin Exp Ophthalmol* 2020; 258: 1871–1880. doi:10.1007/s00417-020-04744-2
- [5] Walter P, Hellmich M, Baumgarten S et al.; VIPER Study Group. Vitrectomy with and without encircling band for pseudophakic retinal detachment: VIPER Study Report No 2 – main results. *Br J Ophthalmol* 2017; 101: 712–718. doi:10.1136/bjophthalmol-2016-309240
- [6] Faude F, Wiedemann P. Intraokulare Gase in der Glaskörper- und Netzhautchirurgie. Teil I: Grundlagen. *Ophthalmologie* 1999; 96: 349–358
- [7] Faude F, Wiedemann P. Intraokulare Gase in der Glaskörper- und Netzhautchirurgie. Teil II: Klinik. *Ophthalmologie* 1999; 96: 413–420
- [8] Faude F, Wolf S, Wiedemann P. Flüssige Perfluorkarbone in der Glaskörper- und Netzhautchirurgie. *Ophthalmologie* 2000; 97: 652–661
- [9] Chang S. Intraocular Gases. In: Ryan SJ, ed. *Retina*. 2nd ed.; St. Louis: Mosby-Year Book; 1989: 2115–2129
- [10] Pastor JC, Rojas J, Pastor-Idoate S et al. Proliferative vitreoretinopathy: A new concept of disease pathogenesis and practical consequences. *Prog Retin Eye Res* 2016; 51: 125–155. doi:10.1016/j.preteyeres.2015.07.005

- [11] Hecht I, Mimouni M, Blumenthal EZ et al. Sulfur Hexafluoride (SF<sub>6</sub>) versus Perfluoropropane (C<sub>3</sub>F<sub>8</sub>) in the Intraoperative Management of Macular Holes: A Systematic Review and Meta-Analysis. *J Ophthalmol* 2019; 2019: 1820850. doi:10.1155/2019/1820850
- [12] Hillenkamp J, Surguch V, Framme C et al. Management of submacular hemorrhage with intravitreal versus subretinal injection of recombinant tissue plasminogen activator. *Graefes Arch Clin Exp Ophthalmol* 2010; 248: 5–11. doi:10.1007/s00417-009-1158-7
- [13] Feltgen N, Hoerauf H. Aktueller Stellenwert von schweren Flüssigkeiten als intraoperatives Hilfsmittel bei vitreoretinalen Eingriffen. *Ophthalmologie* 2019; 116: 919–924
- [14] Framme C, Junker B, Feltgen N et al. Indikationen bei Intravitrealer Injektionstherapie mit Anti-VEGF für Makulaerkrankungen – Fehler vermeiden. *Ophthalmologie* 2022; 119: 309–326. doi:10.1007/s00347-021-01553-8
- [15] Chang S. Low viscosity liquid fluorochemicals in vitreous surgery. *Am J Ophthalmol* 1987; 103: 38–43
- [16] Chang S, Zimmerman NJ, Iwamoto T et al. Experimental vitreous replacement with perfluorotributylamine. *Am J Ophthalmol* 1987; 103: 29–37
- [17] Gamulescu MA, Helbig H, Bartz-Schmidt UK. Luftembolie bei Vitrektomie? *Klin Monbl Augenheilkd* 2010; 227: 185–186. doi:10.1055/s-0028-1109959
- [18] Morris RE, Sapp MR, Oltmanns MH et al. Presumed air by vitrectomy embolisation (PAVE) a potentially fatal syndrome. *Br J Ophthalmol* 2014; 98: 765–768. doi:10.1136/bjophthalmol-2013-303367
- [19] Jousseaume AM, Wong D. Egress of large quantities of heavy liquids from exposed choroid: a route for possible tumor dissemination via vortex veins in endoresection of choroidal melanoma. *Graefes Arch Clin Exp Ophthalmol* 2015; 253: 177–178
- [20] Fiorentzis M, Bechrakis NE. Vortex vein cauterization and truncation to avoid perfluorocarbon syndrome during endoresection of uveal melanomas: a retrospective study. *Eye (Lond)* 2022. doi:10.1038/s41433-022-02119-x
- [21] Rojanaporn D, Tipsuriyaporn B, Chulalaksiriboon P et al. Fatal Air Embolism after Choroidal Melanoma Endoresection without Air Infusion: A Case Report. *Ocul Oncol Pathol* 2021; 7: 321–325
- [22] Pastor JC, Coco RM, Fernandez-Bueno I et al. Acute Retinal Damage after Using a Toxic Perfluoro-Octane for Vitreo-Retinal Surgery. *Retina* 2017; 37: 1140–1151
- [23] Menz DH, Feltgen N, Lechner T et al. Hydrofluoric Acid and Other Impurities in Toxic Perfluorooctane Batches. *Transl Vis Sci Technol* 2019; 8: 24. doi:10.1167/tvst.8.3.24
- [24] Menz DH, Feltgen N, Menz H et al. How to Ward Off Retinal Toxicity of Perfluorooctane and Other Perfluorocarbon Liquids? *Invest Ophthalmol Vis Sci* 2018; 59: 4841–4846
- [25] Cibis PA, Becker B, Okun E et al. The use of liquid silicone in retinal detachment surgery. *Arch Ophthalmol* 1962; 68: 590–599
- [26] Scott JD. A rationale for the use of liquid silicone. *Trans Ophthalmol Soc UK* (1962) 1977; 97: 235–237
- [27] Zivojnović R, Mertens DA, Baarsma GS. Das flüssige Silikon in der Amiotichirurgie. Bericht über 90 Fälle. *Klin Monbl Augenheilkd* 1981; 179: 17–22
- [28] Szurman P, Bartz-Schmidt KU. Silikonöl in der Netzhautchirurgie. *Ophthalmologie* 2000; 97: 514–525. doi:10.1007/s003470070085
- [29] Bausch + Lomb. Oxane®-Silikonöle. Accessed January 5, 2022 at: <https://www.bausch-lomb.de/fachbereich/augenchirurgen/vitreoretinale-tamponaden/oxaner/>
- [30] Fluron®. Densiron® 68. Die bewährte „Schwerer-als-Wasser“-Silikonöltamponade. Accessed January 5, 2022 at: [https://www.fluoron.de/produkte\\_loesungen/langzeit-tamponaden/densiron-68/](https://www.fluoron.de/produkte_loesungen/langzeit-tamponaden/densiron-68/)
- [31] Kirshof B. Vor- und Nachteile des schweren Silikonöls. *Ophthalmologie* 2010; 107: 566, 568–570. doi:10.1007/s00347-010-2215-7
- [32] Jousseaume AM, Kirshof B, Schrage N et al.; HSO Study Group. Heavy silicone oil versus standard silicone oil as vitreous tamponade in inferior PVR (HSO Study): design issues and implications. *Acta Ophthalmol Scand* 2007; 85: 623–630. doi:10.1111/j.1600-0420.2007.00898.x
- [33] Regler R, Sachs HG, Hillenkamp J et al. Long-term evaluation of anatomic and functional results after complicated retinal detachment treated with pars plana vitrectomy and heavy silicone oil tamponade. *Klin Monbl Augenheilkd* 2009; 226: 707–712. doi:10.1055/s-0028-1109685
- [34] Jousseaume AM, Rizzo S, Kirshof B et al.; HSO Study Group. Heavy silicone oil versus standard silicone oil in as vitreous tamponade in inferior PVR (HSO Study): interim analysis. *Acta Ophthalmol* 2011; 89: e483–e489. doi:10.1111/j.1755-3768.2011.02139.x
- [35] Schwartz SG, Flynn HW jr., Lee WH et al. Tamponade in surgery for retinal detachment associated with proliferative vitreoretinopathy. *Cochrane Database Syst Rev* 2014; (2): CD006126. doi:10.1002/14651858.CD006126.pub3
- [36] Morescalchi F, Costagliola C, Duse S et al. Heavy silicone oil and intraocular inflammation. *Biomed Res Int* 2014; 2014: 574825. doi:10.1155/2014/574825
- [37] Lucke K, Strobel B, Foerster M et al. Sekundärglaukome nach Silikonölschirurgie. *Klin Monbl Augenheilkd* 1990; 196: 205–209. doi:10.1055/s-2008-1046155
- [38] Framme C, Hoerauf H, Wachtlin J et al. Retinale Lasertherapie – Fehler vermeiden. *Ophthalmologie* 2020; 117: 169–188. doi:10.1007/s00347-019-01035-y
- [39] Beekhuis WH, Ando F, Zivojnović R et al. Basal iridectomy at 6 o'clock in the aphakic eye treated with silicone oil: prevention of keratopathy and secondary glaucoma. *Br J Ophthalmol* 1987; 71: 197–200. doi:10.1136/bjo.71.3.197
- [40] Lappas A, Dietlein TS, Rosentreter A et al. Visusverlust nach Silikonölschirurgie. *Klin Monbl Augenheilkd* 2018; 235: 725–729. doi:10.1055/s-0042-120281

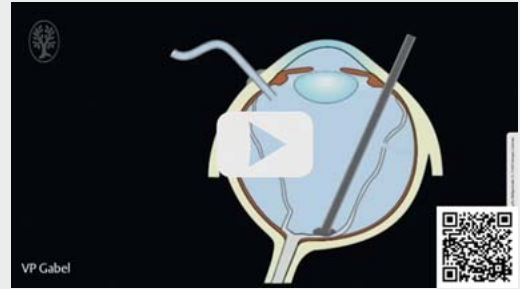## Supplementary Material

▶ VIDEO



▶ **Video 1** Supplementary material A.

▶ VIDEO



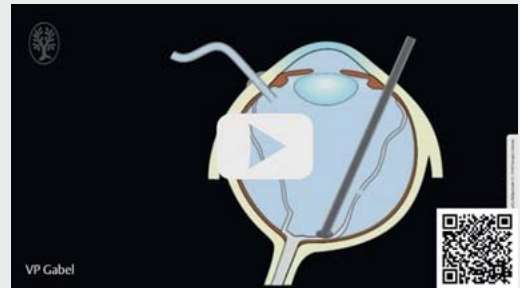▶ **Video 4** Supplementary material D.

▶ VIDEO



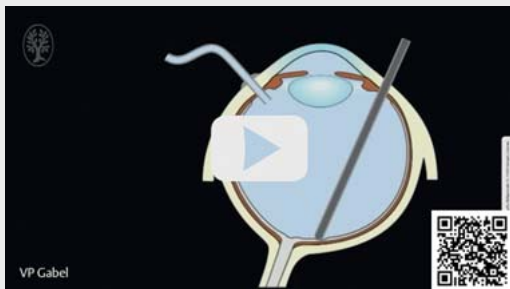▶ **Video 2** Supplementary material B.

▶ VIDEO



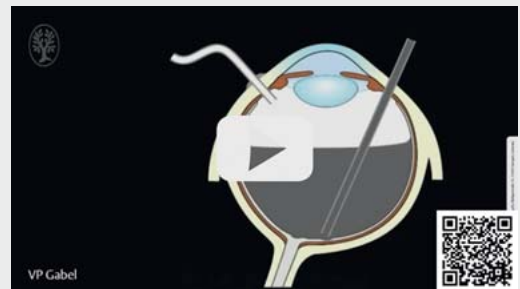▶ **Video 5** Supplementary material E.

▶ VIDEO



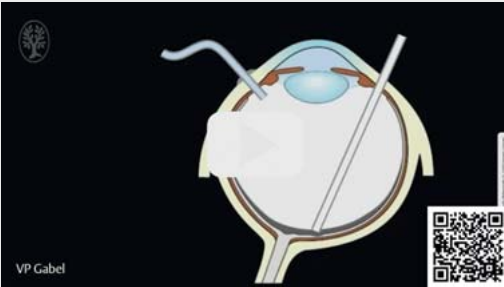▶ **Video 3** Supplementary material C.

▶ VIDEO



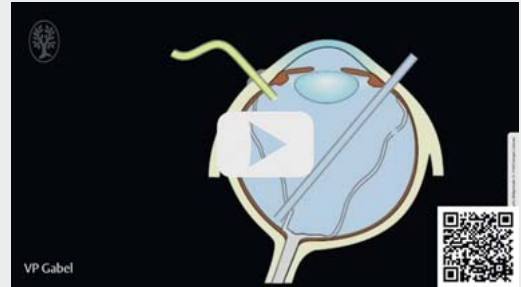▶ **Video 6** Supplementary material F.

▶ VIDEO



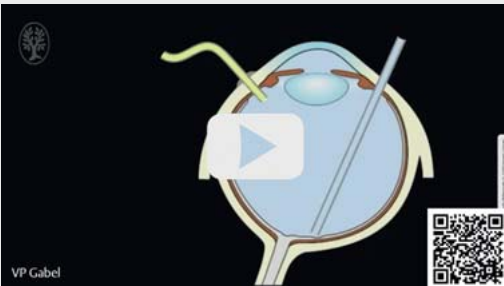▶ Video 7 Supplementary material G.

▶ VIDEO



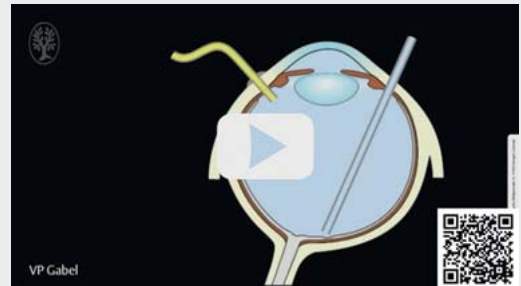▶ Video 10 Supplementary material J.

▶ VIDEO



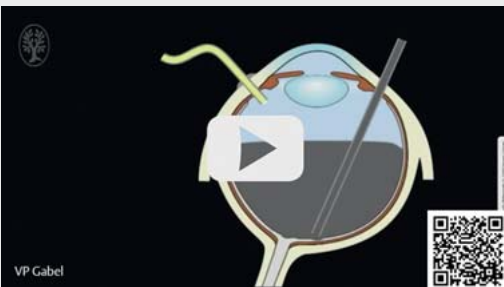
▶ Video 8 Supplementary material H.

▶ VIDEO



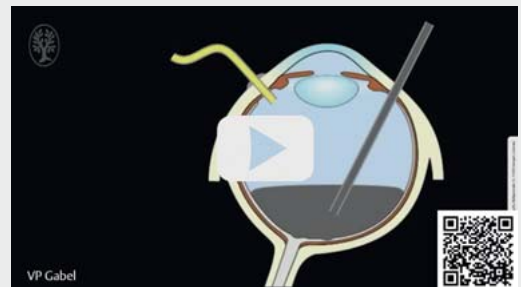
▶ Video 11 Supplementary material K.

▶ VIDEO



▶ Video 9 Supplementary material I.

▶ VIDEO



▶ Video 12 Supplementary material L.



▶ VIDEO



▶ **Video 13** Supplementary material M.