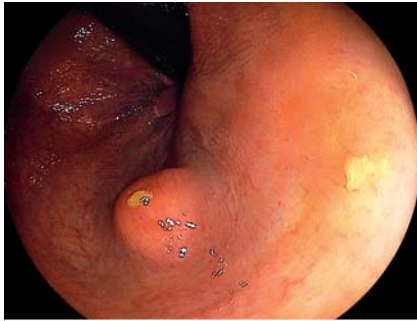
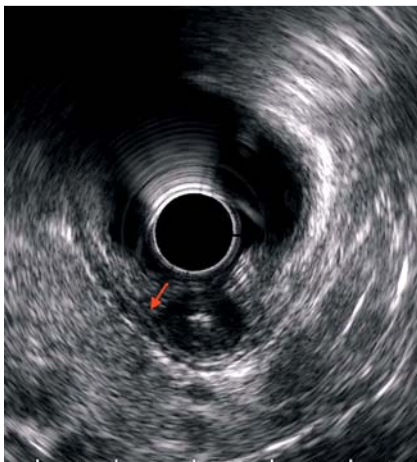

## Endoscopic intermuscular dissection for a lower rectal gastrointestinal stromal tumor

OPEN  
ACCESS

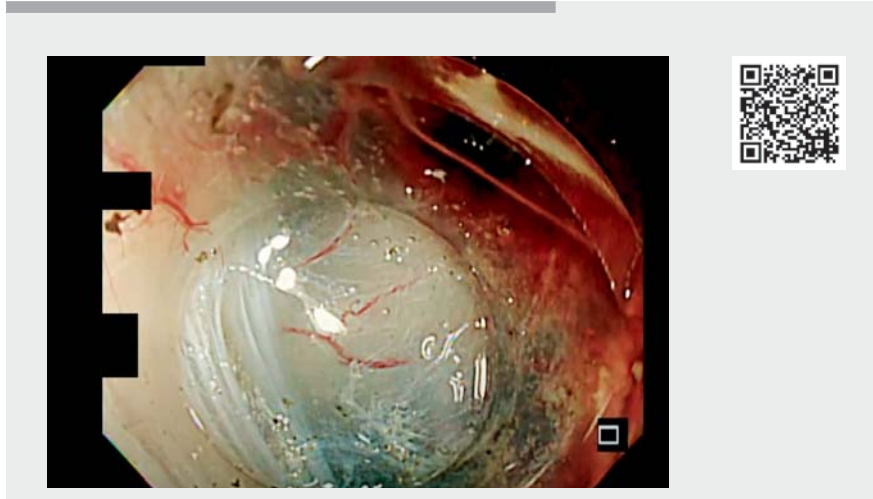


► **Fig. 1** Endoscopic view showing a 1.5-cm submucosal tumor in the lower rectum, which was diagnosed on a boring biopsy to be a gastrointestinal stromal tumor.



► **Fig. 2** Endoscopic ultrasound image showing that the tumor was located primarily in the internal circular muscle, extending to the internal fourth layer (arrow), with no invasion of the external fourth layer.

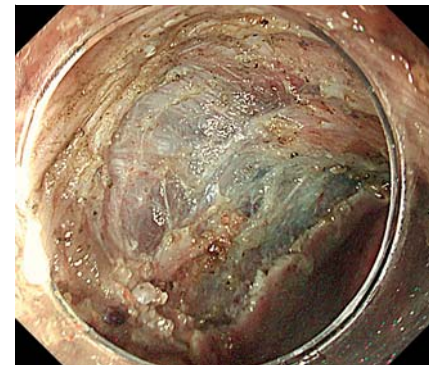The standard treatment for rectal gastrointestinal stromal tumors (GISTs) without metastases is total surgical resection, but this strategy is controversial owing to the extremely low prevalence of GISTs. Minimally invasive transanal surgery can be performed as a surgical reduction technique via transanal local excision; however, this technique is not as selective as endoscopic resection and anastomotic



► **Video 1** Endoscopic intermuscular dissection is performed for a rectal gastrointestinal stromal tumor, allowing the preservation of the external longitudinal muscle.

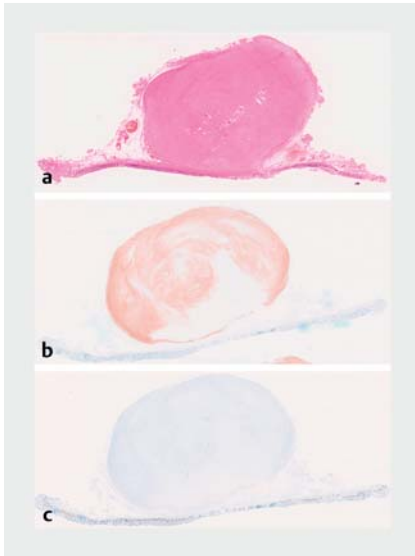
leakage is a reported complication as a result of full-layer resection [1]. Although a number of endoscopic resections have been reported [2, 3], no established procedure is available.

A 36-year-old man was diagnosed with a GIST of approximately 1.5 cm in the lower rectum (► **Fig. 1**). Endoscopic ultrasound revealed a tumor that was predominantly located in the internal circular muscle, without invasion of the external longitudinal muscle (► **Fig. 2**). We considered selective resection to preserve the external longitudinal muscle and subsequently performed endoscopic intermuscular dissection [4]. We used a GIF-H290 T gastroscope (Olympus, Tokyo, Japan) with an ST hood short-type tip (DH-28GR; Fujifilm, Tokyo, Japan) and resected the tumor using a DualKnife J (Olympus, Tokyo, Japan) and injection of hyaluronic acid. We adopted the Endocut I mode (effect 2, duration 3, interval 3) of the VIO300-D electro-surgical system (Erbe Elektromedizin GmbH, Tübingen, Germany) during myotomy. Treatment was completed within 45 minutes without perforation (► **Video 1**; ► **Fig. 3**). Pathological find-



► **Fig. 3** Endoscopic appearance after the tumor and the invaded internal circular muscle had been resected, leaving the external longitudinal muscle preserved and intact, with no evidence of perforation.

ings demonstrated complete resection without tumor exposure and a very low risk GIST (► **Fig. 4**) [5]. The layer between the inner circular and external longitudinal muscles was accessed and injected with water-jet instrumentation to facilitate dissection and selective excision. The patient was discharged on the sixth postoperative day without complications.



► **Fig. 4** Histopathology of the resected submucosal tumor showing: **a** on hematoxylin and eosin staining, the tumor surface covered by the submucosal and muscular layer, with no tumor exposure observed; **b** positivity on c-Kit staining; **c** a Ki-67 index of <5%.

Endoscopic intermuscular dissection can be a treatment option for lower rectal GISTs without preoperative invasion of the external longitudinal muscle.

Endoscopy\_UCTN\_Code\_TTT\_1AQ\_2AD

### Competing interests

The authors declare that they have no conflict of interest.

### The authors

**Chikamasa Ichita<sup>1</sup>**, **Akiko Sasaki<sup>1</sup>**, **Jun Kawachi<sup>2</sup>**, **Haruto Hirose<sup>1</sup>**, **Hideki Kamiishi<sup>1</sup>**, **Jun Kubota<sup>1</sup>**, **Miki Nagayama<sup>1</sup>**

- 1 Gastroenterology Medicine Center, Shonan Kamakura General Hospital, Kamakura, Kanagawa, Japan
- 2 Department of Surgery, Shonan Kamakura General Hospital, Kamakura, Kanagawa, Japan

### Corresponding author

**Chikamasa Ichita, MD**

Gastroenterology Medicine Center,  
Shonankamakura General Hospital,  
1370-1 Okamoto, Kamakura, Kanagawa  
247-8533, Japan  
ichikamasa@yahoo.co.jp

### References

- [1] Albert MR, Atallah SB, deBeche-Adams TC et al. Transanal minimally invasive surgery (TAMIS) for local excision of benign neoplasms and early-stage rectal cancer: efficacy and outcomes in the first 50 patients. *Dis Colon Rectum* 2013; 56: 301–307
- [2] Wallenhorst T, Jacques J, Lièvre A et al. Endoscopic resection of a rectal gastrointestinal stromal tumor using the submucosal tunneling endoscopic resection (STER) technique. *Endoscopy* 2022; 54: E273–E274
- [3] Kim SJ, Jung Y, Hong R et al. Successful endoscopic resection of a rectal gastrointestinal stromal tumor larger than 5 cm. *Korean J Gastroenterol* 2021; 78: 235–239
- [4] Moons LMG, Bastiaansen BAJ, Richir MC et al. Endoscopic intermuscular dissection for deep submucosal invasive cancer in the rectum: a new endoscopic approach. *Endoscopy* 2022; 54: 993–998

- [5] Joensuu H. Risk stratification of patients diagnosed with gastrointestinal stromal tumor. *Hum Pathol* 2008; 39: 1411–1419

### Bibliography

*Endoscopy* 2023; 55: E258–E259

DOI 10.1055/a-1974-8823

ISSN 0013-726X

published online 25.11.2022

© 2022. The Author(s).

This is an open access article published by Thieme under the terms of the Creative Commons Attribution-NonDerivative-NonCommercial License, permitting copying and reproduction so long as the original work is given appropriate credit. Contents may not be used for commercial purposes, or adapted, remixed, transformed or built upon. (<https://creativecommons.org/licenses/by-nc-nd/4.0/>)

Georg Thieme Verlag KG, Rüdigerstraße 14,  
70469 Stuttgart, Germany



### ENDOSCOPY E-VIDEOS

<https://eref.thieme.de/e-videos>



*Endoscopy E-Videos* is an open access online section, reporting on interesting cases and new techniques in gastroenterological endoscopy. All papers include a high quality video and all contributions are freely accessible online. Processing charges apply (currently EUR 375), discounts and waivers acc. to HINARI are available.

This section has its own submission website at  
<https://mc.manuscriptcentral.com/e-videos>