

Endoscopic strictureplasty for severe colonic anastomotic stricture

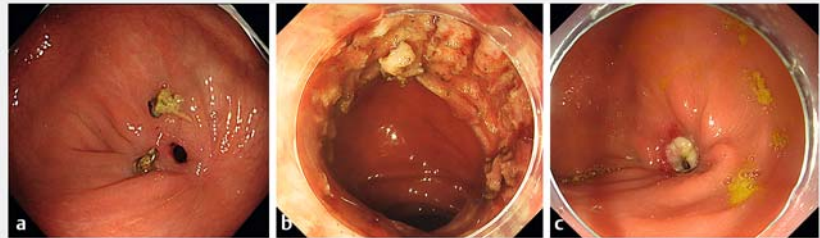OPEN
ACCESS

Benign anastomotic stricture after colonic resection usually requires surgical or endoscopic dilation. The radial incision and cutting (RIC) method was recently developed to treat resistant strictures and the recurrence rate is 28.5–44.2% [1, 2]. In this report, we developed endoscopic strictureplasty (ESP) for refractory anastomotic stricture after colorectal surgery not resolved by two RICs.

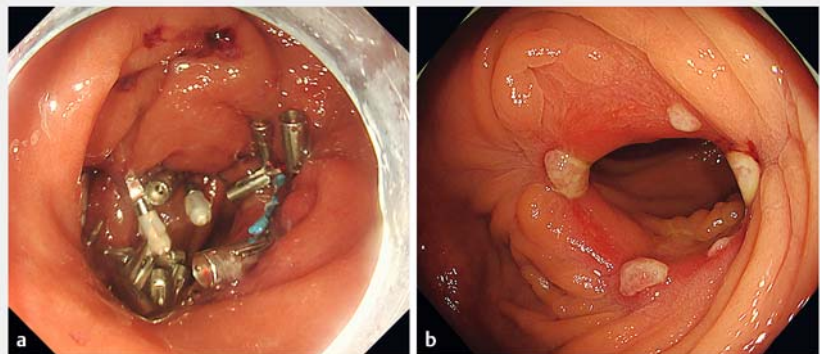
A 70-year-old man with colorectal cancer at the sigmoid colon underwent surgery with end-to-end anastomosis using a circular stapling device. A colonoscopy for constipation revealed an anastomotic stricture (► Fig. 1 a). RIC was performed twice, however, both times the stricture recurred (► Fig. 1 b, c). Therefore, ESP was performed (► Fig. 2 a, ► Video 1).

ESP was adapted from the Heineke-Mikulicz (HM) strictureplasty, a conventional method of strictureplasty [3]. The HM strictureplasty involves resection of the tract from the serosal side, although this method uses an endoscope to resect the muscle layer from the mucosal side without full-thickness resection. First, the blade of the ITknife2 (Olympus, Tokyo, Japan) was inserted and three longitudinal incisions were made into the stricture, and the inner circular and outer longitudinal muscle layers were dissected until the subserosal layer was visualized. The incision was resutured transversely; a 30-mm endoloop (HX-400U-30; Olympus) was anchored to the proximal and distal edge of the defect with a SureClip (Micro-Tech, Nanjing, China), and closed bringing both edges together. Finally, clips were applied to close the remaining defect (► Fig. 3).

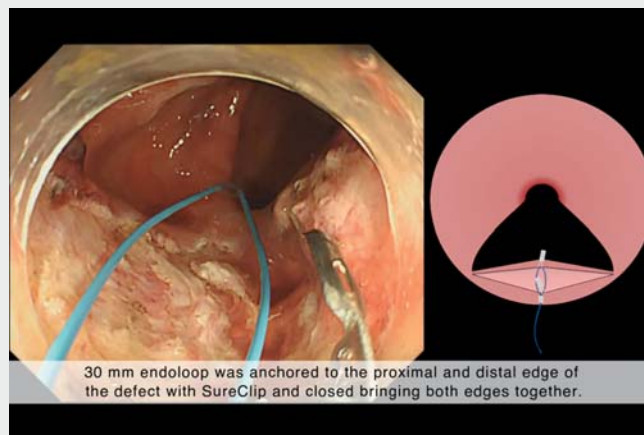
The recurrence after two RICs is considered to be due to the distortion of the muscular layer. In such cases, a direct approach to the muscle layer is more effective than RIC. Closing the defect transversely allows the lumen to dilate. There was no recurrence 6 months after the procedure (► Fig. 2 b).



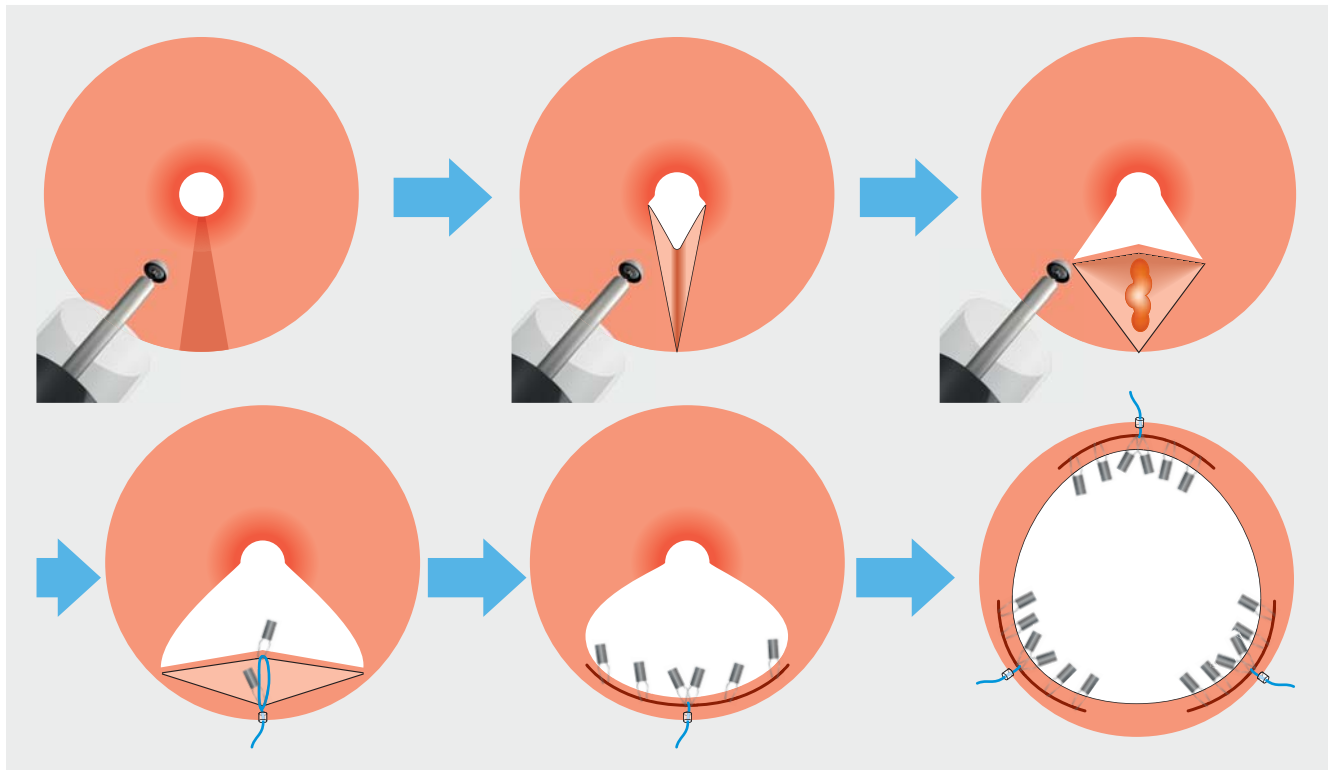
► Fig. 1 Endoscopic images. a Anastomotic stricture at the sigmoid colon after surgery. b Satisfactory patency immediately after radial incision and cutting (RIC). c Resistant anastomotic stricture after 2 RICs.



► Fig. 2 Endoscopic images. a Endoscopic strictureplasty performed for resistant anastomotic stricture. b No recurrence 6 months after endoscopic strictureplasty.



► Video 1 Endoscopic strictureplasty was performed for resistant anastomotic stricture.



► Fig. 3 Endoscopic strictureplasty procedure.

Endoscopic strictureplasty is an effective endoscopic surgery for resistant anastomotic stricture.

Endoscopy_UCTN_Code_CCL_1AD_2A]

Competing interests

The authors declare that they have no conflict of interest.

The authors

Shunya Takayanagi¹, Ken Ohata¹, Yoshiaki Kimoto¹, Rindo Ishii¹, Ryoju Negishi¹, Yohei Minato¹, Kentaro Nakajima²

- 1 Department of Gastrointestinal Endoscopy, NTT Medical Center Tokyo, Tokyo, Japan
- 2 Department of Surgery, NTT Medical Center Tokyo, Tokyo, Japan

Corresponding author

Ken Ohata, MD

Department of Gastrointestinal Endoscopy,
NTT Medical Center Tokyo, 5-9-22 Higashi-
gotanda Shinagawa-ku, Tokyo 141-8625,
Japan
Fax: +81-3-3448-6541
ken.ohata1974@gmail.com

References

- [1] Moroi R, Shiga H, Nochioka K et al. Endoscopic radial incision and cutting for benign stenosis of the lower gastrointestinal tract: An investigation of novel endoscopic treatment in multicenter trial. *J Gastroenterol Hepatol* 2022; 37: 1554–1560
- [2] Osera S, Ikematsu H, Odagaki T et al. Efficacy and safety of endoscopic radial incision and cutting for benign severe anastomotic stricture after surgery for lower rectal cancer (with video). *Gastrointest Endosc* 2015; 81: 770–773
- [3] Lee EC, Papaioannou N. Minimal surgery for chronic obstruction in patients with extensive or universal Crohn's disease. *Ann R Coll Surg Engl* 1982; 64: 229–233

Bibliography

Endoscopy 2023; 55: E301–E302
DOI 10.1055/a-1982-3756
ISSN 0013-726X
published online 13.12.2022
© 2022. The Author(s).

This is an open access article published by Thieme under the terms of the Creative Commons Attribution-NonDerivative-NonCommercial License, permitting copying and reproduction so long as the original work is given appropriate credit. Contents may not be used for commercial purposes, or adapted, remixed, transformed or built upon. (<https://creativecommons.org/licenses/by-nc-nd/4.0/>)

Georg Thieme Verlag KG, Rüdigerstraße 14,
70469 Stuttgart, Germany

