

Intercondylar Notch Pathology

Nisha Crouser, MD¹ Jonathan Wright, BS¹ Alex DiBartola, MD¹ David Flanigan, MD¹
Robert Duerr, MD¹

¹Department of Orthopaedics, The Ohio State University Wexner Medical Center, Columbus, Ohio

Address for correspondence Robert Duerr, MD, Division of Sports Medicine, Department of Orthopaedics, The Ohio State University Wexner Medical Center, 915 Olentangy River Road, Columbus, OH 43212 (e-mail: Robert.duerr@osumc.edu).

J Knee Surg 2024;37:149–157.

Abstract

The intercondylar notch of the knee is a relatively small area. However, numerous rare pathologies can arise in this region. A majority of the existing literature has focused on the cruciate ligament injuries, yet there are several other entities that can cause knee pain from within the intercondylar notch. This review focuses on identifying the various diagnostic and treatment options for rare benign and malignant lesions including ganglion cyst formation, mucoid degeneration, benign proliferative conditions, and intra-articular tumors. These entities are most often diagnosed with advanced imaging studies and treated arthroscopically. While rare, these pathologies are important to identify in patients with ongoing vague knee pain.

Keywords

- ▶ intercondylar notch
- ▶ ganglion
- ▶ knee pain

The intercondylar notch of the knee is an anatomic location that contains the cruciate ligaments, attachments of the menisci, and several accessory ligaments. Given the many structures located within the notch, there are numerous pathologies that can arise in this area of the knee. Patients often present with a wide range of symptoms, ranging from pain to instability to mechanical locking. While the majority of studies have focused on injuries of the anterior cruciate ligament (ACL) and posterior cruciate ligament (PCL), there are several other conditions that can arise in the intercondylar notch that should be considered when evaluating patients with intra-articular symptoms.¹

The purpose of this review is to discuss the various rare pathologies that have been identified in the intercondylar notch along with the imaging findings and treatment considerations for these patients. Specifically, we will focus on ganglion cyst formation, mucoid degeneration, benign proliferative conditions, and malignant lesions arising from the intercondylar notch.

Anatomy

The intercondylar notch is the distal femoral fossa residing at the distal end of the femur between the medial and lateral

femoral condyles (▶ **Fig. 1**). It begins at the bony margins of the femoral condyles. The roof of the intercondylar notch can be radiographically estimated by Blumensaat's line.² The floor of the notch is formed by the intercondylar area of the tibial plateau, which contains the insertions of the cruciate ligaments. The intercondylar eminence also divides the floor into anterior and posterior, which house the tibial insertions of the ACL and PCL, respectively. These encapsulated ligamentous origins and insertions within the intercondylar notch produce a labyrinth of synovial invaginations, which can contribute to various pathologies.

Intercondylar notch width tapers from 23 to 18 mm proximal to distal, while notch height is typically 13 mm proximally, peaks at 24 mm midnotch, and ends distally at 18 mm.³ These results reveal a notch shape that is narrowest at its distal opening and widens as it tracks proximally. Furthermore, the roof of the notch is wider posteriorly and tapers anteriorly, creating a trapezoidal shape.² Females tend to have narrower intercondylar notches, even when controlling for height and weight differences.^{4,5} A narrower notch has been correlated with increased risk of osteoarthritis and ACL injury.^{6,7} Notch shape varies as well, ranging from an inverted U shape to A shape to wave shape.^{8,9} A-shaped notches reflect narrower measurements in all dimensions.¹⁰

received

July 6, 2022

accepted after revision

December 16, 2022

accepted manuscript online

December 20, 2022

article published online

February 7, 2023

© 2023. Thieme. All rights reserved.

Thieme Medical Publishers, Inc.,

333 Seventh Avenue, 18th Floor,

New York, NY 10001, USA

DOI <https://doi.org/>

10.1055/a-2001-6764.

ISSN 1538-8506.

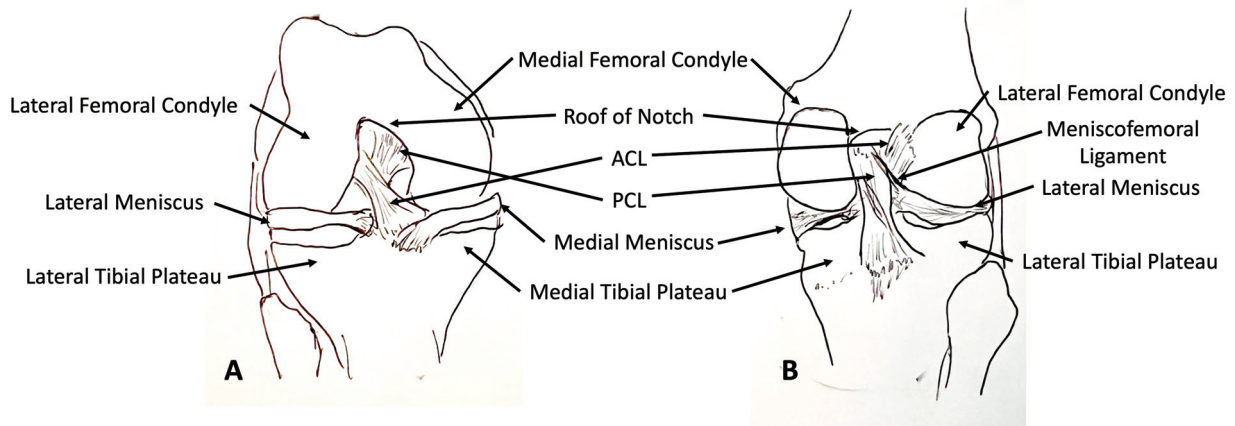


Fig. 1 Drawing of the distal femur demonstrating the bony anatomy of the intercondylar notch from the (A) anterior view and (B) posterior view. ACL, anterior cruciate ligament; PCL, posterior cruciate ligament.

While notch shape has been shown to contribute to the likelihood of cruciate ligament injury, there is not adequate literature to support whether the development of other rare pathologies is linked to notch width or shape.

Intraoperatively, various notch landmarks are used to identify anatomic structures and guide total knee arthroplasty and cruciate ligament reconstruction. Whiteside's line represents an anterior–posterior line from the posterior intercondylar notch to the anterior patellar groove, an important anatomic landmark in total knee replacement alignment.^{11,12} Within the intercondylar notch, there is a cortical thickening on the lateral wall, known as the bifurcate ridge, that represents the functional footprint of the ACL, which is important when planning ACL tunnel placement.^{13,14}

The intercondylar notch has a high incidence of synovial invaginations due to the nature of the intra-articular cruciate ligaments. The complex pattern of synovial folding predisposes this area to be particularly sensitive to synovitis.^{15–17} Synovial pathologies can manifest as rare tumor pathologies such as osteochondromata, lipomas, chondromatosis, chondromas, and giant cell tumors.^{18–22} Other relevant attachments along the intercondylar notch include the infrapatellar fat pad, which can be mistaken for the ligamentum mucosum (infrapatellar plica) and is a specific site for intra-articular ganglia.²³ While the intercondylar notch is relatively small, numerous pathologies have been identified in this location.

General Imaging

In general, radiographs are the first imaging modality for patients presenting with knee pain. However, the preferred noninvasive imaging modality for the intercondylar notch is magnetic resonance imaging (MRI). MRI of the intercondylar notch yields the most accurate preoperative measurements when planning reconstruction and has the highest sensitivity for identifying rare pathologies.²⁴

Ultimately, arthroscopy is the gold standard of diagnostic imaging for the intercondylar notch; other imaging modalities attempt to replicate the view. The intercondylar notch is accessed with the patient supine and knee flexed to

90 degrees, where the notch can be viewed from a standard lateral portal.²⁵ Arthroscopy serves as both the definitive diagnostic tool for pathology and often surgical treatment modality of choice.

Ultrasound does not have strong penetration into bony tissue but does have soft-tissue diagnostic utility. Presently, it has been used in vivo to measure and monitor cartilage in osteoarthritis and rheumatoid arthritis.^{26–29} While the diagnostic utility for ultrasound in intercondylar notch pathology is limited, it is a notable modality due to the evolving nature of the field and the acoustic window the intercondylar notch provides for soft-tissue lesions.

Intra-articular Ganglia

Intra-articular ganglia are relatively rare within the knee and are often discovered incidentally.³⁰ These ganglia are cystic, tumorlike structures with a spindle-shaped cell lining on histology.^{30,31} Ganglion cysts contain mucin or fluid that can be serous, yellow and gelatinous, or hematogenous. About 50 to 60% of knee intra-articular ganglia are located in the intercondylar notch.^{32,33} These cysts are most often incidental findings, with a peak incidence of cruciate ganglion cysts in young to middle-aged adults.^{30,34,35} Ganglion cysts can originate from the cruciate ligaments, infrapatellar fat pad, the menisci, medial plica, popliteus tendon, subchondral bone, and chondral fractures.^{34,36–40} Ganglia most commonly arise from the cruciate ligaments at their femoral insertion or on the infrapatellar fat pad.^{32,41} Prevalence of intra-articular ganglion cysts is reported to be around 1.3% in patients undergoing knee MRI, with 61% of these intra-articular ganglia occurring in the intercondylar notch.^{32,33,42} Ganglia are typically multilocular and ovoid, but can be fusiform, with size ranging from 5 up to 73 mm, averaging from 23 to 31 mm.^{33,36,42} Size is relevant as it was found that ganglia of the ACL and anterior menisci of >20 mm can cause articular cartilage damage.³⁶ Intra-articular ganglia and mucoid degeneration are often concomitant findings in adults.^{42,43} Other associated lesions and complications include bone erosion, tissue dissection, meniscal lesions,

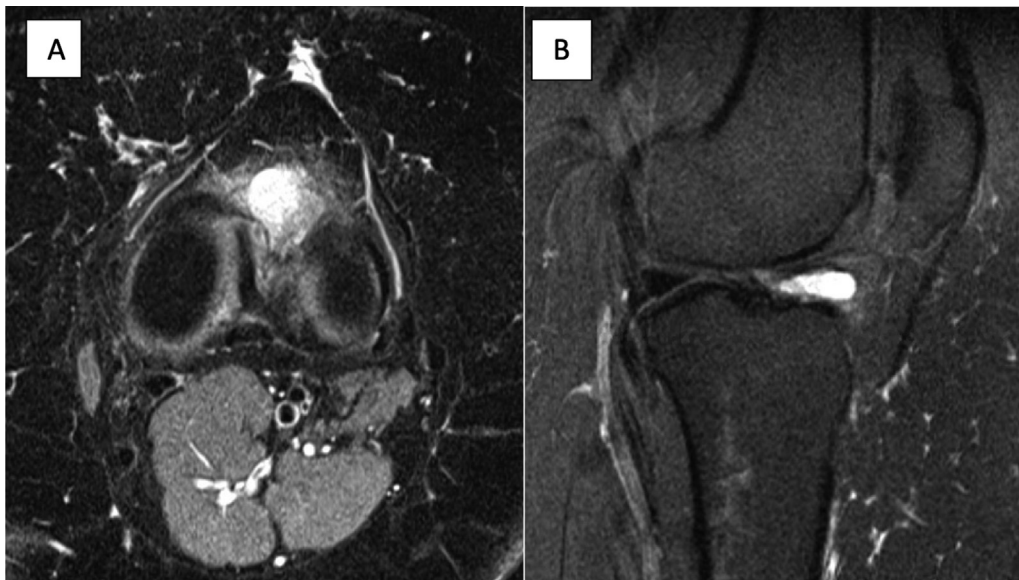


Fig. 2 Intra-articular ganglion cyst. A 28-year-old woman with chronic left knee pain. She described deep, sharp pain with intermittent effusions. She had tried two corticosteroid injections and multiple rounds of physical therapy prior to presentation. On examination, she had mild effusion and range of motion from 0 to 105 degrees. MRI revealed intra-articular ganglion in the anterior aspect of the knee, consistent with ACL ganglion. (A) Axial MRI image demonstrating cyst within the notch. (B) Sagittal MRI illustrating cyst within the notch.

chondromalacia, and synovitis.^{36,44} The pathogenesis of ganglion cysts is debated with a plurality of theories, although previous trauma is reported in 38 to 67% of symptomatic intra-articular ganglia.^{41,45}

In general, intra-articular ganglia are asymptomatic (89%); if symptomatic, the most common complaint is pain.^{36,41,42,46} Symptoms can include medial/lateral joint line pain and tenderness, retropatellar pain, mechanical block, crepitus, and effusion. Symptoms typically correlate with the size and location of the ganglia.^{32,33,47-50} Pain with deep knee flexion and absence of joint instability are

common unique findings.^{33,38,42,49,50} Given the wide range of symptoms and examination findings, imaging is often required for diagnosis of intra-articular ganglion cysts.

MRI findings with arthroscopic confirmation is the gold standard diagnosis for intra-articular ganglia⁵¹ (→Figs. 2 and 3). The cyst's signal intensity parallels water with a homogeneously low signal intensity on T1-weighted spin echo images and high signal intensity on proton density-weighted fast spin echo or short tau inversion recovery (STIR) images.⁵² Further, cysts have a homogeneous

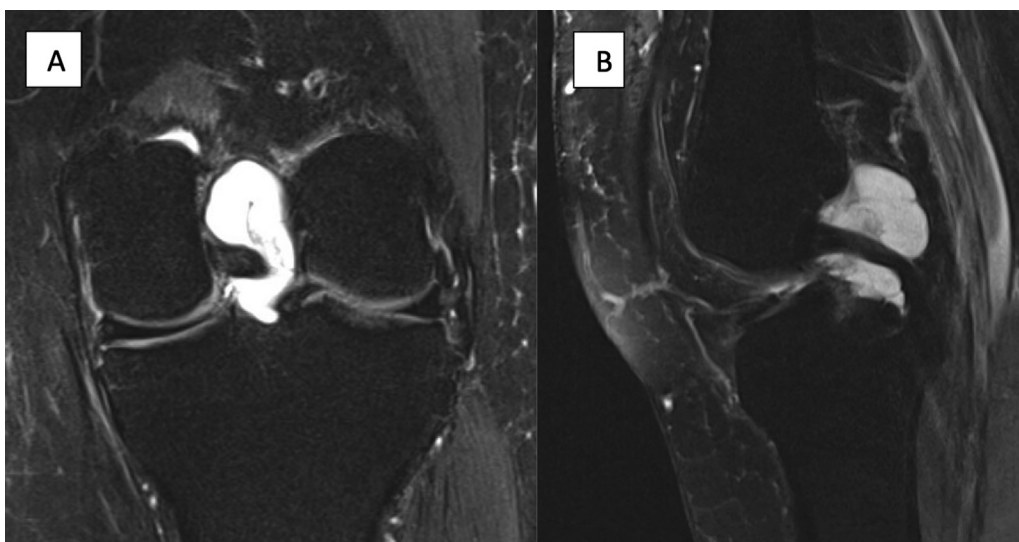


Fig. 3 Parameniscal cyst extending into notch. A 48-year-old woman presented with a 4-month history of knee pain. She described a pain deep in the knee with associated limited range of motion. She noted one episode of mechanical locking. Pain was worse with stairs, squatting, and running. She denied previous knee surgery and had a remote history of patellar dislocation. On examination, she had a mild effusion, range of motion from 5 to 90 degrees, positive McMurray's test, and medial joint line tenderness. MRI revealed tear of the posterior horn of the medial meniscus and associated parameniscal cyst extending into the notch. (A) Coronal STIR image showing cyst occupying notch. (B) Sagittal STIR image with cyst extending into posterior aspect of the knee.

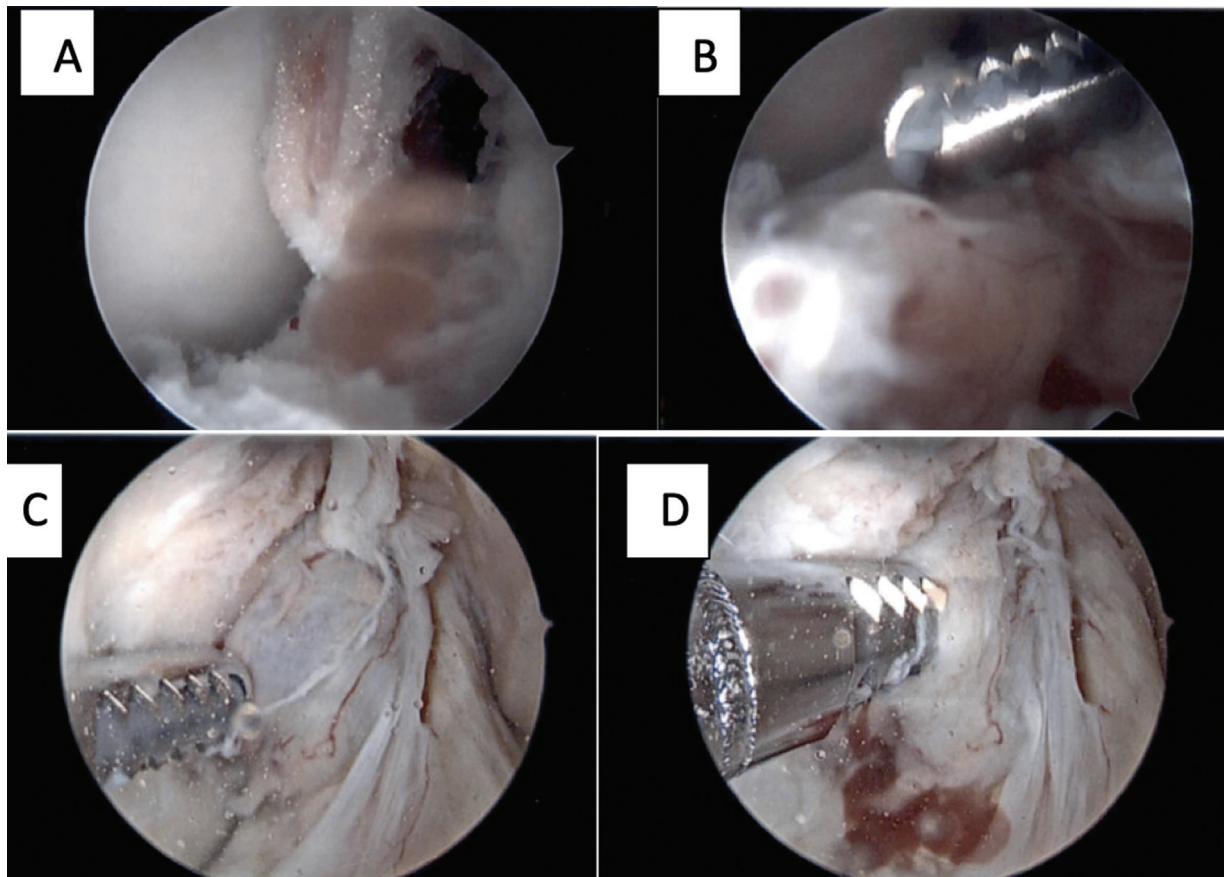


Fig. 4 Intra-articular ganglion cyst arthroscopic treatment. (A) Large ganglion cyst at the base of the ACL insertion measuring ~ 1.5 cm in size. (B) Cyst removed using a shaver; once removed, coblation used for hemostasis. Patient reported 95% improvement in pain at 12-week follow-up visit. (C) Large parameniscal cyst extending from the medial meniscus root along posterior cruciate ligament into the notch between the ACL and PCL. (D) The cyst was debrided with a shaver without disrupting the underlying ACL or PCL.

hyperintense signal compared with skeletal muscle on T2-weighted images.³¹ T1-weighted MRI may make it difficult to differentiate ACL cysts from ACL tears; thus, it is recommended that T2-weighted MRI be used, as the cyst will have contrast against an intact ACL.³² Further, contrast-enhanced MRI is usually not required for diagnosis, but can be a useful tool in differentiating infrapatellar fat pad ganglia from synovial hemangiomas and synovial sarcomas.³³ The differential diagnosis to consider with intra-articular cysts includes synovial chondromatosis, synovial hemangioma, synovial sarcoma, synovial proliferation, lipoma, fibroma, myxoma, pigmented villonodular synovitis, intra-articularly dissecting meniscal cyst, intra-articular ganglion cyst, hematoma, aneurysm, and infrapatellar bursae.^{20,33,36,53,54}

Treatment of symptomatic intra-articular ganglion cysts typically involves arthroscopic resection. Resection is the gold standard of treatment, given the high recurrence rate with retained tissue^{49,55} (**Fig. 4**). Arthroscopic treatment via whole resection and piecemeal resection showed excellent improvement of symptoms and function at 2 weeks and 6 months of follow-up in a study of 38 patients.⁴¹ Several other studies reported majority excellent results following arthroscopic resection for isolated ganglion cysts. Results were less reliable if there were concomitant injuries.^{34,56,57} Duration of symptoms is an important consideration when

discussing treatment options with patients. Earlier diagnosis and arthroscopic debridement is associated with improved results compared with delayed diagnosis, which often makes resection more difficult.⁵⁸

Mucoid Degeneration

Mucoid degeneration of the ACL has been identified as a rare cause of knee pain.⁵⁹ On the basis of a review of 4,221 MRIs, Bergin et al found the incidence of mucoid degeneration to be approximately 1.8%.⁴² Mucoid degeneration of the ACL has been found most commonly in middle-aged patients presenting with posterior knee pain and restricted flexion of the knee, without evidence of ligamentous instability. Typically, there is no history of trauma to the knee or involvement in sports provoking injury in these patients.^{51,60,61} Mucoid degeneration is diagnosed using a combination of MRI, histopathology, and arthroscopy. Interestingly, in one study, investigators reviewed 10 MRIs in which radiologists diagnosed an ACL tear but arthroscopically the ligament was intact and showed evidence of mucoid degeneration. The authors concluded that mucoid degeneration should be considered if the ACL appears thickened and ill-defined on MRI⁶² (**Fig. 5**). Arthroscopically, in the case of mucoid degeneration, the ACL appears bulbous, hypertrophied,

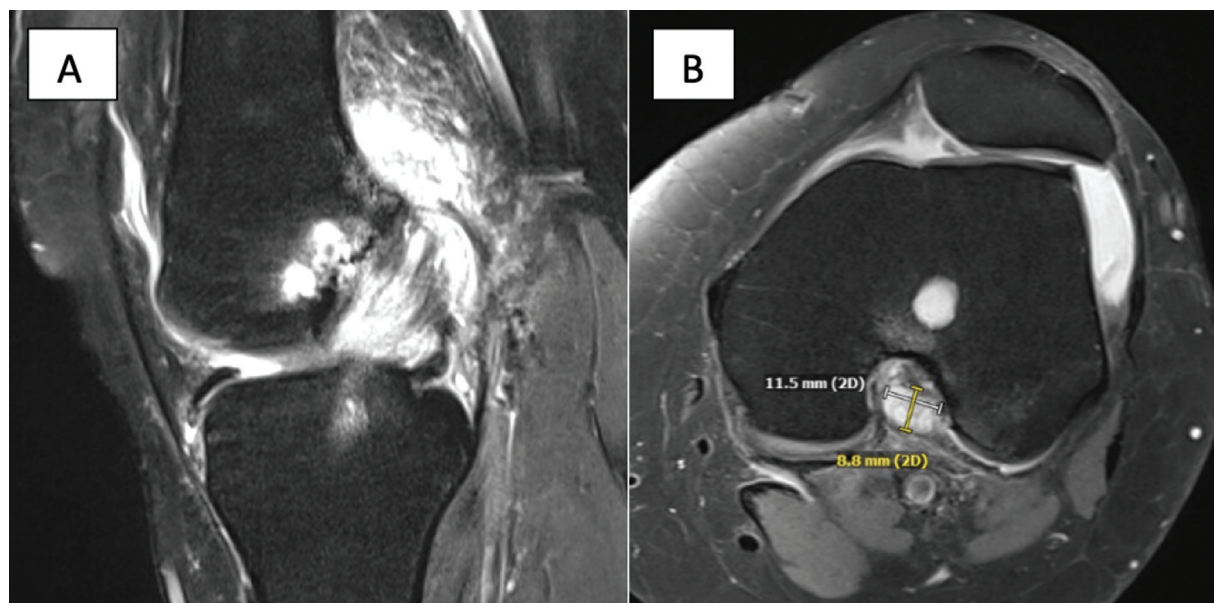


Fig. 5 Mucooid degeneration of ACL. (A) MRI demonstrates parameniscal cyst and mucooid degeneration of the ACL seen on sagittal image with thickening of the ACL and increased signal. (B) Associated large posterior cyst that abuts the posterior femoral condyle and femur.

and taut. A yellowish mass is often identified near the femoral insertion, occupying the notch and impinging the PCL in flexion, which is consistent with physical examination findings of restricted flexion.⁶¹

Several treatment options have been described for mucooid degeneration; the most common consists of arthroscopic debridement of the mucooid tissue resulting in partial resection of the ACL. This decreases the volume and tension of the ligament, providing significant pain relief in these patients while maintaining stability.^{60,61} Similarly, a circular volume reduction plasty of the ACL has been described using a radio-frequency ablation probe to circumferentially reduce the size of the ACL while leaving the intraligamentous mucooid tissue intact.⁶³ Complete excision of the ACL and notchplasty have also been performed, but neither appears necessary for satisfactory results.^{60,64–66} In young, active patients with ongoing instability and findings of ACL laxity, ACL reconstruction may be considered to restore knee stability.⁶⁵

Benign Tumors and Tumorlike Lesions

A variety of tumors and tumorlike lesions have been described in the intercondylar notch. Most commonly these lesions involve the synovium and cruciate ligaments.¹ The majority of proliferative disorders in the knee are benign. Primary synovial chondromatosis (PSC) is a monoarticular disease characterized by soft-tissue masses. In the knee, there is usually diffuse involvement, although isolated involvement of the intercondylar notch has been described.⁶⁷ When diffuse, the disease typically takes the path of least resistance extending into the intercondylar notch and posteriorly behind the proximal tibia.¹ Imaging will typically demonstrate soft-tissue swelling on plain radiographs and evidence of chondral calcification with advanced imaging.⁶⁷ The appearance of chondral calcification is variable on

imaging; one may see “dot and comma” or “popcornlike” calcifications.¹ Often, the extent of synovial disease is underestimated on radiographs. Treatment of PSC focuses on arthroscopic or open loose body removal for symptomatic relief and to prevent further joint degeneration.⁶⁸

Another benign condition that can arise in the notch is tenosynovial giant cell tumor (TSGCT), which is a proliferative disorder of the synovium. It can affect many joints, with the diffuse form (also known as pigmented villonodular synovitis) most prevalent in the knee.¹ Localized disease typically involves the hand and wrists, although rare focal involvement of the knee has been identified. Patients with intra-articular involvement of the knee often present with pain, recurrent knee effusions, mechanical block to motion, and even instability.⁵⁶ Radiographs may be normal given preserved joint space and lack of calcification. MRI appearance is variable: in the focal form, a pedunculated soft-tissue mass may be seen with signal enhancement on T2 and STIR sequences¹ (►Fig. 6). Intraoperatively, these lesions are characterized by a nodular appearance with a brown/yellow color from hemosiderin deposits. Treatment for localized TSGCT typically includes open or arthroscopic synovectomy (►Fig. 7) with very high rates of recurrence.⁶⁹ Involvement of the intercondylar notch is very rare.

Intracapsular and para-articular chondromas are benign tumors arising from the cartilaginous metaplasia of the joint capsule or surrounding tissue. In the knee, lesions are often found in the infrapatellar fat pad and rarely the intercondylar notch.^{70,71} Radiographically, these are soft-tissue masses with varying degrees of chondral calcification. These lesions can be large and histologically appear similar to malignant processes, with hypercellularity and mild atypia. Treatment for these lesions includes marginal resection; therefore, it is important to distinguish para-articular chondromas from chondrosarcomas.^{72,73}

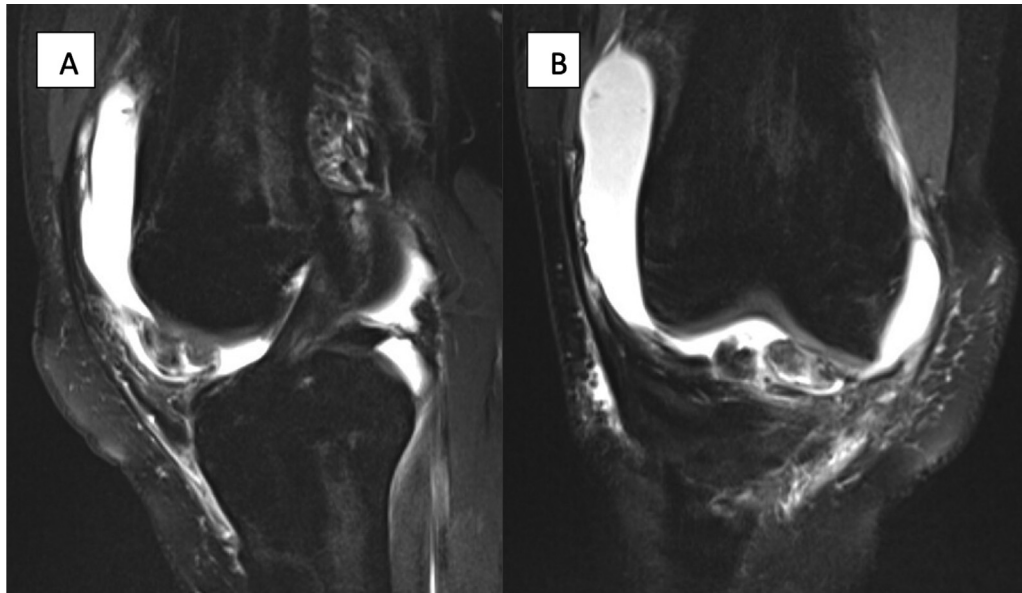


Fig. 6 TSGCT case example. A 23-year-old woman who presented with worsening right knee pain after episode of deep flexion. She has had intermittent mechanical symptoms and effusions for many years. On examination, there was a large effusion and range of motion from 0 to 115 degrees. MRI demonstrated a significant effusion with an associated large pedunculated soft-tissue mass in the anterior compartment seen on (A) sagittal and (B) coronal STIR images.

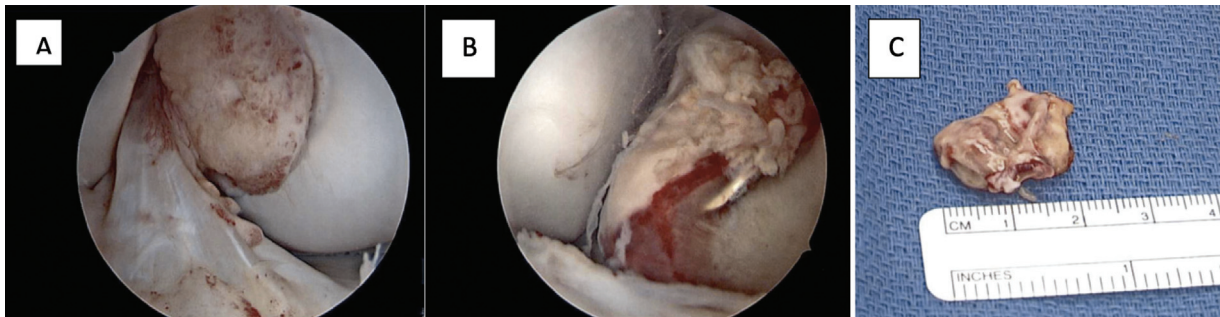


Fig. 7 Arthroscopic treatment of TSGCT. (A) Extensive synovitis with thin layer of erythema diffused throughout the joint. (B) Loose body with the appearance of a localized pigmented villonodular synovitis lesion seen within anterior aspect of the intercondylar notch. (C) The lesion was separated from the synovium and removed in its entirety, measuring ~2 cm in length.

Malignant Lesions in the Intercondylar Notch

With regard to malignant lesions, primary intra-articular tumors are very rare. Typically, malignancies occurring intra-articularly in the knee are the result of secondary invasion from surrounding sarcoma. Synovial sarcomas, despite their name, have no relation to synovial tissue, with less than 10% arising from synovial tissue.^{74–76} They typically occur in the extremities, with more than 25% of synovial sarcomas occurring around the knee and 5 to 10% having intra-articular involvement. Often, there are large cystic components, which can be mistaken for benign cystic lesions such as ganglion cysts. Histologically, two cell types are often identified in these lesions: spindle cells and epithelial cells. Unfortunately, these tumors are very aggressive and treatment often includes wide resection with adjuvant radiotherapy and/or chemotherapy.⁷⁷

Synovial chondrosarcoma can present as a primary malignancy or result from malignant transformation of diffuse PSC to a low-grade chondrosarcoma. This should be considered if there is rapid recurrence of PSC after synovectomy.⁷⁸ Synovial chondrosarcoma occurs typically in middle-aged patients, with males more commonly affected than females. Evidence of permeation of the cartilage into the surrounding bone is a characteristic feature seen on imaging and histology.⁷⁹ Distal metastasis to the lungs is common and should be considered when diagnosis has been made.¹ Treatment is similar to that for synovial sarcoma, with wide resection being the primary intervention.

Synovial metastasis is an extremely rare condition. Lung cancer is the most common malignancy to metastasize to synovial tissue, with the knee most commonly affected.⁸⁰ Although malignancy is low on the differential for intercondylar notch pathology, it should be considered when there are more aggressive features seen on imaging or there is

rapid clinical progression of symptoms since the outcomes can be devastating for patients.

Discussion

Due to their subtle and ambiguous nature, these rare intercondylar notch pathologies can often be missed or misdiagnosed, leading to delays in treatment and overall worse prognosis for patients. This review was intended to shed light on these rare entities and highlight the primary work-up and treatment of these lesions.

Diagnosis of these lesions typically begins with imaging since symptomatology is often vague. While radiographs are the initial imaging modality for both acute and chronic knee pain and injuries, MRI is the preferred noninvasive imaging modality of the intercondylar notch. Arthroscopy serves as the gold standard for diagnosis and treatment option for these pathologies.

Treatment options for these rare intercondylar notch pathologies follow similar recommendations. Malignant potential, functional compromise, and pain are primary reasons for operative intervention. Cysts and tumorlike lesions are typically treated with arthroscopic or open resection, sometimes requiring synovectomy.

Summary

Although the intercondylar notch is relatively small, there are numerous etiologies arising from this region with varying presentations. The majority of reports to date focus on the more common injuries involving the cruciate ligaments, with limited studies of the rare pathologies discussed. It is important that surgeons are aware of these benign and malignant lesions to accurately diagnose and treat their patients. Additional studies are needed to determine the best treatment algorithms and work-up for patients presenting with vague intra-articular knee pain.

Conflict of Interest

None declared.

References

- Li PK, James SL, Davies AM. Tumour and tumour-like lesions of the intercondylar notch of the knee: a pictorial review. *J Med Imaging Radiat Oncol* 2008;52(05):434-446
- Friedman RL, Feagin JA Jr. Topographical anatomy of the intercondylar roof. A pilot study. *Clin Orthop Relat Res* 1994;(306):163-170
- Koukoubis TD, Glisson RR, Bolognesi M, Vail TP. Dimensions of the intercondylar notch of the knee. *Am J Knee Surg* 1997;10(02):83-87, discussion 87-88
- Everhart JS, Flanigan DC, Chaudhari AM. Anteromedial ridging of the femoral intercondylar notch: an anatomic study of 170 archival skeletal specimens. *Knee Surg Sports Traumatol Arthrosc* 2014;22(01):80-87
- Shelbourne KD, Kerr B. The relationship of femoral intercondylar notch width to height, weight, and sex in patients with intact anterior cruciate ligaments. *Am J Knee Surg* 2001;14(02):92-96
- Geng B, Wang J, Ma JL, et al. Narrow intercondylar notch and anterior cruciate ligament injury in female nonathletes with knee osteoarthritis aged 41-65 years in plateau region. *Chin Med J (Engl)* 2016;129(21):2540-2545
- Sutton KM, Bullock JM. Anterior cruciate ligament rupture: differences between males and females. *J Am Acad Orthop Surg* 2013; 21(01):41-50
- Ireland ML, Ballantyne BT, Little K, McClay IS. A radiographic analysis of the relationship between the size and shape of the intercondylar notch and anterior cruciate ligament injury. *Knee Surg Sports Traumatol Arthrosc* 2001;9(04):200-205
- Anderson AF, Lipscomb AB, Liudahl KJ, Addlestone RB. Analysis of the intercondylar notch by computed tomography. *Am J Sports Med* 1987;15(06):547-552
- van Eck CF, Martins CA, Vyas SM, Celentano U, van Dijk CN, Fu FH. Femoral intercondylar notch shape and dimensions in ACL-injured patients. *Knee Surg Sports Traumatol Arthrosc* 2010;18(09):1257-1262
- Cerveri P, Marchente M, Manzotti A, Confalonieri N. Determination of the Whiteside line on femur surface models by fitting high-order polynomial functions to cross-section profiles of the intercondylar fossa. *Comput Aided Surg* 2011;16(02):71-85
- Middleton FR, Palmer SH. How accurate is Whiteside's line as a reference axis in total knee arthroplasty? *Knee* 2007;14(03):204-207
- Norman D, Metcalfe AJ, Barlow T, et al. Cortical bony thickening of the lateral intercondylar wall: the functional attachment of the anterior cruciate ligament. *Am J Sports Med* 2017;45(02):394-402
- Hutchinson MR, Ash SA. Resident's ridge: assessing the cortical thickness of the lateral wall and roof of the intercondylar notch. *Arthroscopy* 2003;19(09):931-935
- Rhodes LA, Keenan AM, Grainger AJ, Emery P, McGonagle D, Conaghan PG. The relationship between limited MRI section analyses and volumetric assessment of synovitis in knee osteoarthritis. *Clin Radiol* 2005;60(12):1295-1299
- Vanneuville G, Guillot M, Bénédict M, Escande G. The capsulo-synovial folds of the intercondylar fossa of the human knee [in French]. *Bull Assoc Anat (Nancy)* 1994;78(240):15-17
- Felson DT, Niu J, Neogi T, et al; MOST Investigators Group. Synovitis and the risk of knee osteoarthritis: the MOST Study. *Osteoarthritis Cartilage* 2016;24(03):458-464
- Chung JW, Lee SH, Han SB, Hwang HJ, Lee DH. A synovial osteochondroma replacing the anterior cruciate ligament at the intercondylar notch. *Orthopedics* 2011;34(02):136
- Sourlas I, Brilakis E, Mavrogenis A, Stavropoulos N, Korres D. Giant intra-articular synovial osteochondromata of the knee. *Hippokratia* 2013;17(03):281-283
- Motsis E, Vasiliadis HS, Xenakis TA. Intraarticular synovial lipoma of the knee located in the intercondylar notch, between ACL and PCL: a case report and review of the literature. *Knee Surg Sports Traumatol Arthrosc* 2005;13(08):683-688
- Fornaciari P, Schai PA, Kurrer MO, Exner GU. Arthroscopic synovectomy in bilateral lipoma arborescens. *J Orthop Case Rep* 2016; 6(05):7-13
- Huang GS, Lee CH, Chan WP, Chen CY, Yu JS, Resnick D. Localized nodular synovitis of the knee: MR imaging appearance and clinical correlates in 21 patients. *AJR Am J Roentgenol* 2003;181(02):539-543
- Abreu MR, Chung CB, Trudell D, Resnick D. Hoffa's fat pad injuries and their relationship with anterior cruciate ligament tears: new observations based on MR imaging in patients and MR imaging and anatomic correlation in cadavers. *Skeletal Radiol* 2008;37(04):301-306
- Staeubli HU, Adam O, Becker W, Burgkart R. Anterior cruciate ligament and intercondylar notch in the coronal oblique plane: anatomy complemented by magnetic resonance imaging in cruciate ligament-intact knees. *Arthroscopy* 1999;15(04):349-359

- 25 Vaswani R, Meredith SJ, Lian J, et al. Intercondylar notch measurement during arthroscopy and on preoperative magnetic resonance imaging. *Arthrosc Tech* 2019;8(10):e1263–e1267
- 26 Nemčić T, Perić P. Ultrasonography of the hip, knee and ankle [in Croatian]. *Reumatizam* 2010;57(02):81–89
- 27 Podlipská J, Koski JM, Pulkkinen P, Saarakkala S. In vivo quantitative ultrasound image analysis of femoral subchondral bone in knee osteoarthritis. *ScientificWorldJournal* 2013;2013:182562
- 28 Sakthiswary R, Rajalingam S, Hussein H, Sridharan R, Asrul AW. Cartilage oligomeric matrix protein (COMP) in rheumatoid arthritis and its correlation with sonographic knee cartilage thickness and disease activity. *Clin Rheumatol* 2017;36(12):2683–2688
- 29 Bajaj S, Lopez-Ben R, Oster R, Alarcón GS. Ultrasound detects rapid progression of erosive disease in early rheumatoid arthritis: a prospective longitudinal study. *Skeletal Radiol* 2007;36(02):123–128
- 30 Haller J, Resnick D, Greenway G, et al. Juxtaacetabular ganglionic (or synovial) cysts: CT and MR features. *J Comput Assist Tomogr* 1989;13(06):976–983
- 31 Recht MP, Applegate G, Kaplan P, et al. The MR appearance of cruciate ganglion cysts: a report of 16 cases. *Skeletal Radiol* 1994;23(08):597–600
- 32 Bui-Mansfield LT, Youngberg RA. Intraarticular ganglia of the knee: prevalence, presentation, etiology, and management. *AJR Am J Roentgenol* 1997;168(01):123–127
- 33 Kim MG, Kim BH, Choi JA, et al. Intra-articular ganglion cysts of the knee: clinical and MR imaging features. *Eur Radiol* 2001;11(05):834–840
- 34 Kang CN, Kim DW, Kim DJ, Kim SJ. Intra-articular ganglion cysts of the knee. *Arthroscopy* 1999;15(04):373–378
- 35 Kim RS, Kim KT, Lee JY, Lee KY. Ganglion cysts of the posterior cruciate ligament. *Arthroscopy* 2003;19(06):E36–E40
- 36 Krudwig WK, Schulte KK, Heinemann C. Intra-articular ganglion cysts of the knee joint: a report of 85 cases and review of the literature. *Knee Surg Sports Traumatol Arthrosc* 2004;12(02):123–129
- 37 Weber D, Friederich NF, Nidecker A, Müller W. Deep posterior knee pain caused by a ganglion of the popliteus tendon—a case report. *Knee Surg Sports Traumatol Arthrosc* 1996;4(03):157–159
- 38 Jäger A, Eberhardt C, Hailer NP. Large lateral meniscal ganglion cyst extending into the intercondylar fossa of the knee. *Arthroscopy* 2004;20(Suppl 2):6–8
- 39 Passler J, Hofer HP, Fellingner M, Peicha G. Intraarticular meniscal cysts of the knee. Report of two cases. *Int Orthop* 1991;15(04):357–358
- 40 Ohno Y, Itokazu M, Sakaeda H, Iinuma N, Shima H. Meniscal cyst in the posterior intercondylar space found by magnetic resonance imaging. *Arch Orthop Trauma Surg* 1998;117(6–7):394–396
- 41 Brown MF, Dandy DJ. Intra-articular ganglia in the knee. *Arthroscopy* 1990;6(04):322–323
- 42 Bergin D, Morrison WB, Carrino JA, Nallamshetty SN, Bartolozzi AR. Anterior cruciate ligament ganglia and mucoid degeneration: coexistence and clinical correlation. *AJR Am J Roentgenol* 2004;182(05):1283–1287
- 43 Jawish R, Nemer C, Assoum H, Haddad A. Ganglion cyst of the anterior cruciate ligament in children. *J Pediatr Orthop B* 2009;18(05):234–237
- 44 Janzen DL, Peterfy CG, Forbes JR, Tirman PF, Genant HK. Cystic lesions around the knee joint: MR imaging findings. *AJR Am J Roentgenol* 1994;163(01):155–161
- 45 Maffulli N, Binfield PM, King JB. Isolated ganglions of the anterior cruciate ligament. *Med Sci Sports Exerc* 1993;25(05):550–553
- 46 McLaren DB, Buckwalter KA, Vahey TN. The prevalence and significance of cyst-like changes at the cruciate ligament attachments in the knee. *Skeletal Radiol* 1992;21(06):365–369
- 47 Deutsch A, Veltri DM, Altchek DW, Potter HG, Warren RF, Wickiewicz TL. Symptomatic intraarticular ganglia of the cruciate ligaments of the knee. *Arthroscopy* 1994;10(02):219–223
- 48 Johnson WL, Corzatt RD. Ganglion cyst of the anterior cruciate ligament. A case report of an unusual cause of mechanical knee symptoms. *Am J Sports Med* 1993;21(06):893–894
- 49 Shetty GM, Nha KW, Patil SP, et al. Ganglion cysts of the posterior cruciate ligament. *Knee* 2008;15(04):325–329
- 50 Huang GS, Lee CH, Chan WP, et al. Ganglion cysts of the cruciate ligaments. *Acta Radiol* 2002;43(04):419–424
- 51 Fealy S, Kenter K, Dines JS, Warren RF. Mucoid degeneration of the anterior cruciate ligament. *Arthroscopy* 2001;17(09):E37
- 52 Stäbler A, Glaser C, Reiser M. Musculoskeletal MR: knee. *Eur Radiol* 2000;10(02):230–241
- 53 Steiner E, Steinbach LS, Schnarkowski P, Tirman PF, Genant HK. Ganglia and cysts around joints. *Radiol Clin North Am* 1996;34(02):395–425, xi–xii
- 54 Calmet J, Hernández-Hermoso J, Giné J, Jimeno F. Localized pigmented villonodular synovitis in an unusual location in the knee. *Arthroscopy* 2003;19(02):144–149
- 55 Saha P, Bandyopadhyay U, Mukhopadhyay AS, Kundu S, Mandal S. Ganglion cyst of knee from Hoffa's fat pad protruding anterolaterally through retinacular rent: a case report. *J Orthop Case Rep* 2015;5(03):69–71
- 56 Calvisi V, Collodel M, Romanini L. Synovial ganglia of the central pivot of the knee. *Ital J Orthop Traumatol* 1991;17(03):305–311
- 57 Sarimo J, Rantanen J, Helttula I, Orava S. Intra-articular cysts and ganglia of the knee: a report of nine patients. *Knee Surg Sports Traumatol Arthrosc* 2005;13(01):44–47
- 58 Andrikoula SI, Vasiliadis HS, Tokis AV, Kosta P, Batistatou A, Georgoulis AD. Intra-articular ganglia of the knee joint associated with the anterior cruciate ligament: a report of 4 cases in 3 patients. *Arthroscopy* 2007;23(07):800.e1–800.e6
- 59 Lintz F, Pujol N, Boisrenoult P, Bargoin K, Beaufile P, Dejour D. Anterior cruciate ligament mucoid degeneration: a review of the literature and management guidelines. *Knee Surg Sports Traumatol Arthrosc* 2011;19(08):1326–1333
- 60 Narvekar A, Gajjar S. Mucoid degeneration of the anterior cruciate ligament. *Arthroscopy* 2004;20(02):141–146
- 61 Motmans R, Verheyden F. Mucoid degeneration of the anterior cruciate ligament. *Knee Surg Sports Traumatol Arthrosc* 2009;17(07):737–740
- 62 McIntyre J, Moelleken S, Tirman P. Mucoid degeneration of the anterior cruciate ligament mistaken for ligamentous tears. *Skeletal Radiol* 2001;30(06):312–315
- 63 Morice A, Couptry A, Lintz F, Robert H. Reduction plasty for hypertrophic anterior cruciate ligament mucoid degeneration: clinical and knee laxity outcomes in 23 cases. *Orthop Traumatol Surg Res* 2013;99(06):693–697
- 64 Kim TH, Lee DH, Lee SH, Kim JM, Kim CW, Bin SI. Arthroscopic treatment of mucoid hypertrophy of the anterior cruciate ligament. *Arthroscopy* 2008;24(06):642–649
- 65 Lintz F, Pujol N, Dejour D, Boisrenoult P, Beaufile P. Anterior cruciate ligament mucoid degeneration: selecting the best treatment option. *Orthop Traumatol Surg Res* 2010;96(04):400–406
- 66 Chudasama CH, Chudasama VC, Prabhakar MM. Arthroscopic management of mucoid degeneration of anterior cruciate ligament. *Indian J Orthop* 2012;46(05):561–565
- 67 Wittkop B, Davies AM, Mangham DC. Primary synovial chondromatosis and synovial chondrosarcoma: a pictorial review. *Eur Radiol* 2002;12(08):2112–2119
- 68 Neumann JA, Garrigues GE, Brigman BE, Eward WC. Synovial chondromatosis. *JBJS Rev* 2016;4(05):e2
- 69 Llauger J, Palmer J, Rosón N, Cremades R, Bagué S. Pigmented villonodular synovitis and giant cell tumors of the tendon sheath: radiologic and pathologic features. *AJR Am J Roentgenol* 1999;172(04):1087–1091

- 70 González-Lois C, García-de-la-Torre P, SantosBriz-Terrón A, Vilá J, Manrique-Chico J, Martínez-Tello J. Intracapsular and para-articular chondroma adjacent to large joints: report of three cases and review of the literature. *Skeletal Radiol* 2001;30(12):672–676
- 71 Steiner GC, Meushar N, Norman A, Present D. Intracapsular and paraarticular chondromas. *Clin Orthop Relat Res* 1994;(303):231–236
- 72 Milgram JW, Dunn EJ. Para-articular chondromas and osteochondromas: a report of three cases. *Clin Orthop Relat Res* 1980;(148):147–151
- 73 Hagan PF, Schoenecker PL. Para-articular osteochondroma. *Am J Orthop* 1995;24(01):65–67
- 74 Ishida T, Iijima T, Moriyama S, Nakamura C, Kitagawa T, Machinami R. Intra-articular calcifying synovial sarcoma mimicking synovial chondromatosis. *Skeletal Radiol* 1996;25(08):766–769
- 75 McLain R, Buckwalter J, Platz CE. Synovial sarcoma of the knee: missed diagnosis despite biopsy and arthroscopic synovectomy. A case report. *J Bone Joint Surg Am* 1990;72(07):1092–1094
- 76 McKinney CD, Mills SE, Fechner RE. Intraarticular synovial sarcoma. *Am J Surg Pathol* 1992;16(10):1017–1020
- 77 Friedman MV, Kyriakos M, Matava MJ, McDonald DJ, Jennings JW, Wessell DE. Intra-articular synovial sarcoma. *Skeletal Radiol* 2013;42(06):859–867
- 78 Taconis WK, van der Heul RO, Taminiou AM. Synovial chondrosarcoma: report of a case and review of the literature. *Skeletal Radiol* 1997;26(11):682–685
- 79 Davis RI, Hamilton A, Biggart JD. Primary synovial chondromatosis: a clinicopathologic review and assessment of malignant potential. *Hum Pathol* 1998;29(07):683–688
- 80 Levine HR, Tingle E, Carter B, Dockery D. Synovial metastasis from lung cancer. *Proc Bayl Univ Med Cent* 2013;26(01):25–27