



Neurofibromatosis Type 1 with Giant Thrombotic Aneurysm of the Internal Carotid Artery Presenting with Rapid Progression of Visual Disturbance: A Case Report and Literature Review

Masato Kobayashi¹  Naoki Otani¹ Ryuta Kajimoto¹ Takamichi Katsuhara¹ Atsuo Yoshino¹

¹Division of Neurosurgery, Department of Neurological Surgery, Nihon University School of Medicine, Tokyo, Japan

J Neurol Surg Rep 2023;84:e6–e10.

Address for correspondence Naoki Otani, MD, PhD, Division of Neurosurgery, Department of Neurological Surgery, Nihon University School of Medicine, 30-1 Oyaguchi-Kamimachi, Itabashi-ku, Tokyo 173-8610, Japan (e-mail: otani.naoki@nihon-u.ac.jp).

Abstract

Background Patients with neurofibromatosis type 1 (NF1) have various vascular diseases due to the vascular fragility, but no reports of case of giant thrombotic aneurysm was found. We treated a rare case of giant thrombotic aneurysm of the internal carotid artery (ICA) in a patient with NF1.

Case Presentation A 60-year-old man had suffered deteriorating visual loss and homonymous hemianopia. Contrast-enhanced computed tomography showed a giant thrombosed aneurysm on the anterior wall of the ICA located in the optic chiasma. We planned and completed the external carotid artery-middle cerebral artery high-flow bypass using radial artery graft. The visual fields test was performed 14 days after surgery. Homonymous hemianopia persisted but no exacerbation of visual field impairment was observed. No complications were found at 14 days after surgery and the postoperative course was uneventful.

Conclusion We consider that external carotid artery-middle cerebral artery bypass surgery using radial artery grafts is a safe and effective treatment method for giant thrombotic aneurysm associated with NF1.

Keywords

- ▶ neurofibromatosis type 1
- ▶ thrombotic aneurysm
- ▶ homonymous hemianopia
- ▶ visual disturbance

Introduction

Neurofibromatosis type 1 (NF1) is an autosomal dominant genetic disorder caused by a mutation in the NF1 gene on the long arm of chromosome 17.¹ Patients with NF1 are more likely to have various vascular disorders such as aneurysms or arteriovenous fistula because of weakness in the arterial walls, which is caused by infiltration of

neurofibromatosis cells, and fragility of the internal elastic membrane due to higher concentration of spindle cells.^{2,3} Incidental detection of intracranial aneurysms by magnetic resonance imaging occurred in 5% of NF1 patients,⁴ but giant thrombotic aneurysm of the internal carotid artery (ICA) was not found. We treated a NF1 patient with a giant thrombotic ICA aneurysm presenting with rapid progression of visual disturbance.

received
April 19, 2022
accepted
December 13, 2022
accepted manuscript online
January 5, 2023

DOI <https://doi.org/10.1055/a-2008-4161>.
ISSN 2193-6358.

© 2023. The Author(s).

This is an open access article published by Thieme under the terms of the Creative Commons Attribution-NonDerivative-NonCommercial-License, permitting copying and reproduction so long as the original work is given appropriate credit. Contents may not be used for commercial purposes, or adapted, remixed, transformed or built upon. (<https://creativecommons.org/licenses/by-nc-nd/4.0/>)

Georg Thieme Verlag KG, Rüdigerstraße 14, 70469 Stuttgart, Germany

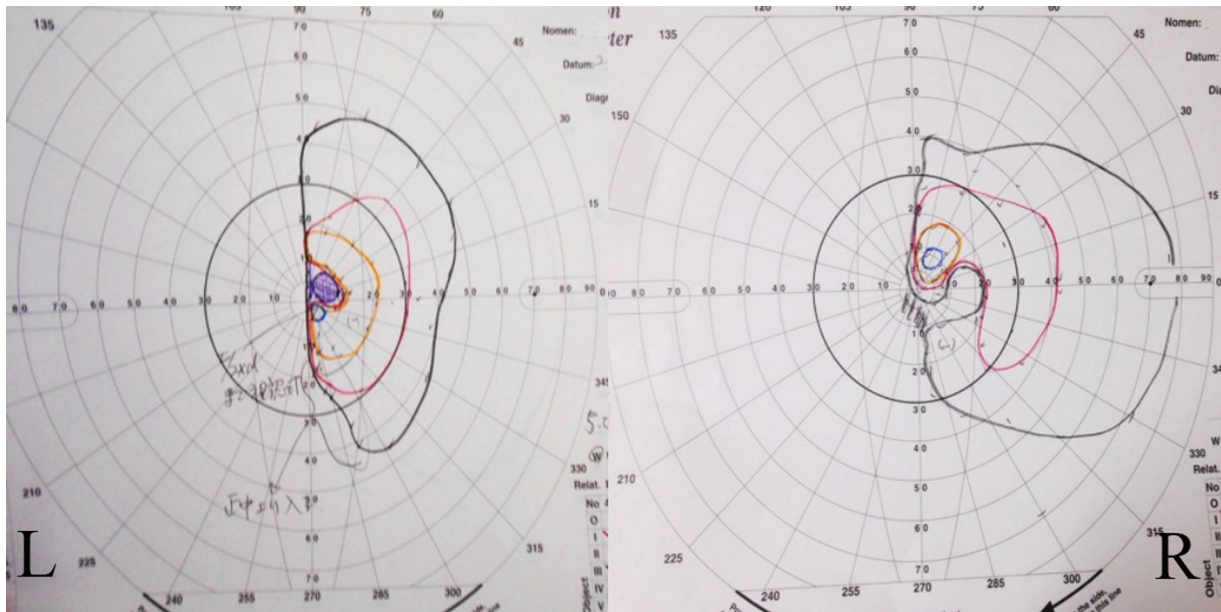


Fig. 1 Homonymous hemianopsia was confirmed at the preoperative examination.

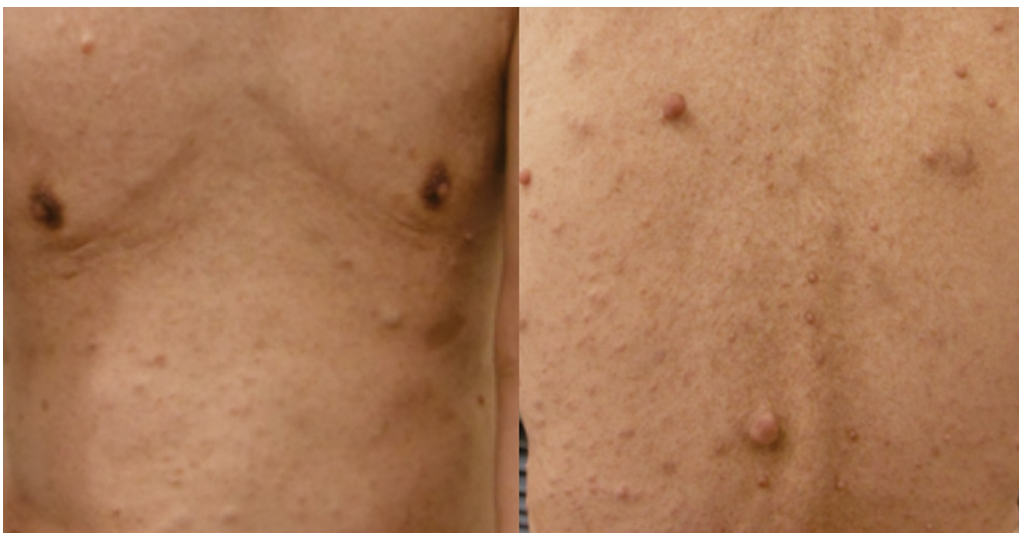

Fig. 2 Neurofibromatosis and café-au-lait spots were found on the front and back of the whole body and limbs.

Case Presentation

A 60-year-old man had complained of deteriorating visual loss and homonymous hemianopsia 6 months before (**► Fig. 1**). Physical examination found café-au-lait spots and neurofibromatosis over the entire body (**► Fig. 2**). His father and sister had similar skin nodules, so NF1 was diagnosed according to the diagnostic standard criteria. Contrast-enhanced computed tomography (CT) revealed a giant thrombosed aneurysm with 30 mm dome diameter on the anterior wall of the ICA located in the optic chiasma. The right middle cerebral artery (MCA) and the posterior communicating artery branched from the dome of the aneurysm (**► Fig. 3**). Calcifications around the aneurysm neck were very

severe (**► Fig. 4**), so we considered that direct neck clipping was probably impossible, and planned trapping of the ICA including the aneurysm neck after external carotid artery (ECA)-MCA bypass using the radial artery (RA) as an intergraft.

Surgical Treatment

He underwent trapping of the thrombosed aneurysm including the parent ICA after ECA-RA-M2 bypass. Frontotemporal craniotomy was first performed according to the standard practice, while simultaneously an RA was harvested and the left ECA was exposed. In advance, superficial temporal artery-M4 bypass was performed to avoid

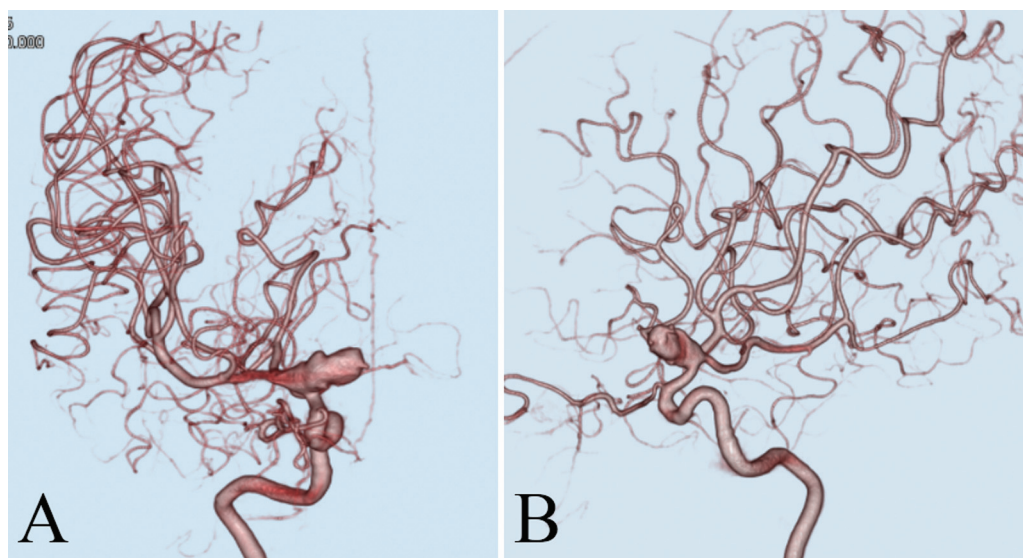


Fig. 3 (A) Preoperative angiogram, anteroposterior view, showing the internal carotid artery (ICA) anterior wall aneurysm with wide neck including the middle cerebral artery (MCA) and posterior communicating artery (PcomA). (B) Preoperative angiogram, lateral view, showing the ophthalmic artery branching off proximal to the aneurysm.

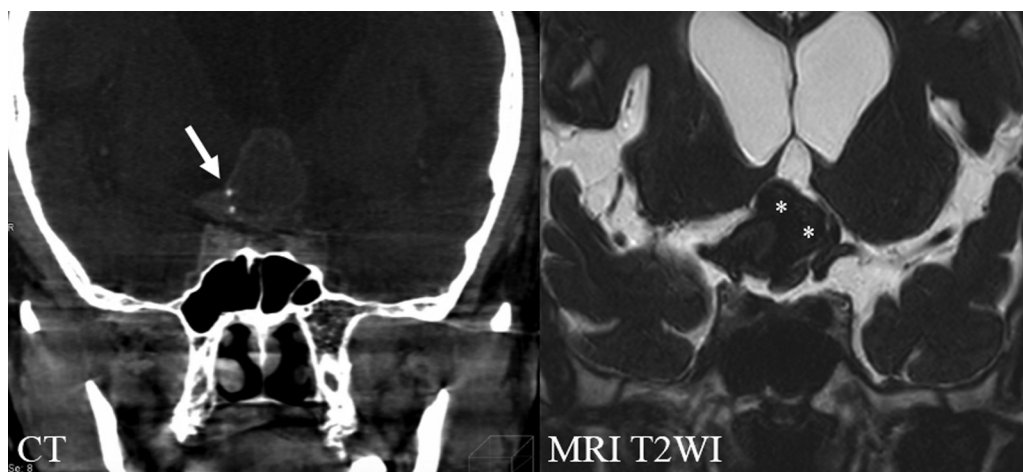

Fig. 4 Sagittal computed tomography (CT) scans demonstrating very severe calcifications (white arrow) around the aneurysm neck. Thrombotic aneurysm (asterisks) compressed and thinned the optic nerve.

cerebral ischemia during temporary occlusion of the M2 segment by trapping for the ECA-MCA bypass. The RA graft was placed from the ECA to the M2 segment, followed by occlusion of the aneurysm and ICA (→Fig. 5). Surgery was completed after confirming the absence of flow into the aneurysm and preserved blood flow through the ECA-M2 bypass using indocyanine green video angiography. No remnant aneurysm was found suggestive of vascular dissection. Contrast-enhanced CT performed 7 days after the operation showed no obstruction of the grafted blood vessels or recipients due to vascular dissection (→Fig. 6). Homonymous hemianopia persisted on the visual field test performed 14 days after surgery, but no exacerbation of visual field impairment was observed (→Fig. 7). No complications were found at 14 days after surgery. The postoperative course was uneventful.

Discussion

Neurofibromatosis was described by von Recklinghausen in 1882,⁵ and numerous studies have since been conducted. Vascular disease occurs with a frequency of approximately 3.6%.⁶ The mechanism of vascular fragility in NF1 patients involves thinning of the blood vessel wall due to direct infiltration of neurofibroma, ischemia of the blood vessel itself due to exclusion of feeding blood vessels, and thinning of the internal elastic membrane caused by spindle-shaped cells proliferating in the intima.^{2,3} Both direct and endovascular surgical procedures are difficult in NF1 patients due to such fragility of the arterial walls.^{4,7,8} However, the surgical procedures of the present case were managed without any problems such as dissecting vessels or occlusion of the RA graft.

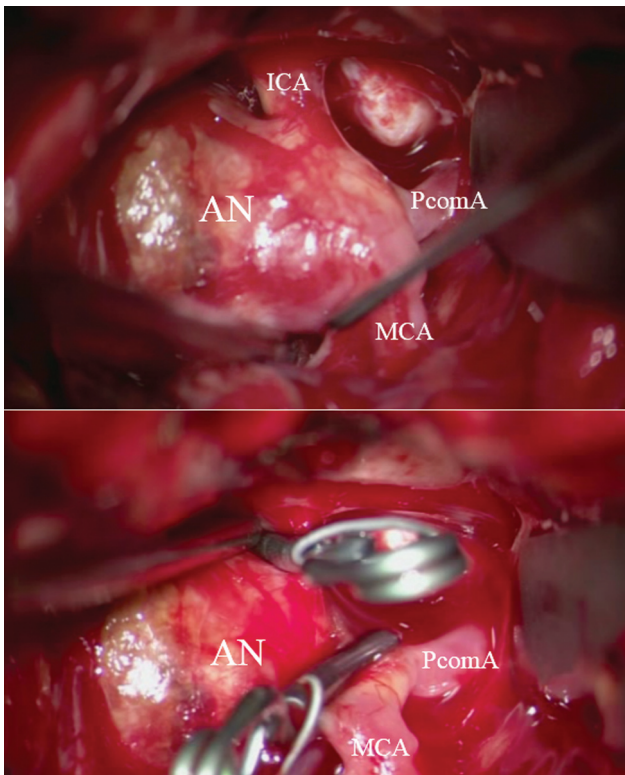


Fig. 5 Intraoperative photographs showing internal carotid artery (ICA) occlusion proximal to the aneurysm (upper), and trapping of the aneurysm with blood flow from the middle cerebral artery (MCA) to the posterior communicating artery (PcomA) (lower). AN indicates aneurysm.

Examination of the visual field and visual acuity test did not show any deterioration, and no other complication such as bleeding and ischemia, especially in areas of the

anterior choroidal artery, or cranial nerve disorders occurred. We consider that ECA-MCA bypass surgery using RA grafts is a safe and effective treatment method for giant thrombotic aneurysm associated with NF1.

Conclusion

ICA trapping with EC-M2 bypass using RA graft was effective for halting deteriorating visual loss and visual field defect in a NF1 patient with a thrombotic ICA aneurysm. Patients with NF1 tend to have fragility of the blood vessels, so surgical procedures such as anastomosis and grafting should be carefully performed to avoid dissection.

Ethics Approval and Consent to Participate
None.

Consent for Publication

The patient has consented to submission of this case report for journal publication, and we have obtained written informed consent.

Availability of Data and Materials
None.

Authors' Contributions

M.K. contributed to the concept of the manuscript and drafted the manuscript. N.O. and A.Y. revised the manuscript and contributed to the concept of manuscript. R.K. and T.K. contributed to the obtainment and interpretation of the clinical information. All authors have read and approved the manuscript.

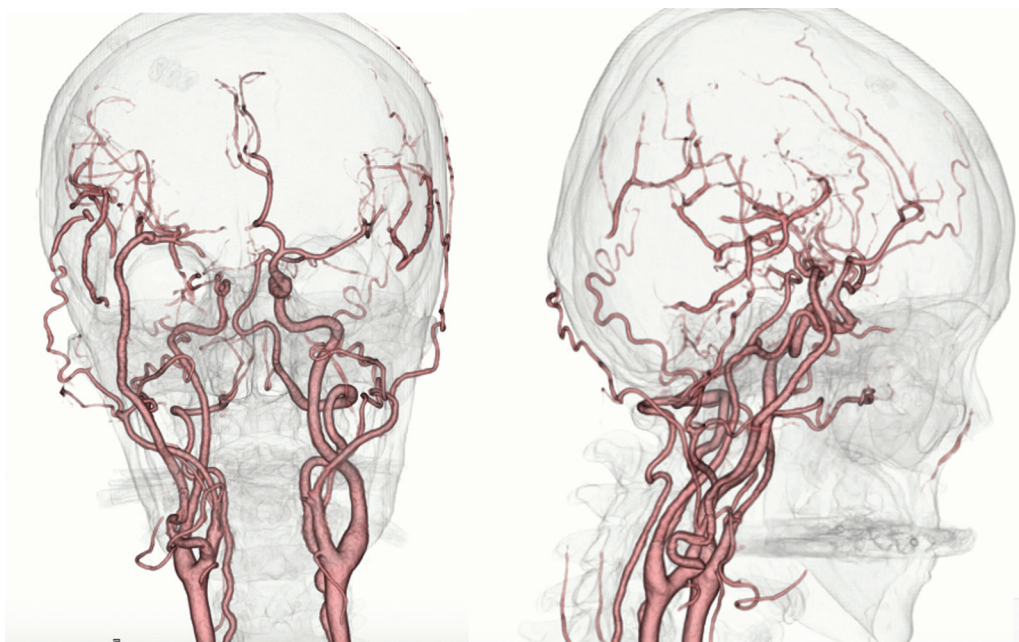


Fig. 6 Postoperative three-dimensional computed tomography (CT) angiograms showing that the external carotid (EC)-radial artery (RA)-M2 bypass was patent with disappearance of the aneurysmal shadow.

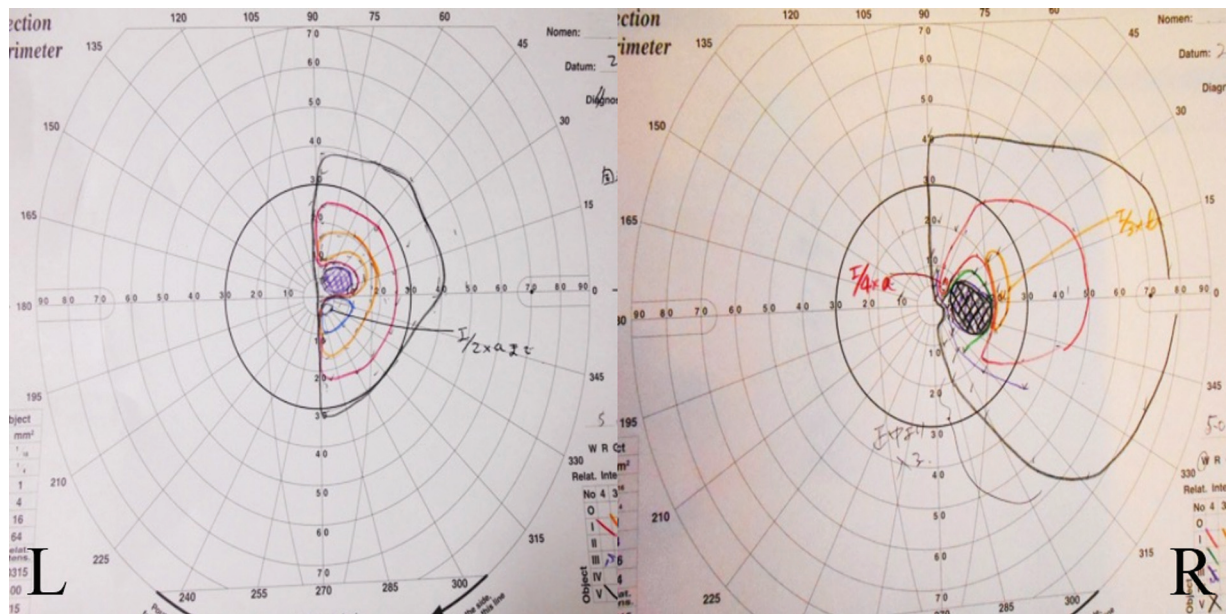


Fig. 7 Postoperative examination of the visual field showing no change, or no worsening of the visual field deficit.

Conflict of Interest

None declared.

Data Available Statement

The data that support the findings of this study are available on request from the corresponding author, M. K. The data are not publicly available due to their containing information that could compromise the privacy of research participants.

References

- 1 Viskochil D. Genetics of neurofibromatosis 1 and the NF1 gene. *J Child Neurol* 2002;17(08):562–570, discussion 571–572, 646–651
- 2 Leier CV, DeWan CJ, Anatasia LF. Fatal hemorrhage as a complication of neurofibromatosis. *Vasc Surg* 1972;6(02):98–101
- 3 Greene JF Jr, Fitzwater JE, Burgess J. Arterial lesions associated with neurofibromatosis. *Am J Clin Pathol* 1974;62(04):481–487
- 4 Schievink WI, Riedinger M, Maya MM. Frequency of incidental intracranial aneurysms in neurofibromatosis type 1. *Am J Med Genet A* 2005;134A(01):45–48
- 5 von Recklinghausen F. Ueber die multiplen Fibroma der Haut and ihre Beziehung zu den multiplen Neuomen. Berlin: August Hirschwald; 1882
- 6 Brasfield RD, Das Gupta TK. Von Recklinghausen's disease: a clinicopathological study. *Ann Surg* 1972;175(01):86–104
- 7 Gutarra F, Rodriguez Asensio J, Miceli M, Mareso E. Ruptured femoropopliteal artery aneurysms in von Recklinghausen neurofibromatosis. *J Vasc Surg* 2007;46(04):808–811
- 8 Arai K, Sanada J, Kurozumi A, Watanabe T, Matsui O. Spontaneous hemothorax in neurofibromatosis treated with percutaneous embolization. *Cardiovasc Intervent Radiol* 2007;30(03):477–479