

Endoscopic entero-enteral bypass to treat postsurgical benign complications of hepatico-jejunostomy: Update of a 7-year single-center experience

OPEN
ACCESS

Authors

Massimiliano Mutignani¹, Edoardo Forti¹, Francesco Pugliese¹, Marcello Cintolo¹, Giulia Bonato¹, Marianna Bravo¹, Lorenzo Dioscoridi¹

Institutions

1 Digestive and Interventional Endoscopy Unit, Niguarda-Ca' Granda Hospital, Milan, Italy

submitted 10.8.2022

accepted after revision 1.2.2023

Bibliography

Endosc Int Open 2023; 11: E394–E400

DOI 10.1055/a-2032-3077

ISSN 2364-3722

© 2023. The Author(s).

This is an open access article published by Thieme under the terms of the Creative Commons Attribution-NonDerivative-NonCommercial License, permitting copying and reproduction so long as the original work is given appropriate credit. Contents may not be used for commercial purposes, or adapted, remixed, transformed or built upon. (<https://creativecommons.org/licenses/by-nc-nd/4.0/>)

Georg Thieme Verlag KG, Rüdigerstraße 14,
70469 Stuttgart, Germany

Corresponding author

Massimiliano Mutignani, Digestive and Interventional Endoscopy Unit, Niguarda Ca' Granda Hospital, Piazza dell'Ospedale Maggiore 3, 20162 Milano, Italy
Fax: +39-02-64442911
massimiliano.mutignani@ospedaleniguarda.it

ABSTRACT

Background and study aims Since 2014, we have been using a new endoscopic approach to improve management of biliary adverse events (BAEs) after bilio-digestive anastomosis. We provide an update about our experience at 7 years.

Patients and methods Patients with BAEs on hepatico-jejunostomy underwent entero-enteral endoscopic by-pass (EEEEB) creation between the duodenal/gastric wall and the biliary jejunal loop. Evaluation of results during our seven-year experience was performed.

Results Eighty consecutive patients (32 patients from Jan 2014 to Dec 2017 and 48 patients from Jan 2018 to Jan 2021) underwent EEEB, which was successful in all but one patient. The cumulative AEs rate was 32%. Endoscopic retrograde cholangiography (ERC) through the EEEB successfully treated all types of BAEs in these patients. Cumulative disease recurrence was 3.8% (three patients) and was retreated through the EEEB.

Conclusions The update of our experience with EEEB confirmed that in patients with BAEs after bilio-digestive anastomosis, EEEB allows successful long-term treatment of different BAEs in a tertiary referral center with an acceptable rate of related AEs.

Introduction

Endoscopic treatment has been described as a minimally invasive approach for management of patients with surgically altered anatomy and biliary adverse events (BAEs) with two critical issues: (1) ability to reach the biliary anastomosis; and (2) performance of an effective therapeutic procedure. Duodenoscopes, gastroscopes and pediatric colonoscopes have all been used, with a poor rate of biliary anastomosis achievement [1]. Enteroscopes (short, long, single- or double-balloon) [1–5] have also been utilized, with an overall technical success rate of about 76%. Finally, a high success rate (around 90%) has also been described for the EUS-guided approach, but still with high rates of morbidity (18%–50%) and mortality (1.5%) [6, 7].

The possibility of performing endoscopic entero-enteral bypass (EEEEB) has been explored in patients with bilio-digestive anastomosis and BAEs [8–11], but data are scant and with limited follow-up. In 2019, our group performed a study to retrospectively evaluate the safety, feasibility, and effectiveness of EEEB for the management of BAEs in 32 patients with Roux-en-Y reconstruction or after a Whipple procedure. We reported recurrence of BAE in two patients and a cumulative AE rate of 18.7% during a mean follow-up of 34.5 ± 23.5 months [12]. We performed this update study to assess the long-term (1–7 years) effectiveness of EEEB for BAEs.

Patients and methods

Data on all consecutive patients with surgically altered anatomy who underwent EEEB between January 2014 and January 2021 were retrospectively retrieved from a prospectively collected database (Niguarda Ethical Committee, n. 43r/2021). Indications for performing EEEB were the same as in our previous study: (1) inability to endoscopically reach the biliary site using 140 cm pediatric colonoscope; and (2) pre-procedure high probability of the need for complex biliary procedures defined as presence of multiple strictures involving both the common bile duct and segmental ducts, (usually related to ischemic colangiopathy) or presence of multiple duct anastomosis (i. e. bi-duct bilio-digestive anastomosis). We do not use enteroscopes in the setting of ERC in altered anatomy to treat complications of hepaticojejunostomy. Definition and severity of the AEs were based on the “AGREE” classification by Nass KJ et al. [13]. Exclusion criteria for the present study were surgically altered anatomy without hepaticojejunostomy, <1 year follow-up after EEEB, presence of malignant biliary stricture (excluded by dedicated imaging, i. e. computed tomography and/or magnetic resonance imaging with contrast) and no indication for EEEB.

To perform the access to the biliary jejunal loop (to recognize it under EUS), four different types of puncture techniques were used: 1) percutaneous transhepatic biliary drainage (PTBD) performed before EEEB session; 2) transgastric EUS-guided puncture of the left hepatic duct; 3) direct EUS-guided puncture of the jejunal loop (recognizing the anastomotic area both under EUS-guide for the proximity to the hepatic hilum and under fluoroscopic check for the position of echoendoscope tip); and 4) placement of a 7F endoscopic tube into the jejunal loop in a retrograde manner.

To create EEEB, Hot Axios Electrocautery and Delivery system (Boston Scientific Corp.) (15-mm diameter, 10-mm length) both under EUS and fluoroscopic guidance was used. The use of a Nagi stent in our first experience was abandoned in favor of the Hot Axios system.

ERC was performed after EEEB during the same session if the axis of the enteral bypass allowed an in-line approach to the bilio-digestive anastomosis. In all other cases, the ERC was done 1 week later to allow for anastomosis consolidation [12]. ERC was generally performed using a 3.8-mm operative channel pediatric colonoscope (ED-127, GS-125, Pentax Europe). Postprocedure management did not change and first endoscopic follow-up was scheduled 6 months after the index procedure in the setting of hepaticojejunostomy. Enteral stents for EEEB were generally removed at 12 months after EEEB creation in asymptomatic patients.

The primary outcome was to evaluate the long-term efficacy of the method defined as absence of strictures and symptom recurrence at >1 year follow-up. BAE recurrence was documented based on new onset of symptoms and new changes in of blood tests for cholestasis. Magnetic resonance cholangiopancreatography was performed in uncertain cases. BAE recurrence was finally always confirmed at cholangiography.

Secondary outcomes were: 1) technical success rate defined as the creation of EEEB and the treatment of BAE through it;

2) clinical success rate defined as resolution of BAE associated with improvement of clinical status; and 3) AEs related to EEEB and ERC. AEs were defined as early if occur within 1 week after EEEB.

Partial migration of the EEEB stent was defined as asymmetrical dislodgement of the flairs on the jejunal or gastric edges close to complete migration.

Complete migration was defined as the absence of the enteral stent at the endoscopic check.

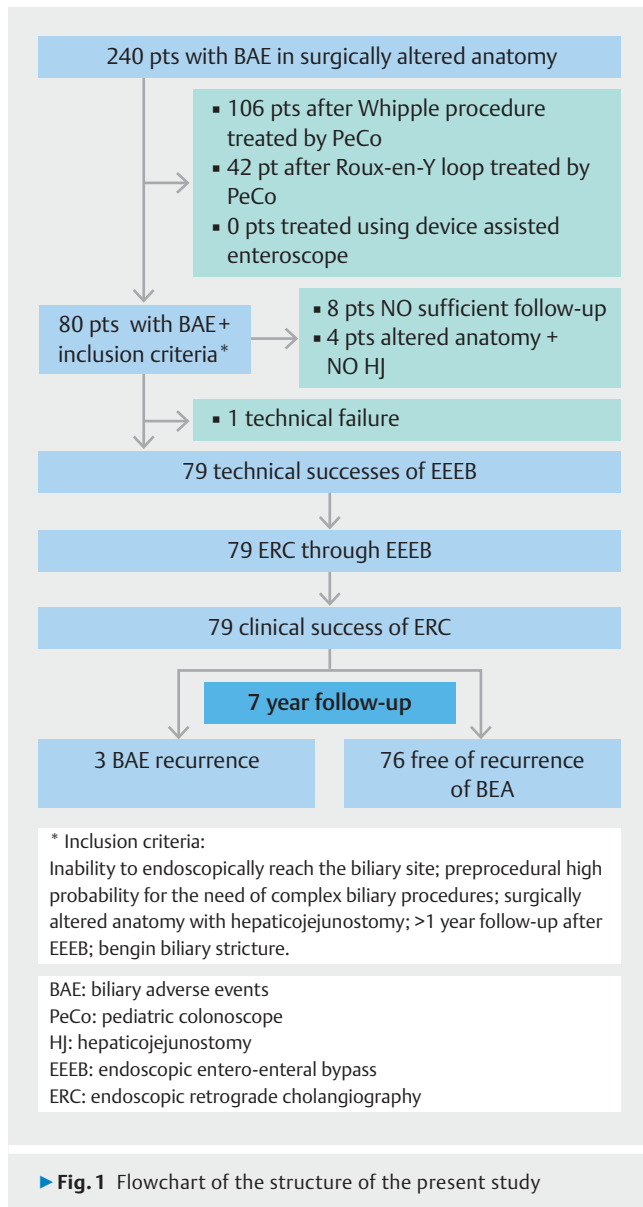
Quantitative variables were described with mean value and standard deviation. Categorical values were described with frequencies (%).

Results

During the study period, 80 consecutive patients underwent EEEB (32 patients from January 2014 to December 2017 plus 48 patients from January 2018 to January 2021). Our first case series of 32 patients was published in 2019 [12]. A flowchart of the study structure is shown in ► **Fig. 1**. Four patients were excluded from the present study because they underwent surgery without creation of hepaticojejunostomy (2 underwent total gastrectomy with Roux-en-Y reconstruction, 1 bariatric gastric bypass and 1 subtotal gastrectomy with Billroth II reconstruction). The other eight patients with hepaticojejunostomy underwent EEEB before March 2022 but were excluded from the present study because of lack of sufficient follow-up. The other 42 patients with Roux-en-Y reconstruction were treated reaching the papilla/hepaticojejunostomy directly using a pediatric colonoscope and were excluded from the present study because they did not undergo EEEB. In the other 106 excluded patients, complications of biliary anastomosis after a Whipple procedure were treated retrograde using a pediatric colonoscope. No patient was treated by device-assisted enteroscopy because of the still low efficacy of treatment and scant long-term clinical outcomes fully demonstrated in this setting.

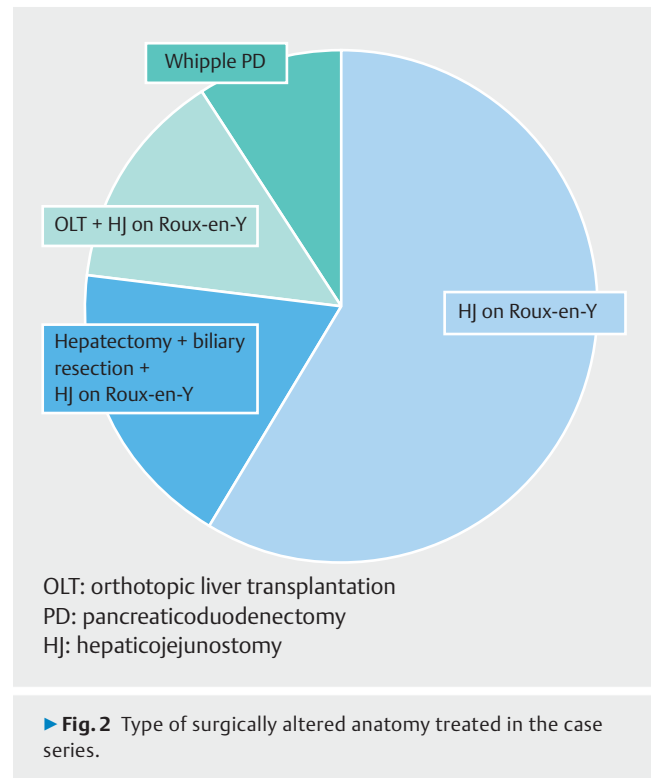
The type of surgically altered anatomy is shown in ► **Fig. 2**. Hepaticojejunostomy on Roux-en-Y loop was the most common type, accounting for 91% of cases. Indications were biliary single-duct anastomotic stricture in 51 (74%), biliary multiple-ducts anastomotic strictures in four (5.7%), uncovered self-expandable metal stents entrapment (placed in other hospitals by interventional radiologists) in four (5.7%), choledocolithiasis in five (7.2%), recurrent cholangitis in two (2.9%), dehiscence of biliary anastomosis in one case (1.4%), external biliary fistula after left hepatectomy in a previous orthotopic liver transplantation (OLT) in one (1.4%) and biliary fistula after pancreaticoduodenectomy in one (1.4%). Six patients with single-duct anastomotic stricture had undergone orthotopic liver transplantation (OLT) on Roux-en-Y loop, five of whom had a second liver transplantation after failure of the first OLT.

In our first series, PTBD was previously positioned in 29 patients, while in other three patients a 7F catheter was used to allow EEEB creation. Of the new 48 cases, the puncture techniques were PTBD in 11 patients, transgastric EUS-guided approach in 16 patients, direct EUS-guided puncture in eight and 7F endoscopic tube in 13 patients. Overall results of our up-



dated series are presented in ► **Table 1**. EEEB was successfully created in 79 of the 80 patients (98.7%), with one failure due to difficulty in maintaining correct echoendoscope position. A 15-mm and 10-mm Hot Axios electrocautery system was used in all updated cases.

ERC could be performed in all patients, in one session (immediately after EEEB creation) in 57 patients. In one case, the hepaticojejunostomy was far from the site of EEEB and not reachable retrogradely using a pediatric colonoscope due to strict angulation of the biliary jejunal loop; in this case, ERC were performed “from a distance” using standard devices. PTBD was removed immediately after ERC in 36 patients. In the remaining four cases the PTBD was left in situ to perform bile duct washing in case of multiple and massive biliary lithiasis associated with the anastomotic stricture (3 patients) and in the case of the still unreachable anastomosis during the 6-month anastomotic stenting to have a second way to assist

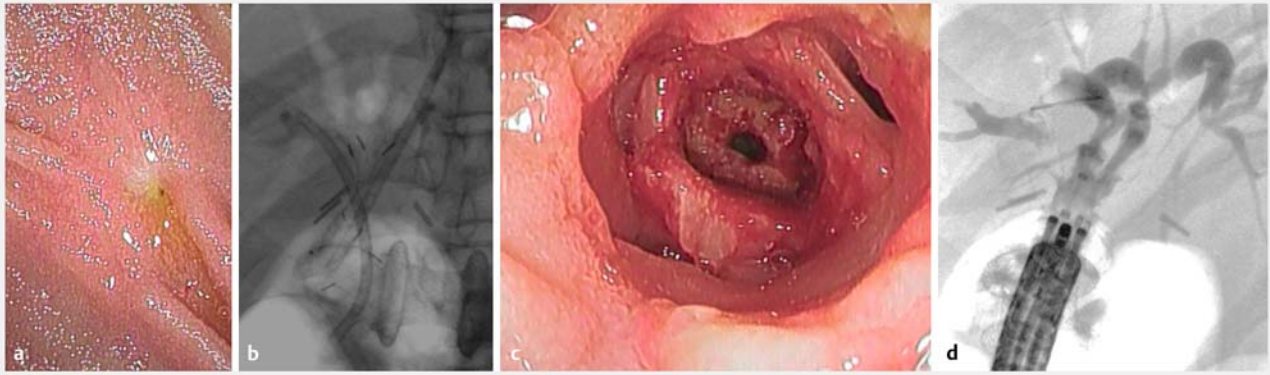


► **Table 1** Main results of the series of patients treated with EEEB-ERC.

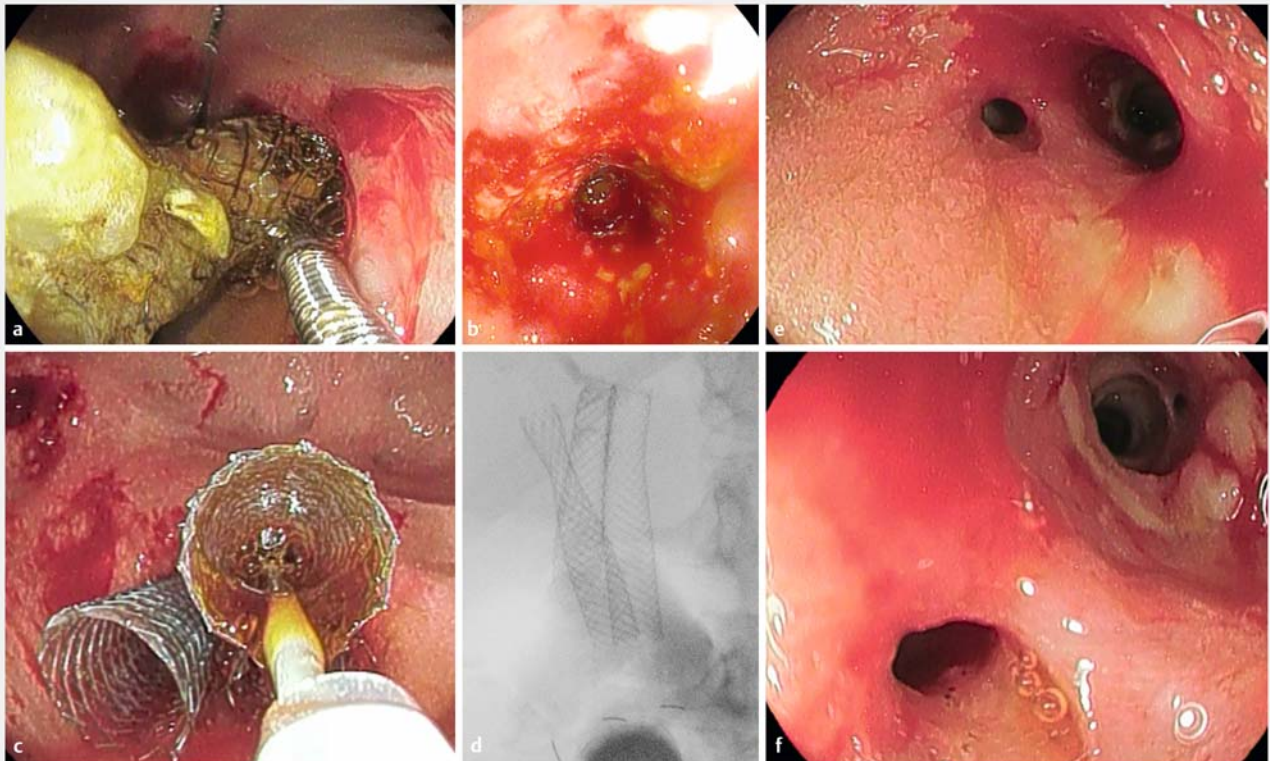
Total number of patients EEEB (2014–2021)	80
Technical success	98.7%
Clinical success	98.7%
Recurrence rate	3.8%
Morbidity	32%
Mortality	0%
Mean follow-up (years)	4

EEEEB-ERC, entero-ental endoscopic bypass endoscopic retrograde cholangiography.

with stent removal (1 case). A total of 14 AEs were reported considering the whole series: seven early and seven late as defined above. Five early AEs were reported in the new case series (3 grade I, 2 grade III according to AGREE classification) plus two cases reported in the previous case series (1 moderate self-bleeding, 1 partial intraprocedural stent displacement): a partial EEEB stent displacement occurred (where second stent was needed to maintain the anastomosis opened), two patients developed moderate self-limited bleeding, one patient developed acute respiratory failure (that was managed with noninvasive ventilation), one case of asymptomatic intraperitoneal free air under diaphragm during ERC (probably due to a partial detachment of the enteral loops). The EEEB allowed performance of successful and effective different types of treatment (► **Fig. 3**, ► **Fig. 4**, ► **Fig. 5**).



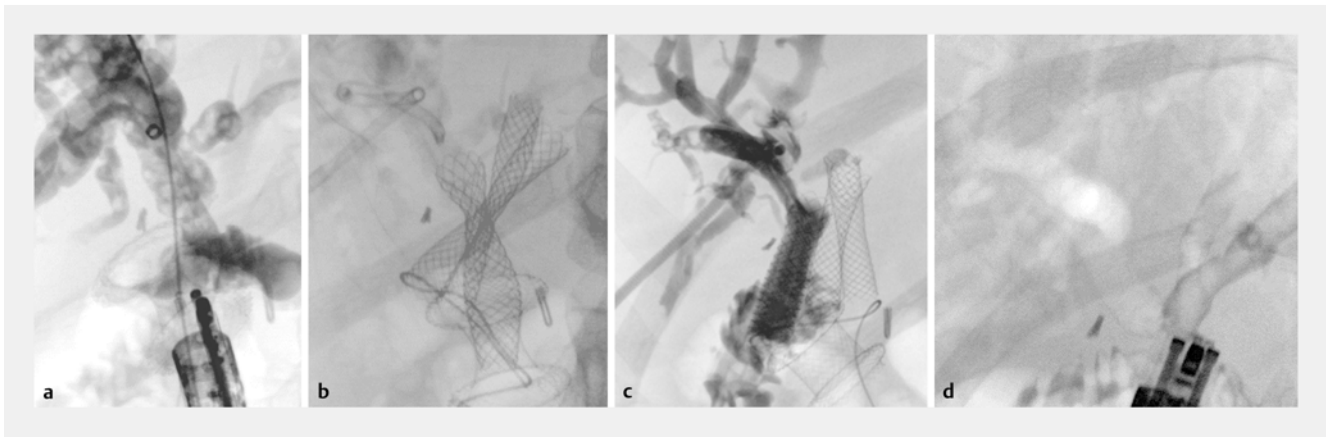
► **Fig. 3** Hepaticojejunostomy stricture treated through EEB. **a** Endoscopic view of the anastomotic stricture. **b** Fluoroscopic view of the endoscopic treatment placing two 8.5 F 5-cm plastic stent (in in the posterior right hepatic duct and one in the left duct) and one 12-mm, 2-cm fc-SEMS (Nagi stent). **c** Endoscopic view of the enlarged anastomosis at 6 months, immediately after stent removal. **d** Fluoroscopic check after stent removal.



► **Fig. 4** Management of entrapped uncovered metal stent placed through hepaticojejunostomy. **a** Endoscopic view of the stent and foreign body forceps used to remove it. **b** Endoscopic view of the hepaticojejunostomy immediately after stent removal showing residual stricture. **c** Stenting performed using three 8-mm, 3-cm fc-SEMS (Wallflex) to avoid recurrent stricture. **d** Fluoroscopic view of the three fc-SEMS positioned through EEB. **e, f** Endoscopic view of the hepaticojejunostomy after stents removal 6 months after the index procedure.

In the previous study, four EEB long-term AEs were reported (grade III according to AGREE classification): spontaneous EEB stent displacement, three complete and one partial, which were solved with insertion of another stent through the stent. In the new case series, there were two more spontaneous

EEB stent dislodgements, one complete and one partial, which were resolved with insertion of another stent as before. We did not report any AEs related to biliary stent placement. In three patients, considering the whole series, biliary stents had spontaneously migrated at the time of the second endoscopic



► **Fig. 5** Hepaticojejunostomy stricture associated with multiple biliary stones treated through EEEB after percutaneous transhepatic trans-anastomotic biliary drainage. **a** Fluoroscopic view of EEEB creation in direct line to the anastomosis. **b** Fluoroscopic view of the treatment positioning two 6-mm, 2-cm fc-SEMS (in the left hepatic duct and anterior right duct) and one 8-mm, 4-cm fc-SEMS (in the posterior right hepatic duct) through anastomotic stricture. **c** Fluoroscopic view at 1 week with biliary stent in site and PTBD left in site for biliary cleansing using sterile saline. **d** Fluoroscopic view after stent removal at 6 months showing massive aerobilia in the whole biliary tree.

check. No differences in timing of enteral stent removal were recorded (12.7 ± 5.4 months vs 12.3 ± 5.5 months) and there were no AEs related to removal. Seven cases of mucosal pressure ulcers without perforation were observed at the endoscopic check after removal. No difference in terms of migration rate was noted if ERC and EEEB were performed during the same session or not.

Mean follow-up of patients was 4 ± 3 years. Two recurrent BAEs occurred in the previous study, one case of choledocolithiasis and one case of biliary stricture; in the updated period (2018–2021), one more recurrence of biliary stricture was reported. Recurrences were successfully retreated through the EEEB. Mean time of recurrence since the first treatment was 14.3 months (12 and 16 months for stricture recurrence; 15 months for choledocolithiasis). During the follow-up period, three patients died: one because of recurrence of previous neoplasm (no cancer recurrence was observed at the level of hepaticojejunostomy), one because of hepatic insufficiency post-OLT due to ischemic cholangiopathy and one due to sequelae of ischemic neurological acute accident. No deaths related to EEEB were reported.

Discussion

After the few successful cases in the first study, we continued to use this technique for all patients with benign BAEs following Roux-en-Y reconstruction or after a Whipple procedure, in whom the biliary anastomosis could not be reached endoscopically or the pre-procedure probability for the need of complex biliary procedures was high.

Indications for the procedure have increased since the previous experience: EEEB also has successfully been performed in two cases of biliary anastomotic dehiscence in which both redo surgery and interventional radiology failed to achieve clinical success because of the coexistence of necrotizing infected tissue in the intestinal loop around the anastomotic area.

The approach to perform EEEB changed between the two periods in favor of EUS-guided techniques.

In our updated experience, the transgastric approach and direct puncture of the jejunal loop both seem to be safe.

Unfortunately, antegrade approach for performing EUS-hepaticogastrostomy alone cannot overcome the limitations of interventional radiology and still is associated with high rates of morbidity and mortality [6–7].

The transition from Nagi stent placement to Hot Axios system has made the procedure safer and faster. However, the instability of position with the echoendoscope and the incorrect opening (just in the middle between the “biliary loop” and the alimentary loop under fluoroscopy) lead to technical failure and procedural AEs. Moreover, the previous more challenging experience using Nagi stent has improved the operators’ skills and their confidence in using the Hot Axios system for EEEB creation.

EEEB was successfully performed in all but one patient from the previous study; no technical failures were experienced using the Hot Axios system. The rate of procedure-related AEs remained acceptable (7,2%) and they were related to the creation of the enteral anastomosis (self-limited bleeding due to involuntary puncture of enteral wall vessels, free intraperitoneal air due to the timing of stent release). The strategy for use of a large-bore fully-covered SEMSs was successful in terms of recurrence rate: the jejunal portion of the anastomotic stricture likely is better dilated by SEMS than multiple plastic stents [12]. The fc-SEMS were “hand-made” tailored in the present study because the length of the commercially available stents was too long to avoid obstruction of the hepatic hilum on one side or mucosal ulcer on the jejunal edge. The stent was cut with sterile scissors once freed from the delivery system. At the end, it was reinserted in the delivery system ready to be placed at the site of the anastomosis. This approach was necessary while improvement in the commercially available stents is awaited.

The recurrence rate remained low in the extension of follow-up. Gradual and long-lasting dilation of the stricture produced by SEMs likely is effective in achieving sufficient long-term control for fibrotic healing of the anastomosis. This is probably related to the fact that the bilio-digestive anastomotic stricture is a compound stenosis (half biliary component and half enteral).

If the biliary part also can be correctly dilated pneumatically, the enteral edge does not respond properly to this type of dilation, as happened with a pure enteral stricture. This is one of the main reasons for scant clinical results from long-term follow-up of interventional radiology in this setting [14], as we discussed in our previous paper [12]. Considering all the cases in which a PTBD was present before EEEB creation, all 40 patients met the inclusion criteria and had anastomotic stricture. In all the cases, PTBD did not provide complete drainage of the biliary tree and only two possible therapeutic chances were proposed: 1) iterative pneumatic dilation of the anastomosis in case of short common bile duct; and 2) placement of biliary percutaneous stents. We have already discussed the long-term effects of pneumatic dilation in this setting, which is associated with a high percentage of major complications [15]. Furthermore, placement of percutaneous stents also has the limitation of use of long stents, which are associated with development of hyperplastic tissue and secondary sludge on the biliary side and risk of jejunal decubitus, perforation and higher risk of migration on the enteral side of the anastomosis. In comparison with EEEB, the percutaneous approach requires many punctures to treat multiple anastomotic strictures and percutaneous stent removal may be more difficult than an endoscopic one. Moreover, in case of entrapped biliary stents, the possibility of managing this AE on the enteral edge led to better treatment due to shorter flogistic ingrowth on this side than on the biliary one.

Long-term EEEB patency has been confirmed in the present study. Spontaneous stent migration is the main long-term AE of EEEB. In the majority of cases, the entero-ental bypass remained patent; in a few cases, partial migration can lead to one flair of the stent being buried, usually through the gastric wall (due to flogistic reactions). In the latter cases, we were able to save the endoscopic anastomosis by placing another stent within the previous one [16]. Pressure mucosal ulcers at the site of the flairs at the time of enteral stent removal did not always require any further treatment. Considering the AEs in their entirety, they should be considered mild because early ones were resolved during the same endoscopic session and did not require further procedures and grade III AEs were stratified in this manner only because an additional endoscopic procedure was needed.

Limitations of the study are its retrospective nature, which does not eliminate the chance of bias; the heterogeneity of the treated patients; and the single-center nature of the study, which does not allow for reproducibility of the procedure.

Conclusions

In conclusion, the present update study confirmed that EEEB in patients with hepaticojejunostomy is safe, feasible, and allows for very effective treatment of different BAEs, based on more than 7 years of experience and research in this field.

Acknowledgments

The authors would like to thank Dr Irene Cottone, datamanager of our endoscopy service, for her efforts in updating the data of our case series.

Competing interests

Mutignani M is proctor for Boston Scientific. All the other authors declare no conflict of interest.

References

- [1] Itokawa F, Itoi T, Ishii K et al. Single- and double-balloon enteroscopy-assisted endoscopic retrograde cholangiopancreatography in patients with Roux-en-Y plus hepaticojejunostomy anastomosis and Whipple resection. *Dig Endosc* 2014; 26: 136–143
- [2] Tomoda T, Tsutsumi K, Okada H et al. Comparison between Roux-en-Y patients with and without gastrectomy during endoscopic retrograde cholangiopancreatography using a short double-balloon enteroscope. *Dig Endosc* 2015; 27: 775
- [3] Zouhairi ME, Watson JB, Desai SV et al. Rotational assisted endoscopic retrograde cholangiopancreatography in patients with reconstructive gastrointestinal surgical anatomy. *World J Gastrointest Endosc* 2015; 7: 278–282
- [4] Blanco-Velasco G, Chavez-Pina H. Treatment of a bile duct leak with ERCP double-balloon enteroscopy in a patient with Roux-en-Y reconstruction. *Endoscopy* 2016; 48: E197–E198
- [5] Kedia P, Kumta NA, Sharaiha R et al. Bypassing the bypass: EUS-directed transgastric ERCP for Roux-en-Y anatomy. *Gastrointest Endosc* 2015; 81: 223–224
- [6] Giovannini M, Bories E, Napoleon B et al. 855 multicentric randomized phase II study: percutaneous biliary drainage vs EUS guided biliary drainage: results of the intermediate analysis. *Gastrointest Endosc* 2015; 81: AB174
- [7] Khan MA, Baron TH, Kamal F et al. Efficacy of self-expandable metal stents in management of benign biliary strictures and comparison with multiple plastic stents: a meta-analysis. *Endoscopy* 2017; 49: 682–694
- [8] Mutignani M, Manta R, Pugliese F et al. Endoscopic ultrasound-guided duodenojejunal anastomosis to treat postsurgical Roux-en-Y hepaticojejunostomy stricture: a dream or a reality? *Endoscopy* 2015; 47: E350–E351
- [9] Majmudar K, Wagh MS. EUS-guided jejuno-jejunoscopy with lumen-apposing metal stent for complete jejunal obstruction after gastric bypass. *Gastrointest Endosc* 2016; 84: 853–854
- [10] Tyberg A, Perez-Miranda M, Sanchez-Ocana R et al. Endoscopic ultrasound-guided gastrojejunostomy with lumen-apposing metal stent: a multicenter, international experience. *Endosc Int Open* 2016; 4: E276–E281

- [11] Ngamreungphong S, Nieto J, Kunda R et al. Endoscopic ultrasound-guided creation of a transgastric fistula for the management of hepatobiliary disease in patients with Roux-en-Y gastric bypass. *Endoscopy* 2017; 49: 549–552
- [12] Mutignani M, Forti E, Larghi A et al. Endoscopic entero-enteral bypass: an effective new approach to the treatment of postsurgical complications of hepaticojejunostomy. *Endoscopy* 2019; 51: 1146–1150
- [13] Nass KJ, Zwager LW, van der Vlugt M et al. Novel classification for adverse events in GI endoscopy: the AGREE classification. *Gastrointest Endosc* 2022; 95: 1078–1085.e8
- [14] Cantwell CP, Pena CS, Gervais DA et al. Thirty years' experience with balloon dilation of benign postoperative biliary strictures: long-term outcomes. *Radiology* 2008; 249: 1050–1057
- [15] Dhondt E, Vanlangenhove P, Van Vlierberghe H et al. Benign anastomotic biliary strictures untreatable by ERCP: a novel percutaneous balloon dilatation technique avoiding indwelling catheters. *Eur Radiol* 2019; 29: 636–644
- [16] Dioscoridi L, Forti E, Pugliese F et al. Buried lumen-apposing metal stent after gastrojejunal bypass. *Endoscopy* 2020; 52: E134–E135