Thieme

Posterior Lamellar Corneal Graft (DSAEK) in an Aphakic and Congenital Aniridic Single Eye: A Case Report Presenting a New Surgical Procedure

OPEN ACCESS

Posteriore lamelläre Hornhauttransplantation (DSAEK) in einem aphakischen und angeborenen Aniridikum-Single-Eye: ein Fallbericht, der einen neuen chirurgischen Eingriff präsentiert

Background/Introduction

Trends in types of corneal grafts have hugely changed during the last 10 years [1] and primary or secondary corneal endothelial decompensation is the main cause of posterior lamellar grafts. DMEK (Descemet Membrane Endothelial Keratoplasty) surgery became more popular because clinical data shows many advantages: better UCVA (Uncorrected Visual Acuity) or CVA (Corrected Visual Acuity), an acceptable amount of endothelial cells lost, lower allograft rejection rate compared to Descemet stripping endothelial keratoplasty (DSAEK) and PK (Penetrating Keratoplasty) [2], and a better survival rate after 5 years (97.5%) compared to DSAEK (76.45%) and PK (54.6%) [3].

Congenital aniridia is a rare ocular disease (1:60 000 to 1:90 000) [4–6]. The presence of an aniridia-associated keratopathy (AAK) increases with age and can contribute to visual impairment. In these cases, endothelial cell loss is usually secondary to cataract and/or glaucoma surgery [7]; however, it could also be primary. Penetrating keratoplasty has a poor prognosis because of the recurrence of the AAK and graft rejection occurs in 64% of the cases [8, 9].

In this case report, we propose to perform a new surgical procedure with a modified shape DSAEK to treat a congenital aniridic and aphakic single eye with endothelial cell decompensation.

History and Signs

We present a 74-year-old Caucasian woman with a single congenital aniridic and secondary aphakic right eye. She was the only child with congenital aniridia in a family of eight children. Of her own two children, one had the disease. Medical history for the right eye included intracapsular cataract extraction and deep sclerectomy and for the left eye, extracapsular cataract extraction and perforating ocular trauma followed by an evisceration. Preoperative BUVA (Best Uncorrected Visual Acuity) was limited to 0.02 (20/1000) and BCAV (Best Corrected Visual Acuity) was evaluated to 0.063 (20/320) and had been 0.1 (20/200) 5 years before (▶ **Fig. 1**). The thinnest pachymetry in the 8 mm of the central cornea (US and light) had increased from 479 µm in 2017 to 920 µm in 2020. The patient reported subjectively a decrease in her vision. Slit lamp evaluation was able to identify remaining vitreous in the vicinity of the endothelium that could play a role in the endothelial cell lost. The cornea was free of neovascularization (no AAK) during the follow-up (▶ **Fig. 1**), with a total hypoesthesia. Fundus was not assessable because of the corneal edema. Intraocular pressure was 13 mmHg.

Therapy and Outcome

Surgery was performed under general anesthesia according to a technique reported by Muraine et al. in 2019 at the French Society of Ophthalmology annual congress. The preparation of the DSAEK with a Moria Microkeratome included a special cutting of the graft with two "ears" that were placed in two side ports and stitched (▶ **Fig. 2**). These two fixation points were used to stabilize the graft during its insertion and maintain it during the tamponade with a mix of air and SF_6 (50/50%) for 24 hours in the supine position (▶ **Fig. 3**). The thickness of the graft was 135 µm at its thinnest point, with a diameter of 7.75 mm (▶ **Fig. 2**). This eye experienced a postoperative "shut down" for 1 month (low pressure evaluated with fin-

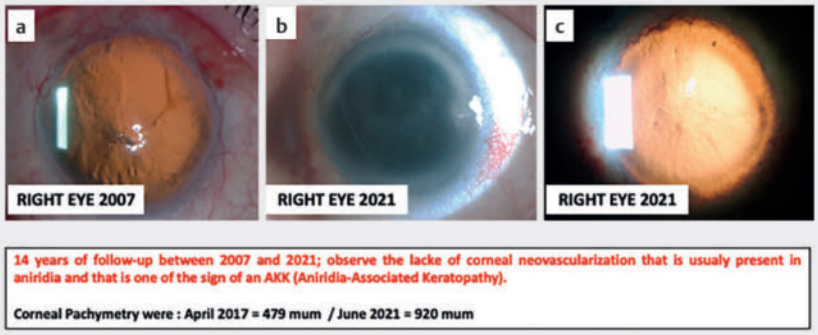

▶ **Fig. 1** **a** Right eye in 2007, 14 years before posterior lamellar graft was performed. Aniridia and aphakia were not associated with AAK (aniridia-associated keratopathy). The pachymetry was 479 microns. Light scattering with the slit lamp showing corneal transparency with no vessels in the corneal stroma. **b** Right eye in 2021, just before the surgery. Pachymetry has increased up to 920 microns at the thinnest point measured in the central 8 mm of the cornea. **c** Light scattering with the slit lamp just before the surgery showing that AKK is still absent.



▶ **Fig. 2** **a** Shape of the DSAEK with the two "ears" prepared to stitch the graft in the corneal stroma and stabilize it during postoperative 24 hours tamponade. **b** In green, the DSAEK and the two "ears" placed in the corneal stroma. In yellow, sagittal cut of a cornea. **c** Cutting the donor on a Moria anterior artificial anterior chamber with a Moria Microkeratome. **d** Putting the donor endothelial cells side up on a 7.75 Moria trephine. **e** Breaking the trephine blade in two spots to create the "ears". **f** Cutting the donor with the trephine. **g** Creating the two "ears" on the donor with an 11 blade. **h** Creating the two "ears" on the donor with an 11 blade. **i** Creating the two "ears" on the donor with an 11 blade. **j** Removing the graft from the corneal ring.

gers). Fourteen days after the surgery, another tamponade was necessary because 20% of the graft was unattached. Twenty-three months after the surgery, the BUVA was 0.02 (20/1000) and the BCVA was 0.1 (20/200) with +8.75 (−1.5@90°) (▶ **Fig. 4**). The patient was subjectively comfortable with her vision and her quality of life was improved because she could resume her normal activities prior to her vision decreasing (going alone to the shops, for example). Corneal pachymetry was 620 µm. Fundus evaluation exhibited atrophy of the retina with optic nerve excavation.

Discussion/Conclusion

According to the literature, in this special case, a penetrating keratoplasty would have had a poor survival rate, with a high risk of rejection [7] and endothelium decompensation because of three risk factors: aphakia, aniridia, and total corneal hypoesthesia. This abnormal eye with multiple surgeries also had a high risk of postoperative shut down. Given all of these elements, a posterior lamellar graft was the best option, and a special surgical approach was necessary to be able to stabilize the graft close to the posterior corneal stroma in the absence of posterior support (iris or lens) to hold the tamponade with a mix of air and SF6. In this case, the surgery was fortunately a success; if not, the patient was at risk of becoming blind.

Penetrating keratoplasty in these types of eyes has a high risk of corneal rejection [8] with recurrent aniridia keratopathy [10]. Because posterior lamellar grafts have a lower rejection rate, this technique appears to be the best option. Posterior lamellar grafts have been proposed in aphakia and large iris defects using "air-assisted" donor lenticule insertion in DSAEK [11]. In this study, mean postoperative follow-up was 19 months with no donor dislocation and a mean BCVA of 0.1 (20/100). Santaella et al. proposed DMEK in a series

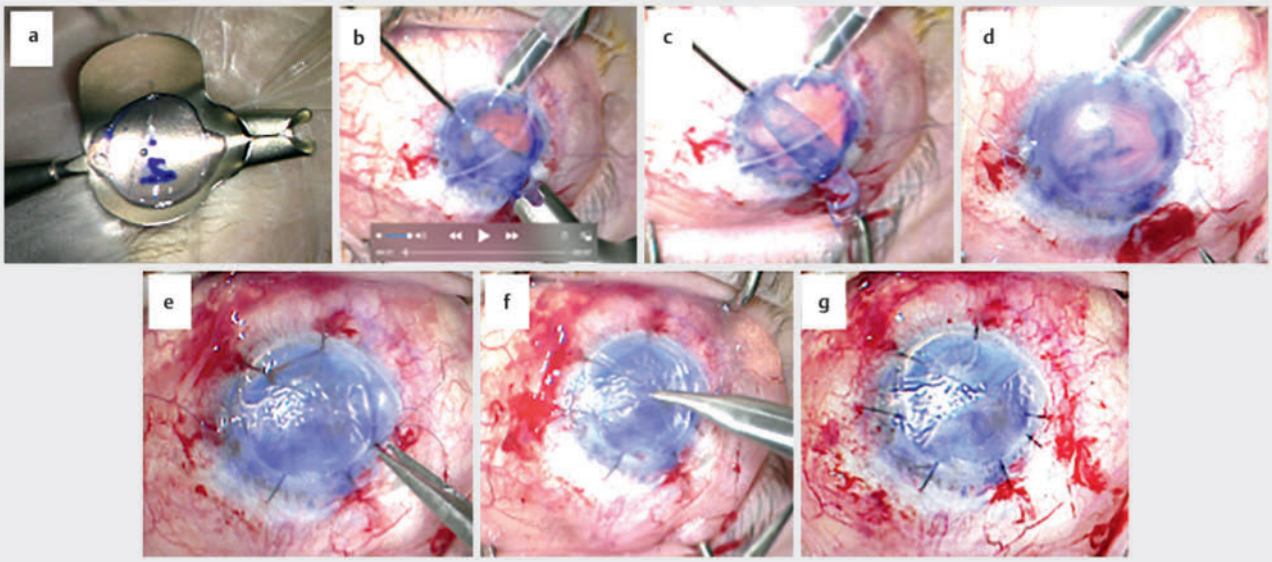

▶ **Fig. 3** **a** Placing the graft on the Busin glider. **b** Virgin silk stitches (7.0) were placed to hold the two "ears" through two side ports placed on a 9-mm diameter circle face to face. **c** The graft is slid into the eye and held with intraocular forceps in one hand and with the glider and the stitch in the other hand. **d** The graft is held through the two side ports with the stitches. The number "2" that we can read on the graft through the corneal stroma of the recipient confirms the good position of the DSAEK (stromal side, up). **e** Side port is closed with a 10.0 nylon stitch. **f** Second side port is closed with a 10.0 nylon stitch. **g** Tamponade is performed with a mix of air and SF_6 (50/50%) for 24 hours in the supine position.

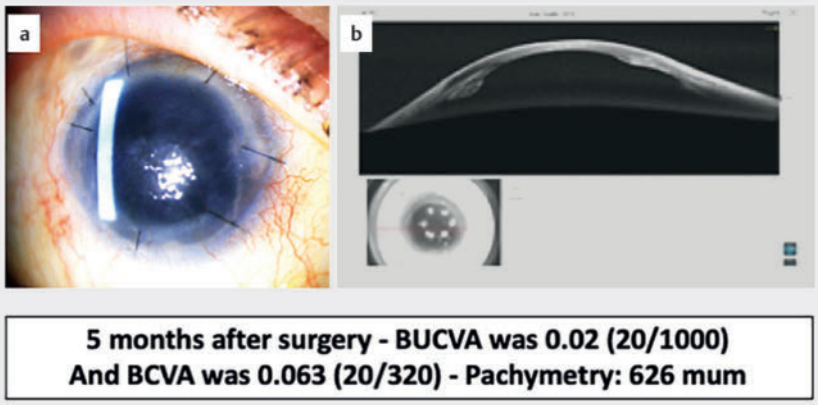

▶ **Fig. 4** **a** Five months after the surgery, the graft is attached to the posterior stroma of the recipient. Corrected vision increased up to 0.063 (20/320) and the thinnest central corneal thickness was 626 microns. **b** Anterior segment OCT (OPTOVUE SOLIX, Visionix SA, Paris, France) exhibits the posterior lamellar graft attached to the posterior corneal stroma of the recipient with one "ear" slipped into the corneal stroma through a side port.

of nine aniridic or aphakic patients, and one of the nine patient was both aniridic and aphakic. In this study, 67% had graft detachment, and graft failure occurred at the final evaluation in 88% of the cases (detachment, hyphema, and short follow-up) [12].

Aphakia is one of the rejection risk factors [13] along with prior corneal graft rejection, neovascularization, and high intraocular pressure [14].

In our case, the risk of slow endothelial decompensation or rejection was high; however, if necessary, reperforming a posterior lamellar graft would be more feasible than performing a penetrating keratoplasty.

This paper reports on a single case with a serious ophthalmological history. Being able to perform a posterior lamellar graft was reassuring for the patient and the surgeon. If a penetrating keratoplasty had been performed, a possible permanent shut down of the eye pressure after the surgery would have presented a grave problem for the patient and the surgeon, and in this case, resulted in blindness. However, in this case, we performed a lamellar graft, and although we observed a shut down in eye pressure for a period of 1 month, it was fortunately without consequence.

This new surgical procedure proposed by Muraine is approachable in the cornea for a trained surgeon. It can be reproduced and can be controlled step by step. Long follow-up studies and more cases would have to be operated on to confirm its efficacy.

Conflict of Interest

The authors declare that they have no conflict of interest.

Authors

François Majo[1,2], Marc Muraine[3]

1 Ophthalmology, Centre Ophtalmologique de la Gare, Lausanne, Switzerland
2 Ophthalmology, Lausanne University Hospital, Lausanne, Switzerland
3 Ophthalmology, Rouen University, Hôpital Charles Nicole, Rouen, France

Correspondence

PD François Majo, MD PhD
Ophthalmology
Centre Ophtalmologique de la Gare
Place de la Gare 10
1003 Lausanne
Switzerland
Phone: + 41 (0) 2 13 21 00 21
Fax: + 41 (0) 2 13 21 00 29
fmajo@bluewin.ch

References

[1] Flockerzi E, Maier P, Böhringer D et al. Trends in Corneal Transplantation from 2001 to 2016 in Germany: A Report of the DOG-Section Cornea and its Keratoplasty Registry. Am J Ophthalmol 2018; 188: 91–98. doi:10.1016/j.ajo.2018.01.018

[2] Kemer OE, Karaca EE, Oellerich S et al. Evolving Techniques and Indications of Descemet Membrane Endothelial Keratoplasty. Turk J Ophthalmol 2021; 51: 381–392. doi:10.4274/tjo.galenos.2021.28227

[3] Woo JH, Ang M, Htoon HM et al. Descemet Membrane Endothelial Keratoplasty Versus Descemet Stripping Automated Endothelial Keratoplasty and Penetrating Keratoplasty. Am J Ophthalmol 2019; 207: 288–303. doi:10.1016/j.ajo.2019.06.012

[4] Käsmann-Kellner B, Latta L, Fries FN et al. Diagnostic impact of anterior segment angiography of limbal stem cell insufficiency in PAX6-related aniridia. Clin Anat 2018; 31: 392–397. doi:10.1002/ca.22987

[5] Lagali N, Wowra B, Fries FN et al. Early phenotypic features of aniridia-associated keratopathy and association with PAX6 coding mutations. Ocul Surf 2020; 18: 130–140. doi:10.1016/j.jtos.2019.11.002

[6] Käsmann-Kellner B, Seitz B. [Congenital aniridia or PAX6 syndrome]. Ophthalmologe 2014; 111: 1144. doi:10.1007/s00347-014-3058-4

[7] Farah CJ, Fries FN, Latta L et al. An attempt to optimize the outcome of penetrating keratoplasty in congenital aniridia-associated keratopathy (AAK). Int Ophthalmol 2021; 41: 4091–4098. doi:10.1007/s10792-021-01982-z

[8] Kremer I, Rajpal RK, Rapuano CJ et al. Results of penetrating keratoplasty in aniridia. Am J Ophthalmol 1993; 115: 317–320. doi:10.1016/s0002-9394(14)73581-0

[9] Tiller AM, Odenthal MT, Verbraak FD et al. The influence of keratoplasty on visual prognosis in aniridia: a historical review of one large family. Cornea 2003; 22: 105–110. doi:10.1097/00003226-200303000-00004

[10] Gomes JA, Eagle RC jr., Gomes AK et al. Recurrent keratopathy after penetrating keratoplasty for aniridia. Cornea 1996; 15: 457–462

[11] Basak S, Basak SK. Air-Assisted" Donor Lenticule Insertion in Descemet Stripping Endothelial Keratoplasty in Aphakia With Large Iris Defect and Without Posterior Capsular Support. Cornea 2022; 41: 927–932. doi:10.1097/ICO.0000000000003043

[12] Santaella G, Sorkin N, Mimouni M et al. Outcomes of Descemet Membrane Endothelial Keratoplasty in Aphakic and Aniridic Patients. Cornea 2020; 39: 1389–1393. doi:10.1097/ICO.0000000000002387

[13] Anshu A, Li L, Htoon HM et al. Long-Term Review of Penetrating Keratoplasty: A 20-Year Review in Asian Eyes. Am J Ophthalmol 2021; 224: 254–266. doi:10.1016/j.ajo.2020.10.014

[14] Debourdeau E, Builles N, Couderc G et al. Risk factors of rejection after penetrating keratoplasty: a retrospective monocentric study. Graefes Arch Clin Exp Ophthalmol 2022; 260; 3627–3638. doi:10.1007/s00417-022-05691-w

Bibliography

Klin Monatsbl Augenheilkd 2023; 240: 394–397
DOI 10.1055/a-2045-7314
ISSN 0023-2165
© 2023. The Author(s).

This is an open access article published by Thieme under the terms of the Creative Commons Attribution-NonDerivative-NonCommercial-License, permitting copying and reproduction so long as the original work is given appropriate credit. Contents may not be used for commercial purposes, or adapted, remixed, transformed or built upon. (https://creativecommons.org/licenses/by-nc-nd/4.0/)
Georg Thieme Verlag KG, Rüdigerstraße 14, 70469 Stuttgart, Germany