Accepted Manuscript online: 2023-03-06 Article published online: 2023-04-06

Optimizing Wound Care after Surgery of the Head and Neck: A Review of Dressing Materials

Peter J.F.M. Lohuis, MD, PhD[1,2,3,4] Felix Maldonado-Chapa, MD[1,2] Karla M. Santos-Santillana, MD[2] Boris Filipović, MD, PhD[1,2] Richard Dirven, MD, PhD[1] M. Baris Karakullukcku, MD, PhD[1] Luc Karssemakers, MD, PhD[1] Willem H. Schreuder, MD, PhD[1] Charlotte L. Zuur, MD, PhD[1] Jacqueline Timmermans, MD, PhD[1]

[1] Department of Head and Neck Surgery and Oncology, The Netherlands Cancer Institute, Amsterdam, The Netherlands
[2] Department of Facial Plastic and Reconstructive Surgery, Lohuis-Filipović Medial Group, Zagreb, Croatia
[3] Department of Facial Plastic and Reconstructive Surgery, Bergman Clinics, Hilversum, The Netherlands
[4] Department of Sleep Medicine, Ruysdael Clinics, Amsterdam, The Netherlands

Address for correspondence Peter J.F.M. Lohuis, MD, PhD, Department of Head and Neck Surgery and Oncology, The Netherlands Cancer Institute, Plesmanlaan 121, Amsterdam, The Netherlands (e-mail: Lohuis1000@gmail.com).

Facial Plast Surg 2024;40:68–79.

Abstract

Wound healing is a complex biological process subject to complications that might jeopardize the patient's postoperative care. Appropriately approaching surgical wounds after head and neck surgery positively influences the quality and speed of wound healing and increases patient comfort. A large variety of dressing materials currently exist that allow the care of different types of wounds. Nevertheless, there is limited literature on the most suitable types of dressings after head and neck surgery. The objective of the present article is to review the most commonly used wound dressings, their benefits, indications, and disadvantages, and to provide a systematic approach for wound care within the head and neck. The Woundcare Consultant Society distinguishes wounds into three groups: black, yellow, and red. Each type of wound represents distinctive underlying pathophysiological processes with unique needs. Utilizing this classification along with the TIME model allows a proper characterization of wounds and the identification of potential healing barriers. This evidence-based and systematic approach can facilitate and guide the head and neck surgeon in selecting a wound dressing upon acknowledging their properties, which are herein reviewed and exemplified with representative cases.

Keywords
- wound care
- surgical wounds
- head and neck
- dressing material

Appropriate wound care after head and neck surgery represents a significant challenge, given the inherent complexity of wound healing in this area and the wide array of available dressings. Wound healing comprises a complex series of biochemical events and stages which overlap each other.[1–3] Different complications during this process can arise, making the postoperative course more difficult than what already represents to patients undergoing head and neck surgery.[4] In fact, discomfort can appear even in those without significant disturbance in the wound healing process.

As the biomolecular knowledge behind wound healing continues to increase over the last decades, the range of options in wound dressings has also evolved considerably.[5] This does not necessarily imply easiness for the head and neck specialist in selecting the most suitable dressing for specific situations. Actually, it appears to be insufficient knowledge among specialists about adequate wound care.[6] Literature addressing wound care in the head and neck area is scarce, and lectures regarding this topic are often focused on nursery training.[7]

accepted manuscript online
March 6, 2023
article published online
April 6, 2023

Thieme Medical Publishers, Inc., 333 Seventh Avenue, 18th Floor, New York, NY 10001, USA

DOI https://doi.org/10.1055/a-2047-6356.
ISSN 0736-6825.

A basic understanding of wound healing is essential for the head and neck surgeon to achieve the best possible postoperative wound result while minimizing patient discomfort. In this narrative review, we appraise the wound healing process in the head and neck and discuss the current dressing options for wound care. We advocate a systematic approach to head and neck wound care, exemplified by representative postoperative cases.

Skin and Subcutaneous Tissue: Anatomical and Functional Considerations

The skin is composed of two layers that contribute to wound healing: the epidermis and dermis. The outermost layer, the epidermis, is thin and avascular, and its main function is to protect the skin from microorganisms and other environmental factors. Its basal layers continuously replicate and push dying keratinocytes to the most superficial layers. As collagen fibers are not present in this layer, wound strength is minimal. It possesses, however, a high growth potential, enabling epithelial cell migration to seal wounds within a few hours.[8]

The dermis forms the underlayer of the skin and contains fibroblasts producing collagen, elastin, and other dermal matrix components. Collagen is the most important component and provides strength by means of extensive cross-linking. This process requires much more time than epithelial closure. The dermis also contains blood vessels, hair follicles, lymphatics, sebaceous glands, and eccrine and apocrine sweat glands. Thick bundles of collagen anchor the dermis to the underlying subcutaneous tissue, such as muscle and bone (►**Fig. 1**).[8]

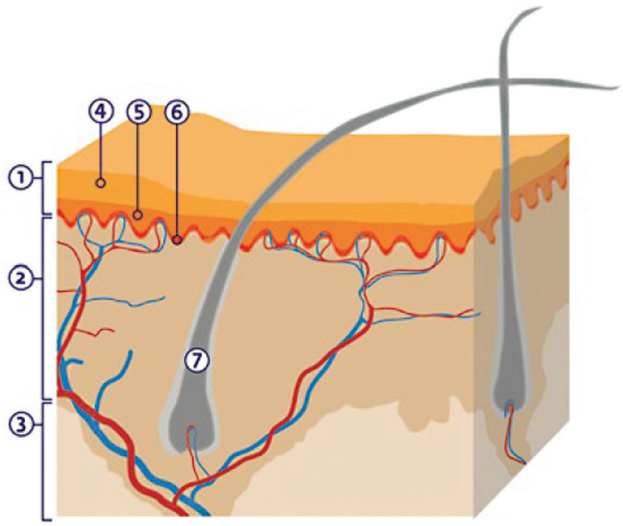

Fig. 1 Cross-section of the skin. The skin is composed of two layers: the epidermis (1) and the dermis (2). Collagen anchors the dermis to the underlying subcutaneous tissue (3). The epidermis is made up of the most superficial corneum layer (4) and a layer with squamous cells (5) and basal cells (6). (7) hair. (Reprinted with permission from Timmermans J, Halff K, van der Eijk M, Lohuis PJFM. Wondverzorging en verbandmateriaal na chirurgie in het hoofd-halsgebied. Nederlands Tijdschrift voor Keel-Neus-Oorheelkunde. 2021;27(2):62e–72e).

Stages of Wound Healing

A wound is defined as a break in the skin continuity resulting from trauma, burns, radiation, or surgery. Healing takes place in phases, which usually overlap, especially when a wound is left to heal by secondary intention (►**Fig. 2**).[9]

The first and second stages of wound healing are hemostasis and inflammation, respectively. The coagulation cascade takes over, and a fibrin network is created that initially covers the wound.[9] Phagocytosis occurs during the first days during which dead cells and bacteria are cleared. In the contaminated wound, granulocytes persist and prolong the inflammatory phase resulting in more severe scarring. It is critical to advance from this stage as early as possible so that collagen deposition may begin.[10]

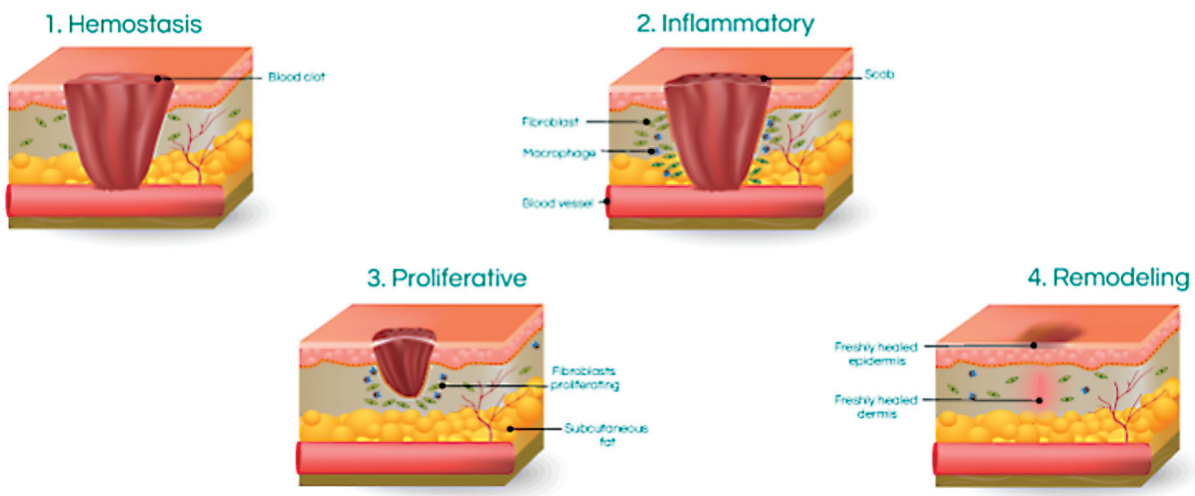

Fig. 2 Overview of the phases of wound healing. (Reprinted with permission from Timmermans J, Halff K, van der Eijk M, Lohuis PJFM. Wondverzorging en verbandmateriaal na chirurgie in het hoofd-halsgebied. Nederlands Tijdschrift voor Keel-Neus-Oorheelkunde. 2021;27 (2):62e–72e).

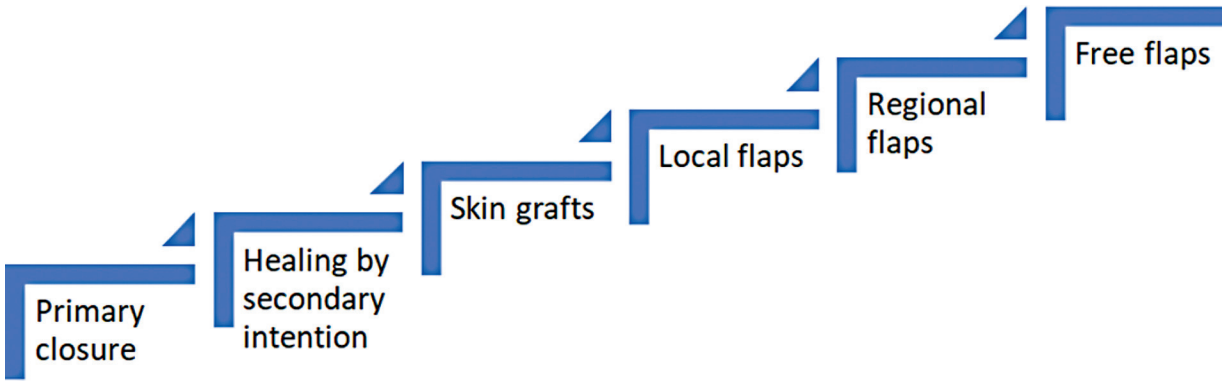

Fig. 3 A wound can be closed with a variety of surgical techniques according to the "reconstructive ladder." (Reprinted with permission from Timmermans J, Halff K, van der Eijk M, Lohuis PJFM. Wondverzorging en verbandmateriaal na chirurgie in het hoofd-halsgebied. Nederlands Tijdschrift voor Keel-Neus-Oorheelkunde. 2021;27(2):62e–72e).

The third stage, the proliferation phase can last for several weeks. Epithelial regeneration, collagen deposition, wound contraction, and neovascularization occur throughout this period. Epithelization reestablishes the barrier that protects underlying tissues. Epithelial cells migrate from wound margins and deeper adnexal structures, covering the wound until they come into contact with similar epithelial cells, followed by epithelial stratification.[1,2]

In wounds closed primarily, epithelization may be completed during the first 48 hours, but secondary intention wounds take considerably longer, especially if the wound is full thickness. Occlusion and creating a moist environment facilitate epithelial migration, providing a faster wound coverage.[11,12] The previously established fibrin network guides the formation of granulation tissue. It contains fibroblasts that produce collagen, elastin, fibronectin, glycosaminoglycans, and collagenase, which will be necessary for the subsequent remodeling phase.[13]

Lastly, in the remodeling stage, the wound matures into a thin, supple, and white connective tissue that remodels under the influence of macrophages and fibroblasts during several months. Although the healing process can be optimal in secondary intention closure, it is usually chosen to close the wound primarily to stimulate and speed up the healing process.[13] In some cases, a different reconstructive procedure is preferred (►**Fig. 3**).

Local and Systemic Factors Affecting Wound Healing

A chronic or complex wound can be defined as a wound in which local or systemic factors disturb the normal healing process. Local factors include inappropriate wound closure technique, resulting in local tissue inflammation and necrosis; wound dissection, impeding epithelial cell migration; wound ischemia (e.g., caused by hematoma, foreign bodies, or anemia); and infection, prolonging the inflammatory phase and perpetuating the presence of bacteria that compete for oxygen and nutrients within the wound.[4]

Systemic factors affecting wound healing include advanced age, smoking history, malnutrition, granulocytopenia, diabetes, coagulation disorders, and systemic drugs.[4,14–16] These factors must be counterbalanced or controlled to promote the healing of chronic wounds.

Wound Classification

The Woundcare Consultant Society (WCS) model is one of the most accepted classifications of wounds worldwide (►**Fig. 4**). This classification was developed by the Swedish dermatologist Lars Hellgren in collaboration with the WCS and distinguishes wounds into three different groups: black, yellow, and red.[17]

A black wound contains necrotic tissue. A dry black wound must be protected to heal under the necrotic tissue. The crust must be soaked and removed if there is pus or a soft mass underneath. A yellow wound is characterized by a yellow coating over the wound. These are often wet wounds. The aim is to remove or loosen the yellow layer, after which healing can take place in a suitable wound bed. A red wound indicates granulation tissue. The objective in a red wound should include protecting the granulation tissue from drying out and from other external influences by creating a moist environment.[18]

After a wound has been classified as black, yellow, or red, it is necessary to determine whether it is dry, moist, or wet. Especially in yellow and red wounds, a moist environment speeds up the healing process.[19] In a dry wound, the migration of epithelial cells is slowed down. Furthermore, a moist wound is less painful, less likely to infect, and usually ends up with a better cosmetic result. However, a wound should not become too moist at the edges, as this can lead to maceration of the adjacent tissue, inwardly migrating epithelium, which in turn hinders wound healing.[20]

The wound care guidelines (2013)[21] advise to use the WCS model in conjunction with the TIME model (►**Table 1**). Based on the TIME model, additional disruptive factors in the wound bed are identified and treated by selecting an appropriate wound dressing.

Type of Dressings for Surgical Head and Neck Wounds

An overview of different types of dressings is given in ►**Table 2** and represented in ►**Fig. 5**.

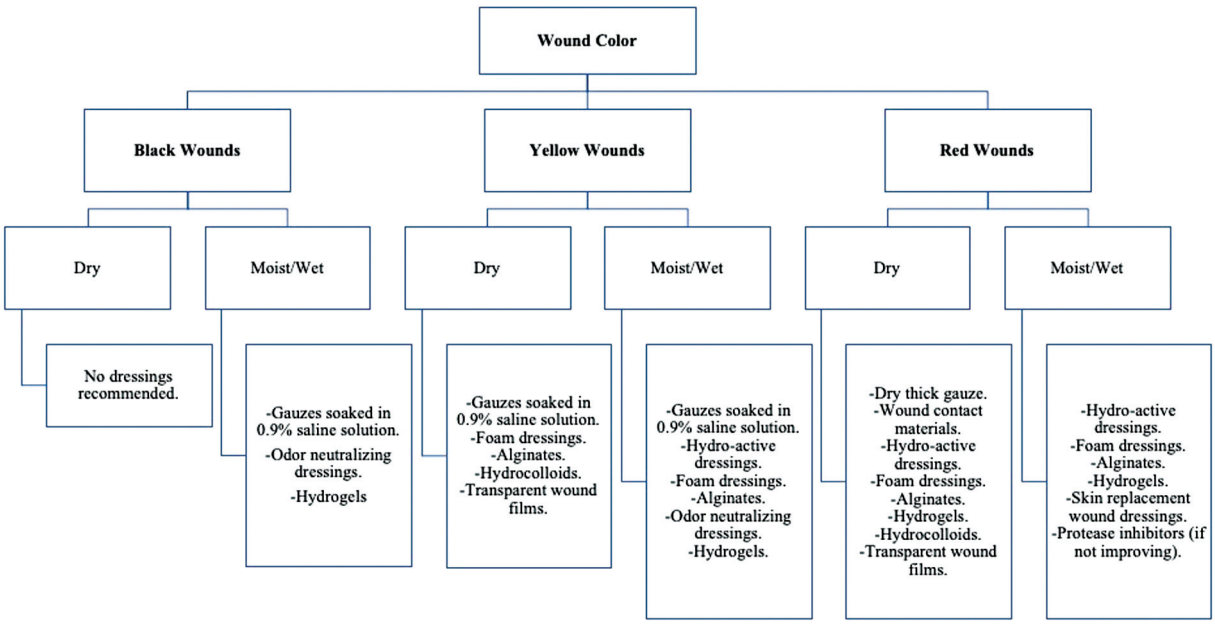

Fig. 4 Recommendations for dressing materials by the WCS according to wound color and type of exudate.

Table 1 TIME model for wound care approach

		Question	Approach
T	Tissue management	Is the wound bed vital?	Wound bed preparation by debriding nonvital tissue[a]. Red and yellow wound debridement to remove the biofilm and reactivate the healing process
I	Inflammation and infection control	Is the wound infected?	Consider antibiotics or antimicrobials dressings.
M	Moisture balance	Is there a moist wound environment?	Choose a dressing material that maintains or creates a moist wound environment.
E	Epithelial edge advancement	Is there any reason why epithelization has stopped?[b]	Depending on the cause. Consider a wound edge protector.

Source: Reprinted with permission from Timmermans J, Halff K, van der Eijk M, Lohuis PJFM. Wondverzorging en verbandmateriaal na chirurgie in het hoofd-halsgebied. Nederlands Tijdschrift voor Keel-Neus-Oorheelkunde. 2021;27(2):62e–72e.
[a]Autolytic, surgical, biological, or enzymatic.
[b]For example, infection, dehydration, dressing trauma

Alginates

Alginates are made from brown seaweed and pose an exceptional absorbent property as they can absorb up to 20 times their own weight.[22] When in contact with wound exudate, a soft gel fills the wound and creates an optimal moist environment, favoring proper wound healing. Alginates also have hemostatic properties due to their calcium content. These properties make alginates suitable for moist or bleeding wounds, as in the donor site after harvesting a split-thickness skin graft (►**Fig. 5A**).[23] Adding silver or honey adds antimicrobial properties.[24–26] One of its main limitations is the need for a secondary dressing for optimal coverage and possibility of allergic reactions.[23] Common examples of alginates include Kaltostat (ConvaTec, Princeton, NJ), Sorbsan (Bertek Pharmaceuticals), Restore Calcicare (Hollister), Tegagen HG (high gelling) and Tegagen HI (high integrity) (3M Health Care), and Comfeel Plus (Alginate-hydrocolloid dressing) (Coloplast).

Foam Dressings

Foam dressings are film dressings with additional absorbency. They are made from hydrophilic silicone or polyurethane that is in contact with the wound and an outer hydrophobic gas-permeable layer. They do not adhere to the wound bed and are available in various thicknesses. These dressings provide a moist environment and insulation. They can be utilized, for example, in the donor site after harvesting a split-thickness skin graft in a dry phase, and to cover a granulating wound in the skull after the excision of a skin tumor (►**Fig. 5B**). Nonsilicone types should be avoided in patients with fragile skin.[23] Commercially available foam dressings include Allevyn (Smith & Nephew Co.), Biatain

Table 2 Wound dressings, their main properties, and examples of indications

Wound dressing	Properties	Indications
Alginate	Absorbent and hemostatic	Donor site after harvesting a split-thickness skin graft.
Antimicrobial dressing	Antimicrobial	Infected and chronic wounds
Collagen	Stimulates the growth of granulation tissue	Infected or long-standing granulating wound (e.g., exposed tendons or irradiated skull bone)
Hydrocolloids	Stimulates the growth of granulation tissue, promotes autolysis (for low to moderate exudate)	Open wound, donor site after harvesting split-thickness skin graft, skull wound
Hydrogels	Creates moist wound environment, stimulates formation of granulation tissue, promotes autolysis	Donor site after harvesting a split-thickness skin graft
Nonadherent dressings	Protects surrounding skin	Thin skin, patients on systemic prednisone, secondary granulating wound
Foam dressing	Absorbent (for moderate exudate)	Donor site after harvesting split-thickness skin graft
Tape	Fixes dressings	Any dressing to be fixed
Transparent film	Creates moist wound environment, stimulates formation of granulation tissue	Donor site after harvesting split-thickness skin graft, fixation of intravenous line

Source: Reprinted with permission from Timmermans J, Halff K, van der Eijk M, Lohuis PJFM. Wondverzorging en verbandmateriaal na chirurgie in het hoofd-halsgebied. Nederlands Tijdschrift voor Keel-Neus-Oorheelkunde. 2021;27(2):62e–72e.

(Coloplast Co.), Askina (Braun Co.), Lyofoam Extra (ConvaTec Co.), Suprasorb (Lohmann & Rauscher Co. Ltd.), Cellosorb Adhesive (Urgo Medical Co.), Foam-S. (3 M Co.), Mepilex (Mölnlycke Health Care Co.), and Polymem (Ferris Manufacturing Co.).

Antimicrobial Dressings

Antimicrobial dressings can be used when a wound is healing slowly due to a suspected bacterial contamination. These dressings usually contain honey, iodine, or silver and are especially suitable for mildly to moderately exudative wounds, donor sites, and highly odorous chronic wounds (►**Fig. 5C**). Honey has long been used for bacterial infections; it provides a moist wound environment and has a protective effect due to its high viscosity and high sugar content. In particular, manuka honey, a monofloral honey from the manuka tree, is known for its antibacterial properties.[25] In 2008, Henle discovered that methylglyoxal is an essential antibacterial component of manuka honey, which is produced only in New Zealand.[26] Iodine also has good antimicrobial activity, but it should be used only for a short period of time.[23] Silver is less commonly used after head and neck surgery. When used, it should only be used for 8 to 10 days as silver can build up in the hair follicles of the skin, which slows down wound healing. Other antimicrobials worth mentioning in the head and neck context are acetic acid when a pseudomonas infection has been demonstrated, and metronidazole, in the case of anaerobic bacteria. Eusol paraffin was used regularly in the past for necrotic wounds and fistulas; however, it is no longer used as it affects the formation of granulation tissue. Antimicrobial dressings do not provide the necessary moist environment for optimal healing, and their use should be limited to 2 weeks or less. Antibiotic resistance with their long-term use has also been reported.[23] Available antimicrobial dressings are:

- Silver containing: Aquacel Ag (ConvaTec,), Contreet (Coloplast Sween, Inc), Arglaes (Medline Industries, Mundeline, IL), Acticoat (Smith & Nephew), Silveron (Silveron Consumer Products, Mundeline, IL), and AcryDerm Silver (AcryMed Inc, Portland, OR).
- Iodine containing: Braunovidon ointment/ointment gauze (B Braun), Inadine (Systagenix), Iodosorb (Smith & Nephew), Iodoflex (Smith & Nephew), Iodozyme (ArchiMed).
- Honey containing: Actilite (Brightwake Ltd, trading as Advancis Medical), Principelle IF (Principelle B.V.), Medihoney (Derma Sciences), and Revamil (Oswell Penda Pharmaceutical Ltd.).

Hydrocolloid Dressings

The main property of hydrocolloid dressings is the creation of a moist wound environment, allowing a clean wound to granulate under the dressing. The sheet form of the dressing is self-adhesive and waterproof, and it does not need a secondary dressing, which makes this dressing easy to use.[23,27] They completely seal off the wound from oxygen. These dressings are made from gelatin, pectin, and carboxymethylcellulose (►**Fig. 5D**).[27] They are used for open wounds, for the donor site after harvesting a split-thickness skin graft and for secondary granulating skull wounds. One major drawback is their low absorbency properties. Furthermore, the hydrocolloid layer creates a gel layer, which must

Fig. 5 Overview of the most commonly used types of dressings in the head and neck area. (**A**) alginate; (**B**) foam dressing; (**C**) antimicrobial dressing; (**D**) hydrocolloid dressing; (**E**) nonadherent dressing; (**F**) tape (Suture Strip Plus adhesive strips); (**G**) transparent film; (**H**) collagen. (Reprinted with permission from Timmermans J, Halff K, van der Eijk M, Lohuis PJFM. Wondverzorging en verbandmateriaal na chirurgie in het hoofd-halsgebied. Nederlands Tijdschrift voor Keel-Neus-Oorheelkunde. 2021;27(2):62e–72e).

be removed to inspect the wounds.[23] Wound edges are prone to maceration, as these dressings stick firmly to the skin around the wound. Foam dressings are often chosen over hydrocolloid dressings for this reason. Examples of hydrocolloid dressings are Granuflex (ConvaTec), NU DERM (Systagenix), and Aquacel (ConvaTec).

Nonadherent Dressings

Nonadherent dressings are usually made of silicone material (such as Mepitel (►**Fig. 4E**), Urgotul [Urgo Medical], Mepitel [Mölnlycke], and Adaptic [Systagenix]).[27] This type of dressing allows exudate to pass through but prevents the dressing from coming into direct contact with the wound bed. These bandages are especially suitable for people with thin skin or in treatment with steroids, as they do not adhere to the wound bed avoiding trauma during their removal.[27] These can also be used in secondary healing wounds, in the donor site of a split-thickness skin graft in the dry phase, and to protect a transplanted skin from sticking to the overlying pressure bandage. They may require a secondary dressing in moderately or highly exudative wounds to improve absorbency.[23]

Adhesive Strips

The proper securing of a dressing is essential. Tapes are mainly used for this purpose and come in different adhesive materials and sizes (►**Fig. 5F**). Tapes with hypoallergenic properties are available. Suture strips are made of a

microporous, slightly stretchable material to quickly and effectively seal a superficial wound and hold the wound edges, especially during the initial healing phase.[28] Example of adhesive strips Mefix (Molnlycke Healthcare), Hypafix (Smith & Nephew), and Fixomull (Bsn Jobst).

Transparent Films

Transparent films are adhesive, semipermeable, and waterproof (►**Fig. 5G**).[23,27] They are impermeable to bacteria and provide a moist wound environment in which the formation of granulation tissue is stimulated. Transparent films can be used, for example, for securing an intravenous line or for covering the donor site after harvesting a split-thickness skin graft. With a transparent film, the wound can be observed through the bandage, and it can easily adjust to different body conformations, as in the head and neck.[23,27] However, leakage can occur along the film edge with a large amount of exudate. Another major disadvantage is the adherence to wound edges, making their removal often traumatic.[27] Different transparent films include Covaclear (Covalon Technologies, Ltd.), Tegaderm (3M Health Care), DermaView II Transparent Film Dressing (DermaRite Industries, LLC), and Hydrofilm (HARTMANN USA, Inc.).

Hydrogel

Hydrogels, such as Intrasite Gel (Smith & Nephew), Nu-Gel (Systagenix), Actiform Cool Hydrogel Sheet (Activa Healthcare), and Aquaflo (Covidien), are water or glycerine-based gels, coming in the form of impregnated gauzes, amorphous gels, or hydrogel sheets.[27] Hydrogels provide a moist wound environment and stimulate granulation and epithelialization. In addition, these dressings are transparent, allowing the wound to be evaluated continuosly.[27] Because these dressings contain a lot of water, some of them are not able to absorb much exudate.

Hydrofibers

Hydrofibers, such as Aquacel AG (ConvaTec) and ActivHeal AquaFiber (Advanced Medical Solutions), are absorbent dressings consisting of dry fibrous material (sodium carboxymethylcellulose). These highly absorbent dressings create a soft gel by interacting with the wound exudate, creating a moist wound environment that promotes wound healing. This type of dressing has to be used together with a secondary dressing (e.g., a hydrocolloid).[27]

Collagen

Collagen plays a role in the last two phases of wound healing (proliferation and remodeling phases). The presence of collagen stimulates and facilitates the formation of granulation tissue in the wound bed. Collagen fibers are suitable for exposed tendons and poorly perfused (e.g., irradiated) skull bone (►**Fig. 5H**). Commercially available collagen dressings include Endoform Natural (Aroa Biosurgery, Ltd.), HYCOL Hydrolyzed Collagen Powder (Sanara MedTech Inc.), Promogran Matrix Family (3M Health Care), BIOCOL (L&R USA, Inc.), and DermaCol Collagen (DermaRite Industries, LLC).

Wound Care in the Head and Neck Area

The head and neck have "their own" issues regarding wound care. First of all, this area is distinctly visible to others. Blood, pus, or fluid in a bandage often run into the eyes. In addition, the fixation of the dressing is sometimes difficult due to the three-dimensional configuration of facial structures, such as the ear and nose, the greasy skin structure, and the skin movement with the underlying facial musculature.

The head and neck have an excellent blood supply, which theoretically facilitates healing, resulting in a decreased incidence of complications. However, previous or postoperative radiotherapy treatment of the wound site can compromise its microvasculature, leading to delayed or impaired wound healing or osteoradionecrosis of the underlying bone, particularly in cases of defects of the skull.[29]

When choosing a dressing for the head and neck, not only the ideal wound environment should be sought but also the patient's comfort. The dressing must be clean on the outside, stick easily, be flexible, preferably be hypoallergenic, and be user-friendly, especially in the case of elderly patients.

Role of the Wound Expert Team

Patients must be referred to the wound expert team in the case of insufficient progress in wound healing and nonhealing chronic wounds (i.e., more than 3 weeks). The wound team guides patients with complex wounds in the hospital, optimizing the control of underlying systemic diseases, counseling patients, and providing recommendations to improve the patient's nutritional status. The team should hold outpatient consultations, advise nurses on the ward, and design a treatment plan for wound care at home.[6]

Costs

In The Netherlands, dressings used in the hospital fall within the hospital budget. Dressings prescribed for wound care at home are entitled to reimbursement of their costs as referred to in the Healthcare Insurance Decree (Article 2.4 and Article 2.9) and the Health Insurance Regulations (Article 2.6, Subtitle K and article 2.18). This reimbursement also applies to dressings for long-term or chronic care of complex wounds. The specialist must provide these patients with a form to justify the chronic aspect of wound care at the pharmacy.

Clinical Cases of Postoperative Wound Care in the Head and Neck Area

►**Fig. 4** shows an overview of the most commonly used dressings in the head and neck area. After the head and neck surgeon has understood its classification by reading the description of the dressing properties in this article, its application will have to take place in an individualized manner. The variation among different patients, each with their own specific local and systemic issues, is broad. Representative cases of wound care in the head and neck area are provided in this section.

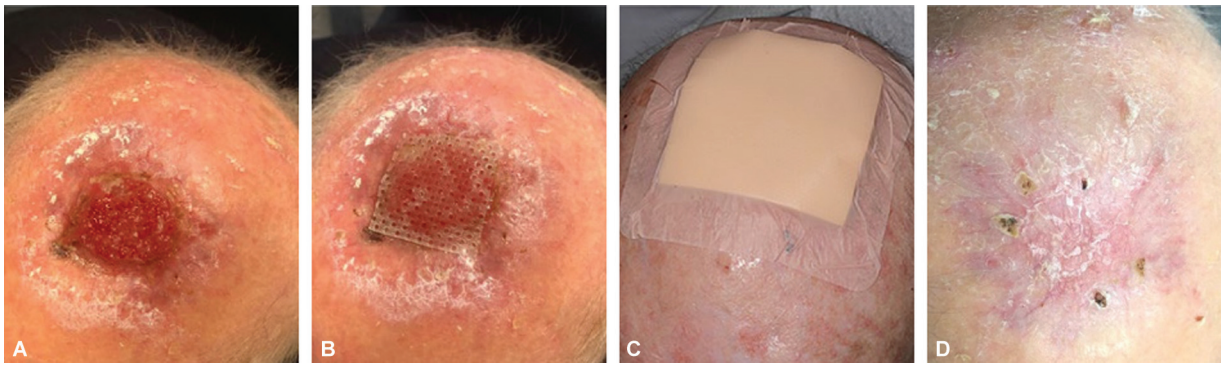

Fig. 6 (**A**) Scalp wound after excision of a cutaneous squamous cell carcinoma down to the galea. Healing through secondary intention. (**B**) The skull wound was treated with a nonadherent porous silicone dressing. (**C**) Covered with an absorbent foam dressing with a wide adhesive strip. (**D**) The wound was completely covered by a newly formed thin epithelial layer after 9 weeks. (Reprinted with permission from Timmermans J, Halff K, van der Eijk M, Lohuis PJFM. Wondverzorging en verbandmateriaal na chirurgie in het hoofd-halsgebied. Nederlands Tijdschrift voor Keel-Neus-Oorheelkunde. 2021;27(2):62e–72e).

Case 1

An elderly man presented with a skull wound after excision of a squamous cell carcinoma down to the galea (►**Fig. 6**). Stimulation and protection of granulation tissue was achieved by means of a foam dressing and greasy ointment (►**Table 3**).

Case 2

A middle-aged man presented with a left helix wound and reconstruction with a full-thickness skin graft (►**Fig. 7**). Compression by means of an adhering greasy gauze was utilized in this case (►**Table 4**).

Case 3

A patient presented after harvesting a split-thickness skin graft on the thigh (►**Fig. 8**). The SHAFE study is currently underway at the Netherlands Cancer Institute/Antoni van Leeuwenhoek Hospital. In this study, three different wound dressings are prospectively compared at the donor site after harvesting a split-thickness skin graft under comparable conditions. The aim was to evaluate prospectively in a

Table 3 Wound care and dressing selection of Case 1

Etiology	Squamous cell carcinoma, excision down to the galea
Confounding Factors	Age, Diabetes Mellitus
Location	Scalp
WCS	Wound is red and moist; wound edge unaffected
TIME	Vital wound bed; not infected
Wound care	Protect wound edges, stimulate granulation and cover with a nonadherent dressing or a foam dressing. Cover the wound with a greasy ointment to protect granulation tissue.

Abbreviation: WCS, Woundcare Consultant Society.
Source: Reprinted with permission from Timmermans J, Halff K, van der Eijk M, Lohuis PJFM. Wondverzorging en verbandmateriaal na chirurgie in het hoofd-halsgebied. Nederlands Tijdschrift voor Keel-Neus-Oorheelkunde. 2021;27(2):62e–72e.

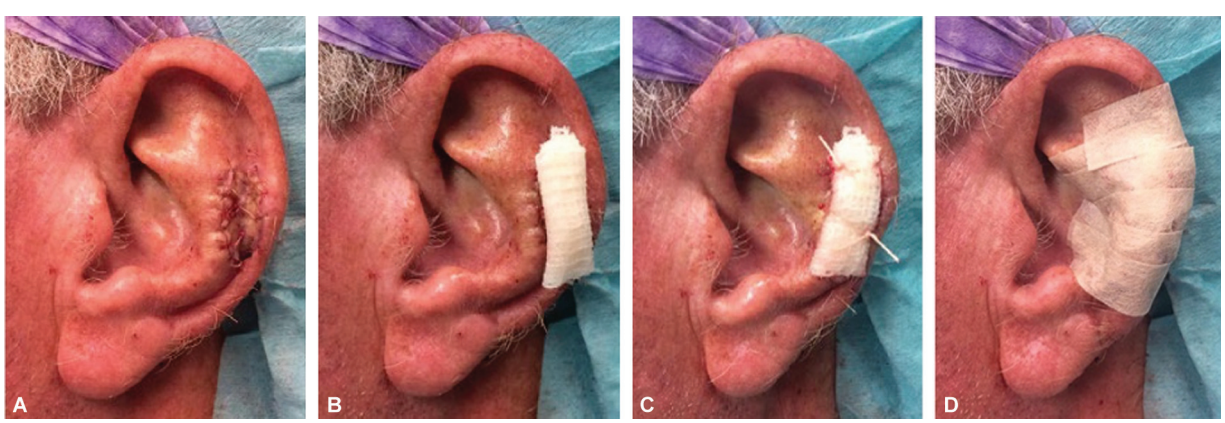

Fig. 7 (**A**). Surgical wound of the left helix after excision of a basal cell carcinoma. Wound reconstruction with a full-thickness skin graft from the neck. (**B** and **C**). Wound care was performed by suturing a nonadherent, greasy gauze. (**D**). Tape was applied as a cover and additional fixation. (Reprinted with permission from Timmermans J, Halff K, van der Eijk M, Lohuis PJFM. Wondverzorging en verbandmateriaal na chirurgie in het hoofd-halsgebied. Nederlands Tijdschrift voor Keel-Neus-Oorheelkunde. 2021;27(2):62e–72e).

Table 4 Wound care and dressing selection of Case 2

Etiology	Basal cell carcinoma, excision and reconstruction with a full-thickness skin graft.
Confounding Factors	Positive smoking history
Location	Left ear
WCS	Closed and dry wound
TIME	Vital wound bed; not infected
Wound care	Compression with an adhering greasy gauze and covering/reinforcement with nonadherent tape. Bandages removed after a week.

Abbreviation: WCS, Woundcare Consultant Society.
Source: Reprinted with permission from Timmermans J, Halff K, van der Eijk M, Lohuis PJFM. Wondverzorging en verbandmateriaal na chirurgie in het hoofd-halsgebied. Nederlands Tijdschrift voor Keel-Neus-Oorheelkunde. 2021;27(2):62e–72e.

randomized manner which dressings score best with regard to the endpoints of pain, patient comfort, and epithelialization (►**Table 5**).

Case 4

A young patient presented with a scar revision in the right cheek (►**Fig. 9**). Adhesive strips were applied for 3 weeks (►**Table 6**).

Case 5

An elderly patient presented with a scalp wound defect after radiotherapy (►**Fig. 10**). Adequate healing was achieved after fixation of a collagen matrix, and the use of a hydrocolloid coating, and a vacuum-assisted closure (VAC) device (►**Table 7**).

Table 5 Wound care and dressing selection of Case 3

Etiology	Split-thickness skin graft for reconstruction of a wound in the head and neck area.
Confounding Factors	None
Location	Thigh (different sites)
WCS	Moist, red wound
TIME	Vital wound bed; not infected; moist wound environment.
Wound care	Coverage during the first 24 h with an alginate and a transparent film (►**Fig. 7B**). After 24 h, the wound continues to be covered with alginate and a transparent film, or can be changed to: a combination of a foam dressing and hydrogel colloid (►**Fig. 7C**), or only a foam dressing (►**Fig. 7D**) depending on the SHAFE study arm to which the patient was randomized.

Abbreviation: WCS, Woundcare Consultant Society.
Source: Reprinted with permission from Timmermans J, Halff K, van der Eijk M, Lohuis PJFM. Wondverzorging en verbandmateriaal na chirurgie in het hoofd-halsgebied. Nederlands Tijdschrift voor Keel-Neus-Oorheelkunde. 2021;27(2):62e–72e.

Case 6

A middle-aged man with a poorly healing wound after a fibula free-flap reconstructed with a split-thickness skin

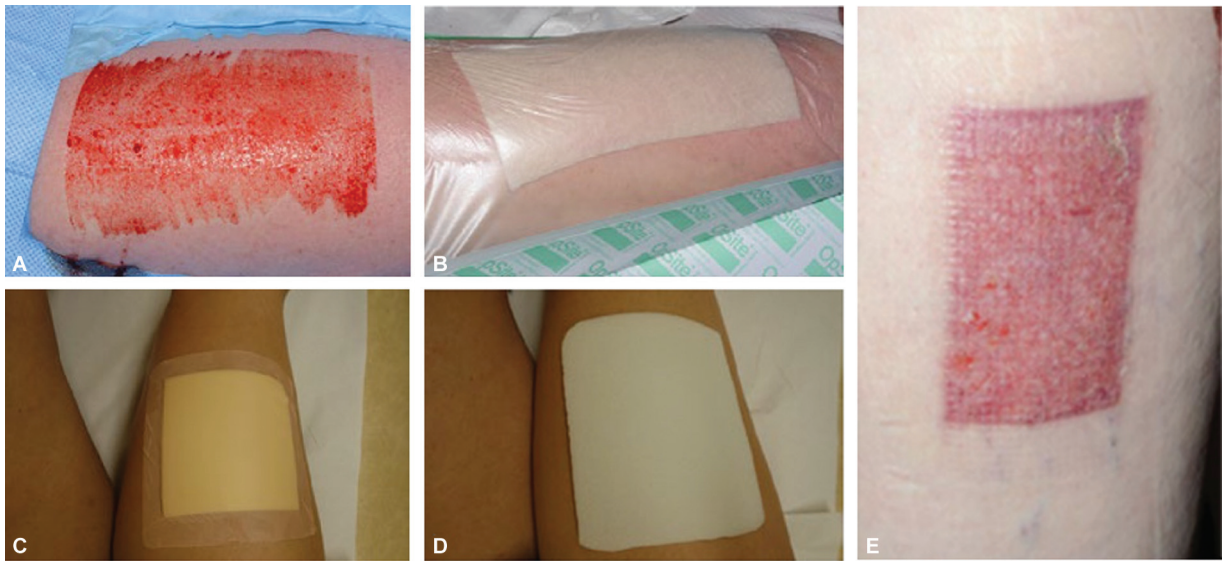

Fig. 8 (A) Donor site immediately after harvesting a split-thickness skin graft. (B) First 24 hours: Coverage with an alginate and a transparent film. Afterwards, patients are randomized among 3 possible study arms according to the SHAFE study: (1) continue treatment with and alginate and transparent film; or (2) the alginate is replaced after 24 hours postoperatively with a foam dressing (Xtrabsorb Foam; (C).), followed by a hydrogel colloid (Xtrabsorb HCS); or (3) the alginate is replaced after 24 hours postoperatively for a foam-only dressing (Mepilex; (D).). (E) Result of the patient from the third study arm at 3 weeks postoperatively. (Reprinted with permission from Timmermans J, Halff K, van der Eijk M, Lohuis PJFM. Wondverzorging en verbandmateriaal na chirurgie in het hoofd-halsgebied. Nederlands Tijdschrift voor Keel-Neus-Oorheelkunde. 2021;27(2):62e–72e).

Table 6 Wound care and dressing selection of Case 4

Etiology	Scar revision after excision of a dermoid cyst.
Confounding Factors	Elastic young skin.
Location	Right cheek
WCS	Closed, dry wound
TIME	Vital wound bed; not infected
Wound care	Approximate (wide adhesive strips) for 3 wk. Dermabrasion after scar maturing.

Abbreviation: WCS, Woundcare Consultant Society.
Source: Reprinted with permission from Timmermans J, Halff K, van der Eijk M, Lohuis PJFM. Wondverzorging en verbandmateriaal na chirurgie in het hoofd-halsgebied. Nederlands Tijdschrift voor Keel-Neus-Oorheelkunde. 2021;27(2):62e–72e.

Table 7 Wound care and dressing selection of Case 5

Etiology	Skull wound after radiotherapy of a cutaneous squamous cell carcinoma.
Confounding Factors	Osteoradionecrosis of skull bone after adjuvant radiotherapy.
Location	Scalp
WCS	Dry wound, exposed bone.
TIME	Nonvital wound bed; noninfected, dry wound environment; wound edges encapsulate wound so that no migration of epithelium across the wound bed can take place.
Wound care	(1) Drilling of the tabula externa down to the bone marrow. (2) Fixation of a collagen matrix (INTEGRA). (3) Protection of wound edges with thin hydrocolloid coating. (4) Applying vacuum-assisted closure device (VAC device).

Abbreviation: WCS, Woundcare Consultant Society.
Source: Reprinted with permission from Timmermans J, Halff K, van der Eijk M, Lohuis PJFM. Wondverzorging en verbandmateriaal na chirurgie in het hoofd-halsgebied. Nederlands Tijdschrift voor Keel-Neus-Oorheelkunde. 2021;27(2):62e–72e.

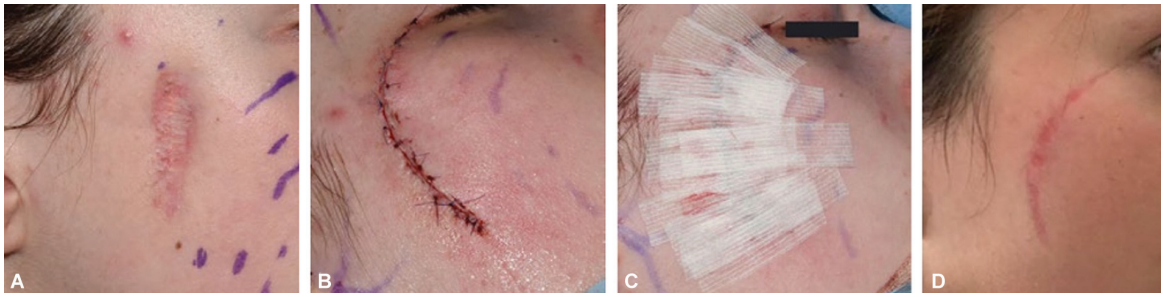

Fig. 9 (**A**) Right cheek scar to be revised. (**B**) Primary wound closure. (**C**) Approximation with adhesive strips. (**D**) Result after 6 months. (Reprinted with permission from Timmermans J, Halff K, van der Eijk M, Lohuis PJFM. Wondverzorging en verbandmateriaal na chirurgie in het hoofd-halsgebied. Nederlands Tijdschrift voor Keel-Neus-Oorheelkunde. 2021;27(2):62e–72e).

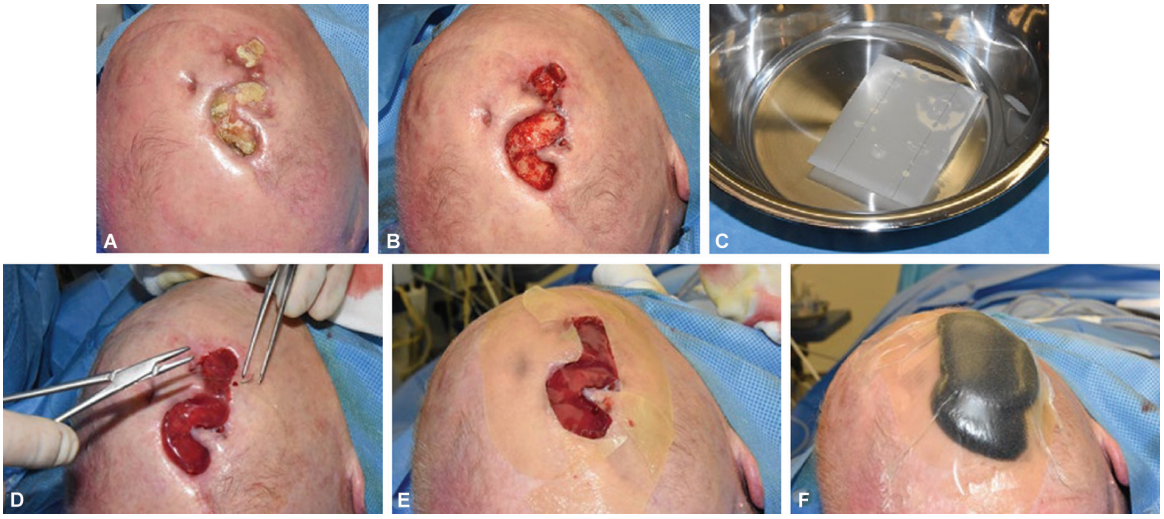

Fig. 10 (**A**) Scalp wound after irradiation to treat a cutaneous squamous cell carcinoma. (**B**) Preparation of wound bed by drilling the tabula externa down to the bone marrow. (**C**) Collagen Matrix (INTEGRA) (**D**) Fixation of the Collagen Matrix to the wound edges. (**E**) Protecting the wound edges with thin hydrocolloid coating. (**F**) Applying a VAC device. (Reprinted with permission from Timmermans J, Halff K, van der Eijk M, Lohuis PJFM. Wondverzorging en verbandmateriaal na chirurgie in het hoofd-halsgebied. Nederlands Tijdschrift voor Keel-Neus-Oorheelkunde. 2021;27(2):62e–72e).

Fig. 11 (**A**) Wound before VAC device treatment. (**B**) Treatment with a VAC device. (**C**) Wound after VAC device treatment. Wound contraction due to granulation and partial re-epithelialization is observed. (Reprinted with permission from Timmermans J, Halff K, van der Eijk M, Lohuis PJFM. Wondverzorging en verbandmateriaal na chirurgie in het hoofd-halsgebied. Nederlands Tijdschrift voor Keel-Neus-Oorheelkunde. 2021;27 (2):62e–72e).

graft (►**Fig. 11**). Granulation tissue growth was promoted by means of a VAC device (►**Table 8**).

Case 7

An elderly man with an unresectable sarcoma of the scalp (►**Fig. 12**). No epithelization is seen due to tumor activity. A comfortable dressing was chosen for this patient (►**Table 9**).

Conclusion

The head and neck surgeon has to deal with the assessment of wounds on a daily basis. During the medical training, insufficient focus is given to appropriate wound care and dressing materials. Nevertheless, adequate evaluation and care of surgical wounds in the head and neck area are crucial, as this positively influences the quality and speed of wound healing while improving patient comfort. With this review, we attempt to increase interest in appropriate wound care

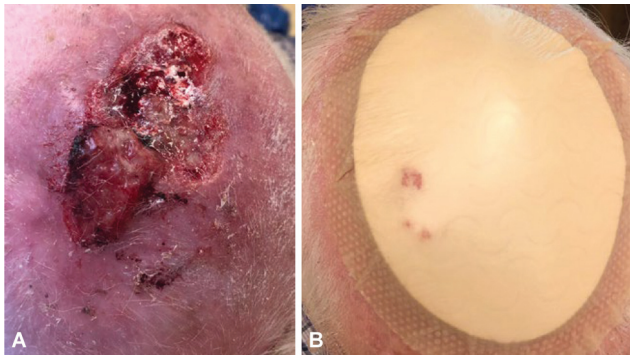

Fig. 12 (**A**) Inoperable sarcoma of the skull. (**B**) Foam bandage with adhesive edge for comfort. (Reprinted with permission from Timmermans J, Halff K, van der Eijk M, Lohuis PJFM. Wondverzorging en verbandmateriaal na chirurgie in het hoofd-halsgebied. Nederlands Tijdschrift voor Keel-Neus-Oorheelkunde. 2021;27(2):62e–72e).

Table 8 Wound care and dressing selection of Case 6

Etiology	Donor site after fibula free-flap.
Confounding Factors	Smoking and Diabetes Mellitus
Location	Right leg
WCS	Moist wound, with exposed tendon.
TIME	Vital wound bed, uninfected, moist wound environment, exposed bone.
Wound care	VAC device to promote growth of granulation tissue.

Abbreviation: WCS, Woundcare Consultant Society.
Source: Reprinted with permission from Timmermans J, Halff K, van der Eijk M, Lohuis PJFM. Wondverzorging en verbandmateriaal na chirurgie in het hoofd-halsgebied. Nederlands Tijdschrift voor Keel-Neus-Oorheelkunde. 2021;27(2):62e–72e.

Table 9 Wound care and dressing selection of Case 7

Etiology	Sarcoma of the scalp, not suitable for surgical treatment.
Confounding Factors	Smoking history
Location	Scalp
WCS	Red, dry wound
TIME	Vital, moist, slightly infected, absent epithelialization due to tumor activity.
Wound care	Palliative absorbent and covering foam dressing with wide adhesive edge for patient's comfort.

Abbreviation: WCS, Woundcare Consultant Society.
Source: Reprinted with permission from Timmermans J, Halff K, van der Eijk M, Lohuis PJFM. Wondverzorging en verbandmateriaal na chirurgie in het hoofd-halsgebied. Nederlands Tijdschrift voor Keel-Neus-Oorheelkunde. 2021;27(2):62e–72e.

within the head and neck by sharing a systematic approach amidst a wide variety of dressing materials available.

Conflict of Interest
None declared.

References

1 Gurtner GC, Werner S, Barrandon Y, Longaker MT. Wound repair and regeneration. Nature 2008;453(7193):314–321
2 Singer AJ, Clark RA. Cutaneous wound healing. N Engl J Med 1999; 341(10):738–746
3 Eming SA, Wynn TA, Martin P. Inflammation and metabolism in tissue repair and regeneration. Science 2017;356(6342): 1026–1030
4 Menke NB, Ward KR, Witten TM, Bonchev DG, Diegelmann RF. Impaired wound healing. Clin Dermatol 2007;25(01):19–25
5 Tran HQ, Shahriar SMS, Yan Z, Xie J. Recent advances in functional wound dressings. Adv Wound Care (New Rochelle) 2022 ;12(07): 399–427
6 Schubert S, Marzloff G, Ryder S, Ott K, Hutton J, Becker M. Establishing a comprehensive wound care team and program. Phys Med Rehabil Clin N Am 2022;33(04):805–810
7 Morrell S, Pittman G, Mulcaster A. Wound management provided by advanced practice nurses: a scoping review protocol. JBI Evid Synth 2022;20(07):1806–1813
8 Gaboriau HP, Murakami CS. Skin anatomy and flap physiology. Otolaryngol Clin North Am 2001;34(03):555–569
9 Goslen JB. Wound healing for the dermatologic surgeon. J Dermatol Surg Oncol 1988;14(09):959–972
10 Huang C, Dong L, Zhao B, et al. Anti-inflammatory hydrogel dressings and skin wound healing. Clin Transl Med 2022;12 (11):e1094
11 Winter GD, Scales JT. Effect of air drying and dressings on the surface of a wound. Nature 1963;197:91–92
12 Winter GD. Effect of air exposure and occlusion on experimental human skin wounds. Nature 1963;200:378–379
13 Shams F, Moravvej H, Hosseinzadeh S, et al. Overexpression of VEGF in dermal fibroblast cells accelerates the angiogenesis and wound healing function: in vitro and in vivo studies. Sci Rep 2022; 12(01):18529
14 Sørensen LT. Wound healing and infection in surgery: the pathophysiological impact of smoking, smoking cessation, and nicotine replacement therapy: a systematic review. Ann Surg 2012;255 (06):1069–1079
15 Quain AM, Khardori NM. Nutrition in wound care management: a comprehensive overview. Wounds 2015;27(12):327–335
16 Baltzis D, Eleftheriadou I, Veves A. Pathogenesis and treatment of impaired wound healing in diabetes mellitus: new insights. Adv Ther 2014;31(08):817–836
17 Zwarts S. Het WCS-classificatiemodel voor lokale wondbehandeling. [The WCS classification for local wound care (Woundcare Consultant Society)]Tijdschr Ziekenverpl 1991;(19):694–695
18 Krasner D. Wound care: how to use the red-yellow-black system. Am J Nurs 1995;95(05):44–47
19 Winter GD. Formation of the scab and the rate of epithelization of superficial wounds in the skin of the young domestic pig. Nature 1962;193:293–294
20 Koopman-Kuijl CA, de Goederen-Geleijnse MMT. Wondbedpreparatie model deel 1. WCS Nieuws. 2015;31:42–46
21 Brölmann FE, Vermeulen H, Go PMNYH, Ubbink DT. 2013 Richtlijn 'Wondzorg'. Evidence-based richtlijn van wonden met een acute etiologie. Concept richtlijn.
22 Hess CT. Clinical Guide To Skin And Wound Care. 7th ed. Philadelphia: Lippincott Williams & Wilkins; 2012
23 Sinha SN, Free B, Ladlow O. The art and science of selecting appropriate dressings for acute open wounds in general practice. Aust J Gen Pract 2022;51(11):827–830
24 Alinezhad Sardareh E, Shahzeidi M, Salmanifard Ardestani MT, Mousavi-Khattat M, Zarepour A, Zarrabi A. Antimicrobial activity of blow spun PLA/gelatin nanofibers containing green synthesized silver nanoparticles against wound infection-causing bacteria. Bioengineering (Basel) 2022;9(10):518
25 Alvarez-Suarez JM, Gasparrini M, Forbes-Hernández TY, Mazzoni L, Giampieri F. The composition and biological activity of honey: a focus on manuka honey. Foods 2014;3(03):420–432
26 Mavric E, Wittmann S, Barth G, Henle T. Identification and quantification of methylglyoxal as the dominant antibacterial constituent of Manuka (*Leptospermum scoparium*) honeys from New Zealand. Mol Nutr Food Res 2008;52(04):483–489
27 Vowden K, Vowden P. Wound dressings: principles and practice. Surgery 2014;32(09):462–467
28 Rodeheaver GT, Halverson JM, Edlich RF. Mechanical performance of wound closure tapes. Ann Emerg Med 1983;12(04):203–207
29 Russell NS, Hoving S, Heeneman S, et al. Novel insights into pathological changes in muscular arteries of radiotherapy patients. Radiother Oncol 2009;92(03):477–483