



# DIEP Flap Transplantation in Monozygotic Twins for Breast Reconstruction: A Case Report and Literature Review

Cemile Nurdan Ozturk, MD<sup>1</sup> Arvind D. Manisundaram, MD<sup>1</sup> Mariangela Rivera, MD<sup>1</sup>  
Can Ozturk, MD<sup>1</sup> Wong Moon, MD<sup>1</sup>

<sup>1</sup>Department of Head and Neck/Plastic and Reconstructive Surgery, Roswell Park Comprehensive Cancer Center, Buffalo, New York

**Address for correspondence** Cemile Nurdan Ozturk, MD, Department of Head and Neck/Plastic and Reconstructive Surgery, Elm & Carlton Streets, Buffalo, NY 14263 (e-mail: Cemile.ozturk@roswellpark.org).

J Reconstr Microsurg Open 2023;8:e66–e72.

## Abstract

**Background** Composite tissue allotransplants are performed for various defects when local, or distant reconstructive options are limited. Though this type of transplant replaces similar tissue, it is complicated by immunosuppression. This limitation may be avoided in monozygotic twins since they share identical genetic code. Free soft tissue transplantation across identical twins has been reported for breast, scalp, and thoracic reconstruction when autologous tissues were insufficient. We present a case of a successful deep inferior epigastric artery perforator (DIEP) flap transplantation in monozygotic twins.

**Methods** The recipient twin was a patient with history of breast cancer and failed prosthetic reconstruction. She desired autologous reconstruction with a DIEP flap but had insufficient donor tissue. She refused alternative sites; however, she had an identical twin willing to donate her excess abdominal tissue. The twins underwent deoxyribonucleic acid testing, human leukocyte antigen/blood type testing, and screening for communicable diseases.

**Results** The twins were found to have greater than 99.99% probability of being monozygotic twins. A bipediced conjoined DIEP was harvested from donor twin and transplanted to recipient twin. Immunosuppressive regimen was not utilized. Patients healed uneventfully and are currently 5 years postop without long-term complications.

**Conclusion** Isogeneic flap transplant is a viable option to consider when autologous tissues are restricted, and monozygotic twins are present. Appropriate counseling of twins is critical for a successful and satisfactory outcome.

## Keywords

- ▶ twin transplantation
- ▶ soft tissue transplantation
- ▶ breast reconstruction
- ▶ flap transplantation
- ▶ DIEP transplantation

Composite tissue allotransplantation is an advanced surgical technique utilized for reconstruction of defects and defor-

mities when local, or distant reconstructive options are absent. Even though this type of transplant is ideal in terms of transferring tissue that matches the recipient's missing component, patients necessitate immunosuppression and have to accept risk of rejection. These limitations may be

*Presented at: Plastic Surgery the Meeting (ASPS) 2020 (virtual).*

received  
December 7, 2022  
accepted after revision  
February 28, 2023  
accepted manuscript online  
May 4, 2023

DOI <https://doi.org/10.1055/a-2086-5667>.  
ISSN 2377-0813.

© 2023. The Author(s).

This is an open access article published by Thieme under the terms of the Creative Commons Attribution-NonDerivative-NonCommercial-License, permitting copying and reproduction so long as the original work is given appropriate credit. Contents may not be used for commercial purposes, or adapted, remixed, transformed or built upon. (<https://creativecommons.org/licenses/by-nc-nd/4.0/>)

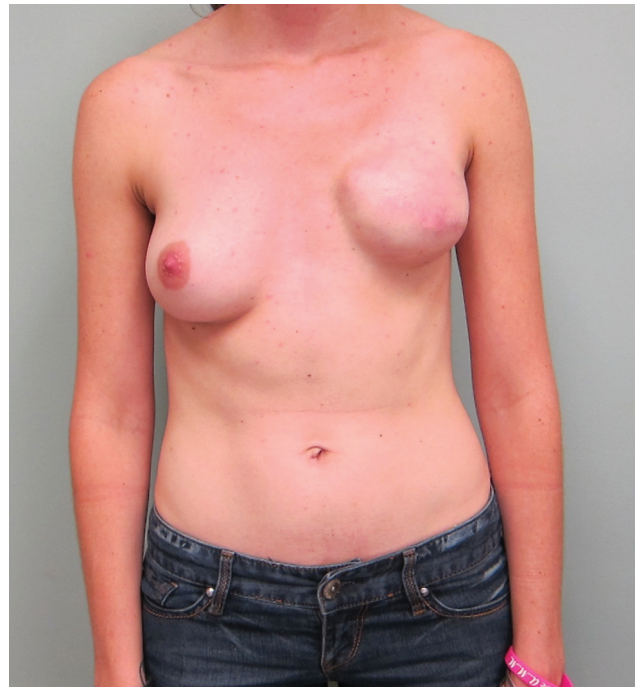Thieme Medical Publishers, Inc., 333 Seventh Avenue, 18th Floor, New York, NY 10001, USA

avoided in monozygotic twins since they share nearly identical genetic code, not requiring lifelong immunosuppression.<sup>1,2</sup> Due to relatively low incidence of monozygotic twins (1 in 250 births) and rarity of scenarios needing tissue transfer between individuals, only a scarce number of flap transplantations have been reported.<sup>2-8</sup> These include cases of breast, scalp, and thoracic reconstruction where patients' autologous tissues were not available or were insufficient.

Breast reconstruction is a commonly performed procedure as it increases a woman's quality of life by improving body image, femininity, and overall sense of well-being.<sup>9,10</sup> The deep inferior epigastric artery perforator (DIEP) flap has become a preferred choice for autologous breast reconstruction, yet it may not be feasible in patients with low body mass index (BMI) or prior abdominal surgeries such as abdominoplasty.<sup>11,12</sup> In absence of adequate tissues or when patient is refusing alternative donor sites, free flap transplantation from a monozygotic twin might be considered. Due to elective nature of breast reconstruction, specific challenges arise in decision making such as ethical aspects of transferring flap donor risk to another individual. We present a case of DIEP flap transplantation between monozygotic twins. A review of literature and an algorithm to aid in preoperative workup are also provided.

## Methods

This patient was a 28-year-old female who was diagnosed with stage I (T1bN0M0) ER +/PR +/HER2- breast cancer. She had past medical history of celiac disease and was a previous smoker, quit 5 years prior to presentation. She underwent left skin-sparing mastectomy and sentinel lymph node biopsy with immediate staged breast reconstruction using a tissue expander and acellular dermal matrix. The patient did not require postoperative chemotherapy or radiation. Unfortunately, she developed an implant infection after second stage of breast reconstruction that resulted in removal of implant. Several years following explantation, she started contemplating breast reconstruction and was interested in the DIEP flap. Despite focused attempts at weight gain with a dietician, she was unable to increase her BMI above 19.1, and she did not appear to have adequate skin laxity for a DIEP flap (► **Fig. 1**). Alternative autologous options, including latissimus flap, gluteal perforator flap, and transverse upper gracilis flap, were discussed which were not found acceptable by the patient. She also was hesitant to attempt another implant-based reconstruction due to her previous implant infection. Patient was followed up over a period of 5 years, as she was strongly interested in pursuing breast reconstruction but was not satisfied with options offered. During one of the clinic encounters, the patient stated that she had an identical twin who had volunteered (unprompted) to donate her excess abdominal tissue. They had discussed the "tissue donation" casually and were not sure if it was technically feasible but were interested in looking further into its possibility. The primary surgeon (W.M.) met with the patient's twin sister, and she was found to have appropriate abdominal tissue redundancy for a DIEP



**Fig. 1** Preoperative photo of the recipient prior to complications requiring implant removal.

flap harvest. Multiple clinic encounters took place with both patients for counseling and planning. A detailed family history was obtained showing that the twins had no other family history for breast or related cancers. The donor was extensively counseled on her own risk of developing breast cancer in the future. All potential reconstructive options were discussed with the donor should such circumstances arise, and she stated that she would desire either implant-based reconstruction, remain flat, or would be agreeable to autologous options other than a DIEP flap. Possible risks and complications of flap harvest from the abdominal area were explained to the donor twin. She was specifically informed that the surgery had no obvious benefit to her. The twin sister showed a good understanding of risks involved and consented to undergo the procedure. After confirming with both patients that they desired to move forward with transplantation surgery, the plastic surgery team's next step was to acquire approval from the participating hospital where the surgery would take place. A meeting was held with hospital's ethics committee in a multidisciplinary setting. The proposed surgery was deemed feasible and ethics committee concluded that the consent process was appropriate.

The transplantation literature was reviewed to identify appropriate screening and testing requirements for flap transplant. The twins underwent comparative deoxyribonucleic acid (DNA) sequencing at 21 small tandem repeats (STRs) from buccal samples, human leukocyte antigen (HLA), and blood group matching. Genetic testing (BRCA1/BRCA2) to evaluate breast cancer risk was performed. Detailed medical history and allergies were obtained. Both patients were evaluated for communicable diseases, including human immunodeficiency virus (HIV)-1, human T-lymphotropic virus type 1 (HTLV-1)/2, hepatitis C virus (HCV),

hepatitis B virus (HBV), syphilis, and cytomegalovirus (CMV).<sup>13</sup> Data including postoperative complications, surgery time, length of hospital stay, and follow-up were obtained from electronic medical records.

### Results

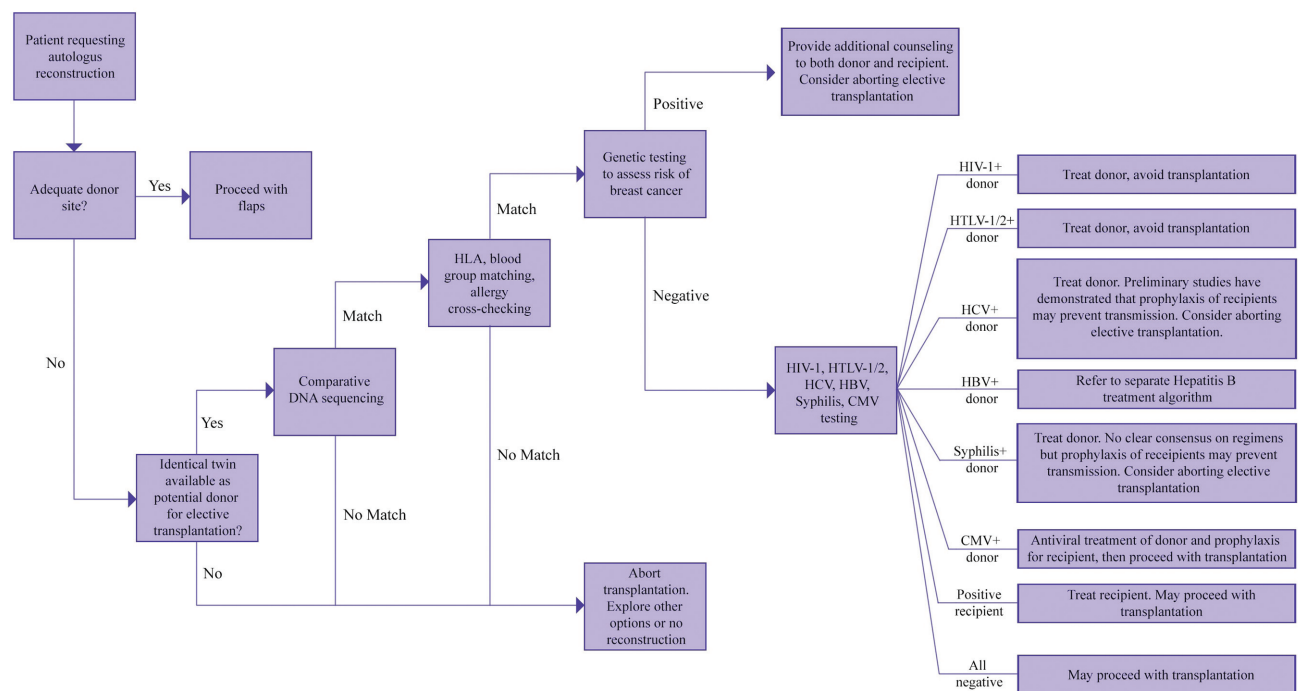
The twins were found to have greater than 99.99% probability of being monozygotic twins as per DNA sequencing. BRCA1/BRCA2 genetic testing was reported negative. The recipient was allergic to azithromycin, clindamycin, tazocillin-sulbactam, and chlorhexidine. The donor had no significant medical history or allergies. Tests for communicable diseases were negative except for the donor being CMV immunoglobulin G positive. She was started on valacyclovir 1 g every 8 hours 3 days prior to surgery. The recipient was started on the same regimen for 5 days after the transplant. An algorithm was developed during this process to help decision making in the future for similar flap transplantation cases (►Figs. 2 and 3).

The surgeries were simultaneously performed in adjacent operating rooms with two microsurgical teams. In the donor room, a bipediced conjoined DIEP flap was harvested with a total of five perforators. In the recipient room, the left internal mammary vessels were dissected using a microscope. The flaps were brought from the donor room to the recipient room in a sterile covered basin. The left and right flap vessels were anastomosed to the antegrade and retrograde internal mammary vessels. Operative times for donor and recipient were 662 and 674 minutes, respectively. The donor patient was admitted for two nights and required Foley catheterization for urinary retention that resolved before discharge. The recipient twin was admitted to hospi-

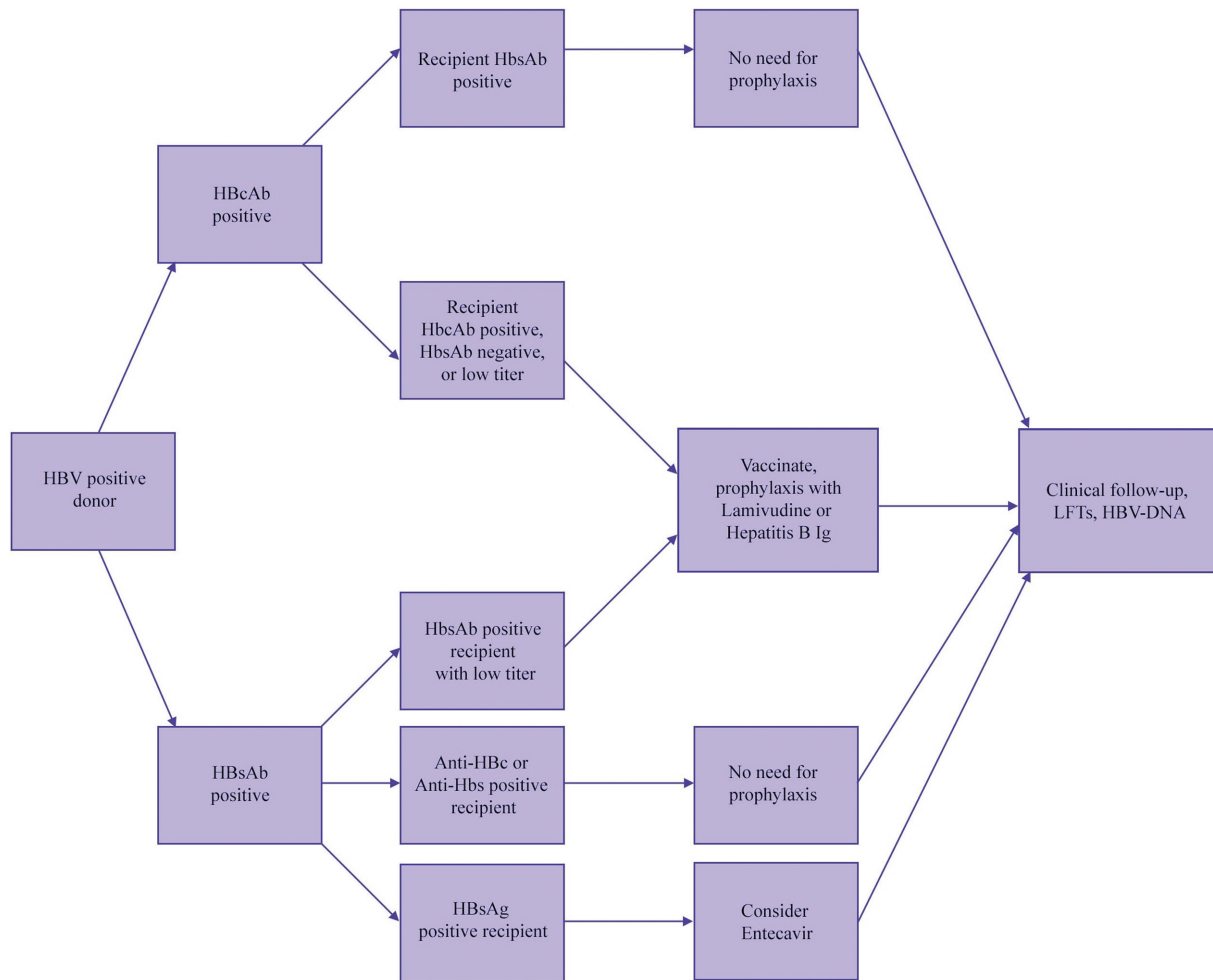
tal's specialized flap monitoring unit and discharged on postoperative day 5 without any events. Both patients recovered in expected time frame and were closely monitored in plastic surgery clinic. Three months after DIEP flap reconstruction, the recipient twin underwent flap revision for contouring and fat grafting. At 1-year follow-up both twins continued to heal well without complications (►Figs. 4 and 5). The recipient twin underwent another revision for right breast mastopexy and fat grafting to left reconstructed breast. The donor twin did not need any revisions. Currently, both patients are 5 years posttransplant and doing well without late-term complications.

### Discussion

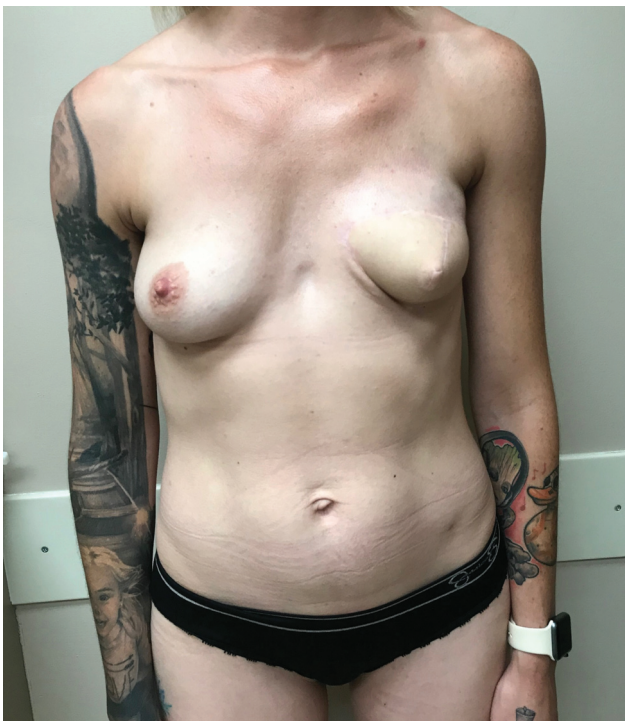Due to their tolerogenic potential, monozygotic twins have taken a central role in advancing transplantation science. Since the first successful kidney transplant performed on twins in 1954, the range of isogeneic transplants has expanded to include pancreas, liver, heart, small bowel, skin, rib cage, parathyroid, testicle, and lower extremity.<sup>14-22</sup> Compared to isogeneic solid organ transplants (SOTs), isogeneic soft tissue transplants are less frequently performed. Flap transplantation between monozygotic twins has been used for reconstruction of scalp, breast, and thoracic defects<sup>2-8</sup> (►Table 1). This is the fifth reported case of DIEP flap transfer for breast reconstruction in monozygotic twins, and the first to describe transplanting a bipediced flap to reconstruct a unilateral breast.<sup>2,3</sup> From an allogenic standpoint, myocutaneous flaps behave like vascularized composite allotransplants than SOTs; however, in the case of isogeneic transplant, immunosuppression is not needed.<sup>23</sup> Among the previously published flap transplantation cases,



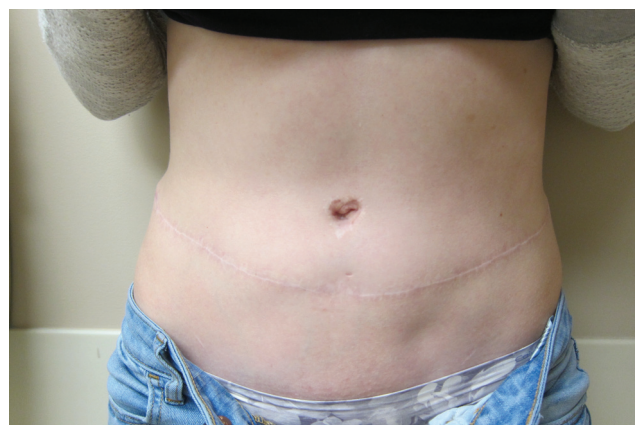**Fig. 2** Recommended preoperative workup prior to twin flap transplantation for breast reconstruction.



**Fig. 3** Recommended preoperative workup for hepatitis B screening.



**Fig. 4** Postoperative photo of the recipient at 1-year follow-up.



**Fig. 5** Postoperative photo of the donor at 1-year follow-up.

only one of the authors reported utilizing immunosuppression (1 month of short steroid taper) as recommended by their hospital's transplant service.<sup>7</sup> No flap transplant rejections were reported.

The algorithm (→Figs. 2 and 3) was designed based on studies examining SOT between twins as well as those studying soft tissue transplantation.<sup>2-6,14,16,17</sup> The first step is identifying that the twins are monozygotic. This is

**Table 1** Previously reported cases of free flap transplantation in monozygotic twins are listed below

Author	Procedure	Indication	Age	Zygosity testing	Immunosuppression	Follow-up	Results and complications
Allen et al, 2008	DIEP flap	Breast cancer. Failure of implant secondary to radiation, exposure, and infection	46 y	"DNA testing"	None	Unknown	No complications. No evidence of rejection
	SIEA flap	Breast cancer. Patient desired autologous reconstruction, previous history of abdominoplasty	n/r	"DNA testing"	None	Unknown	Debridement for distal inferolateral ischemic flap. No evidence of rejection
	DIEP flap	Breast cancer. Failure of implant reconstruction due to radiation, exposure, and infection. Patient desired autologous reconstruction, previous history of abdominoplasty	44 y	"DNA testing"	None	Unknown	Revision of contracted irradiated skin with fat grafting from twin. No evidence of rejection
Hazani et al, 2009	DIEP flap	Breast cancer. Patient undergoing bilateral mastectomy due to recurrence. Sufficient autologous tissue available for unilateral reconstruction only	53 y	STR sequence homology at 9 DNA alleles. HLA/ABO compatible	None	1 y	No complications. No evidence of rejection
Buncke et al, 1982 Valauri et al, 1990	Three free scalp flaps in 2 separate operations	MVA with avulsion of 50–60% of the parieto-occipital region. Repeated skin breakdown and poor cosmesis after skin graft and local flaps	30 y	HLA (type A3/A7) ABO identical. Mixed lymphocyte culture nonreactive. Finger print analysis: 90% likelihood of twins	None	Unknown	Venous congestion treated with leech therapy. Hematoma treated with evacuation. Infection treated with drainage, IV antibiotics, and hyperbaric oxygen. Successful hair growth and adequate coverage. No evidence of rejection
Park et al, 2016	Lattissimus dorsi myocutaneous flap	Soft tissue coverage of a thoraco-abdominal defect from separation of thoraco-omphalopagus conjoined twins	15 d	Conjoined at birth	None	100 d	Venous congestion compromising 1/3 of the flap treated with debridement. Eventual closure was planned but the neonate expired on day 100 secondary to heart failure
Banwell et al, 2011	Lattissimus dorsi myocutaneous flap	Soft tissue coverage of exposed thoracic spine instrumentation for severe kyphoscoliosis	19 y	DNA microsatellite homozygosity testing	None	1 y	Subsequent flap elevation for spinal hardware revision. Flap remains healthy without evidence of rejection
Selber et al, 2021	Bilateral DIEP	Soft tissue coverage of back wound following resection of recurrent plefixiform malignant histiocytic fibrosarcoma	56 y	Negative crossmatch, 10/10 HLA homozygosity	Steroid taper (1 mo)	2 y	No complications. No evidence of rejection

Abbreviations: DIEP, deep inferior epigastric artery perforator; DNA, deoxyribonucleic acid; HLA, human leukocyte antigen; IV, intravenous; MVA, motor vehicle accident; SIEA, superficial inferior epigastric artery; STR, small tandem repeat.

done by performing comparative DNA sequencing—in our patient, this was performed at 21 STRs from buccal samples. HLA and blood group matching is routinely performed as per SOT pretransplant protocols, as well as allergy cross-checking. Even though monozygotic twins have identical genetic code, many cellular and genetic mechanisms can cause discordant phenotypes and subtle differences due to factors such as environmental exposure, diet, and sporadic mutations.<sup>24–26</sup> The zygosity of twins may be thought of as more of a spectrum than simply binary. How this heterogeneity alters operational tolerance, need for immunosuppressive therapy, and ultimately clinical outcome is unclear. Traditionally, SOT between monozygotic twins utilized immunosuppressive therapy. Yet, transplant survival was found similar between patients with or without immunosuppression, suggesting that immunosuppression may be unnecessary.<sup>1,27</sup> Evidence supports that calculated withdrawal of immunosuppressants or complete omission is possible.<sup>28–30</sup> Since rejection events in monozygotic twin soft tissue transplants have not been reported, we felt it was acceptable in our case to proceed without immunosuppression. Selection or omission of immunosuppressive therapy should be individualized taking into consideration variation that can occur with age, environmental, or lifestyle factors.

Our next step of preoperative testing was to identify genetic predisposition to breast cancer. The twins were negative for BRCA1/BRCA2, but this is not overly reassuring, since these genes account for only 16% of total familial risk.<sup>31</sup> The cumulative lifetime incidence of breast cancer increases from 8 to 28% when a monozygotic cotwin is diagnosed.<sup>31</sup> Furthermore, when a twin is diagnosed before age 50, as with this patient, her cotwin's risk increases further. Finally, there could be other mutations not readily identified with current genetic testing protocols. Additional effort was undertaken with the donor twin to clarify her cancer risk so that she was prepared to make a well-informed decision.

Final step of preoperative workup was screening for communicable diseases such as HIV-1, HTLV-1/2, HCV, HBV, syphilis, and CMV, which were carried out following previously established SOT transplant policies<sup>13,32–35</sup> (► **Figs. 2** and **3**). In our case, the donor twin was found to be CMV positive via serology testing. Donor-positive/recipient-negative status is not an absolute contraindication for transplant and can be managed with either prophylactic therapy or preemptive treatment, or a combination of both.<sup>13</sup> Various protocols have been described, utilizing ganciclovir, valacyclovir, and valganciclovir.<sup>36,37</sup> After consultation with infectious diseases, the donor twin was started on valacyclovir 1 g every 8 hours 3 days prior to surgery, and the recipient was on the same regimen for 5 days after the transplant.

It should be emphasized that like many other transplant scenarios from a living donor, the most challenging aspect was not the surgery itself but the decision-making process. The ethical aspect of tissue transplantation for an elective reconstructive surgery was thoroughly discussed by a multidisciplinary committee. The risks pertaining to the donor and benefits to the recipient were reviewed carefully in this

regard. Our clinical teams met with both patients multiple times prior to the surgery to ensure transplantation was an acceptable decision for both twins. A psychological evaluation was not deemed necessary for our case as both patients demonstrated a good understanding of the plan and were in mutual agreement. However, we do believe similar transplantation scenarios may benefit from professional counseling to make this a well-reasoned and balanced care decision.

## Conclusion

Isogenic flap transplant is an alternative option to consider when autologous tissues are insufficient and monozygotic twins are present. Appropriate counseling of twins is critical for a successful and satisfactory outcome; potentially benefiting both in physical and mental aspects. Caregivers should not hesitate to seek additional counsel if necessary for psychological evaluation. The presented algorithm may guide surgeons in completing workup prior to attempting transfer.

### Ethical Approval

IRB approval (#281415) was obtained for retrospective review of the patient's charts.

### Funding

None.

### Conflict of Interest

None declared.

## References

- 1 Kessar N, Mukherjee D, Chandak P, Mamode N. Renal transplantation in identical twins in United States and United Kingdom. *Transplantation* 2008;86(11):1572–1577
- 2 Allen RJ Jr, LoTempio MM, Craigie JE, Allen RJ Sr. Transplantation in identical twins: another option for breast reconstruction. *Plast Reconstr Surg* 2008;122(04):1019–1023
- 3 Hazani R, Coots BK, Buntic RF, Brooks D. Bilateral breast reconstruction: the simultaneous use of autogenous tissue and identical twin isograft. *Ann Plast Surg* 2009;63(05):496–498
- 4 Buncke HJ, Hoffman WY, Alpert BS, Gordon L, Stefani AE. Microvascular transplant of two free scalp flaps between identical twins. *Plast Reconstr Surg* 1982;70(05):605–609
- 5 Valauri FA, Buncke HJ, Alpert BS, Lineaweaver WC, Argenta LC. Microvascular transplantation of expanded free scalp flaps between identical twins. *Plast Reconstr Surg* 1990;85(03):432–436
- 6 Banwell ME, Clibbon JJ, Sassoon EM. Transplantation of a latissimus dorsi flap between identical twins. *J Plast Reconstr Aesthet Surg* 2011;64(10):1366–1369
- 7 Selber JC, Kamani L, Torres K, et al. Successful double DIEP syngeneic transplantation across monozygotic twins for total back reconstruction. *Plast Reconstr Surg* 2021;148(05):1125–1133
- 8 Park JS, Park JJ, Kim DY, Eom JS. Emergency transplantation of free flap between separated thoraco-omphalopagus conjoined twins. *Arch Plast Surg* 2016;43(01):97–99
- 9 Maguire GP, Lee EG, Bevington DJ, Kuchemann CS, Crabtree RJ, Cornell CE. Psychiatric problems in the first year after mastectomy. *BMJ* 1978;1(6118):963–965
- 10 Penman DT, Bloom JR, Fotopoulos S, et al. The impact of mastectomy on self-concept and social function: a combined cross-

- sectional and longitudinal study with comparison groups. *Women Health* 1986;11(3-4):101-130
- 11 Pien I, Caccavale S, Cheung MC, et al. Evolving trends in autologous breast reconstruction: is the deep inferior epigastric artery perforator flap taking over? *Ann Plast Surg* 2016;76(05):489-493
  - 12 Kamali P, Paul MA, Ibrahim AMS, et al. National and regional differences in 32,248 postmastectomy autologous breast reconstruction using the Updated National Inpatient Survey. *Ann Plast Surg* 2017;78(06):717-722
  - 13 Fischer SA, Avery RKAST Infectious Disease Community of Practice. Screening of donor and recipient prior to solid organ transplantation. *Am J Transplant* 2009;9(Suppl 4):S7-S18
  - 14 Benedetti E, Dunn T, Massad MG, et al. Successful living related simultaneous pancreas-kidney transplant between identical twins. *Transplantation* 1999;67(06):915-918
  - 15 Liu LU, Schiano TD, Min AD, et al. Syngeneic living-donor liver transplantation without the use of immunosuppression. *Gastroenterology* 2002;123(04):1341-1345
  - 16 Yoshizawa A, Takada Y, Fujimoto Y, et al. Liver transplantation from an identical twin without immunosuppression, with early recurrence of hepatitis C. *Am J Transplant* 2006;6(11):2812-2816
  - 17 Blitzer D, Yedlicka G, Manghelli J, Dentel J, Caldwell R, Brown JW. Twin-to-twin heart transplantation: a unique event with a 25-year follow-up. *Ann Thorac Surg* 2017;103(04):e341-e342
  - 18 Barwick WJ, Oakes J, Goldberg JA. Closure of myelomeningocele using skin from stillborn twin. *Ann Plast Surg* 1993;30(02):171-174
  - 19 Turk E, Karagulle E, Turan H, et al. Successful skin homografting from an identical twin in a severely burned patient. *J Burn Care Res* 2014;35(03):e177-e179
  - 20 Segerberg EC, Grubb WG, Henderson AE. The first successful parathyroid transplant from an identical twin for the cure of permanent postoperative hypoparathyroidism. *Surgery* 1992;111(03):357-358
  - 21 Silber SJ. Transplantation of a human testis for anorchia. *Fertil Steril* 1978;30(02):181-187
  - 22 Fattah A, Cypel T, Donner EJ, Wang F, Alman BA, Zuker RM. The first successful lower extremity transplantation: 6-year follow-up and implications for cortical plasticity. *Am J Transplant* 2011;11(12):2762-2767
  - 23 Thaanat O, Badet L, Dubois V, Kanitakis J, Petruzzo P, Morelon E. Immunopathology of rejection: do the rules of solid organ apply to vascularized composite allotransplantation? *Curr Opin Organ Transplant* 2015;20(06):596-601
  - 24 Machin G. Non-identical monozygotic twins, intermediate twin types, zygosity testing, and the non-random nature of monozygotic twinning: a review. *Am J Med Genet C Semin Med Genet* 2009;151C(02):110-127
  - 25 Silva S, Martins Y, Matias A, Blickstein I. Why are monozygotic twins different? *J Perinat Med* 2011;39(02):195-202
  - 26 Day E, Kearns PK, Taylor CJ, Bradley JA. Transplantation between monozygotic twins: how identical are they? *Transplantation* 2014;98(05):485-489
  - 27 Krishnan N, Buchanan PM, Dzebisashvili N, Xiao H, Schnitzler MA, Brennan DC. Monozygotic transplantation: concerns and opportunities. *Am J Transplant* 2008;8(11):2343-2351
  - 28 Hüser N, Matevosian E, Schmidbauer P, et al. Calculated withdrawal of low-dose immunosuppression based on a detailed immunological monitoring after kidney transplantation between monozygotic twins. *Transpl Immunol* 2009;22(1-2):38-43
  - 29 Kim YK, Yoon HE, Kim SH, et al. Long-term follow-up of three identical twin transplant recipients without maintenance immunosuppressive therapy. *Nephrology (Carlton)* 2008;13(05):447-448
  - 30 Rao Z, Huang Z, Song T, Lin T. A lesson from kidney transplantation among identical twins: case report and literature review. *Transpl Immunol* 2015;33(01):27-29
  - 31 Mucci LA, Hjelmborg JB, Harris JR, et al; Nordic Twin Study of Cancer (NorTwinCan) Collaboration. Familial risk and heritability of cancer among twins in Nordic countries. *JAMA* 2016;315(01):68-76
  - 32 Gonçalves DU, Proietti FA, Ribas JG, et al. Epidemiology, treatment, and prevention of human T-cell leukemia virus type 1-associated diseases. *Clin Microbiol Rev* 2010;23(03):577-589
  - 33 Woolley AE, Singh SK, Goldberg HJ, et al; DONATE HCV Trial Team. Heart and lung transplants from HCV-infected donors to uninfected recipients. *N Engl J Med* 2019;380(17):1606-1617
  - 34 Veroux M, Ardita V, Corona D, et al. Kidney transplantation from donors with hepatitis B infection. *Med Sci Monit* 2016;22(22):1427-1434
  - 35 Cortes NJ, Afzali B, MacLean D, et al. Transmission of syphilis by solid organ transplantation. *Am J Transplant* 2006;6(10):2497-2499
  - 36 Boeckh M, Ljungman P. How we treat cytomegalovirus in hematopoietic cell transplant recipients. *Blood* 2009;113(23):5711-5719
  - 37 Ramanan P, Razonable RR. Cytomegalovirus infections in solid organ transplantation: a review. *Infect Chemother* 2013;45(03):260-271