

# Potential role of a novel endoscopic retrieval bag for large colorectal resected specimen: a proof-of-concept study

**OPEN  
ACCESS**

## Authors

Yasuhiro Tani<sup>1</sup>, Yoji Takeuchi<sup>1</sup>, Yuya Asada<sup>1</sup>, Yuki Okubo<sup>1</sup>, Yushi Kawakami<sup>1</sup>, Satoki Shichijo<sup>1</sup>, Takashi Kanesaka<sup>1</sup>, Koji Higashino<sup>1</sup>, Noriya Uedo<sup>1</sup>, Tomoki Michida<sup>1</sup>, Ryu Ishihara<sup>1</sup>, Kiyokazu Nakajima<sup>2</sup>

## Institutions

- 1 Gastrointestinal Oncology, Osaka International Cancer Institute, Osaka, Japan
- 2 Department of Gastroenterological Surgery, Osaka University Graduate School of Medicine, Suita, Japan

received 30.1.2023

accepted after revision 15.5.2023

accepted manuscript online 23.5.2023

## Bibliography

Endosc Int Open 2023; 11: E714–E718

DOI 10.1055/a-2098-2664

ISSN 2364-3722

© 2023. The Author(s).

This is an open access article published by Thieme under the terms of the Creative Commons Attribution-NonDerivative-NonCommercial License, permitting copying and reproduction so long as the original work is given appropriate credit. Contents may not be used for commercial purposes, or adapted, remixed, transformed or built upon. (<https://creativecommons.org/licenses/by-nc-nd/4.0/>)

Georg Thieme Verlag KG, Rüdigerstraße 14,  
70469 Stuttgart, Germany

## Corresponding author

MD. Yoji Takeuchi, Osaka International Cancer Institute,  
Gastrointestinal Oncology, Osaka, Japan  
yoji.endoscopy@oici.jp  
yojit1@mac.com

## ABSTRACT

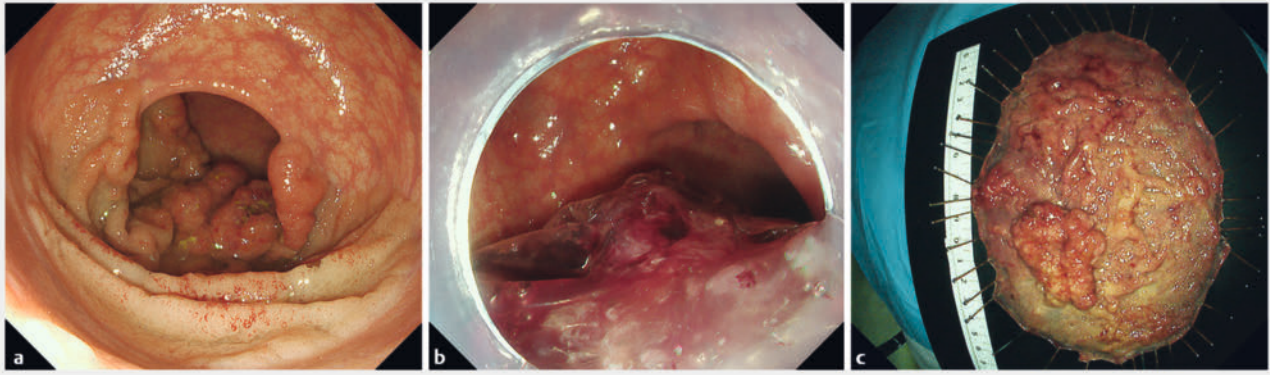
Endoscopic submucosal dissection enables en bloc resection of large superficial colorectal neoplasms. However, it is sometimes challenging to retrieve a large resected specimen via the anus without sample fragmentation. A novel “bag-type” retrieval device has been developed to accomplish complete isolation and non-destructive delivery of oversized specimens. This single-center retrospective study was performed to demonstrate the efficacy of this device for large colorectal resected specimens. Among 17 patients, we identified 18 superficial colorectal lesions for which the use of a novel retrieval device (Endo Carry Large Type) was indicated at specimen delivery at a referral cancer institute from March 2021 to July 2022. The median (interquartile range) tumor size was 62.5 (52.0–79.5) mm. Retrieval of 17 (94%) of 18 resected specimens was performed using the Endo Carry Large Type, and 16 (89%) were successfully retrieved without sample fragmentation. The median (interquartile range) retrieval time was 4 (4–8) minutes, and no apparent adverse events were observed. The novel Endo Carry Large Type device can accomplish colorectal specimen retrieval safely and quickly without specimen damage and therefore may contribute to accurate pathological diagnosis.

## Introduction

Endoscopic resection of colorectal polyps has made remarkable progress and has facilitated challenging resection of larger lesions. In particular, endoscopic submucosal dissection (ESD) enables en bloc resection of large superficial colorectal neoplasms, thus reducing local recurrence and facilitating accurate pathological assessment [1]. However, it is sometimes challenging to retrieve a large resected specimen via the anus without fragmentation because the anus is too narrow for large lesions to pass through. Fragmentation of a resected specimen sacrifices the effort involved in en bloc resection for accurate patho-

logical diagnosis. Therefore, several techniques for retrieval of large resected specimens have been developed [2, 3, 4].

We previously published a video case report using a novel retrieval device, the Endo Carry Large Type (Hakko Co., Tokyo, Japan) [5]. This device enables complete isolation of the specimen in the bag followed by protective retrieval via the anus. This study was performed to show the efficacy of this novel retrieval device for removal of large colorectal resected specimens.



► **Fig. 1** **a** Colonoscopy revealed a 150-mm lesion in the rectum. **b** The lesion was resected with endoscopic submucosal dissection and enclosed in the bag. **c** Macroscopic appearance of the resected specimen.

## Materials and methods

### Study design and patients

This was a single-center retrospective study. We reviewed medical records and identified superficial colorectal lesions for which use of the Endo Carry Large Type was indicated for retrieval of the resected specimen at Osaka International Cancer Institute from March 2021 to July 2022. This retrieval device was used to remove endoscopically resected specimens >4 cm that were considered too large to retrieve without fragmentation by conventional retrieval devices or that had undergone failed retrieval by conventional retrieval devices.

### Endoscopic resection of large colorectal neoplasms

In our facility, ESD was mainly performed for large superficial colorectal neoplasms. A FlushKnife BT (1.5 mm, DK2618JB; FUJIFILM Medical Co., Ltd., Tokyo, Japan) and Coagrasper (FD-410LR; Olympus Corporation, Tokyo, Japan) were used for electrical cutting and hemostasis, respectively, using an electrosurgical unit (VIO300D; ERBE, Tübingen, Germany). ESD was performed according to a standardized method as previously described [6]. Polypectomy was also performed for pedunculated lesions if the stalk was able to be strangled by a 30-mm oval-type electrosurgical snare (Lariat Snare; Steris, Mentor, Ohio, United States). ESD was performed for lesions with a stalk that was too thick to strangle with a snare.

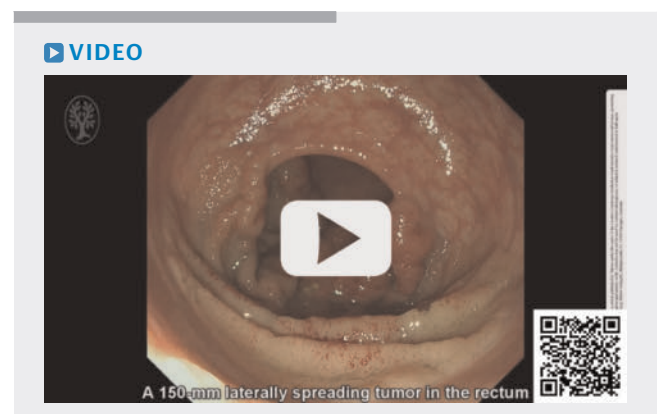
### Endo Carry Large Type

The Endo Carry Large Type is a modification of an existing endoscopic retrieval device, the Endo Carry (Hakko Co.). The original Endo Carry has a large drawstring-type bag to use through the scope. The bag of the original Endo Carry was 40 mm in diameter and 20 mm deep, much larger than conventional products. To maintain the capacity of the bag of the original Endo Carry, it is designed so that the bag portion cannot be restored in the sheath portion of the device after opening the bag portion, even when it is completely closed. We redesigned the bag to increase its capacity (60 mm in diameter and 40 mm in depth). As a result, the capacity of the new bag, the Endo Carry Large

Type, increased from 3 to 20 mL. Because this new bag no longer passed through the endoscope, the sheath portion was shortened to a length of 1000 mm to facilitate its operation independently of the endoscope.

### Retrieval technique

The retrieval procedure using the Endo Carry Large Type is as follows. When the lesion is not located in the rectum, the resected specimen should be transferred to the rectum using endoscopic forceps. The endoscope is pulled out and the tip of the endoscope is covered by the open bag of the Endo Carry Large Type. The endoscope with the Endo Carry Large Type is reinserted through the anus using a sufficient amount of lubricating jelly. The endoscope is withdrawn within the rectum to free it from the open bag. The specimen is placed in the bag under endoscopic vision using endoscopic forceps. The snare is pulled and the specimen is completely enclosed in the bag. The Endo Carry Large Type is pulled out and the specimen is retrieved without fragmentation through the anus. A representative case is shown in ► **Fig. 1** and ► **Video. 1**.



► **Video 1** A representative case in which a large resected specimen was retrieved with the Endo Carry Large Type

## Clinical findings and outcome definitions

The location, morphology, lesion size, and specimen size were reviewed in the medical records. The macroscopic nodule size of protruding lesions was estimated based on the recorded endoscopic images of resected specimens. We reviewed all recorded videos of endoscopic procedures, and the retrieval time was defined as the time from reinsertion of the colonoscope with the Endo Carry Large Type to extraction of the resected specimen in minutes. Technical success was defined as retrieval of the resected specimen with the Endo Carry Large Type, allowing for split collection of lesions not resected en bloc. Clinical success was defined as retrieval of the specimen with no fragmentation of the specimen.

## Histological assessment

Resected specimens were fixed in 10% formalin and cut into 2-mm slices. After the specimens were embedded in paraffin, they were sliced into 3  $\mu$ m-thick sections and stained with hematoxylin and eosin. Histological assessments were performed according to the Japanese Classification of Colorectal, Appendiceal, and Anal Carcinoma: the 3rd English Edition [7].

## Ethics

This study protocol was approved by the Ethics Committee of Osaka International Cancer Institute (No.21158). All participants were provided opportunities to decline study participation prior to the present investigation using the opt-out method on our hospital website.

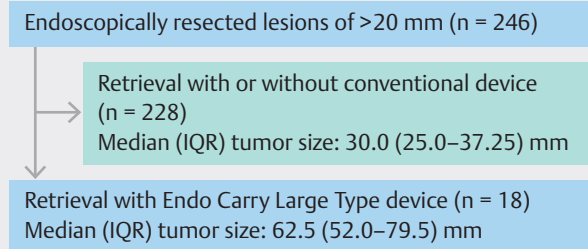
## Results

### Patients and lesions

In total, 246 lesions larger than 2 cm were endoscopically resected at Osaka International Cancer Institute from March 2021 to July 2022, and 18 lesions in 17 patients were retrieved with the Endo Carry Large Type (► Fig. 2). Sixteen lesions were treated with ESD and two lesions with polypectomy. The median (interquartile range [IQR]) tumor size was 62.5 mm (IQR 52.0–79.5), and 16 lesions were resected en bloc. The median (IQR) estimated macroscopic nodule size of the 17 lesions, excluding one superficial lesion (0-IIa+IIc), was 50 mm (IQR 35–60). Ten lesions were located in the rectum and eight in the colon. The characteristics of the patients and lesions are summarized in ► Table 1.

### Clinical outcomes

The technical success rate and clinical success rate were 94% (17/18, 95% confidence interval [CI] 72.7%–99.9%) and 89% (16/18, 95% CI 65.3%–98.6%), respectively. Technical failure was encountered for a circumferential lesion in the lower rectum that was impossible to enclose in the bag. Although the specimen was finally extracted with forceps, fragmentation was observed. Clinical failure occurred for a pedunculated lesion in the sigmoid colon. Although the lesion was too large to pull out of the anus after storing it in the Endo Carry Large Type bag, the patient was able to excrete the lesion by straining on



► Fig. 2 Study flowchart. IQR, interquartile range.

► Table 1 Characteristics of patients, lesions, and outcomes.

	17 cases 18 lesions
Median age, years (range)	63 (40–82)
Sex, n	
Male/Female	9/8
Location, n	
Right colon/left colon/rectum	4/4/10
Macroscopic type, n	
0-Ip/0-Isp/0-Is/0-IIa+IIc/LST-GM	2/1/2/1/12
Median (IQR) tumor size, mm	62.5(52–79.5)
Endoscopic resection, n	
ESD/polypectomy	16/2
Histology	
HGA/Tis in adenoma/T1b/T2	2/12/3/1
En bloc resection rate, % (n), [95% CI]	89% (16/18) [65.3–98.6]
Technical success rate, % (n), [95% CI]	94% (17/18) [72.7–99.9]
Clinical success rate, % (n), [95% CI]	89% (16/18) [65.3–98.6]
Median (IQR) retrieval time, minutes	4 (4–8)
IQR, interquartile range; ESD, endoscopic submucosal dissection; HGA, high-grade adenoma; CI, confidence interval; LST-GM, laterally spreading tumor-granular nodular mixed type.	

his own while the specimen was still contained within the Endo Carry Large Type bag. However, fragmentation of the specimen was observed. The median (IQR) retrieval time was 4 minutes (IQR, 4–8). Patient clinical outcomes are summarized in ► Table 1. No apparent adverse events (AEs) related to use of the Endo Carry Large Type were observed.

## Discussion

In this study, the Endo Carry Large Type was used for retrieval of 18 endoscopically resected specimens. The technical success rate and clinical success rate were 94% and 89%, respectively. The device enabled retrieval of lesions up to 150 mm in diameter without fragmentation. The median retrieval time was

short, and no AEs associated with the use of this novel retrieval device were observed.

As the lesion size increases, the incidence of invasive cancer increases. Because depth of invasion determines the need for additional treatment [8,9], it is important to accurately determine the presence and depth of invasion. Theoretically, en bloc resection of specimens provides better pathological information than piecemeal resection. However, as lesion size increases, damage to the lesion more readily occurs during retrieval through the narrow anus. The Endo Carry Large Type enables retrieval of large lesions without fragmentation. This device will maximize the advantages of ESD, which can enable resection of large lesions en bloc.

Conventional endoscopic retrieval devices used through the working channel are limited by the size of the specimen that can be placed into the bag and passed through the narrow channel. The most important feature of the Endo Carry Large Type is that it is not passed through the endoscopic working channel. In addition, the bag does not need to be completely retracted into the device sheath because of its structure, which resembles a drawstring bag, ensuring maximal capacity of the bag. These features increase the capacity of the bag and allow large resected specimens to be protectively retrieved. Moreover, although cooperation between the endoscopist and assistant is important for use of this device, its simple operation and high follow-up performance make it easy to handle even for inexperienced assistants. In fact, although this device was handled by assistants who had used it for the first time or only a few times in this study, the median retrieval time was only 4 minutes.

Several techniques have been developed to retrieve large resected specimens after ESD. One such technique involves the Valsalva maneuver and is known as tumor extraction by defecation (TED) [4]. However, the TED procedure requires the patient to defecate, which may be difficult depending on the depth of sedation. Our novel retrieval device can be used regardless of the depth of sedation. Tanaka et al. [2] reported a retrieval method using a small grip-seal plastic bag. While this method is effective for retrieving large colorectal resected specimens, the procedure is complicated and the bag is not designed for use with colonoscopy. Therefore, some patients complain of pain when the bag passes through the anus. In contrast, the Endo Carry Large Type was designed for use with colonoscopy and is considered more generalizable.

In the present study, two lesions could not be retrieved without fragmentation of the specimens. One lesion was too large to enclose within the bag because it was an entire circumferential lesion in the rectum and its size was 120 mm in diameter. The other lesion could be enclosed within the bag, but the specimen could not be retrieved via the anus, probably because the patient was a young man and the contraction of his anal sphincter was strong. The specimen was finally retrieved with the TED method while keeping the bag closed, but fragmentation was observed. These lesions are deemed difficult to retrieve with no fragmentation by any device.

The Endo Carry Large Type can be used in the rectum only because it is difficult to insert into the colon, and large lesions

must be brought from the colon to the rectum. However, there is currently no comparable method to retrieve such a large colonic lesion that cannot be brought to the rectum; such a lesion must be fragmented to bring to the rectum. To our knowledge, the Endo Carry Large Type is the most effective device with which to retrieve a large lesion through the anus. This study is limited by the possibility of selection bias due to the retrospective design, although the patients were consecutively enrolled. In addition, this was a single-center, single-group study, which may limit the generalizability of the results to other settings.

## Conclusions

In conclusion, the novel Endo Carry Large Type device can accomplish colorectal specimen retrieval safely and quickly without specimen damage and, therefore, may contribute to accurate pathological diagnosis.

## Acknowledgement

We thank Angela Morben, DVM, ELS, from Edanz (<https://jp.edanz.com/ac>) for editing a draft of this manuscript.

## Conflict of Interest

Satoki Shichijo has received personal fees from Olympus Corporation, Daiichi-Sankyo, EA Pharma, AstraZeneca, AI Medical Service Inc., and Janssen Pharmaceutical. Takashi Kanesaka has received personal fees from Olympus Corporation. Yoji Takeuchi received honoraria for his lectures from Olympus, Boston Scientific (Japan), Daiichi-Sankyo, Miyarisan Pharmaceutical, Asuka Pharmaceutical, AstraZeneca, EA Pharma, Zeria Pharmaceutical, Fujifilm, Kaneka Medix, Kyorin Pharmaceutical, and the Japan Gastroenterological Endoscopy Society. Noriya Uedo has received personal fees from Olympus Corporation, Boston Scientific Japan, FUJIFILM Medical Co., Ltd., Daiichi-Sankyo, Takeda Pharmaceutical, EA Pharma, Otsuka Pharmaceutical, AstraZeneca, AI Medical Service Inc., and Miyarisan Pharmaceutical. Ryu Ishihara has received personal fees from Olympus Corporation, FUJIFILM Medical Co., Ltd., Daiichi-Sankyo, Ono Pharmaceutical, EA Pharma, and AstraZeneca. The other authors have no financial relationships to disclose.

## Funding

Japan Agency for Medical Research and Development  
<http://dx.doi.org/10.13039/10000961922ck0106556h0003>

## References

- [1] Ohata K, Kobayashi N, Sakai E et al. Long-term outcomes after endoscopic submucosal dissection for large colorectal epithelial neoplasms: a prospective, multicenter, cohort trial from Japan. *Gastroenterology* 2022; 163: 1423–1434.e2
- [2] Tanaka S, Toyonaga T, East J et al. Endoscopic retrieval method using a small grip-seal plastic bag for large colorectal resection specimens after endoscopic submucosal dissection. *Endoscopy* 2010; 42: E186–E187 doi:10.1055/s-0029-1244168

- [3] Ikehara H, Saito Y, Uraoka T et al. Specimen retrieval method using a sliding overtube for large colorectal neoplasm following endoscopic submucosal dissection. *Endoscopy* 2015; 47: E168–E169 doi:10.1055/s-0034-1391496
- [4] Nemoto D, Hayashi Y, Utano K et al. A novel retrieval technique for large colorectal tumors resected by endoscopic submucosal dissection: tumor extraction by defecation. *Endosc Int Open* 2016; 4: E93–E95 doi:10.1055/s-0041-107902
- [5] Inoue T, Shichijo S, Nakajima K. Novel protective retrieval device for a large rectal cancer specimen resected by endoscopic submucosal dissection. *Dig Endosc* 2021; 33: e129–e130 doi:10.1111/den.14064
- [6] Takeuchi Y, Uedo N, Ishihara R et al. Efficacy of an endo-knife with a water-jet function (Flushknife) for endoscopic submucosal dissection of superficial colorectal neoplasms. *Am J Gastroenterol* 2010; 105: 314–322
- [7] Japanese Society for Cancer of the Colon and Rectum. Japanese classification of colorectal, appendiceal, and anal carcinoma: the 3d English edition [secondary publication]. *J Anus Rectum Colon* 2019; 3: 175–195 doi:10.23922/jarc.2019-018
- [8] Hashiguchi Y, Muro K, Saito Y et al. Japanese Society for Cancer of the Colon and Rectum (JSCCR) guidelines 2019 for the treatment of colorectal cancer. *Int J Clin Oncol* 2020; 25: 1–42 doi:10.1007/s10147-019-01485-z
- [9] Pimentel-Nunes P, Libânio D, Bastiaansen BAJ et al. Endoscopic submucosal dissection for superficial gastrointestinal lesions: European Society of Gastrointestinal Endoscopy (ESGE) Guideline – Update 2022. *Endoscopy* 2022; 54: 591–622 doi:10.1055/a-1811-7025